Challenges in the Medical and Surgical Management of Chronic Inflammatory Bowel Disease

Ellen H. Bailey, MD, Sean C. Glasgow, MD*

KEYWORDS

• Crohn's disease • Ulcerative colitis • Intestinal fistula • Intestinal failure
• Intestinal pouch complications • Venothromboembolism

KEY POINTS

- Inflammatory bowel disease is often a chronic relapsing medical condition requiring a multidisciplinary team and thoughtful surgical approach for optimal outcomes.
- Intestinal fistula is a devastating but well-recognized complication of Crohn's disease, and the management approach involves nutritional optimization, wound containment, and careful operative planning.
- Crohn's disease after multiple resections or long segment involvement can result in short bowel syndrome, and the challenges of ongoing nutritional support are discussed.
- Intestinal pouches are a popular alternative to permanent stoma after total proctocolectomy, and this article addresses several common complications and management strategies.
- Increasing awareness of elevated venous thromboembolic events in the inflammatory bowel disease population mandates mention and aggressive prophylaxis during hospitalization and postoperatively.

INTRODUCTION

An estimated 1.6 million Americans are living today with inflammatory bowel disease, and as many as 70,000 new cases are diagnosed annually.[1] About half of all individuals with ulcerative colitis achieve remission, but recurrence is not uncommon after cessation of medical therapy, and up to 35% will require re-treatment within

Disclosure Statement: The authors have nothing to disclose.
Section of Colon & Rectal Surgery, Department of Surgery, Washington University School of Medicine, 660 South Euclid Avenue, Campus Box 8109, St Louis, MO 63110, USA
* Corresponding author.
E-mail address: GLASGOWS@WUDOSIS.WUSTL.EDU

Surg Clin N Am 95 (2015) 1233–1244
http://dx.doi.org/10.1016/j.suc.2015.08.003 **surgical.theclinics.com**
0039-6109/15/$ – see front matter Published by Elsevier Inc.

1 year.[2] At any given time, 50% of Crohn patients are in remission with medical therapy, but maintenance of treatment is recommended for several years.[3] Unfortunately, recurrences are frequent in Crohn's disease, with relapse rates of 20% at 1 year, 40% at 2 years, 67% at 5 years, and 79% at 10 years.[4] This patient population faces an increasing number of medical therapies with frequent changes in regimens. The side-effect profiles and cumulative costs are not insignificant.

About 20% of patients with ulcerative colitis will require surgery during their lifetime, and up to 80% of individuals with Crohn's disease will undergo operative intervention.[5] Crohn's disease recurs in nearly 30% of people within 3 years after resection and 60% at 10 years after resection.[6] Up to 70% of patients are estimated to need repeat resections for Crohn.[7] Surgeries performed for inflammatory bowel disease are not without complications and require careful, multidisciplinary approaches for best outcomes. Several specific and challenging complications arising from long-term inflammatory bowel disease and its surgical management are discussed.

INTESTINAL FISTULA

By definition, this process involves only those patients with Crohn's disease, because ulcerative colitis does not demonstrate transmural inflammation except in the acute setting when perforation is more likely than fistulization. An estimated 5% to 15% of Crohn patients will experience this disease-related complication during their lifetime.[8] A fistula is a connection between 2 epithelialized surfaces and is commonly identified by the 2 involved organs (ie, enterocolonic or colovaginal). Enteroenteric fistulas can present on a spectrum from asymptomatic and an incidental finding at the time of exploration or imaging to debilitating and lifestyle limiting. For the purpose of this review, only the symptomatic variety is addressed, beginning with the troublesome and morbid enterocutaneous fistula.

The acute management of an enterocutaneous fistula in a patient with inflammatory bowel disease is focused on stabilizing the individual because they often present with sepsis, volume depletion, and malnutrition.[9] This process involves a several-pronged approach (**Box 1**) that is largely preserved since the original publication of management guidelines in 1964 by Chapman and colleagues.[10] The key elements include draining intra-abdominal sepsis, correcting volume depletion, and managing the effluent by protecting the skin. Measurements such as body mass index (BMI) and serum albumin can help estimate the degree of malnutrition.[11] Nutritional support should be initiated when the resuscitation is complete, and the enteral route is preferred if feasible to maintain the intestinal lining and use hormonal and absorptive functions. Patients with daily fistula output greater than 1500 mL typically require intravenous fluid replacement. Malnourishment due to proximal fistula losses can be subtle and requires close surveillance with serial nutrition laboratory tests (serum albumin, prealbumin, iron studies, electrolyte panels). Enteral feeding may not be tolerated if it significantly increases fistula output, and total parenteral nutrition (TPN) is another viable option.[12] Complications related to long-term TPN use are well established and are discussed in more detail later in the section on short bowel syndrome.

For ongoing patient support with fluids and nutrition as well as surgical planning, it is useful to define the fistula based on anatomic location and volume of output. Proximal small bowel fistulae are commonly high output (>500 mL/d) and less likely to close when compared with colonic or low output fistulae (<200 mL/d). Spontaneous closure of fistulae is rarely seen in Crohn's disease because ongoing inflammation or distal obstruction is usually present.[13] The amount of residual uninvolved bowel must be noted in this patient population for surgical planning. Antitumor necrosis factor therapy

Box 1
Approach to inflammatory bowel disease–related enterocutaneous fistula

Stabilize the patient

- Manage sepsis
  - Empiric systemic antibiotics as indicated
  - Remove infected central lines
  - Radiologic drainage of intra-abdominal fluid collections
  - Avoid acute operative intervention if possible
- Restore intravascular volume status
- Control wound effluent and protect abdominal skin

Optimize the patient

- Assess nutritional status objectively
- Enteral (preferred) or parenteral nutrition
- Measure daily wound effluent
- Manage abdominal wound
  - Negative pressure wound therapy
  - Ostomy appliance or large wound manager
  - Avoid simple gauze dressings
- Stop corticosteroids if possible

Surgical planning

- Quantify length of remaining bowel
- Localize enteric fistula
- Define remaining active inflammatory bowel disease (if any)
- Determine need for complex abdominal wall reconstruction

has shown modest success in perianal fistula closure but has not demonstrated similar results in enterocutaneous fistulae.[14] Wound management is often problematic in these patients (Fig. 1). Generally, routine wet-to-dry dressings with cotton gauze should be avoided because they poorly control effluent and serve no function for wound

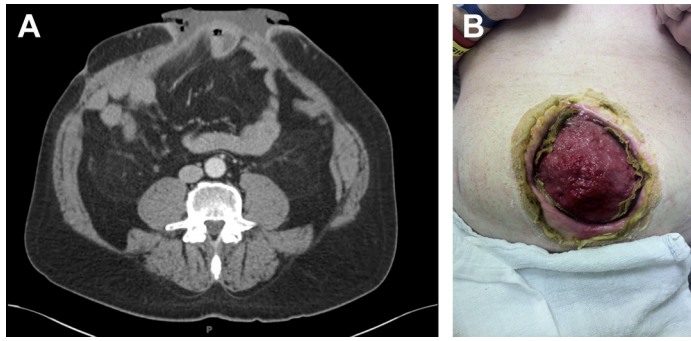

Fig. 1. (*A*) Abdominal computed tomographic scan showing open wound with underlying enteric fistula that occurred following reoperative ileocolic resection and subsequent dehiscence. (*B*) Clinical appearance of same patient. Note the previously placed polypropylene mesh at the edges of the open wound.

debridement. When possible, negative pressure wound therapy is used to speed development of granulation tissue, accelerate wound edge contraction, and control drainage.[15] Effort is required to avoid applying the vacuum dressing to the actual fistula, because this may overwhelm the collecting system and prevent adequate sealing. Creative techniques for wound management are described in the literature.[16,17]

A variety of medical therapies exist to aid in managing the patient with an enterocutaneous fistula. Most patients will require antidiarrheals to reduce fluid losses. Loperamide primarily inhibits μ-opioid signaling in the myenteric plexus (parasympathetic system) of the gastrointestinal tract, thereby impairing smooth muscle contractions and slowing intestinal transit. Patients may also benefit from reducing gastric acid and fluid secretion through the routine use of a proton pump inhibitor such as pantoprazole. Octreotide, a somatostatin analogue, has not shown efficacy in decreasing need for surgery in Crohn-associated enterocutaneous fistulae.[18] Antibiotic therapy for intestinal fistulae is limited to scenarios with sepsis or small bowel overgrowth.[19] The nonspecific signs and symptoms of small intestine bacterial overgrowth include diarrhea, abdominal pain, and bloating and overlap broadly with other pathologic conditions. No gold-standard diagnostic test exists, so empiric antibiotic therapy (frequently rifaximin) is often initiated, and clinical improvement supports this diagnosis.[20,21] Evidence exists to suggest that steroids worsen outcomes in complex Crohn's disease including those patients with internal fistulae,[19] and immunologics, particularly infliximab, likely do not have a role in the treatment of enterocutaneous fistulae.[22] Mahadevan and colleagues[23] demonstrated some improvement in CD fistulae with methotrexate in a small case series. In general, the diseased segment of bowel resulting in the fistula requires surgical resection.

Operative therapy for enterocutaneous fistulae begins with stabilization of the patient as described above and also a period of watchful waiting for the inflammatory intra-abdominal process to improve. The ideal duration of expectant management is widely accepted to be at least 6 months due to the associated obliterative peritonitis.[24] The need for patience in treating Crohn-related enterocutaneous fistulas cannot be overemphasized and must be reinforced to the patient, their family, and other consulting physicians. Before operative intervention, a complete radiographic "road map" is useful. The authors typically use magnetic resonance enterography to evaluate for other areas of active disease (aside from the fistula itself). Water-soluble contrast enemas may also aid in establishing the length of remaining distal bowel and to ensure prior ileocolonic anastomoses have not strictured. The procedure begins with a carefully planned incision with forethought given toward performing an abdominal closure with well-vascularized tissue. The intra-abdominal anatomy is well defined with a meticulous lysis of adhesions from the ligament of Treitz to the rectum if necessary to delineate the involved segment.[25] Following restoration of gastrointestinal continuity, complex abdominal wall reconstruction is frequently required. Unilateral or bilateral component separation should be performed to reduce tension on the midline closure. Ideally, bridging the gap between rectus muscles should be avoided. When bridging with mesh is required, the authors favor using biological mesh such as Strattice (LifeCell, Bridgewater, NJ, USA), with the understanding that subsequent incisional hernia repair may be needed.

SHORT BOWEL SYNDROME

Classically short bowel is defined by loss of absorptive surface to the degree that patients demonstrate dehydration and malnutrition necessitating supplementation for health maintenance. This complication is usually observed when less than 200 cm

of small bowel remain proximal to a stoma or less than 100 cm of small bowel remain proximal to an enterocolostomy, although every patient responds differently, and long-term adaptations can lead to recovery of bowel function. A longer segment of diseased bowel in situ may demonstrate worse function than a shorter length of healthy intestine. Multiple bowel resections in Crohn's disease remain the number one cause of short bowel syndrome.[26]

A recent retrospective study from Watanabe and colleagues[27] showed increasing incidence of intestinal failure (defined as dependence on intravenous infusional therapy at least twice weekly for a year or more) with time since initial operation. In this study group, 8.5% of Crohn's disease patients had developed short bowel syndrome by 20 years after their first resection, and the individuals experiencing intestinal failure averaged 3.3 operations over their lifetime. For this reason, the surgical principles of bowel conservation in the Crohn patient population are mandatory. These measures include bowel-sparing procedures such as stricturoplasty when appropriate as well as minimization of gross resection margins and maximizing medical management before undertaking surgery.[28]

Medical optimization of patients with intestinal failure focuses on avoiding dehydration, acid/base disturbances, vitamin deficiencies (especially fat-soluble vitamins A, D, E, and K), and malnutrition. TPN is often used in the acute phase of postoperative intestinal failure, but with the adaptations of crypts and villi hypertrophy, this may be discontinued or at least weaned over time.[29] Although intestinal adaptation is more common in children, diseased remaining bowel in Crohn patients may adapt more slowly or not at all. Life-long parenteral nutrition may be necessary in a subset of patients with intestinal failure, along with associated hazards such as bloodstream infections and thromboembolic risks due to the required indwelling central venous catheter and multifactorial hepatic dysfunction.[30]

Various pharmacologic agents, supplements, and growth factors have shown promise in the support of patients with intestinal failure. Antimotility agents effectively slow intestinal transit time in many patients with proximal stomas.[26] Somatostatin analogues such as octreotide act globally to reduce all digestive secretions, thereby decreasing excreted fluid load. However, octreotide seems to lose efficacy and is not a long-term therapy in this patient population.[31] A landmark randomized, controlled, double-blind study by Byrne and colleagues[32] examining the use of human growth hormone (somatropin (rDNA); Zorbtive) with or without supplemental oral glutamine found a decrease in the need for parenteral calories and fluid volume after 4 weeks of treatment. However, on pooled analysis of several studies, durable benefits have not been demonstrated with either therapy in short bowel syndrome.[33]

In late 2012, the US Food and Drug Administration approved teduglutide (Gattex) injections for the treatment of short bowel syndrome secondary to many causes, including because of Crohn's disease. This glucagon-like peptide-2 analogue promotes structural adaptation such as lengthening villi and increasing crypt depth, as well as functional adaptation by slowing intestinal transit.[34] Several prospective studies demonstrated reduction in parenteral caloric and fluid volume requirements, with some patients experiencing sustained benefit after stopping treatment. The estimated annual cost of the medication is $300,000[35]; pharmacoeconomics analyses are needed to determine the role of this therapeutic.

Surgical therapies for short bowel syndrome range from restoration of intestinal continuity if the colon remains in situ, stricturoplasties, lengthening procedures, segmental reversals, and small bowel transplant. The common tenets used in these operations are increasing or maintaining absorptive area and slowing transit.[26] Intact colon has benefits including increased absorptive capacity for liquid and nutrients, but

also downsides such as increased bile salt deconjugation leading to watery diarrhea.[30] Lengthening procedures are uncommon in the adult population because the mesenteric leaves are fused and very difficult to separate while maintaining blood supply, and this technique requires dilated bowel.[36] Segmental reversal techniques can be used in normal caliber bowel and lead to decreased parenteral nutrition dependence in intestinal failure populations.[37] Stricturoplasty, a well-described and conservative surgical technique commonly used in Crohn's disease, leads to resolution of obstructive symptoms and weight gain secondary to improved oral intake (**Fig. 2**).[38] The length of involved bowel dictates the type of stricturoplasty with Heineke-Mickulicz used for short segment (<10 cm) narrowing, Finney for medium length (10–20 cm) diseased regions, and the side-to-side isoperistaltic stricturoplasty used in long strictures. Short bowel syndrome secondary to Crohn's disease is an indication for intestinal transplantation, although fewer than 50 patients worldwide have undergone transplant for failure due to inflammatory bowel disease, and long-term survival may be worse than maintenance on parenteral nutrition.[39]

Depending on the distribution of inflammation and regions of intestinal resections, patients with inflammatory bowel disease display several well-described malabsorption syndromes. The distal 100 cm of the terminal ileum performs critical functions in water-soluble vitamin (absorption, especially B12), and inflammatory disease or surgical absence of this segment can lead to megaloblastic anemia and neurologic symptoms. Health maintenance in patients with inflammatory bowel disease includes daily multivitamin with iron supplementation, vitamin D, and calcium, as well as vitamin B12 and folate serum level monitoring.[11] Height, weight, and BMI measurements are crucial components of outpatient visits especially in children, adolescents, and young adults because protein loss in chronic diarrhea can lead to growth disturbances.[40] In a recent European case control study, BMI and serum albumin level were the 2 patient characteristics most associated with malnutrition, and recent unintentional weight loss can also indicate a significant ongoing nutritional disturbance.[41]

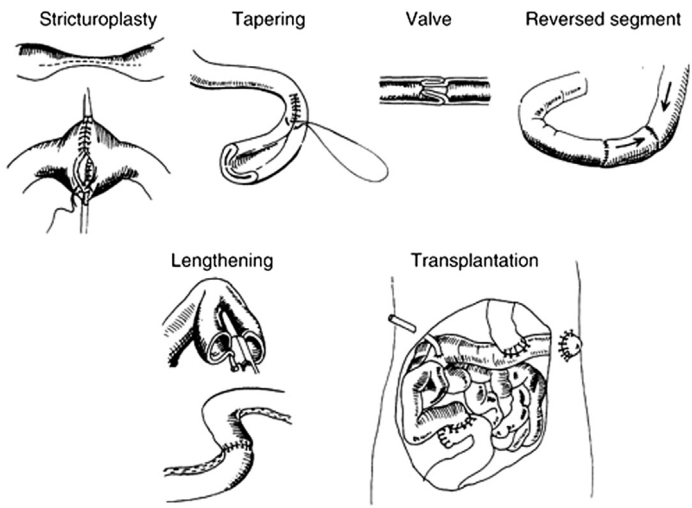

Fig. 2. Surgical procedures for improvement of bowel function in short bowel syndrome. (*From* Thompson JS, Langnas AN, Pinch LW, et al. Surgical approach to short-bowel syndrome. Experience in a population of 160 patients. Ann Surg 1995;222(4):602; [discussion: 605–7]; with permission).

POUCH COMPLICATIONS

For patients with a diagnosis of ulcerative colitis who desire restoration of intestinal continuity after proctocolectomy, the ileal pouch anal anastomosis (IPAA) is performed. This procedure was first described by Sir Alan Parks and Nicholls in 1978[42] and is now commonly offered to individuals with good sphincter function as an alternative to a permanent stoma. Despite a low mortality, there are several unique complications arising from this restorative proctocolectomy.

Pelvic sepsis results from a presumed pouch leak in 3 of 4 cases, and the specific location of the leak is usually the pouch-anal anastomosis (56%).[43] A leak is identified from the tip of the pouch more rarely (7% in Heuschen series), but based on the small case series published by Kirat and colleagues,[44] this complication often mandates an abdominal approach for management with either pouch repair or re-creation for pouch salvage. These leaks are extremely rare and notoriously difficult to diagnose; they require a high index of suspicion in patients presenting with a chronic, indolent course of pelvic sepsis or a fistula.

Anastomotic stricture can be observed after resolution of pelvic sepsis and may require repeated dilations[45] or even pouch advancement to achieve acceptable function.[46] At the first postoperative visit, patients undergo a digital rectal examination to break the filmy adhesions that commonly form over the defunctionalized distal anastomosis and also to identify an early anastomotic stricture. Before reversing a diverting ileostomy, the patient should again be examined for any evidence of a distal narrowing that would render pouch function unacceptable; serial dilations may be initiated at this time. Routine retrograde contrast study of the pouch before ostomy takedown may not increase the diagnosis of occult leaks or routinely alter management.[47]

Pouch vaginal fistulas are a devastating complication observed in 2% to 6% of cases following IPAA.[48] Often these are located at the pouch-anal anastomosis and have high recurrence rates up to 70% following attempted primary repair.[49] Those fistulas presenting within 6 months of surgery are thought to be secondary to pelvic sepsis and seem to be more successfully repaired than later fistulas that are more suggestive of previously undiagnosed Crohn's disease.[50] A transanal or transvaginal approach is often used for fistulae originating at or distal to the anastomosis[49,50] and both yield a fistula closure rate of 50%. It is the authors' opinion that almost all symptomatic pouch-vaginal fistulas require loop ileostomy creation before (or concurrent with) fistula repair in order to optimize healing conditions at the initial attempt.

Nonspecific inflammation of the ileal pouch is known as pouchitis, and the incidence increases over time from surgery, with one recent series reporting at least one episode in 70% of patients at 20-year follow-up.[51] Patients will often describe fever, pelvic pain, increase in defecation, and cramping. Index presentation with these symptoms should prompt endoscopic evaluation of the pouch, with random biopsies to evaluate for other causes, such as undiagnosed Crohn's disease. The cause remains uncertain but is thought to be related to overgrowth of anaerobic bacteria. Because of uncertainty of the true cause, many systemic and intraluminal therapies have been examined (**Box 2**). Currently, first-line treatment is primarily with antibiotics such as rifaximin or ciprofloxacin with or without metronidazole.[52] A *Cochrane Review* of 11 randomized controlled trials suggested budesonide enemas and probiotics were more effective than placebo at inducing remission.[53] Cuffitis refers to inflammation of the 1 to 4 cm of remnant rectal mucosa after the double stapled technique of IPAA. It presents in similar fashion to pouchitis, although only 10% of patients are symptomatic.[54] Treatment of cuffitis includes topical steroids or 5-aminosalicylic preparations with an excellent response rate of greater than 90%.[55] If cuffitis or

Box 2
Treatment options for acute and chronic pouchitis

Systemic

- Antibiotics such as rifaximin, ciprofloxacin, metronidazole
- Probiotics such as VSL3
- Oral 5-aminosalicylic acid (5-ASA) agents
- Absorbant spherical carbon
- Infliximab

Intraluminal/topical

- 5-ASA agent enemas
- Budesonide enemas or by mouth
- Bismuth carbomer foam enemas
- Tacrolimus enemas
- Hydrocortisone suppositories
- Glutamine suppositories
- Butyrate suppositories

Surgical

- Pouch excision with end ileostomy

pouchitis fails to improve with established therapies, the clinician must rule out other causes of bowel habit changes, such as infection with *Clostridium difficile* or cytomegalovirus, Crohn's disease, and other more unusual cause such as ischemic pouchitis or autoimmune disorders.[56] Fecal transplantation may be a successful management strategy in patients with refractory pouchitis or *C difficile* colonization, leading to pouch dysfunction, although evidence to support this practice is currently lacking.[57]

Overall pouch failure rate ranges from 3% to as high as 48% in the literature due to differing definitions and length of follow-up.[51,58] Many patient and technical factors are associated with pouch failure, but pelvic sepsis and Crohn's disease remain the most consistently identified.[56] Salvage surgery for pouch dysfunction after septic complications seems to lead to reasonable long-term function with up to an 86% success rate.[59] In patients who do require a permanent stoma for pouch failure, the current literature supports pouch excision with end ileostomy rather than diverting stoma (and leaving the pouch in situ) when feasible due to improved quality of life.[60]

DEEP VENOUS THROMBOSIS

Individuals with inflammatory bowel disease exhibit increased rates of venous thromboembolic events (VTE) during hospitalizations and especially after intestinal resection.[61] Sites of involvement range from extremity deep venous thrombosis to pulmonary embolism, mesenteric and portal venous thrombosis, and thromboembolic phenomena and can occasionally result in death. Patients can experience VTE despite appropriate mechanical and pharmacologic prophylaxis so the provider's index of suspicion must remain high. Gross and colleagues[62] recently demonstrated that patients with inflammatory bowel disease are at higher risk for postoperative VTEs than patients with cancer. After operative resection, the National Comprehensive

Cancer Network recommends 4 weeks of out-of-hospital pharmacologic thromboprophylaxis for patients with colorectal cancer; individuals with inflammatory bowel disease would likely benefit from similar management.[63]

Portomesenteric vein thrombosis occurs in both patients with ulcerative colitis and patients with Crohn's disease, and its occurrence is likely underestimated. Symptoms of acute thrombosis include nonspecific abdominal pain, fevers, and inflammatory symptoms. Forty percent of patients remain asymptomatic, and the thrombus is found incidentally.[64] Hyperhomocysteinemia and other known prothrombotic disorders should be sought, although a firm diagnosis occurs in the minority. Risk factors for portal thrombosis in this population include active inflammatory bowel disease, tobacco use, underlying malignancy or hepatic disease (eg, nonalcoholic steatohepatitis or hepatitis), and recent abdominal surgery.[64–66] Although the natural history of this thrombus is uncertain, systemic anticoagulation should be initiated if not otherwise contraindicated. Successful recanalization of the portomesenteric venous system is more likely in the acute setting (65% vs 37% for chronic thrombosis).[64]

SUMMARY

Inflammatory bowel disease affects a significant portion of the American population and frequently follows a chronic clinical course with episodic flares and periods of remission. Many patients with Crohn's disease and ulcerative colitis will ultimately come to surgical resection, and these individuals require an organized operative approach tailored to their anatomy and distribution of disease. Presented are several specific complications with unique implications in the inflammatory bowel disease population, and evidence-based techniques for management are discussed. Caring for this patient population often leads to the development of long-term clinical relationships, and a systematic approach toward treatment of ongoing disease-related complications will yield the best possible outcomes.

REFERENCES

1. Loftus CG, Loftus EV Jr, Harmsen WS, et al. Update on the incidence and prevalence of Crohn's disease and ulcerative colitis in Olmsted County, Minnesota, 1940–2000. Inflamm Bowel Dis 2007;13(3):254–61.
2. Farkas K, Lakatos PL, Nagy F, et al. Predictors of relapse in patients with ulcerative colitis in remission after one-year of infliximab therapy. Scand J Gastroenterol 2013;48(12):1394–8.
3. Affronti A, Orlando A, Cottone M. An update on medical management on Crohn's disease. Expert Opin Pharmacother 2015;16(1):63–78.
4. Lapidus A, Bernell O, Hellers G, et al. Clinical course of colorectal Crohn's disease: a 35-year follow-up study of 507 patients. Gastroenterology 1998;114(6):1151–60.
5. Sica GS, Biancone L. Surgery for inflammatory bowel disease in the era of laparoscopy. World J Gastroenterol 2013;19(16):2445–8.
6. Larson DW, Pemberton JH. Current concepts and controversies in surgery for IBD. Gastroenterology 2004;126(6):1611–9.
7. Bernell O, Lapidus A, Hellers G. Risk factors for surgery and postoperative recurrence in Crohn's disease. Ann Surg 2000;231(1):38–45.
8. Michelassi F, Stella M, Balestracci T, et al. Incidence, diagnosis, and treatment of enteric and colorectal fistulae in patients with Crohn's disease. Ann Surg 1993;218(5):660–6.

9. Schein M. What's new in postoperative enterocutaneous fistulas? World J Surg 2008;32(3):336–8.
10. Chapman R, Foran R, Dunphy JE. Management of intestinal fistulas. Am J Surg 1964;108:157–64.
11. Song HK, Buzby GP. Nutritional support for Crohn's disease. Surg Clin North Am 2001;81(1):103–15, viii.
12. Lloyd DA, Gabe SM, Windsor AC. Nutrition and management of enterocutaneous fistula. Br J Surg 2006;93(9):1045–55.
13. McIntyre PB, Ritchie JK, Hawley PR, et al. Management of enterocutaneous fistulas: a review of 132 cases. Br J Surg 1984;71(4):293–6.
14. Reenaers C, Belaiche J, Louis E. Impact of medical therapies on inflammatory bowel disease complication rate. World J Gastroenterol 2012;18(29):3823–7.
15. Terzi C, Egeli T, Canda AE, et al. Management of enteroatmospheric fistulae. Int Wound J 2014;11(Suppl 1):17–21.
16. Hoedema RE, Suryadevara S. Enterostomal therapy and wound care of the enterocutaneous fistula patient. Clin Colon Rectal Surg 2010;23(3):161–8.
17. de Leon JM. Novel techniques using negative pressure wound therapy for the management of wounds with enterocutaneous fistulas in a long-term acute care facility. J Wound Ostomy Continence Nurs 2013;40(5):481–8.
18. Draus JM Jr, Huss SA, Harty NJ, et al. Enterocutaneous fistula: are treatments improving? Surgery 2006;140(4):570–6 [discussion: 576–8].
19. Peter Irving DR, Shanahan F. Clinical dilemmas in inflammatory bowel disease. Malden (MA): Mass: Blackwell Pub. LTD; 2006.
20. Shah SC, Day LW, Somsouk M, et al. Meta-analysis: antibiotic therapy for small intestinal bacterial overgrowth. Aliment Pharmacol Ther 2013;38(8):925–34.
21. Grace E, Shaw C, Whelan K, et al. Review article: small intestinal bacterial overgrowth–prevalence, clinical features, current and developing diagnostic tests, and treatment. Aliment Pharmacol Ther 2013;38(7):674–88.
22. Miehsler W, Reinisch W, Kazemi-Shirazi L, et al. Infliximab: lack of efficacy on perforating complications in Crohn's disease. Inflamm Bowel Dis 2004;10(1):36–40.
23. Mahadevan U, Marion JF, Present DH. Fistula response to methotrexate in Crohn's disease: a case series. Aliment Pharmacol Ther 2003;18(10):1003–8.
24. Joyce MR, Dietz DW. Management of complex gastrointestinal fistula. Curr Probl Surg 2009;46(5):384–430.
25. Schecter WP, Hirshberg A, Chang DS, et al. Enteric fistulas: principles of management. J Am Coll Surg 2009;209(4):484–91.
26. Keller J, Panter H, Layer P. Management of the short bowel syndrome after extensive small bowel resection. Best Pract Res Clin Gastroenterol 2004;18(5):977–92.
27. Watanabe K, Sasaki I, Fukushima K, et al. Long-term incidence and characteristics of intestinal failure in Crohn's disease: a multicenter study. J Gastroenterol 2014;49(2):231–8.
28. Michelassi F, Sultan S. Surgical treatment of complex small bowel Crohn disease. Ann Surg 2014;260(2):230–5.
29. Lentze MJ. Intestinal adaptation in short-bowel syndrome. Eur J Pediatr 1989;148(4):294–9.
30. Sundaram A, Koutkia P, Apovian CM. Nutritional management of short bowel syndrome in adults. J Clin Gastroenterol 2002;34(3):207–20.
31. Harris AG. Somatostatin and somatostatin analogues: pharmacokinetics and pharmacodynamic effects. Gut 1994;35(3 Suppl):S1–4.

32. Byrne TA, Wilmore DW, Iyer K, et al. Growth hormone, glutamine, and an optimal diet reduces parenteral nutrition in patients with short bowel syndrome: a prospective, randomized, placebo-controlled, double-blind clinical trial. Ann Surg 2005;242(5):655–61.
33. Wales PW, Nasr A, de Silva N, et al. Human growth hormone and glutamine for patients with short bowel syndrome. Cochrane Database Syst Rev 2010;(6):CD006321.
34. Wilhelm SM, Lipari M, Kulik JK, et al. Teduglutide for the treatment of short bowel syndrome. Ann Pharmacother 2014;48(9):1209–13.
35. Herper M. Inside the pricing of a $300,000-a-year drug. New York: Pharma & Healthcare; 2013. Available at: http://www.forbes.com/sites/matthewherper/2013/01/03/inside-the-pricing-of-a-300000-a-year-drug/. Accessed March 1, 2013.
36. Carlson GL. Surgical management of intestinal failure. Proc Nutr Soc 2003;62(3):711–8.
37. Beyer-Berjot L, Joly F, Maggiori L, et al. Segmental reversal of the small bowel can end permanent parenteral nutrition dependency: an experience of 38 adults with short bowel syndrome. Ann Surg 2012;256(5):739–44 [discussion: 744–5].
38. Yamamoto T, Fazio VW, Tekkis PP. Safety and efficacy of strictureplasty for Crohn's disease: a systematic review and meta-analysis. Dis Colon Rectum 2007;50(11):1968–86.
39. Harrison E, Allan P, Ramu A, et al. Management of intestinal failure in inflammatory bowel disease: small intestinal transplantation or home parenteral nutrition? World J Gastroenterol 2014;20(12):3153–63.
40. Rufo PA, Denson LA, Sylvester FA, et al. Health supervision in the management of children and adolescents with IBD: NASPGHAN recommendations. J Pediatr Gastroenterol Nutr 2012;55(1):93–108.
41. Mijac DD, Jankovic GL, Jorga J, et al. Nutritional status in patients with active inflammatory bowel disease: prevalence of malnutrition and methods for routine nutritional assessment. Eur J Intern Med 2010;21(4):315–9.
42. Parks AG, Nicholls RJ. Proctocolectomy without ileostomy for ulcerative colitis. Br Med J 1978;2(6130):85–8.
43. Heuschen UA, Allemeyer EH, Hinz U, et al. Outcome after septic complications in J pouch procedures. Br J Surg 2002;89(2):194–200.
44. Kirat HT, Kiran RP, Oncel M, et al. Management of leak from the tip of the "J" in ileal pouch-anal anastomosis. Dis Colon Rectum 2011;54(4):454–9.
45. Lewis WG, Kuzu A, Sagar PM, et al. Stricture at the pouch-anal anastomosis after restorative proctocolectomy. Dis Colon Rectum 1994;37(2):120–5.
46. Fazio VW, Tjandra JJ. Pouch advancement and neoileoanal anastomosis for anastomotic stricture and anovaginal fistula complicating restorative proctocolectomy. Br J Surg 1992;79(7):694–6.
47. Kalady MF, Mantyh CR, Petrofski J, et al. Routine contrast imaging of low pelvic anastomosis prior to closure of defunctioning ileostomy: is it necessary? J Gastrointest Surg 2008;12(7):1227–31.
48. Johnson PM, O'Connor BI, Cohen Z, et al. Pouch-vaginal fistula after ileal pouch-anal anastomosis: treatment and outcomes. Dis Colon Rectum 2005;48(6):1249–53.
49. Heriot AG, Tekkis PP, Smith JJ, et al. Management and outcome of pouch-vaginal fistulas following restorative proctocolectomy. Dis Colon Rectum 2005;48(3):451–8.
50. Shah NS, Remzi F, Massmann A, et al. Management and treatment outcome of pouch-vaginal fistulas following restorative proctocolectomy. Dis Colon Rectum 2003;46(7):911–7.

51. Hahnloser D, Pemberton JH, Wolff BG, et al. Results at up to 20 years after ileal pouch-anal anastomosis for chronic ulcerative colitis. Br J Surg 2007;94(3):333–40.
52. Shen B, Achkar JP, Lashner BA, et al. A randomized clinical trial of ciprofloxacin and metronidazole to treat acute pouchitis. Inflamm Bowel Dis 2001;7(4):301–5.
53. Holubar SD, Cima RR, Sandborn WJ, et al. Treatment and prevention of pouchitis after ileal pouch-anal anastomosis for chronic ulcerative colitis. Cochrane Database Syst Rev 2010;(6):CD001176.
54. Thompson-Fawcett MW, Mortensen NJ, Warren BF. "Cuffitis" and inflammatory changes in the columnar cuff, anal transitional zone, and ileal reservoir after stapled pouch-anal anastomosis. Dis Colon Rectum 1999;42(3):348–55.
55. Shen B, Lashner BA, Bennett AE, et al. Treatment of rectal cuff inflammation (cuffitis) in patients with ulcerative colitis following restorative proctocolectomy and ileal pouch-anal anastomosis. Am J Gastroenterol 2004;99(8):1527–31.
56. Francone TD, Champagne B. Considerations and complications in patients undergoing ileal pouch anal anastomosis. Surg Clin North Am 2013;93(1):107–43.
57. Allegretti JR, Hamilton MJ. Restoring the gut microbiome for the treatment of inflammatory bowel diseases. World J Gastroenterol 2014;20(13):3468–74.
58. Fazio VW, Ziv Y, Church JM, et al. Ileal pouch-anal anastomoses complications and function in 1005 patients. Ann Surg 1995;222(2):120–7.
59. Fazio VW, Wu JS, Lavery IC. Repeat ileal pouch-anal anastomosis to salvage septic complications of pelvic pouches: clinical outcome and quality of life assessment. Ann Surg 1998;228(4):588–97.
60. Kiran RP, Kirat HT, Rottoli M, et al. Permanent ostomy after ileoanal pouch failure: pouch in situ or pouch excision? Dis Colon Rectum 2012;55(1):4–9.
61. Dwyer JP, Javed A, Hair CS, et al. Venous thromboembolism and underutilisation of anticoagulant thromboprophylaxis in hospitalised patients with inflammatory bowel disease. Intern Med J 2014;44(8):779–84.
62. Gross ME, Vogler SA, Mone MC, et al. The importance of extended postoperative venous thromboembolism prophylaxis in IBD: a National Surgical Quality Improvement Program analysis. Dis Colon Rectum 2014;57(4):482–9.
63. Vedovati MC, Becattini C, Rondelli F, et al. A randomized study on 1-week versus 4-week prophylaxis for venous thromboembolism after laparoscopic surgery for colorectal cancer. Ann Surg 2014;259(4):665–9.
64. Landman C, Nahon S, Cosnes J, et al. Portomesenteric vein thrombosis in patients with inflammatory bowel disease. Inflamm Bowel Dis 2013;19(3):582–9.
65. Leung GG, Sivasankaran MV, Choi JJ, et al. Risk factors of portal vein thrombosis in Crohn's disease patients. J Gastrointest Surg 2012;16(6):1199–203.
66. Fichera A, Cicchiello LA, Mendelson DS, et al. Superior mesenteric vein thrombosis after colectomy for inflammatory bowel disease: a not uncommon cause of postoperative acute abdominal pain. Dis Colon Rectum 2003;46(5):643–8.