Colorectal Neoplasia and Inflammatory Bowel Disease

Jamie Cannon, MD

KEYWORDS

• Colorectal cancer • Inflammatory bowel disease • Neoplasia • Crohn's disease
• Ulcerative colitis

KEY POINTS

- Ulcerative colitis and Crohn's colitis are associated with a 2- to 5-fold increased risk of colorectal cancer.
- Patients with ulcerative colitis and Crohn's colitis should undergo surveillance colonoscopy to detect dysplasia, and if detected, should generally undergo prophylactic surgical resection.
- Patients that have undergone restorative proctocolectomy should have their ileal pouch and the anal transition zone surveyed via endoscopy.
- Patients with Crohn's disease are at increased risk of developing small bowel and anal cancers.

INTRODUCTION

Crohn's disease and ulcerative colitis are significant risk factors for the development of gastrointestinal neoplasias.[1] The association between ulcerative colitis and colorectal cancer has long been recognized, and surveillance protocols to detect neoplasia in the setting of ulcerative colitis are well established. Engaging in surveillance has been shown to decrease the risk of death from colorectal cancer among ulcerative colitis patients. Although the cancer risk related to Crohn's disease is not as well defined, all inflamed segments of bowel are at increased risk for the development of neoplasia. Crohn's colitis is associated with a risk of colorectal cancer similar to that of ulcerative colitis, and the risk of small bowel adenocarcinoma in patients with Crohn's enteritis is greatly elevated compared with that of the general population.

Department of Surgery, University of Alabama at Birmingham, 1720 2nd Ave S, Birmingham, AL 35294-0016, USA
E-mail address: jacannon@uab.edu

Surg Clin N Am 95 (2015) 1261–1269
http://dx.doi.org/10.1016/j.suc.2015.08.001 **surgical.theclinics.com**
0039-6109/15/$ – see front matter © 2015 Elsevier Inc. All rights reserved.

MECHANISM OF ACTION OF INCREASED RISK

Sporadic colorectal cancers develop via the classic adenoma-dysplasia-carcinoma sequence. The development of colorectal cancer in the setting of colitis also progresses from dysplasia to carcinoma, although the process appears to be different and the progression is accelerated. It is thought that the inflammatory process leads to oxidative stress-induced DNA damage of the affected mucosa. Loss of p53 function is seen early in this sequence, unlike in sporadic cancers wherein this is usually a late finding.[2,3] Constant attempts at regeneration provide more opportunities for transcription errors and the subsequent development of neoplasia via activation of procarcinogenic genes and inhibition of tumor suppressor genes. Alteration in the colonic flora has also been proposed as a mechanism to increase the cancer risk. Altered flora may increase the degree of inflammation, or possibly produce procarcinogenic substances. *Bacteroides fragilis* and *Enterococcus feacalis* have been implicated as procarcinogens.

The use of immunosuppression to treat inflammatory bowel disease plays a role as well. Optimal control of inflammation is important, because the degree of inflammation correlates with the cancer risk.[4] However, immunosuppression may also allow neoplasia to advance at a faster rate. 5-Aminosalicylic acid drugs, on the other hand, have been shown to have a protective effect.[5] Cancers that arise in the setting of inflammatory bowel disease are more likely to be poorly differentiated,[2] although whether this portends a poorer prognosis is not clear. Studies have been contradictory, with some showing similar overall survival to sporadic cancers,[6,7] and others showing a poorer stage-for-stage survival.[8,9] As the increased risk is a field effect to all areas of inflamed bowel, inflammatory bowel disease–related cancers are also associated with a higher risk of both synchronous (12.4%) and metachronous (14.3%) cancers.[8]

ULCERATIVE COLITIS AND COLORECTAL CANCER

Ulcerative colitis is associated with a 2- to 5-fold risk for the development of colorectal cancer,[10–12] although the reported increased risk varies widely from study to study. The incidence has been estimated as approximately 1% per year, or 30% at 35 years.[13] Alternatively, Choi and colleagues[14] found the incidence of colorectal cancer to be only 10% at 40 years. Those who also have primary sclerosing cholangitis are at an even greater risk for colorectal cancer, and that increased risk is present at the onset of disease.[15]

SURVEILLANCE

Prophylactic total proctocolectomy is the recommended surgical treatment option for those at greatest risk of colorectal cancer. As the risk of developing neoplasia increases with the duration of disease, prophylactic surgery used to be recommended after 10 years of active disease to reduce cancer risk. The current trend is toward a more individualized approach, with surveillance recommended for most patients. Multiple societies have published recommended surveillance guidelines, although they are all quite similar. National Comprehensive Cancer Network (NCCN) guidelines recommend beginning surveillance after 8 to 10 years of pancolitis[16] with colonoscopies performed every 1 to 2 years, because the incidence of colorectal cancer increases after 8 years of disease.[1,17] Biopsies should be taken in 4 quadrants every 10 cm, resulting in more than 30 biopsy specimens for pathology. The chance of a false-negative surveillance colonoscopy decreases with the more biopsies that are taken.

It has been estimated that it is necessary to take 33 biopsies to achieve a 90% sensitivity for the detection of dysplasia.[3] Many authors have recommended using chromoendoscopy rather than standard white light colonoscopy to perform targeted rather than random biopsies. Chromoendoscopy allows for the identification of abnormal-appearing mucosa and has been demonstrated to detect neoplasia at double the rate of standard white-light colonoscopy.[14,18] However, a recent review by Mooiweer and colleagues[19] did not find that chromoendoscopy improved the detection of dysplasia.

Surveillance colonoscopy is less effective in those who have continuing active disease and abnormal-appearing colonic mucosa. If possible, surveillance colonoscopies should be performed when disease is in remission. The presence of active inflammation interferes with the pathologist's ability to accurately diagnose dysplasia on biopsy specimens. In addition, cancers in the presence of abnormal colonic mucosa can be difficult to detect. A reactive pseudopolyposis of the colon can very easily hide a colon cancer, as can tissue bridges and active ulceration. If medical therapy does not render the colon easier to survey, consideration should be given to prophylactic surgery. Even in the absence of active inflammation, advanced cancers develop in patients undergoing a surveillance program. Cancers that develop in the setting of ulcerative colitis are more likely to be flat cancers without significant mass effect than cancers that arise spontaneously. They also have more extensive submucosal spread and advance more quickly.

MANAGEMENT OF DYSPLASIA

The goal of a surveillance program is to identify those with dysplasia that are at greatest risk for having or developing colorectal cancer. The presence of high-grade dysplasia (HGD) in normal appearing mucosa is widely accepted as an indication for prophylactic surgery. When HGD is detected on random biopsies, there is a high incidence of occult colorectal cancer in the resected specimen. Most studies estimate the risk of occult cancer to be from 36% to 71%.[14,20–24] Choi and colleagues[14] reviewed 40 years of a surveillance program from the United Kingdom and found that among patients who had HGD on their surveillance colonoscopies, 55% were found to have occult cancer in their colon resection specimens. The high rate of occult cancer clearly demonstrates that the presence of HGD warrants proctocolectomy.

The management of low-grade dysplasia (LGD) is a continued area of controversy. The same study from the United Kingdom found a 28% incidence of occult cancer in the surgical resection specimens of patients who were preoperatively found to have LGD on their surveillance colonoscopy. Among patients that did not have a colectomy for LGD, 32% progressed to more advanced neoplasia (HGD or adenocarcinoma). These findings suggest that even LGD should be managed with prophylactic surgery. However, a recent study by Murphy and colleagues[25] found drastically different results. This study showed only a 2% incidence of occult colorectal cancer when biopsies showed LGD, and 3% when they showed HGD. **Table 1** summarizes the incidence of occult colorectal cancer from numerous studies. These contradictory results present a challenge when counseling patients concerning prophylactic surgery. NCCN guidelines recommend surgical consultation for resection when LGD is detected.[16] The approach should be individualized, and consideration should be given to the patient's disease state, likelihood of follow-up for continued surveillance, and acceptance of prophylactic surgery versus cancer risk. **Fig. 1** provides a proposed algorithm for the management of endoscopically detected neoplasia.

Table 1
Incidence of occult colorectal cancer after dysplasia is detected on surveillance colonoscopy

Study	LGD on Biopsy	HGD on Biopsy
Choi et al,[14] 2015	9/32 (28%)	16/29 (55%)
Murphy et al,[25] 2014	3/141 (2%)	1/33 (3%)
Bernstein et al,[20] 1994	3/16 (19%)	10/24(42%)
Nugent et al,[21] 1991	—	7/18 (39%)
Kewenter et al,[22] 1982	—	5/14 (36%)
Fuson et al,[23] 1980	—	5/7 (71%)
Lennard-Jones et al,[24] 1977	—	4/7 (57%)

Data from Refs.[14,20–25]

DYSPLASIA-ASSOCIATED LESION OR MASS

A patient with ulcerative colitis can develop a sporadic adenoma with HGD, as can any other patient. The challenge to the physician is determining if the HGD is related to a global effect caused by the inflammatory state, in which case proctocolectomy would be recommended. If the lesion is truly sporadic and not related to the patient's inflammatory bowel disease, resection of the lesion alone with close surveillance should be sufficient. Therefore, whenever an actual mass or polyp is identified and removed from a patient with inflammatory bowel disease, biopsies of normal-appearing mucosa around the lesion should be obtained. If the lesion is able to be completely resected, and surrounding mucosal biopsies are normal without evidence of dysplasia, the lesion may be considered more likely to be sporadic and managed in a fashion similar to that of a healthy individual. However, if there is any dysplasia surrounding the lesion, this would be an indication for proctocolectomy. A dysplasia-associated lesion or mass that cannot be completely resected endoscopically requires surgical intervention and is associated with a 43% to 58% cancer risk.[20,26]

NEOPLASIA FOLLOWING PROCTOCOLECTOMY WITH ILEAL POUCH-ANAL ANASTOMOSIS

Most patients undergoing surgical treatment of ulcerative colitis undergo total proctocolectomy with ileal pouch-anal anastomosis reconstruction. When ileal pouch reconstruction was first introduced, the resection was described as being performed along with a mucosectomy of the anal canal. This resection was thought to eliminate all of the colorectal mucosa, and thus, the concern for development of colorectal cancer. More recent studies, however, have shown that there is still a risk of neoplasia even after mucosectomy. In addition, mucosectomy was also associated with high rates of anal stenosis, and this technique has for the most part been replaced with a double-stapled technique. The double-stapled technique is generally preferred because it provides better bowel function, has fewer complications, and is easier to perform.[27,28] With this operation, the proximal bowel is divided at the level of the pelvic floor and the anastomosis is constructed at this level. The bowel mucosa between the dentate line and the pelvic floor represents the transition zone and is left in place. This 1- to 2-cm remnant of colorectal mucosa is still at risk for the development of colorectal cancer. The incidence of dysplasia in the transition zone has been estimated to be 3% to 4%.[29] Although progression to invasive cancer in this region is very rare, it has been reported in multiple case series,[30–32] and this area should therefore continue to be surveyed. Although some have argued that the low incidence of cancer

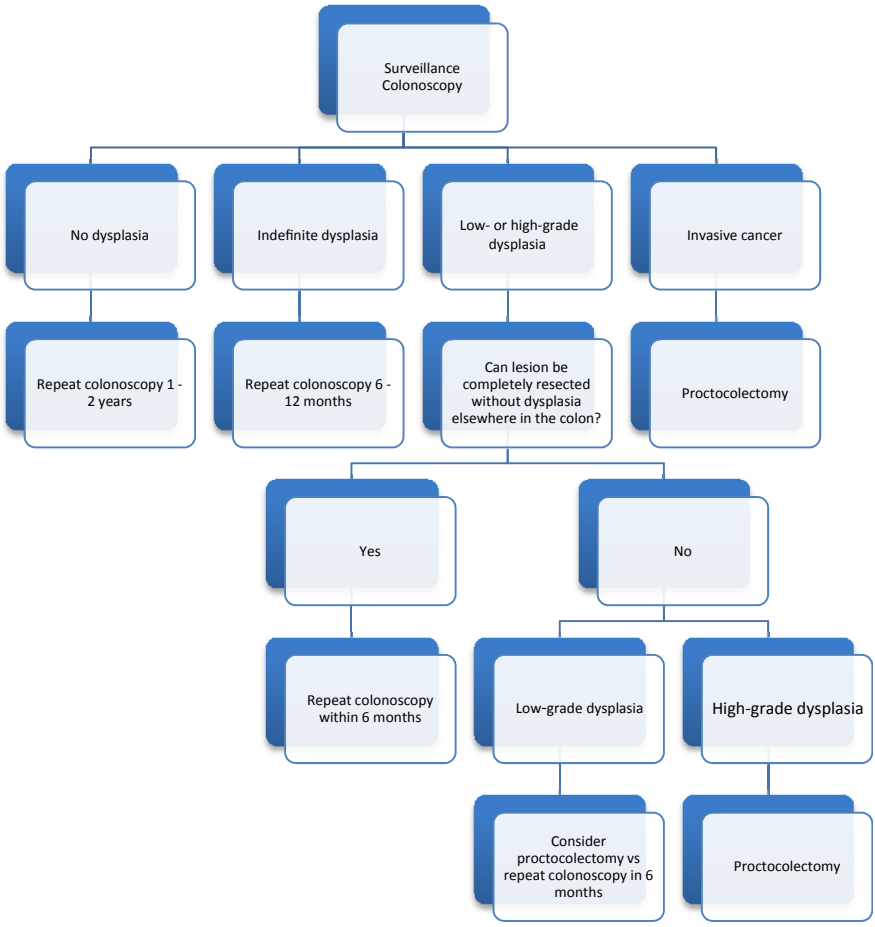

Fig. 1. Algorithm for the management of endoscopically detected neoplasia.

does not warrant surveillance, annual endoscopic examination of the transition zone is generally recommended[33] and widely practiced. Some authors have also promoted random biopsies of the transition zone[29] to identify occult dysplasia.

In addition to neoplasia of the transition zone, cancer can develop within the ileal pouch. Although this is rare, it occurs at a much greater rate than one would expect for a sporadic small bowel cancer. The incidence of pouch neoplasia has been reported to be similar to that in the transition zone, from 0% to 18.5%. A meta-analysis by Scarpa and colleagues[33] estimated the risk to be 1.13%. The most significant risk factor for pouch dysplasia was a diagnosis of dysplasia or cancer at the time of proctocolectomy. Kariv and colleagues[34] grouped pouch and anal transition zone neoplasia together and demonstrated that the risk increases over time, with a 5.1% incidence of neoplasia at 25 years. Options for management of LGD include continued surveillance versus resection. HGD should be treated with resection. The location of the dysplasia determines the surgical management, which is either mucosectomy with pouch advancement or excision and re-creation of the ileal pouch. If re-creation of a pouch-anal anastomosis is not technically feasible, an end ileostomy may be necessary.

CROHN'S DISEASE

Like ulcerative colitis, Crohn's colitis is associated with increased rates of colorectal cancer. In the presence of colitis, the risk is similar to that of ulcerative colitis, with an estimated 8% incidence after 20 years of disease.[35] Therefore, patients with Crohn's colitis should undergo a surveillance regimen of the colon and rectum identical to that of patients with ulcerative colitis. The findings of neoplasia should be managed in a similar fashion, although segmental colectomy can be considered. The at-risk bowel should in theory be the segments of colon that have been affected by inflammation, and not necessarily the entire colon. However, if a segmental resection is performed, close surveillance should continue, because there is a high rate of metachronous cancers.

Because Crohn's disease also affects the small intestine, Crohn's is associated with increased rates of small bowel adenocarcinoma. Fortunately, this more aggressive cancer is not common in the general population, but patients with Crohn's disease have a 20- to 30-fold risk of development of small bowel cancer.[36,37] No specific surveillance is recommended other than the standard management of active Crohn's disease. It seems reasonable, however, to examine as much of the terminal ileum as possible during surveillance colonoscopies. In a patient undergoing surgery for small bowel Crohn's disease, the possibility of neoplasm should be kept in mind at the time of the operation. Although mesenteric dissection can be difficult in the setting of active Crohn's disease, if there is concern for malignancy, an attempt should be made to include the mesentery of the affected and surrounding small bowel.

CANCER IN A FISTULA

The presence of fistulizing anorectal disease is a risk factor for development of rectal/anal adenocarcinoma and squamous cell cancer. Although this is not common, it is a hard condition to treat and is associated with very high mortality. Treatment of the cancer is also complicated by the fact that it occurs in the presence of active Crohn's disease, which may limit treatment options. Fistulizing tracts throughout the perirectal tissues result in the loss of normal anatomic barriers, which allows for easier and earlier spread of neoplasia, making local control a challenge. This disease process is associated with high rates of local recurrence. When possible, these patients should be treated with neoadjuvant chemoradiation in order to maximize local control. The extent of perianal sepsis, however, may preclude the ability to provide neoadjuvant treatment and mandate surgery as the initial management. Surgical therapy is an abdominal perineal resection with wide margins to include all fistula tracts. Reconstruction with myocutaneous rectus abdominus flaps is often necessary given the extent of resection required. Despite aggressive therapy, these cancers are associated with very poor 5-year survival. Devon and colleagues[38–42] reported 14 patients with this diagnosis. With a mean follow-up of 42 months, only 5 patients were without evidence of disease. This study also found that none of the patients' malignancies were detected on preoperative imaging. Therefore, when operating on perianal Crohn's disease, the surgeon must maintain a high index of suspicion and be liberal with biopsies of concerning areas.

SUMMARY

Inflammatory bowel disease is associated with increased rates of gastrointestinal neoplasia. Ulcerative colitis and Crohn's colitis increase the risk of colorectal cancer, and patients with these conditions should be monitored via an intensive surveillance

program. This intensive surveillance program should include colonoscopies every 1 to 2 years with multiple biopsies of the colon taken. The presence of dysplasia should warrant referral for consideration of prophylactic proctocolectomy. Crohn's disease is also associated with an increased risk of small bowel and anal cancers.

REFERENCES

1. Eaden JA, Abrams KR, Mayberry JF. The risk of colorectal cancer in ulcerative colitis: a meta-analysis. Gut 2001;48:526–35.
2. Harpaz N, Peck AL, Yin J, et al. p53 protein expression in ulcerative colitis-associated colorectal dysplasia and carcinoma. Hum Pathol 1994;25:1069–74.
3. Cohen RD, Hanauer SB. Surveillance colonoscopy in ulcerative colitis: is the message loud and clear. Am J Gastroenterol 1995;90:2090–2.
4. Rubin DT, Huo D, Kinnucan JA, et al. Inflammation is an independent risk factor for colonic neoplasia in patients with ulcerative colitis: a case-control study. Clin Gastroenterol Hepatol 2013;11(12):1601–8.e1–4.
5. Lyakhovich A, Gasche C. Systematic review: molecular chemoprevention of colorectal malignancy by mesalazine. Aliment Pharmacol Ther 2010;31:202–9.
6. Delaunoit T, Limburg PJ, Goldberg RM, et al. Colorectal cancer prognosis among patients with inflammatory bowel disease. Clin Gastroenterol Hepatol 2006;4:335–42.
7. Kiran R, Khoury W, Church J, et al. Colorectal cancer complicating inflammatory bowel disease. Ann Surg 2010;252:330–5.
8. Gearhart SL, Nathan H, Pawlik TM, et al. Outcomes from IBD-associated and non-IBD associated colorectal cancer: a surveillance epidemiology and end results medicare study. Dis Colon Rectum 2012;55(3):270–7.
9. Jensen A, Larsen M, Gislum M, et al. Survival after colorectal cancer in patients with ulcerative colitis: a nationwide population-based Danish study. Am J Gastroenterol 2006;101:1283–7.
10. Herrinton LJ, Liu L, Levin TR, et al. Incidence and in persons with inflammatory bowel disease from 1998 to 2010. Gastroenterology 2012;143:382–9.
11. Efthymiou M, Taylor AC, Kamm MA. Cancer surveillance strategies in ulcerative colitis: the need for modernization. Inflamm Bowel Dis 2011;17:1800–13.
12. Bernstein CN, Blanchard JF, Kliewer E, et al. Cancer risk in patients with inflammatory bowel disease: a population-based study. Cancer 2001;91:854–62.
13. Ekbom A, Helmick C, Zack M, et al. Ulcerative colitis and colorectal cancer: a population based study. N Engl J Med 1990;323:1228–33.
14. Choi CH, Rutter MD, Askari A, et al. Forty-year analysis of colonoscopic surveillance program for neoplasia in ulcerative colitis: an updated overview. Am J Gastroenterol 2015;110(7):1022–34.
15. Jess T, Simonsen J, Jorgensen KT, et al. Decreasing risk of colorectal cancer in patients with inflammatory bowel disease over 30 years. Gastroenterology 2012;143(2):375.
16. NCCN Guidelines Version 1. 2014 Colorectal Cancer Screening.
17. Lutgens MW, van Oijen MG, van der Heijden GJ, et al. Declining risk of colorectal cancer in inflammatory bowel disease: an updated meta-analysis of population-based cohort studies. Inflamm Bowel Dis 2013;19:789–99.
18. Annese V, Daperno M, Rutter MD, et al. European evidence based consensus for endoscopy in inflammatory bowel disease. J Crohn's Colitis 2013;7:982–1018.
19. Mooiweer E, van der Meulen-de Jong AE, Ponsioen CY, et al. Chromoendoscopy for surveillance in inflammatory bowel disease does not increase neoplasia

detection compared with conventional colonoscopy with random biopsies: results from a large retrospective study. Am J Gastroenterol 2015;110(7):1014–21.
20. Bernstein C, Shanahan F, Weinstein W. Are we telling patients the truth about surveillance colonoscopy in ulcerative colitis? Lancet 1994;343:71–5.
21. Nugent FW, Haggitt RC, Gilpin PA. Cancer surveillance in ulcerative colitis. Gastroenterology 1991;100(5 pt 1):1241–8.
22. Kewenter J, Hultén L, Ahrén C. The occurrence of severe epithelial dysplasia and its bearing on treatment of longstanding ulcerative colitis. Ann Surg 1982;195:209–13.
23. Fuson JA, Farmer RG, Hawk A, et al. Endoscopic surveillance for cancer in chronic ulcerative colitis. Am J Gastroenterol 1980;73:120–6.
24. Lennard-Jones JE, Morson BC, Ritchie JK, et al. Cancer in colitis: assessment of the individual risk by clinical and histological criteria. Gastroenterology 1977;73:1280–9.
25. Murphy J, Kalkbrenner KA, Pemberton JH, et al. Dysplasia in ulcerative colitis as a predictor of unsuspected synchronous colorectal cancer. Dis Colon Rectum 2014;57(8):993–8.
26. Blackstone MO, Riddell RH, Rogers BH, et al. Dysplasia-associated lesion or mass (DALM) detected by colonoscopy in long-standing ulcerative colitis: an indication for colectomy. Gastroenterology 1981;80:366–74.
27. Lovegrove RE, Constantinides VA, Heriot AG, et al. A comparison of hand-sewn versus stapled ileal pouch anal anastomosis (IPAA) following proctocolectomy: a meta-analysis of 4183 patients. Ann Surg 2006;244:18–26.
28. Lavery IC, Tuckson WB, Easley KA. Internal anal sphincter function after total abdominal colectomy and stapled ileal pouch-anal anastomosis without mucosal proctectomy. Dis Colon Rectum 1989;32:950–3.
29. Silva-Velazco J, Stocchi L, Wu XR, et al. Twenty-year-old stapled pouches for ulcerative colitis without evidence of rectal cancer: implications for surveillance strategy? Dis Colon Rectum 2014;57:1275–81.
30. Um JW, M'Koma AE. Pouch-related dysplasia and adenocarcinoma following restorative proctocolectomy for ulcerative colitis. Tech Coloproctol 2011;15:7–16.
31. Sequens R. Cancer in the anal canal (transitional zone) after restorative proctocolectomy with stapled ileal pouch–anal anastomosis. Int J Colorectal Dis 1997;12:254–5.
32. Rotholtz NA, Pikarsky AJ, Singh JJ, et al. Adenocarcinoma arising from along the rectal stump after double-stapled ileorectal J-pouch in a patient with ulcerative colitis: the need to perform a distal anastomosis. Report of a case. Dis Colon Rectum 2001;44:1214–7.
33. Scarpa M, van Koperen PJ, Ubbink DT, et al. Systematic review of dysplasia after restorative proctocolectomy for ulcerative colitis. Br J Surg 2007;94:534–45.
34. Kariv R, Remzi FH, Lian L, et al. Preoperative colorectal neoplasia increases risk for pouch neoplasia in patients with restorative proctocolectomy. Gastroenterology 2010;139:806–12.
35. Gillen CD, Andrews HA, Prior P, et al. Crohn's disease and colorectal cancer. Gut 1994;35:651–5.
36. Jess T, Gamborg M, Matzen P, et al. Increased risk of intestinal cancer in Crohn's disease: a meta-analysis of population-based cohort studies. Am J Gastroenterol 2005;100:2724–9.
37. von Roon AC, Reese G, Teare J, et al. The risk of cancer in patients with Crohn's disease. Dis Colon Rectum 2007;50(6):839–55.
38. Devon KM, Brown CJ, Burnstein M, et al. Cancer of the anus complicating perianal Crohn's disease. Dis Colon Rectum 2009;52(2):211–6.

39. Wu XR, Remzi FH, Liu XL, et al. Disease course and management strategy of pouch neoplasia in patients with underlying inflammatory bowel diseases. Inflamm Bowel Dis 2014;20(11):2073–82.
40. Rosenstock E, Farmer RG, Petras R, et al. Surveillance for colonic carcinoma in ulcerative colitis. Gastroenterology 1985;89:1342–6.
41. von Herbay A, Herfarth C, Otto HF. Cancer and dysplasia in ulcerative colitis: a histologic study of 301 surgical specimen. Z Gastroenterol 1994;32:382–8.
42. Beaugerie L, Itzkowitz SH. Cancers complicating inflammatory bowel disease. N Engl J Med 2015;372(15):1441–52.