Diagnostic Modalities for Inflammatory Bowel Disease: Serologic Markers and Endoscopy

Clarence Clark, MD, Jacquelyn Turner, MD*

KEYWORDS

• Serologic markers • Endoscopy • Inflammatory bowel disease

KEY POINTS

- Perinuclear antineutrophil cytoplasmic antibody is associated with ulcerative colitis; anti-*Saccharomyces cerevisiae* mannan antibodies are more commonly detected in patients with Crohn's disease (CD).
- Deep endoscopy is a useful tool for detection and surveillance of small bowel CD.
- Video capsule endoscopy and colon capsule endoscopy are promising modalities for gastrointestinal evaluation.
- Chromoendoscopy and confocal laser endomicroscopy allow for targeted biopsies which have shown to detect more intraepithelial neoplasms with fewer biopsy specimens.
- Endoscopic scoring systems help to increase intraobserver agreement of disease activity and severity among endoscopists.

INTRODUCTION

As endoscopic technology and advances in laboratory assays have evolved in the past two decades, better understanding of the pathogenesis and natural history of inflammatory bowel disease (IBD) has emerged. Central to these medical advances is the ability to discriminate between the subtypes of IBD (Crohn's disease [CD], ulcerative colitis [UC], and indeterminate colitis) especially when limited to the colon. Gross endoscopic and histologic findings in concert with serologic markers are critical to medicine and surgical specialties treating persons with these conditions. Herein, we examine the current literature as it pertains to endoscopy and serology as diagnostic tools for IBD.

The authors have nothing to disclose.
Department of Surgery, Division of Colon and Rectal Surgery, Morehouse School of Medicine, 720 Westview Drive Southwest, Atlanta, GA 30310, USA
* Corresponding author.
E-mail address: jturner@msm.edu

Surg Clin N Am 95 (2015) 1123–1141
http://dx.doi.org/10.1016/j.suc.2015.07.008 **surgical.theclinics.com**
0039-6109/15/$ – see front matter © 2015 Elsevier Inc. All rights reserved.

RELEVANT ANATOMY AND PATHOPHYSIOLOGY

Essential to the pathogenesis of IBD is the epithelial barrier of the gastrointestinal tract. This first line of defense is composed of a mucinous layer coupled with an epithelium that produces antimicrobial peptides that limit bacterial invasion.[1] Damage to the epithelial barrier leads to increased permeability and an increased uptake of luminal antigens. This process is often regarded as a key stage in the pathogenesis of IBD.

Pathologic features of UC include mucin depletion, erosion, and ulceration. Crypt architecture in UC is often distorted in addition to crypt branching, decreased crypt density, and crypt abscesses. Crypt architecture abnormalities are more common in UC than CD (57%–100% of cases compared with 21%–71% of cases, respectively).[2] At the level of the laminal propria, UC is notable for transmucosal inflammation and basal plasmacytosis.[1,2] In contrast, granulomas are characteristic of CD and be present in 21% to 37% of specimens taken.[2] Crypt architecture in CD includes segmental crypt atrophy and distortion. Both CD and UC have increased basal lamina propria cellularity and basal plasmacytosis.

CLINICAL PRESENTATION

Tables 1 and **2** and **Figs. 1–5** detail the clinical presentation of IBD.

SEROLOGIC MARKERS AS DIAGNOSTIC MODALITIES FOR INFLAMMATORY BOWEL DISEASE

Increased exposure to environmental microbiota and inflammatory response to common environmental pathogens have been implicated in the pathogenesis of IBD.[2–7] This association has led to a host of studies identifying serologic markers to these antigens for diagnosis and differentiation of the various subtypes of IBD. In this section, we review these serologic markers and the evidence for their use in the diagnosis and management of IBD.

Atypical Perinuclear Antineutrophil Cytoplasmic Antibody

Atypical perinuclear antineutrophil cytoplasmic antibody (pANCA) is a type of antibody that targets antigens present on azurophilic granules of polymorphonuclear leukocytes with a perinuclear staining pattern.[8] A number of studies have demonstrated

Table 1
Signs and symptoms of inflammatory bowel disease

Ulcerative Colitis	Crohn's Disease
• Disease confined to the colon; colonic involvement is usually left sided	• Small bowel is involved in 80% of cases; right sided colonic involvement
• Rectosigmoid colon is invariably involved	• Rectosigmoid junction is often spared
• Chronic, episodic	• Chronic, episodic
• Increased risk of colon cancer	• Perianal disease
• Bloody stools	• Fistulizing
• Tenesmus/fecal urgency	• Bowel obstruction
• Abdominal pain	• Increased risk of colon cancer
• Fever	• Nausea/vomiting
• Nocturnal diarrhea	• Weight loss
• Frequent small bowel movements	• Severe malabsorption
	• Bloody stools
	• Abdominal pain

Table 2
Endoscopic characteristics of inflammatory bowel disease

Ulcerative Colitis	Crohn's Disease
• Erythema	• Erythema
• Friability	• Friability
• Pseudopolyps	• Pathos ulcers
• Rectal involvement	• Linear/serpiginous ulcers
• Continuous involvement	• Rectal involvement (fairly common)
• Mucosa erythema	• Pseudopolyps (fairly common)
• Loss of colon architecture	• Segmental inflammation
• loss of vascular pattern	• Strictures
• Erosions	• Mucosal erythema
• Ulcerations	• Loss of villi
• Spontaneous bleeding	• Mucosal fissures
• Granularity	• Fistula scaring
	• Cobblestone appearance

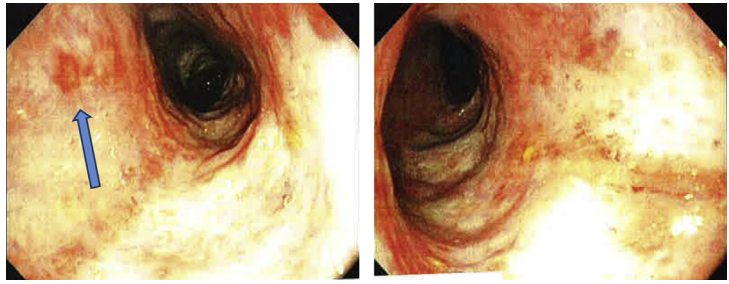

Fig. 1. Endoscopic findings of a Crohn's patient with loss of colonic architecture, friability, erythema, and aphthous ulceration (*blue arrow*).

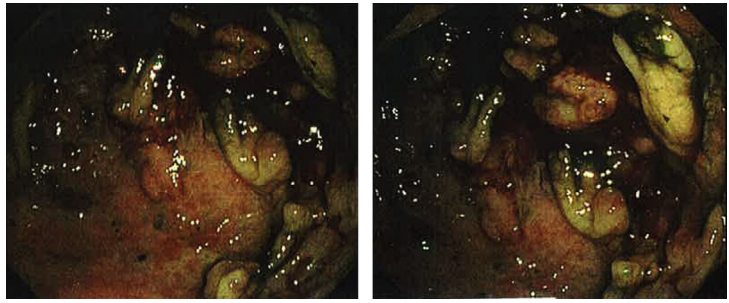

Fig. 2. Endoscopic findings from a patient with Crohn's disease with friability, erythema, and severe cobblestone appearance of the mucosa.

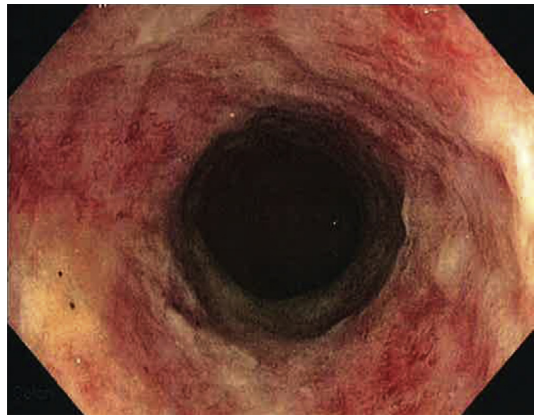

Fig. 3. A patient with Crohn's disease misdiagnosed as ulcerative colitis. Endoscopy shows loss of colon architecture, erythema, and friability.

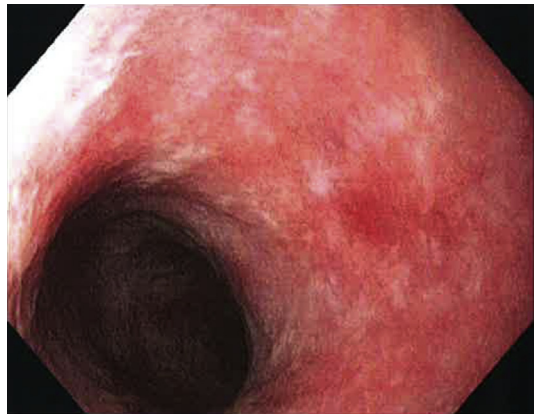

Fig. 4. Patient with ulcerative colitis showing mild left-sided colitis with loss of mucosal architecture.

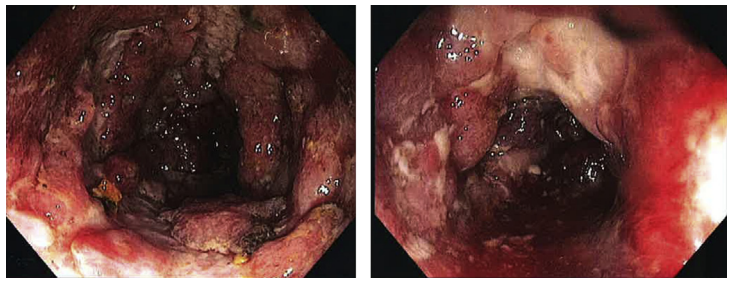

Fig. 5. Endoscopic findings of a patient with ulcerative colitis with pseudopolyps, erythema, friability, loss of vascular pattern, and fibrinous exudate.

the presence of these antibodies in the sera of patients with idiopathic inflammatory disorders, including but not limited to idiopathic rapidly progressive glomerulonephritis, microscopic polyangiitis, primary sclerosing cholangitis, and IBD.[9–11]

The prevalence of pANCA ranges from 40% to 80% in UC and from 0% to 20% in CD.[12–16] Peeters and colleagues[17] used indirect immunofluorescence for the detection of pANCA and showed a sensitivity, specificity, positive predictive value, and negative predictive value in differentiating IBD from controls of 50%, 95%, 69%, and 89%, respectively. This pattern of low sensitivity and high specificity for pANCA is also seen in patients with UC in various cohort studies.[18–22] In addition, Sandborn and colleagues[20] showed that the low sensitivity was seen across several laboratories with a range of 0% to 60% in patients with UC. In a metaanalysis of 60 studies composed of 3841 UC and 4019 CD patients, Reese and colleagues[21] reported a sensitivity and specificity of 55.3% and 88.5%, respectively, in UC patients positive for pANCA. Furthermore, the authors found an increased sensitivity and specificity (70.3% and 93.4%, respectively) in their pediatric subgroup when combined with a negative anti-*Saccharomyces cerevisiae* mannan antibodies (ASCA) tests. The use of pANCA alone, therefore, has utility in ruling out the presence of UC if this serology test is negative. Its use in combination with ASCA serologic testing, however, may offer improved diagnostic accuracy when differentiating patients with UC and CD.

Anti-Saccharimyces cerevisiae Antibody

In 1988, Main and colleagues[22] published one of the earliest reports of significantly elevated immunoglobulin (Ig)G and IgA blood titers to ASCA in 55 patients with Crohn's disease when compared with 30 controls. Since this study, numerous reports have been published examining this yeast found in dietary products and serologic markers associated with this organism.

Annese and colleagues[23] examined the presence of ASCA using standard enzyme-linked immunosorbent assay of patients with sporadic and familial CD or UC and their unaffected relatives. They found ASCAs were detected in 35% of patients with sporadic CD, 12% with sporadic UC, and 4% of controls. In addition, the presence of ASCA was significantly more frequent in patients with familial CD and familial UC than in sporadic cases. Accuracy data reported by Peeters and colleagues[17] revealed a sensitivity, specificity, positive predictive value, and negative predictive value rates for differentiating IBD from controls, using ASCA as a marker, of 60%, 91%, 88%, and 68%, respectively. Specifically in patients with CD, a similar sensitivity rate, ranging from 39% to 76%, has been reported in the literature.[20,24] However, with regard to CD limited to the colon, studies have shown a decrease in sensitivity of this serologic marker.[21]

When combined with a negative pANCA, a positive ASCA test has shown to have a higher sensitivity for CD at 54.6% with a 92.8% specificity in a recent metaanalysis.[21] Ruemmele and colleagues[18] showed that ASCA titers decreased toward normal values after resection in patients with CD. In summary, the presence of ASCA is most useful in confirming the diagnosis of CD and maybe a useful marker to trend after surgical resection for complicated CD.

Antibodies to Escherichia coli Outer Membrane Porin

Gram-negative bacteria cells are surrounded by an outer membrane layer with various transport proteins such as *Escherichia coli* outer membrane porin C (OmpC).[25] Serum antibodies to OmpC (anti-OmpC) have been used in the evaluation of IBD. Conflicting data exist regarding the utility of this serologic marker for the assessment of IBD. Mei

and colleagues[26] showed, in their cohort study of CD patients from CD-only families and from families with both UC and CD, a prevalence rate of 37.8% and 43.8%, respectively. A similar rate was seen by Arnott and colleagues[27] in CD patients, suggesting a possible role for this marker in the evaluation of IBD patients, specifically those with likely CD. To further define the role of this marker, anti-OmpC was assessed in various phenotypes of CD and was independently associated with internal perforations in patients with complicated small bowel CD.[28]

Several studies did not show, however, any benefit or diagnostic value of this assay.[29,30] In a retrospective review of 81 children with CD, 54 with UC, and 63 controls, Zholudev and colleagues[31] showed a sensitivity rate for CD and UC of 24% and 11%, respectively, for the anti-OmpC assay. The utility of this serologic marker alone in the management of IBD, therefore, has yet to be clearly elucidated thus far.

Pseudomonas fluorescens–Associated Sequence I2

The emergence of *P fluorescens*-associated sequence I2 began at the turn of the millennium. Sutton and colleagues[32] in 2000 identified I2 DNA in 43% of colonic specimens of CD patients compared with only 9% of UC and 5% of non-IBD tissue. The authors found this DNA to be prevalent in CD specimens, especially those originating from the ileum. Subsequently, *P fluorescens* was found to be the microorganism that encoded this DNA sequence.[33] To better understand the clinical utility of this marker, Arnott and colleagues,[27] in an observational study, showed anti-I2 was present in 52% of the sera from of CD patients. This pattern was also seen in pediatric patients with CD by Iltanen and colleagues.[34] This serologic marker thus has some promise when attempting to distinguish the various subtypes of IBD with a predilection to CD.

Flagellin CBir1/Fla-X/A4-Fla2

In 2004, Lodes and colleagues[35] showed elevated serum anti–flagellin IcG2a in an IBD mouse model and flagellin-specific $CD4^+$ T-cell induction of severe colitis in immunodeficient mice. From this observation, they were able to show the presence of serum IgG to these flagellins in patients with CD but not in patients with UC or controls. Specifically, significantly higher levels of serum anti–CBir1 and anti–Fla-X were found in CD patients. These findings suggest that CBir1 responses may be valuable in the diagnosis of IBD and discrimination between IBD subtypes.

After this study, further evidence was published to further define the role of CBir1 in the diagnosis of IBD. Enzyme-linked immunosorbent assay analysis of anti-CBir1 by Targan and colleagues[36] of 40 normal controls, 21 disease controls, 50 UC patients, and 373 CD patients previously typed for ASCA, anti-I2, anti-OmpC, and pANCA further defined the value of this marker. The authors showed IgG anti-CBir1 was associated with CD independently, especially in pANCA-positive patients with CD. In addition, anti-CBir1 expression was found to be associated with small bowel, internal-penetrating, and fibrostenosing disease.

With regard to the role of Fla-X flagellin, further studies by Schoepfer and colleagues[37] have defined the seroreactivity to Fla-X as well as similar flagellin strain, A4-Fla2, in a population of CD, UC, and healthy controls. Seropositivity to A4-Fla2 and Fla-X was found in 59% and 57% of patients with CD, respectively, whereas only 6% each in patients with UC, and 0% and 2% of healthy controls, respectively, were noted. These data along with prior studies demonstrate anti-CBir1, anti-Fla-X, and anti-A4-Fla2 may play a role in the diagnosis and discrimination between IBD

subtypes favoring the CD subtype when present. A summary of serologic markers is presented in **Table 3**.

Serologic Panels

Various combinations of ASCA, pANCA, anti-OmpC, anti-CBir1, and anti-I2 have been studied starting with pANCA and ASCA combined compared with more complex panels.[17,18,21,36–39] Although patterns of these markers may discriminate between CD and UC, the utility of such panels has recently come into question, more specifically as it compares with inexpensive, conventional laboratory blood tests such as complete blood count and/or erythrocyte sedimentation rate (ESR).

Sabery and colleagues[38] demonstrated in a pediatric observational study that serologic testing for IBD had 60% sensitivity, 92% specificity, and 60% positive predictive value. The authors found these rates were much lower compared with those seen in tests for anemia and ESR, especially in a subgroup of patients who do not have rectal bleeding. Similar findings were seen by Benor and colleagues,[39] who reported a sensitivity, specificity, positive predictive value, and negative predictive value for the serologic panel of 67%, 76%, 63%, 79%, and 42%, respectively. Higher values were seen in abnormal routine laboratory tests (age-adjusted hemoglobin, platelet count, and ESR) which were 72%, 94%, 85%, 79%, and 47%, respectively. The authors also reported a lower cost for complete blood count and ESR testing (<$100) compared with the cost of the IBD serology 7 panel (approximately $450). The use of combination serology panels, therefore, has promise but, given the cost and diagnostic value compared with conventional blood tests, the routine use of these panels is still being elucidated.

Table 3
Summary of serologic markers used for inflammatory bowel disease

Serologic Marker	Target	Disease Association
Perinuclear antineutrophil cytoplasmic antibody (pANCA)	Targets antigen on azurophilic granules of polymorphonuclear leukocytes	More commonly detected in UC
Anti-*Saccharomyces cerevisiae* mannan antibodies (ASCA)	Targets *Saccharimyces cerevisiae* antibody	More commonly detected in CD
Anti-outer membrane porin C (OmpC)	Targets the outer membrane transport protein found on *E coli*	More commonly detected in CD; specifically associated with perforated CD
Anti-I2	Antibodies to DNA sequence I2 encoded by *Pseudomonas flourescens*	More commonly detected in CD
Anti-CBir1	Antibodies to flagellin CBir1	More commonly detected in CD; specifically associated with small bowel, internal-penetrating, fibrostenosing disease
Anti-Fla-X/anti –A4-Fla2	Antibodies to flagellin Fla-X and similar flagellin strain A4-Fla2	More commonly detected in CD

Abbreviations: CD, Crohn's disease; UC, ulcerative colitis.

ENDOSCOPIC DIAGNOSTIC MODALITIES

Deep Enteroscopy

Deep enteroscopy is a useful way to assess the small bowel that in the past was inaccessible by routine endoscopy. The technique of deep enteroscopy was described in 2002.[40] The typical endoscope used for this procedure has a total working length ranging between 200 and 250 cm. With various maneuvers, this length allows the endoscopist to examine approximately 430 cm of small bowel via an oral antegrade approach or a retrograde approach through the rectum.[40,41]

There are 4 different deep enteroscopy systems currently available: balloon-assisted enteroscopy, single-balloon enteroscopy (SBE), double-balloon enteroscopy (DBE), and spiral enteroscopy (SE).[42] Herein, we examine these systems closely and the literature to support their use.

Balloon-assisted enteroscopy

Balloon-assisted enteroscopy uses a standard endoscope and an overtube with a balloon at its distal end. The purpose of the balloon is to stabilize the endoscope while in the small intestine.[43] The overtube, on the other hand, increases the stiffness of the scope, which can reduce excess looping in the stomach.[41] The overtube has been found to increase the depth of insertion significantly, although few clinical data exist supporting this added benefit.[43,44]

Single-balloon enteroscopy

The SBE is a push–pull technique using a standard endoscope with a flexible overtube. A latex-free balloon is attached at the tip of the overtube. The inflation and deflation of the balloon is controlled by a pressure-controlled pump system. The technique of SBE is described below.[45]

1. The endoscope with an overtube is introduced orally and advanced into the stomach.
2. The balloon on the overtube remains deflated until the duodenum is reached.
3. Once in the duodenum, the balloon is inflated to stabilize the enteroscope while it is advanced to a maximum distance.
4. The overtube balloon is then deflated and advanced along the enteroscope until the tip is reached.
5. The overtube balloon is then reinflated and the process is repeated.

The tip of the enteroscope can be angled to enable hooking behind a fold for stabilization. For further advancement, the enteroscope and the overtube can be pulled back simultaneously while the balloon is inflated to compress the bowel. An alternative for advancement is to pull back the overtube with the balloon inflated while simultaneously advancing the enteroscope.

Double-balloon enteroscopy

The DBE is also a push–pull technique that consist of a 2-balloon system (prototype: Fujinon, Inc, Saitman, Japan)[42]: 1 balloon is attached to a semiflexible overtube and the second balloon is attached to the enteroscope. The balloon inflation and deflation is controlled by a pressure-controlled pump system. The technique of DBE is described below.[40]

1. The endoscope with an overtube is introduced orally and advanced into the stomach.
2. The balloons remain deflated until the duodenum is reached.

3. Once in the duodenum, the balloon on the overtube is inflated to stabilize it in the intestine while the enteroscope is inserted to a maximum distance.
4. After the enteroscope is inserted at its maximum distance, the balloon on the enteroscope is inflated.
5. The balloon on the overtube is deflated and advanced over the endoscope until the tip of the scope is reached.
6. The balloon on the overtube is now reinflated to stabilize the bowel at a second point. The overtube is withdrawn to compress the bowel. The sequence is then repeated until the full length of the small bowel is reached.

Spiral enteroscopy

Spiral enteroscopy incorporates a rotational technique by using a special overtube with a helical thread at its distal segment (prototype: Spirus Medical INC, Stoughton, MA).[46] The overtube used for SE is slightly larger than the largest overtube used for DBE (16-mm vs 13.2-mm diameter, respectively).[42] The technique of SE is described below.[46]

1. The endoscope with an overtube is introduced orally and advanced into the stomach.
2. The endoscope is passed through the overtube and locked at the proximal end.
3. The scope and overtube are advanced beyond the ligament of Treitz.
4. The scope is then unlocked from the overtube and further advanced.
5. The overtube is then advanced over the scope in a clockwise rotation until it is just proximal to the tip of the scope (about 12 cm).
6. The overtube is relocked. The bowel becomes pleated with the advancement of the overtube. The steps are repeated until the rotation is no longer effective.
7. After the scope has reached its maximum distance, the scope and overtube are withdrawn. During withdrawal, the overtube is turned counterclockwise while examining the mucosa.

Outcomes of Deep Enteroscopy

When comparing the different techniques, DBE, SBE, and SE have similar diagnostic yields. Lenz and colleagues[43] evaluated several studies comparing DBE, SBE, and SE. Oral intubation depth was comparable between DBE (239 $\pm$ 24.3 cm), SBE (233 $\pm$ 31 cm), and SE (236 $\pm$ 23 cm). However, anal intubation depth was much lower in the SE group (88 $\pm$ 25 cm) compared with the depth obtained by DBE (130 $\pm$ 18 cm) and SBE (123 $\pm$ 34 cm). Complete enteroscopy was more likely to be achieved in the DBE group (33.9% $\pm$ 10.1%) compared with the SBE (12.4% $\pm$ 9.8%) and SE (2.9% $\pm$ 4.3%).[43] When comparing SBE with SE, there are no differences in procedure time despite the shorter depth of insertion seen in the SBE group.[47] Messer and colleagues[42] compared DBE with SE and found a significantly higher complete enteroscopy rate with DBE (92%) compared with SE (8%). However, DBE is more time consuming with an average examination time of 59.62 $\pm$ 12.5 minutes, whereas SE has an average examination time of 43.43 $\pm$ 10.19 minutes. There was no difference in diagnostic or therapeutic yields when DBE was compared with SE (69% vs 46%, respectively; $P = 0.428$).

The most common site for CD is the terminal ileum, which may be difficult to evaluate in its entirety. Observation of about 100 cm of bowel from the terminal ileum is usually significant.[48] A combination of small bowel follow through, DBE, and ileal intubation during colonoscopy can provide adequate assessment of the ileum.

With regard to postprocedure outcomes, deep enteroscopy has a low complication rate. Specifically, DBE has a complication rate of 1%.[42] Pancreatitis is a commonly

reported complication of deep enteroscopy. Pancreatitis can be avoided by inflating the balloons after passing the ligament of Treitz.[43] Significant abdominal pain and perforation (likely caused by the overtube or at the site of ulcerative pathology) has also been reported.[42,48]

Video Capsule Endoscopy

Video capsule endoscopy (VCE; prototype: Given Imaging; Yoqneam, Israel) has been available in the United States since 2001.[49] The VCE is a wireless video-containing capsule. Within the capsule is a sensing system that includes a sensing belt, data recorder unit, battery pack, and real-time viewer. Contraindications of VCE include known strictures, obstruction, fistulas, and pregnancy. Implanted electromedical devices, such as a cardiac pacemaker, are a relative contraindication owing to a potential risk of magnetic interference. MRI or computed tomographic enterography is needed in patients with suspected CD to evaluate for strictures before VCE. Optionally, a patency capsule, made up of lactose and barium sulfate surrounded by cellophane walls, has been used to determine patency of the gastrointestinal tract before VCE. If the capsule is retained, the components of the capsule dissolve after 30 hours. The nondissolvable components are usually able to pass through strictures. VCE is then performed if the capsule passes intact or if the radiofrequency tag inside the capsule is not detected by the radiofrequency scanner after 30 hours.

VCE has been compared with push enteroscopy and enteroclysis. VCE has a higher yield of detecting small bowel disease.[50,51] A metaanalysis comparing VCE with push enteroscopy for obscure gastrointestinal bleeding found that VCE had a higher diagnostic yield than push enteroscopy (63% vs 28%, respectively; $P<0.00001$).[51] Chong and colleagues[50] detected small bowel disease in 3 of 22 patients with known CD who underwent push enteroscopy, 4 of 21 patients who underwent enteroclysis, and 17 of 22 patients who underwent VCE ($P<0.001$). However, disadvantages of VCE include the inability to definitively localize and/or sample pathology.[48] In addition, incomplete examinations can occur in up to 80% of patients. Inpatient status, delayed gastric emptying, and prior abdominal surgery have been associated with incomplete examinations. Chong and colleagues[50] reported battery life as a problem with capsule endoscopy and that 6 of 43 patients had incomplete examinations owing to a limited battery life. Complications include capsule retention with 1.4% needing surgical or endoscopic removal of the retained capsule.[49] A summary of deep endoscopy modalities and VCE is presented in **Table 4**.

Magnification Endoscopy and Chromoendoscopy (Dye-Based and Dyeless Chromoendoscopy)

Several techniques have emerged to enhance the visualization of mucosal surfaces in IBD patients. Detailed characterization of mucosal surfaces and pit patterns can aid in targeted biopsies for more effective surveillance of IBD patients. Enhancing the mucosal surface features can be accomplished with magnification, dye agents, and optical or digital enhancement.[52–54]

Magnification endoscopy allows for detailed inspection of the mucosa through a movable lens with 1.5- to 150-fold magnification.[52,53] This technology is often used in conjunction with chromoendoscopy. Chromoendoscopy uses dyes to stain the mucosa surface, resulting in improved pattern recognition and clarify borders of neoplastic lesion.[53,54] The dyes are sprayed by a catheter through the working channel of the endoscope. Such dyes include absorptive agents (Lugol solution, methylene blue, toluidine blue, and cresyl violet), contrast agents (indigo carmine and acetic acid), and reactive staining agents (Congo red and phenol red). The enhancement

Table 4
Summary of deep endoscopy modalities and video capsule endoscopy

	Advantages	Disadvantages
Balloon-assisted enteroscopy	Push–pull technique	• Risk of perforation, postprocedural pancreatitis, and postprocedural abdominal pain • Associated learning curve
Single-balloon enteroscopy	Push–pull technique	• Risk of perforation, postprocedural pancreatitis, and postprocedural abdominal pain • Associated learning curve
Double-balloon enteroscopy	• Push–pull technique • More likely to perform complete enteroscopy	• More time consuming • Risk of perforation, postprocedural pancreatitis, and postprocedural abdominal pain • Associated learning curve
Spiral enteroscopy	• Rotational technique • Less time consuming	• Shorter depth of intubation with anal approach • Risk of perforation, postprocedural pancreatitis, and postprocedural abdominal pain • Associated learning curve
Video capsule endoscopy	• Video capsule technique • Less invasive • High negative predictive value for Crohn's disease • Higher diagnostic yield for detecting small bowel disease	• Contraindicated with known strictures, obstruction, fistulas and pregnancy • Need preprocedural evaluation with computed tomography enterography, MRI, or patency capsule to evaluate for strictures • Relatively contraindicated with implanted electromedical devices • Inability to definitively localize lesion • Inability to sample tissue • Capsule retention may occur needing endoscopic removal of retained capsule

of mucosal detail has allowed for categorization of the different staining patterns of the colon.[52,53]

Dyeless chromoendoscopy uses either optical imaging or computer based imaging. Narrow band imaging (Olympus, Tokyo, Japan) or compound band imaging (Aohua, Shanghai, China) are 2 common optical chromoendoscopy enhancement systems that alter the bandwidth of transmitted light through filters within the light source of the endoscope. I-scan (Pentax, Tokyo, Japan) and Fujinon intelligent color enhancement (Fujinon, Tokyo, Japan) are 2 digital chromoendoscopy enhancement systems.[52]

Colonic chromoendoscopy and targeted biopsies of suspicious lesions are more effective in surveying IBD patients for intraepithelial neoplasia than previous methods of taking multiple, random biopsies.[52,53] In addition, chromoendoscopy has been shown to provide more accurate diagnosis of disease activity when compared with white light endoscopy.[55,56] Neumann and colleagues[56] demonstrated that there is an increased agreement between histology and dyeless chromoendoscopy compared with high-definition white light colonoscopy with regard to disease extent (48.71% and 92.31%, respectively) and disease activity (53.85% and 89.74%) of UC.

There are several limitations to magnification and chromoendoscopy. The high magnification setting can make screening impractical in this mode and examination difficult with peristalsis and respiratory movements. In addition, inflammation can disturb the image and produce false-positive results. Last, there is a learning curve to this technique that can increase the procedure time initially.[53]

Confocal Laser Endomicroscopy

Endomicroscopy is relatively new technology that allows for imaging of the cellular and subcellular level of the mucosa during colonoscopy.[54] It is being used for IBD patients to improve dysplasia detection and differentiation of lesions, such as colitis-associated neoplasia, sporadic neoplasia, and nonneoplastic lesions. These lesions can easily be missed with standard endoscopy owing to their flat appearance in colitis patients.[57] The technique of confocal laser endomicroscopy (CLE) involves using a low-power laser to focus on a single point in a microscopic field of view. The lens used for CLE allows for both illumination and detection systems to align in the same focal plane, thus the term confocal.

Currently, there are 2 CLE-based systems: the Pentax Endomicroscopy System from Japan, which uses an integrated confocal scanner at the tip of a flexible endoscope, and the Cellvizio Endomicroscopy System (Mauna Kea Technologies, Paris, France), which uses a flexible miniprobe inserted through the working channel of an endoscope.[54] CLE can be further guided using contrast agents, such as intravenous fluorescein and topical acriflavine and cresyl violet, to enhance the image.

CLE is useful in predicting inflammatory and neoplastic activity. Kiesslich and colleagues[57] found overall concordance between CLE and histology in determining UC disease activity to be 92.5% compared with 58.9% concordance with standard endoscopy. Moreover, this study revealed more intraepithelial neoplastic lesions are identified with CLE (19 of 80) compared with standard endoscopy (4 of 73; $P = 0.005$). Neumann and colleagues[58] determined that CLE could identify architectural changes (such as crypt tortuosity, crypt dilation, microerosion, vascularity, number of goblet cells, and cellular infiltrate in the laminal propria) in patients with active CD similar to established histopathologic criteria.

Similar to chromoendoscopy, CLE allows for targeted biopsies thus reducing the number of random biopsies.[54,57] Overall, 4.75-fold more intraepithelial neoplasms could be detected with 50% fewer biopsy specimens using CLE when compared with standard endoscopy.[57] One limitation, as seen with chromoendoscopy, is the lengthy time required to examine large surface areas.

Colon Capsule Endoscopy

Recently, a VCE device, referred to as colon capsule endoscopy (CCE), was developed specifically to target colonic mucosal evaluation. One such device is PillCam Colon (Given Imaging).[49,59] In a study by Herrerias-Gutierrez et al,[60] 144 patients were evaluated with the aim of comparing outcomes of CCE with colonoscopy. These authors found a rate of agreement between CCE and colonoscopy to be 75.6%. There are few studies evaluating CCE as a diagnostic modality for IBD to date. Sung and colleagues[61] have published the largest prospective trial evaluating the PillCam Colon in UC patients. One hundred patients were evaluated with 4 patients excluded owing to technical failure or slow transit time of the capsule. Nine patients had transit times of greater than 8.5 hours requiring endoscopic removal of the capsule. The specificity and sensitivity to detect mucosal inflammation was 89% and 75%, respectively. The authors concluded that CCE is a safe procedure and can be used to monitor mucosal healing in UC. A summary of colonoscopy imaging modalities is provided in **Table 5**.

Table 5
Summary of colonoscopic imaging techniques

	Advantages	Disadvantages
Magnification endoscopy	• Enhances mucosal surfaces through a magnification lens • Can be used for targeted biopsies • Can be used in conjunction with chromoendoscopy	• Not practical for screening endoscopy • Inflammation in colitis can produce false positives • Associated learning curve
Chromoendoscopy	• Enhances mucosal surfaces through spray dyes • Can be used for targeted biopsies • Can be used in conjunction with chromoendoscopy and confocal laser endomicroscopy • More accurate diagnosis of disease activity than white light endoscopy	• Inflammation in colitis can produce false positives • Associated learning curve
Confocal laser endomicroscopy	• Images the cellular and subcellular level of the mucosa • Improves the detection of dysplasia, colitis-associated neoplasia, sporadic neoplasia, and nonneoplastic lesions • Can be used in conjunction with chromoendoscopy • Can be used for targeted biopsies	• Time consuming • Not practical for screening endoscopy
Colon capsule endoscopy	• Video capsule technique • Less invasive	• Capsule retention may occur which may limit examination • Limited studies

ENDOSCOPIC MONITORING OF DISEASE ACTIVITY

Endoscopic monitoring and determining severity of disease activity can be interpreted differently by clinicians. Scoring systems have been developed to increase intraobserver agreement of disease activity and severity. There are many scoring systems for endoscopic monitoring of disease activity in both CD and UC. The commonly used scoring systems for UC and CD are presented in **Tables 6–8**.

Currently, the Mayo endoscopic subscore is the most used to describe endoscopic activity in clinical trials.[2] A Mayo subscore of 0 or 1 is commonly accepted as criteria for mucosal healing with a decreased likelihood of needed a colectomy.[2,62] In addition

Table 6
Mayo endoscopic subscore

Subscore	Disease Activity	Endoscopic Feature
0	Normal or inactive disease	—
1	Mild disease	Erythema, decreased vascular pattern, mild friability
2	Moderate disease	Marked erythema, absent vascular patter, friability, erosions
3	Severe disease	Spontaneous bleeding, ulceration

Adapted from Mazzouli S, Guglielmi F, Antonelli E, et al. Definition and evaluation of mucosal healing in clinical practice. Dig Liver Dis 2013;45:969–77; and Schroeder K, Tremaine W, Ilstrup D. Coated oral 5-aminosalicylic acid therapy for mildly to moderately active ulcerative colitis. A randomized study. N Engl J Med 1987;317(1987):1625–9.

Table 7
Ulcerative Colitis Colonoscopic Index of Severity (UCCIS)

Lesion	Score	Endoscopic Feature
Vascular pattern	0	Normal, clear vascular pattern
	1	Partially visible vascular pattern
	2	Complete loss of vascular patter
Granularity	0	Normal, smooth and glistening
	1	Fine
	2	Coarse
Ulceration	0	Normal, no erosion or ulcer
	1	Erosions or pinpoint ulcerations
	2	Numerous shallow ulcers with mucopus
	3	Deep, excavated ulcerations
	4	Diffusely ulcerated with >30% involvement
Bleeding/friability	0	Normal, no bleeding, no friability
	1	Friable, bleeding to light touch
	2	Spontaneous bleeding
Grading of global assessment of endoscopic severity and segmental assessment of endoscopic severity	0	Normal/quiescent: visible vascular pattern with no bleeding, erosions, ulcers, or friability
	1	Mild: erythema, decreased or loss of vascular pattern, fine granularity, but no friability or spontaneous bleeding
	2	Moderate: friability with bleeding to light touch, coarse granularity, erosions, or pinpoint ulcerations
	3	Severe: spontaneous bleeding or gross ulcers

From Samuel S, Bruining D, Loftus E, et al. Validation of the ulcerative colitis colonoscopic index of severity and its correlation with disease activity measures. Clin Gastroenterol Hepatol 2013;11:50; with permission.

to the Mayo endoscopic subscore, the Mayo score consist of evaluating stool frequency, rectal bleeding, endoscopic findings, and physician global assessment on a scale of 0 to 3 for a total possible score between 0 and 12. A score of less than 2 indicates remission, whereas a score of 11 or 12 indicates severe disease. Several studies have reported fair intraobserver agreement for the Mayo scale.[63–65]

Table 8
Sample of Crohn's Disease Endoscopic Index of Severity (CDEIS) score sheet

Parameter	Rectum	Sigmoid and Left Colon	Transverse Colon	Right Colon	Ileum	Total
Deep ulceration (12 if present, 0 if absent)	—	—	—	—	—	Total 1
Superficial ulceration (6 if present, 0 if absent)	—	—	—	—	—	Total 2
Surface involved by disease (in cm)	—	—	—	—	—	Total 3
Ulcerated surface (in cm)	—	—	—	—	—	Total 4

Total 1 + 2 + 3 + 4 = Total *A*.
Number of segments totally or partially explored (1–5) = *n*.
Total *A*/*n* = Total *B*.
If ulcerated stenosis is present, Total *C* = 3. If no ulcerated stenosis is present Total *C* = 0.
If nonulcerated stenosis is present, Total *D* = 3, If no ulcerated stenosis is present Total *D* = 0.
Total *B* + Total *C* + Total *D* = CDEIS.
From Cohen R. Should mucosal healing be used instead? AGA Perspectives 2013;9(2):7.

The Mayo scoring system was created based on sigmoidoscopy examinations. In contrast, the Ulcerative Colitis Colonoscopic Index of Severity is a scoring system created from full, high-definition colonoscopic findings.[49] The Ulcerative Colitis Colonoscopic Index of Severity significantly correlates with clinical indexes of disease activity and laboratory parameters of active inflammation (hemoglobin, albumin, and C-reactive protein).[64]

The Crohn's Disease Endoscopic Index of Severity, which was developed in 1989, is the first endoscopic scoring system for evaluating CD.[2] This scoring system is not only used to guide treatment strategies, it has shown to predict corticosteroid-free clinical remission.[66]

SUMMARY

A thorough history and physical examination are essential to diagnose IBD clinically. Endoscopic, serologic, and histologic evaluation is needed to confirm the diagnosis of IBD. Distinguishing between UC and CD can be a challenge. Serologic studies can aid in this process. ASCA, anti-OmpC, anti-CBir1, and anti–Fla-X-flagellin are detected more commonly in CD, whereas pANCA is more commonly detected in UC.

The visual assessment and monitoring of small bowel CD can be particularly difficult for the clinician. Deep enteroscopy and ileal intubation during colonoscopy can provide adequate assessment of the entire small bowel. VCE has a higher yield of detecting small bowel disease when compared with enteroscopy. Conversely, the inability to definitively localize lesions and obtain tissue samples is a disadvantage of VCE.

The emergence of novel imaging technology for the evaluation of the colon and rectum has shown promise in the management of IBD. Chromoendoscopy has shown to increase agreement between endoscopy and histology when compared with high-definition white light colonoscopy. Both chromoendoscopy and CLE allow for targeted biopsies, thus decreasing the number of random biopsies. However, the lengthy time required to examine large surface areas currently limits this technique when surveying the entire colon. CCE is still being developed as a diagnostic tool for IBD as well as the use of scoring systems to improve observer agreement among clinicians.

REFERENCES

1. Ordas I, Eckmann L, Talamini M, et al. Ulcerative colitis. Lancet 2012;380:1606–19.
2. Mazzouli S, Guglielmi F, Antonelli E, et al. Definition and evaluation of mucosal healing in clinical practice. Dig Liver Dis 2013;45:969–77.
3. Wayne LG, Hollander D, Anderson B, et al. Immunoglobulin A (IgA) and IgG serum antibodies to mycobacterial antigens in patients with Crohn's disease and their relatives. J Clin Microbiol 1992;30:2013–8.
4. Blaser MJ, Miller RA, Lacher J, et al. Patients with active Crohn's disease have elevated serum antibodies to antigens of seven enteric bacterial pathogens. Gastroenterology 1984;87:888–94.
5. Liu Y, Van Kruiningen HJ, West AB, et al. Immunocytochemical evidence of Listeria, *Escherichia coli*, and Streptococcus antigens in Crohn's disease. Gastroenterology 1995;108:1396–404.
6. De Hertogh G, Aerssens J, Geboes KP, et al. Evidence for the involvement of infectious agents in the pathogenesis of Crohn's disease. World J Gastroenterol 2008;14(6):845–52.

7. Chen S-J, Liu X-W, Liu J-P, et al. Ulcerative colitis as a polymicrobial infection characterized by sustained broken mucus barrier. World J Gastroenterol 2014; 20(28):9468–75.
8. Hartman C, Eliakim R, Shamir R. Perinuclear antineutrophil cytoplasmic autoantibodies and anti-Saccharomyces cerevisiae antibodies: serologic markers in inflammatory bowel disease. Isr Med Assoc J 2004;6(4):221–6.
9. Morgan MD, Harper L, Williams J, et al. Anti-neutrophil cytoplasm-associated glomerulonephritis. J Am Soc Nephrol 2006;17(5):1224–34.
10. Stone JH, Talor M, Stebbing J, et al. Test characteristics of immunofluorescence and ELISA tests in 856 consecutive patients with possible ANCA-associated conditions. Arthritis Care Res 2000;13:424–34.
11. Seibold F, Weber P, Schöning A, et al. Neutrophil antibodies (pANCA) in chronic liver disease and inflammatory bowel disease: do they react with different antigens? Eur J Gastroenterol Hepatol 1996;8:1095–100.
12. Saxon A, Shanahan F, Landers C, et al. A distinct subset of antineutrophil cytoplasmic antibodies is associated with inflammatory bowel disease. J Allergy Clin Immunol 1990;86:202.
13. Rump JA, Schölmerich J, Gross V, et al. A new type of perinuclear antineutrophil cytoplasmic antibody (p-ANCA) in active ulcerative colitis but not in Crohn's disease. Immunobiology 1990;181:406–13.
14. Duerr RH, Targan SR, Landers CJ, et al. Anti-neutrophil cytoplasmic antibodies in ulcerative colitis: comparison with other colitides/diarrheal illnesses. Gastroenterology 1991;100:1590–6.
15. Colombel JF, Reumaux D, Duthilleul P, et al. Antineutrophil cytoplasmic autoantibodies in inflammatory bowel diseases. Gastroenterol Clin Biol 1992;16:656–60, 7 Cambridge G.
16. Rampton DS, Stevens TRJ, Reumaux D, et al. Antineutrophil antibodies in inflammatory bowel disease: prevalence and diagnostic role. Gut 1992;33:668–74.
17. Peeters M, Joossens S, Vermeire S, et al. Diagnostic value of anti-Saccharomyces cerevisiae and antineutrophil cytoplasmic autoantibodies in inflammatory bowel disease. Am J Gastroenterol 2001;96(3):730–4.
18. Ruemmele FM, Targan SR, Levy G, et al. Diagnostic accuracy of serological assays in pediatric inflammatory bowel disease. Gastroenterology 1998;115:822–9.
19. Vermeire S, Peeters M, Vlietinck R, et al. Anti-Saccharomyces cerevisiae antibodies (ASCA), phenotypes of IBD, and intestinal permeability: a study in IBD families. Inflamm Bowel Dis 2001;7(1):8–15.
20. Sandborn WJ, Loftus EV Jr, Colombel JF, et al. Evaluation of serologic disease markers in a population-based cohort of patients with ulcerative colitis and Crohn's disease. Inflamm Bowel Dis 2001;7(3):192–201.
21. Reese GE, Constantinides VA, Simillis C, et al. Diagnostic precision of anti-Saccharomyces cerevisiae antibodies and perinuclear antineutrophil cytoplasmic antibodies in inflammatory bowel disease. Am J Gastroenterol 2006; 101(10):2410–22.
22. Main J, McKenzie H, Yeaman GR, et al. Antibody to Saccharomyces cerevisiae (bakers' yeast) in Crohn's disease. BMJ 1988;297(6656):1105–6.
23. Annese V, Andreoli A, Andriulli A, et al. Familial expression of anti-Saccharomyces cerevisiae Mannan antibodies in Crohn's disease and ulcerative colitis: a GISC study. Am J Gastroenterol 2001;96(8):2407–12.
24. Vermeire S, Joossens S, Peeters M, et al. Comparative study of ASCA (anti-Saccharomyces cerevisiae antibody) assays in inflammatory bowel disease. Gastroenterology 2001;120(4):827–33.

25. Nikaido H. Porins and specific channels of bacterial outer membranes. Mol Microbiol 1992;6(4):435–42.
26. Mei L, Targan SR, Landers CJ, et al. Familial expression of anti-*Escherichia coli* outer membrane porin C in relatives of patients with Crohn's disease. Gastroenterology 2006;130(4):1078–85.
27. Arnott ID, Landers CJ, Nimmo EJ, et al. Sero-reactivity to microbial components in Crohn's disease is associated with disease severity and progression, but not NOD2/CARD15 genotype. Am J Gastroenterol 2004;99(12):2376–84.
28. Mow WS, Vasiliauskas EA, Lin YC, et al. Association of antibody responses to microbial antigens and complications of small bowel Crohn's disease. Gastroenterology 2004;126(2):414–24.
29. Davis MK, Andres JM, Jolley CD, et al. Antibodies to *Escherichia coli* outer membrane porin C in the absence of anti-Saccharomyces cerevisiae antibodies and anti-neutrophil cytoplasmic antibodies are an unreliable marker of Crohn disease and ulcerative colitis. J Pediatr Gastroenterol Nutr 2007;45(4):409–13.
30. Petersen AM, Schou C, Mirsepasi H, et al. Seroreactivity to E. coli outer membrane protein C antibodiesin active inflammatory bowel disease; diagnostic value and correlation with phylogroup B2 E. coli infection. Scand J Gastroenterol 2012; 47(2):155–61.
31. Zholudev A, Zurakowski D, Young W, et al. Serologic testing with ANCA, ASCA, and anti-OmpC in children and young adults with Crohn's disease and ulcerative colitis: diagnostic value and correlation with disease phenotype. Am J Gastroenterol 2004;99(11):2235–41.
32. Sutton CL, Kim J, Yamane A, et al. Identification of a novel bacterial sequence associated with Crohn disease. Gastroenterology 2000;119(1):23–31.
33. Wei B, Huang T, Dalwadi H, et al. *Pseudomonas fluorescens* encodes the Crohn's disease-associated I2 sequence and T-cell superantigen. Infect Immun 2002; 70(12):6567–75.
34. Iltanen S, Tervo L, Halttunen T, et al. Elevated serum anti-I2 and anti-OmpW antibody levels in children with IBD. Inflamm Bowel Dis 2006;12(5):389–94.
35. Lodes MJ, Cong Y, Elson CO, et al. Bacterial flagellin is a dominant antigen in Crohn disease. J Clin Invest 2004;113(9):1296–306.
36. Targan SR, Landers CJ, Yang H, et al. Antibodies to CBir1 flagellin define a unique response that is associated independently with complicated Crohn's disease. Gastroenterology 2005;128(7):2020–8.
37. Schoepfer AM, Schaffer T, Mueller S, et al. Phenotypic associations of Crohn's disease with antibodies to flagellins A4-Fla2 and FlaX, ASCA, p-ANCA, PAB, and NOD2 mutations in a Swiss Cohort. Inflamm Bowel Dis 2009;15(9): 1358–67.
38. Sabery N, Bass D. Use of serologic markers as a screening tool in inflammatory bowel disease compared with elevated erythrocyte sedimentation rate and anemia. Pediatrics 2007;119(1):e193–9.
39. Benor S, Russell GH, Silver M, et al. Shortcomings of the inflammatory bowel disease Serology 7 panel. Pediatrics 2010;125(6):1230–6.
40. Yamamoto H, Sugano K. A new method of enteroscopy – the double-balloon method. Can J Gastroenterol 2003;17:273–4.
41. Tharian B, Caddy G, Tham T. Enteroscopy in small bowel Crohn's disease: a review. World J Gastrointest Endosc 2013;5(10):476–86.
42. Messer I, May A, Manner H, et al. Prospective, randomized, single-center trial comparing double balloon enteroscopy and spiral enteroscopy in patients with suspected small-bowel disorders. Gastrointest Endosc 2013;77(2):241–9.

43. Lenz P, Domagk D. Double- vs. single- balloon vs spiral enteroscopy. Best Pract Res Clin Gastroenterol 2012;26:303–13.
44. Benz C, Jakobs R, Rieman J. Do we need the overtube for push-enteroscopy? Endoscopy 2001;33(8):658–61.
45. Hartmann D, Eickhoff A, Tamm R, et al. Balloon-assisted enteroscopy using a single-balloon technique. Endoscopy 2007;39:E276.
46. Akerman P, Agrawal D, Chen W, et al. Spiral enteroscopy: a novel method of enteroscopy by using the Endo-Ease Discovery SB overtube and a pediatric colonoscope. Gastrointest Endosc 2009;69(2):327–32.
47. Khashab M, Helper D, Johnson C, et al. Predictors of depth of maximal insertion at double-balloon enteroscopy. Dig Dis Sci 2010;55(5):1391–5.
48. Sunada K, Yamamoto H, Yano T, et al. Advances in the diagnosis and treatment of small bowel lesions with Crohn's disease using double-balloon endoscopy. Therap Adv Gastroenterol 2009;2:357–66.
49. Bouchard S, Ibrahim M, Gossum A. Video capsule endoscopy: perspectives of a revolutionary technique. World J Gastroenterol 2014;20(46):17330–44.
50. Chong A, Taylor A, Miller A, et al. Capsule endoscopy vs. push enteroscopy and enteroclysis in suspected small-bowel Crohn's disease. Gastrointest Endosc 2005;61(2):255–61.
51. Triester S, Leighton J, Leontiadis G, et al. A meta-analysis of the yield of capsule endoscopy compared to other diagnostic modalities in patients with obscure gastrointestinal bleeding. Am J Gastroenterol 2005;100(11):2407–8.
52. Tontini G, Vecchi M, Neuraht M, et al. Advanced endoscopic imaging techniques in Crohn's disease. J Crohns Colitis 2014;8:261–9.
53. Kiesslich R, Jung M, DisSario J, et al. Perspectives of chromo and magnifying endoscopy- how, how much, when, whom should we stain? J Clin Gastroenterol 2004;38(1):7–13.
54. Teubner D, Kiesslich R, Matsumoto T, et al. Beyond standard image-enhanced endoscopy confocal endomicroscopy. Gastrointest Endosc Clin N Am 2014;24:427–34.
55. Kiesslich R, Fritsch J, Holtmann M, et al. Methylene blue-aided chromoendoscopy for the detection of intraepithelial neoplasia and colon cancer in ulcerative colitis. Gastroenterology 2003;124:880–8.
56. Neumann H, Vieth M, Gunther C, et al. Virtual chromoendoscpy for prediction of severity and disease extent with inflammatory bowel disease: a randomized controlled study. Inflamm Bowel Dis 2013;19(9):1935–42.
57. Kiesslich R, Goetz M, Lammersdorf K, et al. Chromoscopy-guided endomicroscopy increases the diagnostic yield of intraepithelial neoplasia in ulcerative colitis. Gastroenterology 2007;132:874–82.
58. Neumann H, Vieth M, Atreya R, et al. Assessment of Crohn's disease activity by confocal laser endomicroscopy. Inflamm Bowel Dis 2012;18(12):2261–9.
59. Eliakam R, Fireman Z, Gralnek M, et al. Evaluation of the PillCam colon capsule in the detection of colonic pathology: results of the first multicenter, prospective comparative study. Endoscopy 2006;38(10):963–70.
60. Herrerias-Gutierrez J, Arguelles-Arias F, Caunedo-Alvarez A, et al. PillCamColon capsule for the study of colonic pathology in clinical practice. Study of agreement with colonoscopy. Rev Esp Enferm Dig 2011;103(2):69–75.
61. Sung J, Ho K, Chiu H, et al. The use of Pillcam colon in assessing mucosal inflammation in ulcerative colitis: a multicenter study. Endoscopy 2012;44(8):754–8.

62. Schroeder K, Tremaine W, Ilstrup D. Coated oral 5-aminosalicylic acid therapy for mildly to moderately active ulcerative colitis. A randomized study. N Engl J Med 1987;317(26):1625–9.
63. Daperno M, Comberlato M, Bossa F, et al. Intra-observer agreement in endoscopic scoring systems: Preliminary report of an ongoing study from the Italian Group for Inflammatory Bowel Disease (IG-IBD). Dig Liver Dis 2014;46:969–73.
64. Samuel S, Bruining D, Loftus E, et al. Validation of the ulcerative colitis colonoscopic index of severity and its correlation with disease activity measures. Clin Gastroenterol Hepatol 2013;11:49–54.
65. Walsh A, Brain O, Keshav S, et al. How variable is the Mayo score between observers and might this affect trial recruitment or outcome? Gastroenterology 2009;136:A677.
66. Ferrante M, Colobel J, Sandborn W, et al. Validation of endoscopic activity scores in patients with Crohn's disease based on a post hoc analysis of data from SONIC. Gastroenterology 2013;145:978–86.