Extraintestinal Manifestations Associated with Inflammatory Bowel Disease

Shaun R. Brown, DO[a,b], Lisa C. Coviello, DO[c,d,*]

KEYWORDS

- Inflammatory bowel disease • Multiple organ systems
- Extraintestinal manifestations

KEY POINTS

- Inflammatory bowel disease (IBD) affects multiple organ systems outside of the gastrointestinal tract.
- The clinician treating patients with IBD should be acutely aware of the diagnosis and treatment of extraintestinal manifestations in order to decrease morbidity.
- The management can be difficult and often times requires a multidisciplinary approach.
- Future research investigating the pathophysiology, diagnosis, and treatment is needed to further the care of these patients.

INTRODUCTION

Extraintestinal manifestations (EIMs) associated with inflammatory bowel disease (IBD) are conditions commonly seen in patients who suffer from ulcerative colitis (UC) or Crohn's disease (CD). These manifestations can involve several organ systems and may develop before the onset of gastrointestinal symptoms. In this article, the major EIMs of IBD affecting the musculoskeletal, dermatologic, hepatobiliary, ocular, renal, and pulmonary system are reviewed, as well as current treatment options (**Table 1**).

The underlying pathophysiology related to the development of EIM associated with IBD remains uncertain. Several hypotheses have been proposed, including genetic susceptibility, abnormal self-recognition, and autoantibodies against organ-specific cellular antigens shared by the gastrointestinal tract and other organ systems[1]; this

[a] Department of Colorectal Surgery, Oschner Clinic Foundation, New Orleans, LA, USA; [b] Department of Surgery, Uniformed Services University of Health Sciences, Bethesda, MD 20814, USA; [c] Department of Surgery, National Capital Region Medical Directorate, Fort Belvoir, VA 22060, USA; [d] Department of Surgery of the Uniformed Services University of Health Sciences and the Walter Reed National Military Medical Center, Bethesda, MD 20814, USA
* Corresponding author.
E-mail address: lccovi@gmail.com

Surg Clin N Am 95 (2015) 1245–1259
http://dx.doi.org/10.1016/j.suc.2015.08.002 surgical.theclinics.com
0039-6109/15/$ – see front matter Published by Elsevier Inc.

Table 1
Extraintestinal manifestations associated with inflammatory bowel disease

Musculoskeletal	Pauciarticular arthritis AS/axial arthropathies
Dermatologic	EN PG Apthous ulcers Sweets syndrome
Ocular	Uveitis Episcleritis
Hepatobiliary	PSC Cholelithiasis PVT
Pulmonary	Large and small airway disease Chronic bronchitis Bronchiectasis
Renal	Nephrolithiasis Obstructive uropathy Fistulization

has been demonstrated in patients with primary sclerosing cholangitis (PSC) wherein autoantibodies to the colon cross-react with the biliary epithelium.[2]

EIMs can be classified into 3 groups, based on the association with intestinal disease activity (**Box 1**).[1] The first group has a direct relationship with intestinal disease and parallels the disease process. These EIMs include episcleritis, erythema nodosum (EN), oral apthous ulcers, and pauciarticular arthritis.[3] The second group of EIMs seems to develop and progress independent from intestinal disease activity and may simply reflect the susceptibility of these patients to autoimmune disorders. This group includes ankylosing spondylitis (AS) and uveitis.[3] The third group consists of

Box 1
Association between inflammatory bowel disease and extraintestinal manifestations

Group I: EIMs that parallel disease activity of IBD

Oral aphthous ulcers

Erythema nodosum

Pauciarticular arthritis

Episcleritis

Group II: EIMs with independent course from IBD activity

Ankylosing spondylitis

Uveitis

Group III: EIMs and IBD activity unclear

Primary sclerosing cholangitis

Pyoderma gangrenosum

(*From* Trikudanathan G, Venkatesh PG, Navaneethan U. Diagnosis and therapeutic management of extra-intestinal manifestations of inflammatory bowel disease. Drugs 2012;72(18): 2333–49; with permission.)

EIMs that have an unclear relationship with intestinal inflammation. This group includes pyoderma gangrenosum (PG) and PSC, which may or may not be related to intestinal inflammation[3] (see **Box 1**).

MUSCULOSKELETAL MANIFESTATIONS

Musculoskeletal manifestations are the most common EIM seen in IBD and are present in 20% to 30% of patients.[4] Joint involvement can be classified as either peripheral or axial, and men and women appear to have a similar risk of developing joint involvement.[5]

Peripheral Arthropathies

Peripheral arthropathies (PA) are divided into 2 subgroups, according to the classification of Orchard and colleagues.[6] Type 1 (pauciarticular) arthritis is an acute, self-limiting arthropathy that typically affects fewer than 5 large joints. It occurs in approximately 5% to 10% of UC and 10% to 20% of CD patients, respectively.[6] Type 1 PA is unique from other forms of arthritis in that there is little to no joint destruction, and patients are serologically negative for rheumatoid factor and antinuclear antibody.[7] Thus, PA is a seronegative arthritis. The risk of developing peripheral arthritis increases with the extent of IBD activity. In addition, the presence of complications related to IBD activity, such as abscess, perianal disease, or other EIM, also appears to be associated with an increased risk of PA.[5]

In contrast, type 2 (polyarticular) arthritis is a chronic, often bilateral, symmetric, polyarticular arthropathy affecting 5 or more small joints. Often, type 2 arthritis flares occur independent from IBD activity, with a prevalence of 2% to 4% in both CD and UC.[8] It may persist before surgery for IBD or present years later after a total abdominal proctocolectomy with ileopouch anal anastomosis.[9] In addition, type 2 arthritis is associated with an increased risk of uveitis.[10]

The diagnosis of PA is made clinically, given that radiologic imaging fails to show any erosions or deformities. Treatment recommendations for IBD-related arthropathies are based on the treatment of other forms of arthritis/spondyloarthropathy.[11] Because type I PA is linked with IBD activity, treatment is aimed at addressing the underlying intestinal inflammation. Symptoms usually resolve within 8 to 10 weeks after successful treatment of an IBD flare.[12] Nonsteroidal anti-inflammatory drugs (NSAIDs) may be used, but with caution due to the risk of exacerbating the underlying IBD. Selective cyclo-oxygenase (COX)-2 inhibitors have been used with improvement in symptoms in up to 60% of patients; however, clinical relapse of IBD requiring discontinuation of therapy was seen within the first few days of treatment in 25% of patients.[13] Although a recent *Cochrane Review* failed to show an increased risk of IBD exacerbation with the use of COX-2 inhibitors, the investigators thought that due to the small sample size and short follow-up, no definitive conclusion could be made.[14] Thus, more trials with COX-2 inhibitors are needed to determine the safety and provide further recommendations for their use. Treatment of type 2 arthritis is different in that it does not simply mirror the underlying bowel activity. Sulfasalazine is the first-line treatment. However, methotrexate may be used when sulfasalazine is not effective and should be started at 7.5 mg weekly along with folic acid to decrease side effects.[5] In addition, biologic therapy may be used in those patients that continue to suffer from refractory disease. Kaufman and colleagues[15] demonstrated an improvement in symptoms of 7 of 11 arthralgia patients after a single dose of infliximab 5 mg/kg. However, this improvement in symptoms may be short lived. A randomized prospective study, which included 487 patients, confirmed that

infliximab therapy is a valid option for refractory disease, but concluded that this treatment must be weighed against the absence of clinical differences at 24 months and an increase in treatment cost.[16]

Axial Arthropathies

Axial arthropathies occur in 3% to 5% of patients with IBD, with men being affected more commonly than women.[17] Axial arthropathies are categorized into AS and sacroiliitis. Axial arthropathies do not parallel IBD activity. AS occurs in up to 10% of patients with IBD, which is 20-fold higher than the general population. Most patients are HLA-B27 positive. The disease course is usually progressive and often results in spinal destruction. Clinically, patients often experience severe back pain that is aggravated by periods of rest. On physical examination, there is limited spinal mobility and reduced chest expansion. Advanced cases are characterized by squaring of vertebral bodies, and bony proliferation and ankylosis, classically known as "bamboo spine." Although plain films may demonstrate abnormal findings, MRI is now the gold standard for diagnosis.[18] Management of IBD-related AS is similar to non-IBD patients. Physical therapy and exercise regimens, such as deep breathing, spinal exercises, and swimming, are essential to retain spine mobility and minimize disability.[19] NSAIDs may aid in symptom relief but they do not have an effect on underlying spinal destruction. Similarly, local corticosteroid injections may provide symptom improvement, but their effects are fleeting. Sulfasalazine, methotrexate, and azathioprine are generally ineffective in the treatment of AS. Biologic therapy, including both infliximab and adalimumab, has been well studied in several placebo-controlled trials in AS patients without IBD and have demonstrated efficacy.[20,21] In a controlled trial of 36 patients with both IBD and spondyloarthropathy, 24 patients were treated with infliximab versus 12 patients treated with steroids, azathioprine, antibiotics, and salicylates. The infliximab arm showed a rapid and continued improvement in disease activity with an improvement in the Bath Ankylosing Spondylitis Disease Activity Index at 1 year compared with the control group.[22]

Unlike AS, sacroiliitis is usually asymptomatic and non-progressive. Most patients with sacroiliitis are HLA-B27 negative and do not progress to AS.[1] Plain radiographs may show unilateral or bilateral sclerosis along with evidence of erosion. Unfortunately, patients with radiographic evidence of sacroiliitis are more likely to progress to AS.[5] MRI has a high sensitivity to detect sacroiliitis and is regarded as the gold standard.

DERMATOLOGIC MANIFESTATIONS

Skin manifestations are common EIMs associated with IBD. The 2 most recognized examples are EN and PG, although the incidence varies, widely affecting 3% to 20%, and 0.5% to 20% of patients, respectively.[17,23] At the time of diagnosis of IBD, up to 10% of patients may already be suffering from cutaneous manifestations.[24] The diagnosis of cutaneous EIM is often made based on clinical examination, specifically, the characteristic features associated with each manifestation.

Erythema Nodosum

EN has been reported to occur in up to 15% of patients with CD and 10% of patients with UC.[25] EN is classically described as raised, red, tender inflammatory nodules of 1 to 5 cm in diameter. The lesions are usually on the anterior, extensor surface of the lower extremities, but can affect the face and trunk.[25] The lesions usually heal without ulceration, and the prognosis is good.[26] EN flares often reflect underlying intestinal activity and improve with treatment of IBD. Histologically, EN demonstrates nonspecific

focal panniculitis and can develop anywhere subcutaneous fat is present; the anterior tibial area is the most common site. EN exacerbations have been associated with infections to include tuberculosis, coccidioidomycosis, histoplasmosis, blastomycosis, and sarcoidosis.[27–30] In addition, medications such as sulfonamides, iodides, bromides, and estrogens have been associated with EN.[26] Symptoms usually mimic intestinal activity; therefore, treatment is aimed at the underlying bowel disease. However, EN may precede intestinal activity and in these cases oral corticosteroids may be required for treatment.[26]

Pyoderma Gangrenosum

PG is a severe, debilitating EIM that is more commonly associated with UC than with CD.[31] Patients with more severe disease or colonic involvement are more likely to develop PG.[31] PG begins with discrete pustules than contain purulent material. These pustules are often sterile unless they become secondarily infected. They then evolve into deep evacuating ulcerations. The most common sites include the shins and peristomal skin, but can occur anywhere. Similar to EN, the diagnosis is made on clinical examination, but cultures and biopsy may be taken to exclude other diagnoses. Histologic examination generally reveals diffuse neutrophilic infiltration and dermolysis. PG lesions are usually preceded by trauma through a phenomenon known as pathergy. Because of this, aggressive surgical debridement is strongly discouraged. Local wound care should follow the tenets of common ulcer treatment and consists of topical compresses, enzymatic ointments, and clean dressings. Peristomal PG is especially problematic given the difficulties with appliance application (**Fig. 1**). Unfortunately, PG often recurs at the area of a new stoma; therefore, stomal relocation is often reserved as a last resort after all other measures have been exhausted.[32] Management of PG is usually begun with high-dose prednisone with tapering or intralesional injections. Funayama and colleagues[33] found that patients with peristomal PG treated with early systemic prednisone, a dose 20 mg to 40 mg, was affective in healing the ulcerations. In more severe cases, cyclosporine or tacrolimus may be effective. Topical tacrolimus has also emerged as a treatment option.[34] Compared with the numerous TNF inhibitor-joint disease trials, very few rigorous studies have been performed to investigate the effectiveness of adalimumab and infliximab for cutaneous EIM associated with IBD. However, there is evidence to support the use of biologic therapy. Brooklyn and colleagues[35] performed a multicenter, randomized, placebo-controlled trial of 30 patients with PG, 19 of which had IBD. Patients were given infliximab 5 mg/kg or placebo infusions at week 0 and were evaluated for response. At week 2, subjects in both arms were offered open-label infliximab 5 mg/kg. Two weeks after the initial infusion, 6 of 13 (46%) patients treated with infliximab had a response compared with 1 of 17 (6%) in the control group ($P = .025$). Most patients (69%) who received open-label infusions of infliximab had a positive response by week 6. There was no difference in response between patients with underlying IBD compared with non-IBD patients.

Aphthous Ulcers

Oral apthous ulcers occur in approximately 10% of patients with UC and 20% to 30% of patients with CD. Ulcers tend to rapidly resolve once remission is achieved in patients with active CD. Ulcer patients with other EIMs are more likely to develop recurrent episodes. Treatment consists of addressing the underlying bowel disease, but symptomatic relief may be achieved with the use of 2% viscous lidocaine along with 0.1% triamcinolone topically.[36]

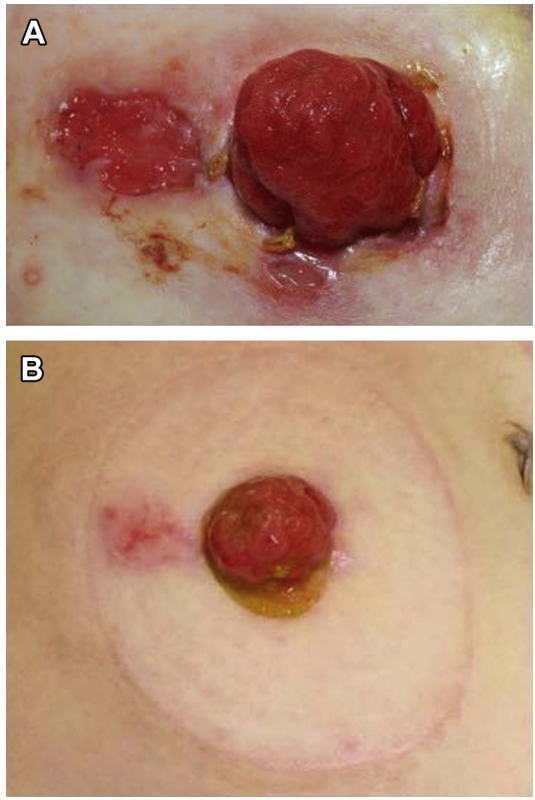

Fig. 1. Peristomal PG (*A*) before and (*B*) after treatment. (*From* Poritz LS, Lebo MA, Bobb AD, et al. Management of peristomal pyoderma gangrenosum. J Am Coll Surg 2008;206(2):313; with permission.)

Sweet Syndrome

Sweet syndrome is a rare EIM that is best described as a neutrophilic dermatosis characterized by painful erythematous plaques or nodules on the face, neck, and extremities. It is often accompanied by fever and leukocytosis.[37] It has been suggested that Sweet syndrome may be part of the spectrum of diseases related to PG.[38] Sweet syndrome is more common in women (87%) and in patients with colonic involvement (100%).[9] Patients usually respond well to corticosteroids, and there are some case reports demonstrating success with biologic therapy.[37,39,40]

Other cutaneous manifestations have been associated with IBD. Acrodermatitis enteropathica is a rare skin disorder that manifests as psoriasiform erythema with vesicles, pustules, and crusts around orifices (perioral, perigenital, perianal) or on extensor surfaces. It is often associated with zinc-deficient diets and malabsorption.[38] In addition, psoriasis has been observed in patients suffering from IBD. Psoriasis occurs in about 1% to 2% of the population, but affects 7% to 11% of patients with IBD. There is no correlation between the course of psoriasis and the activity of intestinal disease.[24]

OCULAR MANIFESTATIONS

Ocular complications are involved in 4% to 10% of IBD patients,[41] which include scleritis, episcleritis, and uveitis. Most patients will already carry the diagnosis of

IBD when they develop ocular symptoms, but a minority of patients will manifest symptoms before the diagnosis of IBD.[42] The ophthalmic complications are usually of inflammatory origin; however, some of these complications may reflect overall disease activity.[25,43]

Episcleritis and Scleritis

Episcleritis is defined as painless hyperemia of the conjunctiva and sclera with no visual deficits (**Fig. 2**). Episcleritis may be unilateral or bilateral and is more common in women.[43] Episcleritis usually mirrors acute flares of IBD, with resolution of symptoms following the use of anti-inflammatory medications. Scleritis is a chronic, painful, and potentially blinding inflammatory process characterized by edema and cellular infiltration of the scleral tissues. It is often classified into anterior and posterior. The initial therapy consists of NSAIDs, followed by corticosteroids if needed.[44,45] In cases refractory to therapy, methotrexate or cyclosporine may be helpful.

Uveitis

Uveitis is the most commonly diagnosed ocular manifestation of IBD. Uveitis is an acute painful condition with associated blurred vision and photophobia. Uveitis may look very similar to episcleritis on gross examination. However, this is a serious condition that must be treated immediately with corticosteroids, because it can progress to blindness if left untreated. Similar to PG, uveitis flares may not be associated exacerbation of IBD or be an indicator of active disease. In addition, uveitis refractory to steroids has been successfully treated with cyclosporine A.[46]

Biologic therapy has shown promising results in treating ocular EIM associated with IBD. Infliximab seems to be effective for acute and chronic uveitis, specifically for patients with ocular disease refractory to other immunosuppressants.[47] Currently, there are more than 65 publications on the use of infliximab for uveitis patients.[48] Suhler and colleagues[49] performed a prospective trial investigating the use of infliximab for the treatment of refractory autoimmune uveitis. In 23 cases of uveitis given a loading dose regimen of infliximab, 18 patients had responded to treatment within 10 weeks based on a composite clinical assessment. In addition, 7 of 14 patients who went on to receive infliximab for 1 year continued to benefit from therapy. In another study, Kahn and colleagues[50] observed that 17 children with refractory uveitis had favorable responses to infliximab, with 13 of the 17 patients having no ocular inflammation after only 2 infusions.

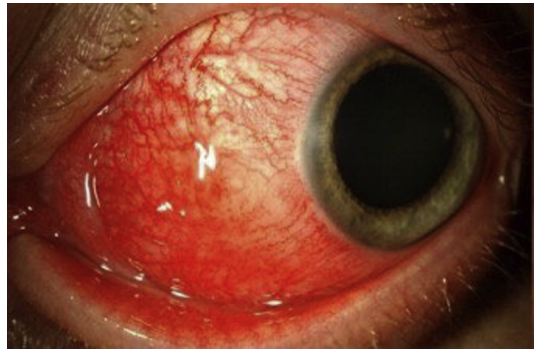

Fig. 2. Slit-lamp view of left eye shows nodular episcleritis. (*From* Hegde V, Mitrut I, Bennett H, et al. Episcleritis: an association with IgA nephropathy. Cont Lens Anterior Eye 2009;32(3):141; with permission.)

HEPATOBILIARY MANIFESTATIONS

Hepatobiliary manifestations are common among patients with IBD. Although PSC is the most recognized, others include cholelithiasis, portal vein thrombosis (PVT), drug-induced hepatotoxicity, and acute and chronic idiopathic pancreatitis.

Primary Sclerosing Cholangitis

PSC is the most recognized biliary EIM of IBD, with a prevalence of 1.4% to 7%.[51] PSC is a chronic, progressive, nonreversible cholestatic disorder that results in fibrosis of the biliary system. Clinical symptoms include fatigue, pruritus, jaundice, abdominal pain, and weight loss. PSC is characterized by progressive inflammation, destruction of the intrahepatic, extrahepatic, or both resulting in obliterative fibrosis.[52] These pathologic changes lead to biliary cirrhosis and in some cases hepatic failure.[53] The pathogenesis of PSC is unclear, but multiple genetic factors associated with susceptibility have been reported.[54] Autoantibodies and bacterial translocation have been hypothesized to be related to PSC in IBD patients; however, these theories have been challenged by recent studies.[55–58]

The prevalence of PSC ranges from 2% to 7.5% in patients with UC and from 1.4% to 3.4% in patients with CD.[59–61] In patients with PSC-IBD, 85% to 90% have UC and the remaining patients have Crohn colitis or Crohn ileocolitis.[62]

The development of cholestasis in any IBD patient should prompt an evaluation for PSC. Jaundice may arise at any time due to biliary strictures. Laboratory abnormalities show an elevated alkaline phosphatase level, whereas aspartate aminotransferase and alanine aminotransferase levels are typically normal. Albumin and prothrombin times are typically normal until the development of cirrhosis. Approximately 33% of patients have an elevated antinuclear antibody level, and 80% will have a positive antineutrophil cytoplasmic antibody level.[63,64] Visualization of the biliary tree is essential to confirm the diagnosis of PSC. The typical findings include multifocal strictures of both the intrabiliary and the extrabiliary system, which results in the classic "bead-on-a-string" pattern (**Fig. 3**). Magnetic resonance cholangiopancreatography is the initial imaging study of choice, with endoscopic retrograde cholangiopancreatography being reserved for those patients that require stenting or biopsy of lesions that are concerning for malignancy due to the risk of cholangitis with instrumentation.[5]

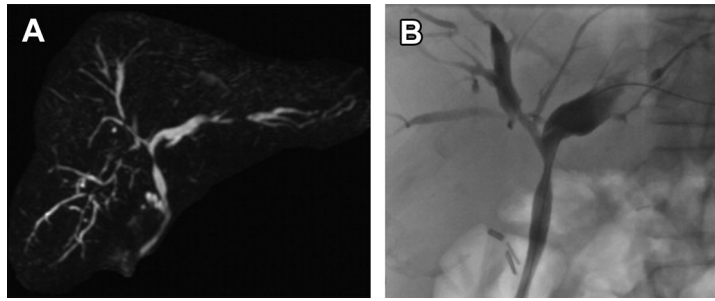

Fig. 3. Typical cholangiographic findings of PSC. (*A*) Magnetic resonance cholangiopancreatography shows multiple strictures and dilatations of the biliary tree, affecting the intrahepatic and extrahepatic biliary tree. (*B*) Endoscopic retrograde cholangiopancreatography with typical findings of pruning and beaded appearance of the biliary tree. (*From* Singh S, Talwalkar JA. Primary sclerosing cholangitis: diagnosis, prognosis, and management. Clin Gastroenterol Hepatol 2013;11(8):899; with permission.)

PSC-IBD patients appear to have a unique form of IBD. UC associated with PSC has a higher prevalence of rectal sparing, backwash ileitis, and colorectal neoplasia.[65] In addition, new onset PSC may be diagnosed years after UC diagnosis with or without proctocolectomy.[5] PSC-IBD patients often have a more quiescent course of colitis than UC patients without PSC.[5]

The presence of PSC is associated with an increased risk for UC-associated dysplasia.[66] This risk continues even after orthotopic liver transplant.[67] Because of this increased risk, it is recommended that patients with PSC-IBD receive annual surveillance colonoscopy once the PSC diagnosis is made,[68] and this surveillance program has been shown to have a survival advantage.[69] In addition, PSC patients have a higher prevalence of cholangiocarcinoma with an annual incidence of 0.6% to 1%.[70] Cholangiocarcinoma may present as an intraductal mass or liver lesion.[71] Although it is clear that PSC is a risk factor for cholangiocarcinoma, it is less clear if there is a link to IBD.

Currently, no medical therapies have been effective at preventing the progression of PSC. Ursodeoxycholic acid (UDCA) has been extensively studied, and the utility of this drug for the treatment of PSC is unclear. In addition, although initially thought to decrease the risk of colorectal neoplasia associated with IBD,[72] UDCA may actually increase that risk.[73] Endoscopic intervention is often needed in patients with progressive disease, increasing jaundice, cholangitis, or suspicion of cholangiocarcinoma. Endoscopic treatments with balloon dilation of strictures and stent placement are required for strictures.[74]

Cholelithiasis

Cholelithiasis is common in IBD patients, specifically in CD patients with ileal disease. Abnormal bile salt absorption and metabolism may result in an increased incidence of gallstone formation in CD patients, ranging from 13% to 38%. Recent studies demonstrated that CD patients have an increased level of both conjugated and unconjugated bilirubin in bile and that an increased enterohepatic circulation of bilirubin was a contributing factor for cholelithiasis formation.[75,76] In addition, CD patients have a decreased gallbladder motility; therefore, the development of cholelithiasis seems to be multifactorial.[77–79]

Portal Vein Thrombosis

PVT is a rare complication in the nonsurgical setting that has been association with coagulation abnormalities; however, the incidence seems to be higher in IBD compared with the general population.[80] It also occurs more frequently in IBD patients with recent abdominal surgery.[80] Venkatesh and colleagues[81] demonstrated that the incidence of PVT in IBD patients was higher (odds ratio [OR] 1.7; 95% confidence interval [CI] 1.01–2.8), which persisted after being adjusted for hypercoagulable disorders. Younger patients (18–39 years) and women had the highest risk compared with control (OR 4.1; 95% CI 1.87–8.9) and (OR 10.9; 95% CI 4.62–25.7).[82]

RENAL

EIM of IBD associated with the renal collecting system includes nephrolithiasis, obstructive uropathy, and fistulization of the urinary tract.[83] Such symptoms may occur in 4% to 23% of IBD patients.[84] Nephrolithiasis, which is more prevalent in CD than UC, is primarily composed of calcium oxalate and urate crystals. Ileocolonic resection in patients with CD and colectomy in UC patients may accelerate the formation of oxalate stones.[84] Another renal EIM associated with IBD is a rare condition

known as secondary amyloidosis. Patients may present with proteinuria, renal failure, and uremia. This condition more commonly affects men and CD patients with a 3-fold and 10-fold increased risk, respectively.[85] The diagnosis is made via liver, rectal, or renal biopsy, because this is a systemic disease. Treatment is aimed at the systemic nature of the disease; although biologic therapy has some proven benefit, some patients may progress to requiring renal transplantation.[86]

PULMONARY

IBD patients commonly suffer from subclinical EIM involving the pulmonary system.[87] The spectrum of respiratory manifestations reported includes both small and large airway disease. Specifically, conditions include chronic bronchitis, subglottic stenosis, bronchiectasis, and bronchiolitis.[88,89] It is important to mention that pulmonary symptoms in IBD patients may be secondary to the treatment of the underlying intestinal disease. Although drug-related conditions are not normally considered EIM of IBD, it is important to remember that nearly all of the proposed treatments for IBD may have some pulmonary side effects.[90] Pulmonary manifestations can occur in nonsmokers, and in general, follow the onset of bowel disease, but in rare cases may precede the onset of intestinal symptoms.[91] Bronchoalveolar lavage demonstrates alveolitis in up to 50% of CD patients without pulmonary symptoms, and pulmonary function testing is abnormal in up to 42% of asymptomatic patients.[87] Lung biopsy often shows nonspecific inflammation, small airway fibrosis, and occasionally, granulomatous bronchiolitis.[5] IBD-related pulmonary disease is difficult to manage and is treated similarly to non-IBD patients for the specific conditions. Improvement following oral steroid therapy may be slight to modest, and lung transplantation may be required for extreme cases.

SUMMARY

IBD affects multiple organ systems outside of the gastrointestinal tract. The clinician treating patients with IBD should be acutely aware of the diagnosis and treatment of EIM in order to decrease morbidity. The management can be difficult and often times requires a multidisciplinary approach. Future research investigating the pathophysiology, diagnosis, and treatment is needed to further the care of these patients.

REFERENCES

1. Trikudanathan G, Venkatesh PGK, Navaneethan U. Diagnosis and therapeutic management of extra-intestinal manifestations of inflammatory bowel disease. Drugs 2012;72(18):2333–49.
2. Chapman RW, Cottone M, Selby WS, et al. Serum autoantibodies, ulcerative colitis and primary sclerosing cholangitis. Gut 1986;27(1):86–91.
3. Loftus EV Jr. Management of extraintestinal manifestations and other complications of inflammatory bowel disease. Curr Gastroenterol Rep 2004;6(6):506–13.
4. Bernstein CN, Wajda A, Blanchard JF. The clustering of other chronic inflammatory diseases in inflammatory bowel disease: a population-based study. Gastroenterology 2005;129(3):827–36.
5. Rothfuss KS, Stange EF. Extraintestinal manifestations and complications in inflammatory bowel diseases. World J Gastroenterol 2006;12(30):4819–31.
6. Orchard TR, Wordsworth BP, Jewell DP. Peripheral arthropathies in inflammatory bowel disease: their articular distribution and natural history. Gut 1998;42(3):387–91.

7. Schorr-Lesnick B, Brandt LJ. Selected rheumatologic and dermatologic manifestations of inflammatory bowel disease. Am J Gastroenterol 1988;83(3):216–23.
8. Lakatos PL, Lakatos L, Kiss LS, et al. Treatment of extraintestinal manifestations in inflammatory bowel disease. Digestion 2011;86(Suppl 1):28–35.
9. Ardizzone S, Puttini PS, Cassinotti A. Extraintestinal manifestations of inflammatory bowel disease. Dig Liver Dis 2008;40(Suppl 2):S253–9.
10. Williams H, Walker D, Orchard TR. Extraintestinal manifestations of inflammatory bowel disease. Curr Gastroenterol Rep 2008;10(6):597–605.
11. Juillerat P, Mottet C, Pittet V, et al. Extraintestinal manifestations of Crohn's disease. Digestion 2005;71:31–6.
12. Scarpa R, Puente AD, D'arienzo A. The arthritis of ulcerative colitis: clinical and genetic aspects. J Rheumatol 1992;19(3):373–7.
13. Reinisch W, Miehsler W, Dejaco C. An open-label trial of the selective cyclooxygenase-2 inhibitor, rofecoxib, in inflammatory bowel disease-associated peripheral arthritis and arthralgia. Aliment Pharmacol Ther 2003;17(11):1371–80.
14. Miao XP, Li JS, Ouyang Q, et al. Tolerability of selective cyclooxygenase 2 inhibitors used for the treatment of rheumatological manifestations of inflammatory bowel disease. Cochrane Database Syst Rev 2014;(10):CD007744.
15. Kaufman I, Caspi D, Yeshurun D, et al. The effect of infliximab on extraintestinal manifestations of Crohn's disease. Rheumatol Int 2005;25(6):406–10.
16. Vollenhoven RFV, Geborek P, Forslind K. Conventional combination treatment versus biological treatment in methotrexate-refractory early rheumatoid arthritis: 2 year follow-up of the randomised, non-blinded, parallel-group Swefot trial. Lancet 2012;379(9827):1712–20.
17. Su CG, Judge TA, Lichtenstein GR. Extraintestinal manifestations of inflammatory bowel disease. Gastroenterol Clin North Am 2002;31(1):307–27.
18. Braun J, Heijde DVD. Imaging and scoring in ankylosing spondylitis. Best Pract Res Clin Rheumatol 2002;16(4):573–604.
19. Dignass A, Assche GV, Lindsay JO. The second European evidence-based consensus on the diagnosis and management of Crohn's disease: current management. J Crohns Colitis 2010;4(1):28–62.
20. Rosman Z, Shoenfeld Y, Zandman-Goddard G. Biologic therapy for autoimmune diseases: an update. BMC Med 2013;11:88.
21. Zochling J, Heijde DVD, Dougados M. Current evidence for the management of ankylosing spondylitis: a systematic literature review for the ASAS/EULAR management recommendations in ankylosing spondylitis. Ann Rheum Dis 2006;65(4):423–32.
22. Generini S, Giacomelli R, Fedi R, et al. Infliximab in spondyloarthropathy associated with Crohn's disease: an open study on the efficacy of inducing and maintaining remission of musculoskeletal and gut manifestations. Ann Rheum Dis 2004;63(12):1664–9.
23. Bodegraven AAV, Peña AS. Treatment of extraintestinal manifestations in inflammatory bowel disease. Curr Treat Options Gastroenterol 2003;6(3):201–12.
24. Veloso FT. Skin complications associated with inflammatory bowel disease. Aliment Pharmacol Ther 2004;20(Suppl 4):50–3.
25. Greenstein AJ, Janowitz HD, Sachar DB. The extra-intestinal complications of Crohn's disease and ulcerative colitis: a study of 700 patients. Medicine (Baltimore) 1976;55(5):401–12.
26. Levine JS, Burakoff R. Extraintestinal manifestations of inflammatory bowel disease. Gastroenterol Hepatol 2011;7(4):235–41.

27. Saslaw S, Beman FM. Erythema nodosum as a manifestation of histoplasmosis. J Am Med Assoc 1959;170(10):1178–9.
28. Löfgren S, Wahlgren F. On the histo-pathology of erythema nodosum. Acta Derm Venereol 1949;29:1–13.
29. Hannuksela M. Erythema nodosum. Clin Dermatol 1986;4(4):88–95.
30. Soderstrom RM, Krull EA. Erythema nodosum. A review. Cutis 1978;21(6): 806–10.
31. Orchard TR, Chua CN, Ahmad T, et al. Uveitis and erythema nodosum in inflammatory bowel disease: clinical features and the role of HLA genes. Gastroenterology 2002;123(3):714–8.
32. Kiran RP, O'Brien-Ermlich B, Achkar JP. Management of peristomal pyoderma gangrenosum. Dis Colon Rectum 2005;48(7):1397–403.
33. Funayama Y, Kumagai E, Takahashi K. Early diagnosis and early corticosteroid administration improves healing of peristomal pyoderma gangrenosum in inflammatory bowel disease. Dis Colon Rectum 2009;52(2):311–4.
34. Chiba T, Isomura I, Suzuki A. Topical tacrolimus therapy for pyoderma gangrenosum. J Dermatol 2005;32(3):199–203.
35. Brooklyn TN, Dunnill MGS, Shetty A, et al. Infliximab for the treatment of pyoderma gangrenosum: a randomised, double blind, placebo controlled trial. Gut 2006;55(4):505–9.
36. Larsen S, Bendtzen K, Nielsen OH. Extraintestinal manifestations of inflammatory bowel disease: epidemiology, diagnosis, and management. Ann Med 2010;42(2): 97–114.
37. Kemmett D, Hunter JAA. Sweet's syndrome: a clinicopathologic review of twenty-nine cases. J Am Acad Dermatol 1990;23(3 Pt 1):503–7.
38. Ochsendorf FR. Cutaneous manifestations of IBD and IBD-associated inflammatory lesions. 1998. Falk symposium Titisee. Germany, May 25–26, 1997.
39. Rochet NM, Chavan RN, Cappel MA, et al. Sweet syndrome: clinical presentation, associations, and response to treatment in 77 patients. J Am Acad Dermatol 2013;69(4):557–64.
40. Foster EN, Nguyen KK, Sheikh RA. Crohn's disease associated with Sweet's syndrome and Sjögren's syndrome treated with infliximab. Clin Dev Immunol 2005; 12(2):145–9.
41. Knox DL, Schachat AP, Mustonen E. Primary, secondary and coincidental ocular complications of Crohn's disease. Ophthalmology 1984;91(2):163–73.
42. Soukiasian SH, Foster CS, Raizman MB. Treatment strategies for scleritis and uveitis associated with inflammatory bowel disease. Am J Ophthalmol 1994; 118(5):601–11.
43. Hopkins DJ, Horan E, Burton IL, et al. Ocular disorders in a series of 332 patients with Crohn's disease. Br J Ophthalmol 1974;58(8):732–7.
44. Galor A, Jabs DA, Leder HA, et al. Comparison of antimetabolite drugs as corticosteroid-sparing therapy for noninfectious ocular inflammation. Ophthalmology 2008;115(10):1826–32.
45. Sobrin L, Christen W, Foster CS. Mycophenolate mofetil after methotrexate failure or intolerance in the treatment of scleritis and uveitis. Ophthalmology 2008; 115(8):1416–21, 1421.e1.
46. Barrie A, Regueiro M. Biologic therapy in the management of extraintestinal manifestations of inflammatory bowel disease. Inflamm Bowel Dis 2007;13(11): 1424–9.
47. Hale S, Lightman S. Anti-TNF therapies in the management of acute and chronic uveitis. Cytokine 2006;33(4):231–7.

48. Schwartzman S, Schwartzman M. The use of biologic therapies in uveitis. Clin Rev Allergy Immunol 2014. [Epub ahead of print].
49. Suhler EB, Smith JR, Wertheim MS. A prospective trial of infliximab therapy for refractory uveitis: preliminary safety and efficacy outcomes. Arch Ophthalmol 2005;123(7):903–12.
50. Kahn P, Weiss M, Imundo LF, et al. Favorable response to high-dose infliximab for refractory childhood uveitis. Ophthalmology 2006;113(5):860–4.e2.
51. Fausa O, Schrumpf E, Elgjo K. Relationship of inflammatory bowel disease and primary sclerosing cholangitis. Semin Liver Dis 1991;11(1):31–9.
52. Chapman RW, Arborgh BA, Rhodes JM. Primary sclerosing cholangitis: a review of its clinical features, cholangiography, and hepatic histology. Gut 1980;21(10): 870–7.
53. Lee YM, Kaplan MM. Primary sclerosing cholangitis. N Engl J Med 1995;332(14): 924–33.
54. Farrant JM, Doherty DG, Donaldson PT. Amino acid substitutions at position 38 of the DRβ polypeptide confer susceptibility to and protection from primary sclerosing cholangitis. Hepatology 1992;16(2):390–5.
55. O'Mahony CA, Vierling JM. Etiopathogenesis of primary sclerosing cholangitis. Semin Liver Dis 2006;26(1):3–21.
56. Worthington J, Cullen S, Chapman R. Immunopathogenesis of primary sclerosing cholangitis. Clin Rev Allergy Immunol 2005;28(2):93–103.
57. Hatano H, Nakajima Y, Sugita S. Experimental portal fibrosis produced by intraportal injection of killed nonpathogenic Escherichia coli in rabbits. Gastroenterology 1988;94(3):787–96.
58. Björnsson ES, Kilander AF, Olsson RG. Bile duct bacterial isolates in primary sclerosing cholangitis and certain other forms of cholestasis–a study of bile cultures from ERCP. Hepatogastroenterology 2000;47(36):1504–8.
59. Schrumpf E, Elgjo K, Fausa O, et al. Sclerosing cholangitis in ulcerative colitis. Scand J Gastroenterol 1980;15(6):689–97.
60. Shepherd HA, Selby WS, Chapman RWG, et al. Ulcerative colitis and persistent liver dysfunction. Q J Med 1983;52(208):503–13.
61. Rasmussen HH, Fallingborg JF. Hepatobiliary dysfunction and primary sclerosing cholangitis in patients with Crohn's disease. Scand J Gastroenterol 1997;32(6): 604–10.
62. Olsson R, Danielsson A, Jarnerot G, et al. Prevalence of primary sclerosing cholangitis in patients with ulcerative colitis. Gastroenterology 1991;100(5 Pt 1):1319–23.
63. Mulder AH, Horst G, Haagsma EB, et al. Prevalence and characterization of neutrophil cytoplasmic antibodies in autoimmune liver diseases. Hepatology 1993;17(3):411–7.
64. Bansi DS, Fleming KA, Chapman RW. Importance of antineutrophil cytoplasmic antibodies in primary sclerosing cholangitis and ulcerative colitis: prevalence, titre, and IgG subclass. Gut 1996;38(3):384–9.
65. Vries BAD, Janse M, Blokzijl H, et al. Distinctive inflammatory bowel disease phenotype in primary sclerosing cholangitis. World J Gastroenterol 2015;21(6): 1956–71.
66. Soetikno RM, Lin OS, Heidenreich PA. Increased risk of colorectal neoplasia in patients with primary sclerosing cholangitis and ulcerative colitis: a meta-analysis. Gastrointest Endosc 2002;56(1):48–54.
67. Bleday R, Lee E, Jessurun J, et al. Increased risk of early colorectal neoplasms after hepatic transplant in patients with inflammatory bowel disease. Dis Colon Rectum 1993;36(10):908–12.

68. Kornbluth A, Sachar DB. Ulcerative colitis practice guidelines in adults. American College of Gastroenterology, Practice Parameters Committee. Am J Gastroenterol 1997;92(2):204–11.
69. Rutter MD, Saunders BP, Wilkinson KH, et al. Cancer surveillance in longstanding ulcerative colitis: endoscopic appearances help predict cancer risk. Gut 2004; 53(12):1813–6.
70. Bergquist A, Ekbom A, Olsson R, et al. Hepatic and extrahepatic malignancies in primary sclerosing cholangitis. J Hepatol 2002;36(3):321–7.
71. Fevery J, Verslype C, Lai G, et al. Incidence, diagnosis, and therapy of cholangiocarcinoma in patients with primary sclerosing cholangitis. Dig Dis Sci 2007; 52(11):3123–35.
72. Pardi DS, Loftus EV, Kremers WK, et al. Ursodeoxycholic acid as a chemopreventive agent in patients with ulcerative colitis and primary sclerosing cholangitis. Gastroenterology 2003;124(4):889–93.
73. Eaton JE, Silveira MG, Pardi DS, et al. High-dose ursodeoxycholic acid is associated with the development of colorectal neoplasia in patients with ulcerative colitis and primary sclerosing cholangitis. Am J Gastroenterol 2011;106(9): 1638–45.
74. Baluyut AR, Sherman S, Lehman GA, et al. Impact of endoscopic therapy on the survival of patients with primary sclerosing cholangitis. Gastrointest Endosc 2001;53(3):308–12.
75. Brink MA, Slors JFM, Keulemans YCA, et al. Enterohepatic cycling of bilirubin: a putative mechanism for pigment gallstone formation in ileal Crohn's disease. Gastroenterology 1999;116(6):1420–7.
76. Parente F, Pastore L, Bargiggia S, et al. Incidence and risk factors for gallstones in patients with inflammatory bowel disease: a large case-control study. Hepatology 2007;45(5):1267–74.
77. Damiao A, Sipahi AM, Vezozzo DP, et al. Gallbladder hypokinesia in Crohn's disease. Digestion 1997;58(5):458–63.
78. Annese V, Vantrappen G. Gall stones in Crohn's disease: another hypothesis. Gut 1994;35(11):1676.
79. Pitt HA, King W, Mann LL, et al. Increased risk of cholelithiasis with prolonged total parenteral nutrition. Am J Surg 1983;145(1):106–12.
80. Jackson LM, O'Gorman PJ, O'connell J. Thrombosis in inflammatory bowel disease: clinical setting, procoagulant profile and factor V Leiden. QJM 1997; 90(3):183–8.
81. Venkatesh PGK, Navaneethan U, Shen B. Hepatobiliary disorders and complications of inflammatory bowel disease. J Dig Dis 2011;12(4):245–56.
82. Sridhar ARM, Parasa S, Navaneethan U. Comprehensive study of cardiovascular morbidity in hospitalized inflammatory bowel disease patients. J Crohns Colitis 2011;5(4):287–94.
83. Banner MP. Genitourinary complications of inflammatory bowel disease. Radiol Clin North Am 1987;25(1):199–209.
84. McConnell N, Campbell S, Gillanders I. Risk factors for developing renal stones in inflammatory bowel disease. BJU Int 2002;89(9):835–41.
85. Wester AL, Vatn MH, Fausa O. Secondary amyloidosis in inflammatory bowel disease: a study of 18 patients admitted to Rikshospitalet University Hospital, Oslo, from 1962 to 1998. Inflamm Bowel Dis 2001;7(4):295–300.
86. Kuroda T, Tanabe N, Kobayashi D, et al. Treatment with biologic agents improves the prognosis of patients with rheumatoid arthritis and amyloidosis. J Rheumatol 2012;39(7):1348–54.

87. Herrlinger KR, Noftz MK, Dalhoff K, et al. Alterations in pulmonary function in inflammatory bowel disease are frequent and persist during remission. Am J Gastroenterol 2002;97(2):377–81.
88. Camus PH, Colby TV. The lung in inflammatory bowel disease. Eur Respir J 2000; 15(1):5–10.
89. Spira A, Grossman R, Balter M. Large airway disease associated with inflammatory bowel disease. Chest 1998;113(6):1723–6.
90. Casella G, Villanacci V, Bella CD, et al. Pulmonary diseases associated with inflammatory bowel diseases. J Crohns Colitis 2010;4(4):384–9.
91. Kelly MG, Frizelle FA, Thornley PT, et al. Inflammatory bowel disease and the lung: is there a link between surgery and bronchiectasis? Int J Colorectal Dis 2006;21(8):754–7.