ORIGINAL ARTICLE

Sentinel Lymph Node Detection in Breast Cancer Patients by Real-Time Virtual Sonography Constructed With Three-Dimensional Computed Tomography-Lymphography

Shigeru Yamamoto, MD,* Noriko Maeda, MD,* Michiko Tamesa, MD,* Yukiko Nagashima, MD,* Kazuyoshi Suga, MD,† and Masaaki Oka, MD*

**Department of Digestive Surgery and Surgical Oncology (Department of Surgery II), Yamaguchi University Graduate School of Medicine, Yamaguchi, Japan; and †Department of Radiology, Yamaguchi University Graduate School of Medicine, Yamaguchi, Japan*

■ **Abstract:** Ultrasonography (US) is one tool for preoperative diagnosis of lymph node metastases in breast cancer. However, US cannot detect true sentinel lymph nodes (SLNs). We identified SLNs in 60 clinically node-negative breast cancer patients using a real-time virtual sonography (RVS) system to display in real time a virtual multi-planar reconstruction obtained from computed tomography (CT) volume data corresponding to the same cross-sectional image from US. CT volume data were obtained from our original three-dimensional CT lymphography (3DCT-LG), which accurately detects SLNs in breast cancer. SLN metastases were assessed by shape and visibility of the hilum. All patients underwent SLN biopsy and SLN metastases were examined pathologically. In all 60 patients, we were able to detect the same SLNs visualized by 3DCT-LG. Suspicious SLN metastases were identified in seven of the 60 patients, and four of seven patients were pathologically positive. Positive predictive value was 57%. The remaining 53 patients displayed non-suspect SLNs in which absence of metastasis from the SLN was confirmed histologically. Overall accuracy was 95%. This is a first attempt at preoperatively identifying SLNs using US guided by the RVS system in breast cancer patients. Although evaluation of SLN metastases was unsatisfactory, this method may be useful for preoperative fine-needle aspiration cytology for diagnosis of SLN metastases. ■

Key Words: breast cancer, computed tomography, lymphography, real-time virtual sonography, sentinel lymph node

To determine lymph node status and reduce postoperative complications in patients with breast cancer, sentinel lymph node (SLN) biopsy (SLNB) is used as an alternative to axillary lymph node dissection (ALND) (1,2). Breast cancer patients with SLN metastases are usually advised to undergo complete ALND (3). This can sometimes be accomplished at the time of operative SLNB if a frozen section or other intraoperative technique identifies metastasis and the patient has consented to this process (4–13).

Preoperative diagnosis of SLN metastases would be preferable to intraoperative identification of metastasis to the SLN. The patient and surgeon could then more adequately plan and discuss ALND. Efforts to preoperatively diagnose SLN metastasis have included clinical examinations, scans (positron emission tomography, computed tomography (CT) or magnetic resonance imaging) (14–16), mammography with extended axillary views, ipsilateral axillary US, or axillary US with fine needle aspiration (FNA) (10,13,17–21). None of these techniques has yet produced sufficient accuracy to supersede SLNB, although positive FNA from a morphologically abnormal node has proven useful in some cases.

The sensitivity of axillary US without FNA cytology is reportedly relatively poor when current radiological criteria are used to assess suspicious lymph node morphology. Many lymph nodes that look normal actually harbor metastases, while those that look abnormal may be free of metastases. FNA of abnormal-looking nodes only would be likely to miss a proportion of

Address correspondence and reprint requests to: Shigeru Yamamoto, MD, Department of Digestive Surgery and Surgical Oncology (Department of Surgery II), Yamaguchi University Graduate School of Medicine, 1-1-1 Minamikogushi, Ube, Yamaguchi 755-8505, Japan, or e-mail; syamamo@yamaguchi-u.ac.jp.

DOI: 10.1111/j.1524-4741.2009.00829.x

© 2009 Wiley Periodicals, Inc., 1075-122X/09

pathologically positive nodes that seem morphologically normal on US. Most SLNs are found intraoperatively within a fairly narrow transverse plane close to the lowest axillary hair follicles (22). US of this same anatomic region offers a higher probability of identifying the correct SLN. However, since US examination of SLN according to anatomical position cannot detect true SLNs, a new method to detect true SLNs by US is required to improve sensitivity to SLN metastases.

We recently developed a new technique for detecting SLNs by interstitial multidetector-row CT lymphography (CT-LG) using iopamidol, a widely available water-soluble nonionic monometric contrast agent (23–25). Clinical studies have shown the potential value of this technique for SLNB navigation in patients with breast cancer, and high-quality topographic volume-rendering three-dimensional (3D) imaging has been introduced to facilitate accurate identification of the anatomy of lymphatic pathways and primary SLNs. When we performed SLNB by both 3DCT-LG and the dye method, SLN detection rate was 100% (24,25).

An image-processing workstation can produce any multiplanar reconstruction (MPR) image from multidetector-row helical CT. A real-time virtual sonography (RVS) system (26,27) was recently developed that shows in real time the virtual MPR image corresponding to the image from US. The RVS system has been described as a novel and effective navigation tool for use in percutaneous radiofrequency ablation of hepatocellular carcinoma. We have therefore applied RVS conducted with 3DCT-LG to preoperative detection of SLNs in breast cancer patients.

The present study examined the significance of US guided by the RVS system displaying virtual MPR images obtained from 3DCT-LG for preoperative detection of SLN and then evaluated SLN metastasis.

PATIENTS AND METHODS

We preoperatively examined SLNs in 60 consecutive breast cancer patients with the RVS system and interstitial CT-LG (60 females; T1, $n = 36$; T2, $n = 24$; age, 35–85 years; mean age, 56 years). Preoperative regional lymph node status by physical examination was clinically node-negative (N0) in all patients.

All study protocols were approved by the Institutional Review Board. Written informed consent was obtained from all patients prior to the procedures.

3DCT-LG

Interstitial CT-LG was performed using a four-detector row CT scanner, as previously described (24). Briefly, under local anesthesia, 4 mL of undiluted iopamidol (Iopamiron 370; Nihon Schering, Osaka, Japan) was injected into the periareolar and peritumoral areas (2 mL at each site), followed by gentle massage for 60 seconds (23–25). Contiguous CT images from the upper thorax to the axillary region were obtained before and immediately after administration of the contrast agent and massage. Contiguous transaxial CT images were reconstructed at intervals of 1.25 mm, and digital imaging and communicaton in medicine (DICOM) data of these images were transferred electronically to a workstation (ZIOSOFT M900, QUADRA; Zaio, Osaka, Japan). Locations of primary SLNs draining directly from the contrast injection sites were determined on these 3D images.

RVS System

The RVS system consists of a magnetic motion-tracking device and US system (EUB-8500; Hitachi Medical, Tokyo, Japan), containing the image-processing workstation and RVS software. The magnetic sensor is fastened to the US probe (3.5–5 MHz). RVS can display in real time the virtual MPR image corresponding to the US image on the US screen. After loading the RVS software and the 3DCT-LG volume data for the patient, the scanner is positioned at the upper margin of the manubrium sternum and scanning is started. We synchronize the US image with the virtual image in which the axillary vein is clearly displayed using the ''Adjust'' function of the system. RVS provides a real-time display of the reconstructed CT image corresponding to the US cross-sectional image on the monitor screen.

US Criteria for SLN Evaluation

After detecting an SLN by the RVS system, the SLN was assessed sonographically for shape and visibility of the hilum. According to previous studies (28,29), our criteria for a ''suspect'' SLN, i.e., an SLN in which metastasis is suspected, were as follows: ratio between longitudinal diameter and transverse diameter (L/T ratio) <2; and ratio between hilar diameter and longitudinal diameter (H/L ratio) is <0.5.

Breast Surgery

The 60 consecutive patients underwent breast surgery (breast-conserving surgery, $n = 25$; mastectomy,

$n = 35$) and SLNB using the blue dye method. A total of 5 mL of indigo carmine dye (Daiichi Seiyaku, Osaka, Japan) was injected into the peritumoral area around each primary tumor. An incision was made along the skin surface marking that was made at 3DCT-LG, then SLNs were identified and biopsied (24). When a positive SLN was found on frozen section, total axillary lymph node dissection was performed. All dissected SLNs were fixed in 10% buffered formalin and sectioned into serial 2.0-mm-thick slices. All slices were embedded in paraffin and examined under hematoxylin and eosin staining.

RESULTS

Using US guided by the RVS system, we were able to detect the same SLN visualized by 3DCT-LG in all patients. The virtual MPR image of the SLN was displayed in good synchronization with the US image (Figs. 1a,b and 2a,b). Suspect SLNs were found in seven of the 60 patients (12%) using US guided by the RVS system. Histological examination confirmed that SLNs were metastatic in four of seven cases. The remaining 53 patients (88%) displayed nonsuspect lymph nodes, with histological examination confirming the absence of metastasis. When predicting SLN metastasis using this RVS system, sensitivity was 100%, specificity was 95%, false-positive rate was 5%, false-negative rate was 0%, positive predictive value was 57% and negative predictive value was 100%. In terms of determining SLN status, the results were unsatisfactory.

DISCUSSION

The RVS system, which displays virtual MPR images obtained from 3DCT-LG, significantly improves the preoperative detection of SLNs. The present study is the first to evaluate the significance of US guided by the RVS system displaying virtual MPR images obtained from 3DCT-LG.

Use of 3DCT-LG allows clear visualization of direct connections between SLNs and lymphatic drainage vessels, even in patients with complex lymphatic routes and multiple SLNs (23–25). Comprehensive preoperative imaging of lymphatic drainage pathways assisted us in finding blue dye-stained lymphatic vessels and SLNs and allowed 100% identification of targeted SLNs in the 61 patients who underwent surgery. SLNs can be visualized precisely by 3DCT-LG, but evaluating SLN status preoperatively by 3DCT-LG alone is difficult. In addition, SLNs in the axillary area cannot be detected by US alone. We therefore used the RVS system, which is a breakthrough diagnostic imaging system, to preoperatively detect SLNs and evaluate SLN status by US.

The RVS system could display in real time the virtual MPR image obtained from CT volume data of 3DCT-LG that corresponded to the same cross-sectional image from US. Iwasaki et al. (26,27) reported that the RVS system offers a novel and effective

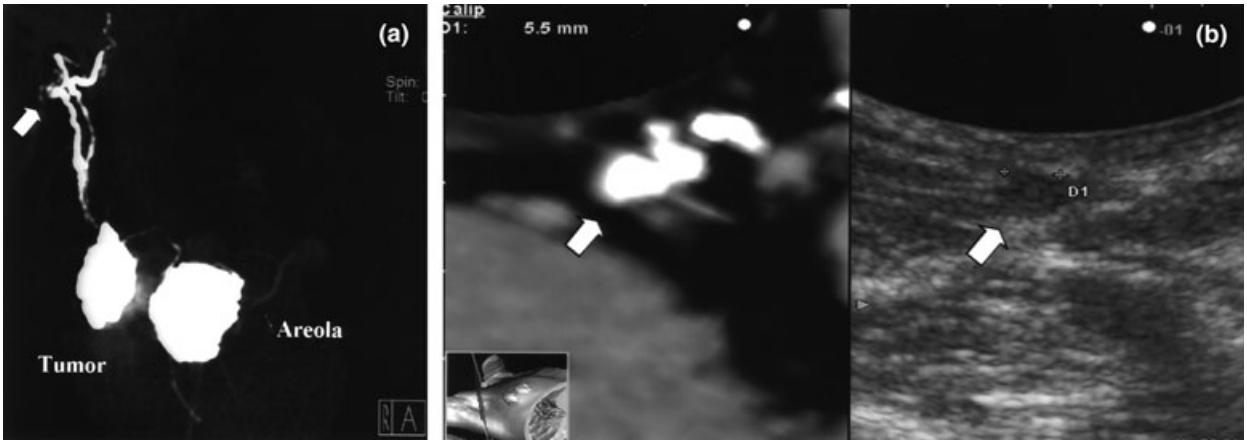

Figure 1. (a) A 3DCT lymphogram. A multiple route/single SLN pattern in a 54-year-old woman with a 50 × 40-mm tumor in the right upper outer quadrant, where multiple lymph vessels drain into a single common SLN. (b) Real-time virtual sonography. A hypoechoic and globular mass shadow corresponding to an SLN detected by 3DCT lymphography (left side, axial image) in the RVS image. This SLN is positive for breast cancer metastasis. The ultrasound image (right side) corresponds to the RVS image of the SLN. sentinel lymph node (SLN).

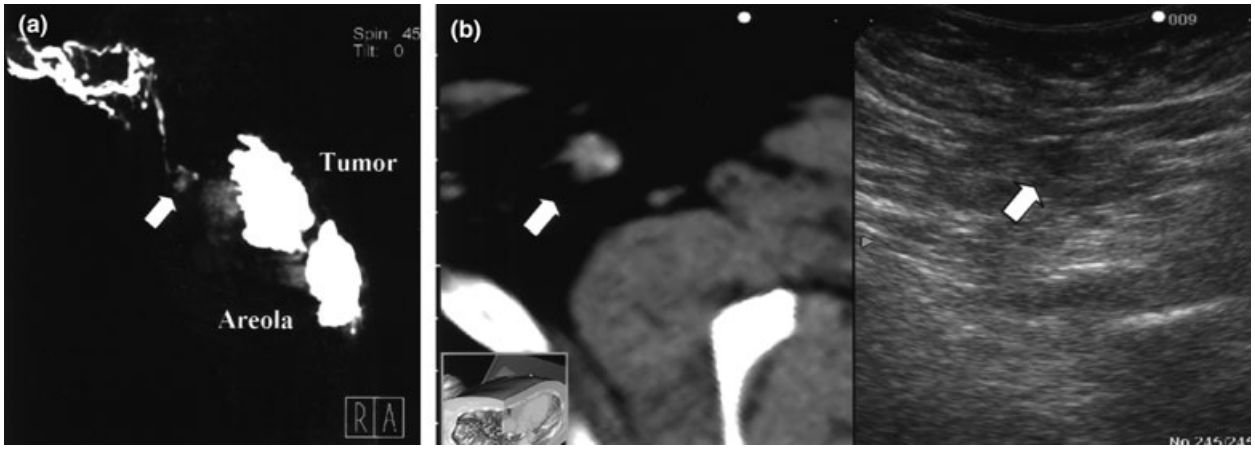

Figure 2. (a) A 3DCT lymphogram. A single route/single SLN pattern in a 41-year-old woman with a 35 × 25-mm tumor in the right upper outer quadrant area, where only a single common lymph vessel from the periareolar and peritumoral areas drains into a single common SLN. (b) Real-time virtual sonography. Hypoechoic shadow corresponds to an SLN detected by 3DCT lymphography (left side, axial image) in the RVS image. This SLN is positive for breast cancer metastasis. The ultrasound image (right side) corresponds to the RVS image of the SLN. sentinel lymph node (SLN).

navigation tool for percutaneous radiofrequency ablation of hepatocellular carcinoma and is useful for identification of residual tumor after ablation and for selection of target tumor among multiple nodular lesions. Few reports pertaining to the RVS system have been presented, as the system was only recently developed. In all patients, we could display the SLN in almost the identical CT plane to that of US imaging and thus diagnose SLN status. The RVS system may prove to be a novel and effective navigation tool for presurgical detection of SLNs in breast cancer patients.

Sakai et al. (28) reported the L/T ratio as >2 in approximately 80% of histologically benign nodes, but <2 in malignant nodes. Nori et al. (29) reported that the H/L ratio is <0.5 in metastatic LN, which is thought to be due to compression or disappearance of hilum fat hyperechogenicity. According to the findings of two previous studies, we diagnosed SLN metastasis if the following criteria were met: L/T ratio <2; and H/L ratio <0.5. However, some studies have shown that node-negative patients cannot be adequately distinguished from node-positive patients on the basis of US findings alone. Positive predictive value was too low (57%) in our study. Since US probe of this RVS system was 3.5–5 MHz, accuracy of US diagnosis may be improved if the US probe is changed to a 10-MHz US linear probe with high resolution.

Many studies have recommended US-guided FNA cytology of axillary lymph nodes for identifying patients with positive nodes, as FNA cytology offers high sensitivity (57–86.4%) and specificity (96–100%) for detecting axillary lymph node metastases (10,19,30). In addition, due to the excellent positive predictive value (100%), futile SLNB can be prevented when preoperative positive FNA results are rendered (31,32).

Although preoperative evaluation of SLN metastatic status by this RVS system was unsatisfactory in this study, the system allows us to perform preoperative FNA cytology of SLN. Moreover, if we directly inject dye into SLNs using the RVS system, SLNB can be easily and accurately performed. Further trials using this system are needed.

REFERENCES

1. Naik AM, Fey J, Gemignani M, *et al.* The risk of axillary relapse after sentinel lymph node biopsy for breast cancer is comparable with that of axillary lymph node dissection: a follow-up study of 4008 procedures. *Ann Surg* 2004;240:462–8.

2. Veronesi U, Paganelli G, Galimberti V, *et al.* Sentinel-node biopsy to avoid axillary dissection in breast cancer with clinically negative lymph-nodes. *Lancet* 1997;349:1864–7.

3. Barranger E, Dubernard G, Fleurence J, *et al.* Subjective morbidity and quality of life after sentinel node biopsy and axillary lymph node dissection for breast cancer. *J Surg Oncol* 2005;92: 17–22.

4. Fleissig A, Fallowfield LJ, Langridge CI, *et al.* Postoperative arm morbidity and quality of life. Results of the ALMANAC randomised trial comparing sentinel node biopsy with standard axillary treatment in the management of patients with early breast cancer. *Breast Cancer Res Treat* 2006;95:279–93.

5. Schwartz GF, Giuliano AE, Veronesi U, *et al.* Proceedings of the Consensus Conference on the role of sentinel lymph node biopsy in carcinoma of the breast. April 19 to 22, 2001, Philadelphia, Pennsylvania. *Hum Pathol* 2002;33:579–89.

6. Lyman GH, Giuliano AE, Somerfield MR, *et al.* American Society of Clinical Oncology guideline recommendations for sentinel lymph node biopsy in early-stage breast cancer. *J Clin Oncol* 2005;23:7703–20.

7. Vaidya JS, Dewar JA, Brown DC, *et al.* A mathematical model for the effect of false-negative sentinel node biopsy on breast cancer mortality: a tool for everyday use. *Breast Cancer Res* 2005;7:225–7.

8. Okamoto T, Yamazaki K, Kanbe M, *et al.* Probability of axillary lymph node metastasis when sentinel node biopsy is negative in women with clinically node negative breast cancer: a Bayesian approach. *Breast Cancer* 2005;12:203–10.

9. Couto D, Dias M, Goncalo M, *et al.* Diagnostic value of ultrasound and color Doppler in identifying axillary lymph node metastases in patients with breast cancer. *Eur J Gynaecol Oncol* 2004;25:568–70.

10. Bonnema J, van Geel AN, van Ooijen B, *et al.* Ultrasound-guided aspiration biopsy for detection of nonpalpable axillary node metastases in breast cancer patients: new diagnostic method. *World J Surg* 1997;21:270–4.

11. Esen G, Gurses B, Yilmaz MH, *et al.* Gray scale and power Doppler US in the preoperative evaluation of axillary metastases in breast cancer patients with no palpable lymph nodes. *Eur Radiol* 2005;15:1215–23.

12. Sapino A, Cassoni P, Zanon E, *et al.* Ultrasonographically-guided fine-needle aspiration of axillary lymph nodes: role in breast cancer management. *Br J Cancer* 2003;88:702–6.

13. Lemos S, Dias M, Goncalo M, *et al.* Detection of axillary metastases in breast cancer patients using ultrasound and colour Doppler combined the fine needle aspiration cytology. *Eur J Gynaecol Oncol* 2005;26:165–6.

14. Wahl RL, Siegel BA, Coleman RE, *et al.* Prospective multicenter study of axillary nodal staging by positron emission tomography in breast cancer: a report of the staging breast cancer with PET Study Group. *J Clin Oncol* 2004;22:277–85.

15. Memarsadeghi M, Riedl CC, Kaneider A, *et al.* Axillary lymph node metastases in patients with breast carcinomas: assessment with nonenhanced versus uspio-enhanced MR imaging. *Radiology* 2006;241:367–77.

16. Stadnik TW, Everaert H, Makkat S, Sacre R, Lamote J, Bourgain C. Breast imaging. Preoperative breast cancer staging: comparison of USPIO-enhanced MR imaging and 18Ffluorodeoxyglucose (FDG) positron emission tomography (PET) imaging for axillary lymph node staging—initial findings. *Eur Radiol* 2006; 16:2153–60.

17. Oruwari JU, Chung MA, Koelliker S, Steinhoff MM, Cady B. Axillary staging using ultrasound-guided fine needle aspiration biopsy in locally advanced breast cancer. *Am J Surg* 2002;184: 307–9.

18. Popli MB, Sahoo M, Merotra N, *et al.* Preoperative ultrasound-guided fine-needle aspiration cytology for axillary staging in breast carcinoma. *Australas Radiol* 2006;50:122–6.

19. Kuenen-Boumeester V, Menke-Pluymers M, de Kanter AY, Obdeijn IM, Urich D, Van Der Kwast TH. Ultrasound-guided fine needle aspiration cytology of axillary lymph nodes in breast cancer patients. A preoperative staging procedure. *Eur J Cancer* 2003; 39:170–4.

20. de Kanter AY, van Eijck CH, van Geel AN, *et al.* Multicenter study of ultrasonographically guided axillary node biopsy in patients with breast cancer. *Br J Surg* 1999;86:1159–62.

21. Bulgaresi P, Cariaggi P, Ciatto S, Houssami N. Positive predictive value of breast fine needle aspiration cytology (FNAC) in combination with clinical and imaging findings: a series of 2334 subjects with abnormal cytology. *Br Cancer Res Treat* 2006; 97:319–21.

22. Cox CE, Salud CJ, Cantor A, *et al.* Learning curves for breast cancer sentinel lymph node mapping based on surgical volume analysis. *J Am Coll Surg* 2001;193:593–600.

23. Suga K, Ogasawara N, Yuan Y, *et al.* Visualization of breast lymphatic pathways with an indirect CT lymphography using a nonionic monometric contrast medium iopamidol: preliminary results. *Invest Radiol* 2003;38:73–84.

24. Tangoku A, Yamamoto S, Suga K, *et al.* Sentinel lymph node biopsy using computed tomography–lymphography in patients with breast cancer. *Surgery* 2004;135:258–65.

25. Suga K, Yamamoto S, Tangoku A, *et al.* Breast sentinel lymph node navigation with three-dimensional interstitial multidetector-row computed tomographic lymphography. *Invest Radiol* 2005;40:336–42.

26. Iwasaki T, Mikami E, Shimosegawa T, *et al.* Real-time Virtual Sonography: a novel navigation tool in percutaneous radiofrequency ablation of hepatocellular carcinomas (abstr). In: *Radiological Society of North America Scientific Assembly and Annual Meeting Program*. Oak Brook, IL: Radiological Society of North America, 2004:392.

27. Iwasaki T, Mikami E, Shimosegawa T, *et al.* Real-time Virtual Sonography (RVS): a novel navigation tool in percutaneous radiofrequency ablation of hepatocellular carcinomas (abstr). In: *Radiological Society of North America Scientific Assembly and Annual Meeting Program*. Oak Brook, IL: Radiological Society of North America, 2004:805.

28. Sakai F, Kiyono K, Sone S, *et al.* Ultrasonic evaluation of cervical metastatic lymphadenopathy. *J Ultrasound Med* 1998;7: 305–10.

29. Nori J, Vanzi E, Bazzocchi M, *et al.* Role of axillary ultrasound examination in the selection of breast cancer patients for sentinel node biopsy. *Am J Surg* 2007;193:16–20.

30. Krishnamurthy S, Sneige N, Bedi DG, *et al.* Role of ultrasoundguided fine needle aspiration of indeterminate and suspicious axillary lymph nodes in the initial staging of breast carcinoma. *Cancer* 2002;95:982–8.

31. Alkuwari E, Auger M. Accuracy of fine-needle aspiration cytology of axillary lymph nodes in breast cancer patients: a study of 115 cases with cytologic-histologic correlation. *Cancer* 2008; 114:89–93.

32. Jain A, Haisfield-Wolfe ME, Lange J, *et al.* The role of ultrasound-guided fine-needle aspiration of axillary nodes in the staging of breast cancer. *Ann Surg Oncol* 2008;15:462–71.