Delivered by Publishing Technology to: Changhua Christian Hospital IP: 203.75.23.20 on: Thu, 14 Mar 2013 15:25:19
Copyright Southeastern Surgical Congress. All rights reserved.

Brief Reports

Brief Reports should be submitted online to www.editorialmanager.com/amsurg. (See details online under "**Instructions for Authors**".) They should be no more than 4 double-spaced pages with no Abstract or sub-headings, with a maximum of four (4) references. If figures are included, they should be limited to two (2). The cost of printing color figures is the responsibility of the author.

In general, authors of case reports should use the Brief Report format.

A Novel Repair of End Colostomy Prolapse

End colostomy prolapse is relatively rare. A case of significant and extreme edematous end colostomy prolapse presented to our center. The ostomy was created two years prior and had been functioning well. Prolapse reportedly occurred after the patient had undergone colonoscopy. Surgical intervention including resection of the redundant prolapsed segment of bowel was performed. Five days after the procedure, the patient was discharged without any complication.

A 56-year-old woman presented to the emergency department with colostomy prolapse. She was previously admitted to the hospital in January 2010 for evisceration of the bowel with fistulas, abdominal wall infection, and exposed mesh after abdominal surgery done in another institute, which the patient could not recall. The patient was a poor historian. She underwent emergent exploratory laparotomy, extensive lysis of adhesions with bowel resection, and end colostomy creation with mucous fistula on that admission. The colostomy had been functioning well for almost two years. The patient went for colonoscopy the day before this admission at another hospital, and she stated that after the procedure, she noticed a large prolapse at the colostomy site. Physical examination reviewed a functioning colostomy with solid stool output. Approximately 30 cm of bowel was prolapsed and intussuscepted from the colostomy. The prolapsed bowel and stoma appeared edematous and pink in color without any signs of necrosis, ischemia, or infection (Fig. 1). All laboratory values and vital signs were within normal limits. The patient denied any other complaints at this time.

The patient was taken to the operating room for colostomy repair. The patient's colostomy was stapled down in three leaflets using Endo GIA ExtraThick Tristaples almost to the level of the skin approximately 1 cm from the skin (Fig. 2). The three leaflets that were created were removed using the Endo GIA stapler. A portion of the mesentery was removed along with the intussuscepted portion of the bowel. The remainder of the end colostomy was approximated to the stump attached to the skin using the Endo GIA stapler and 0 Vicryl suture (Fig. 3). Two days after the procedure, the patient passed gas and stool through the colostomy. On the fifth day after the procedure, the patient was discharged without any complication. Prolonged discharge was at the patient's request to stay in the hospital to be sure the colostomy would function properly.



FIG. 1. Prolapsed end ostomy.

Address correspondence and reprint requests to Michael Paul Betler, D.O., Department of Surgery, Wyckoff Heights Medical Center, 374 Stockholm Street, Brooklyn, NY 11237. E-mail: Drmike324@yahoo.com.

Delivered by Publishing Technology to: Changhua Christian Hospital IP: 203.75.23.20 on: Thu, 14 Mar 2013 15:25:19
Copyright Southeastern Surgical Congress. All rights reserved.



FIG. 2. Three stapled leaflets.

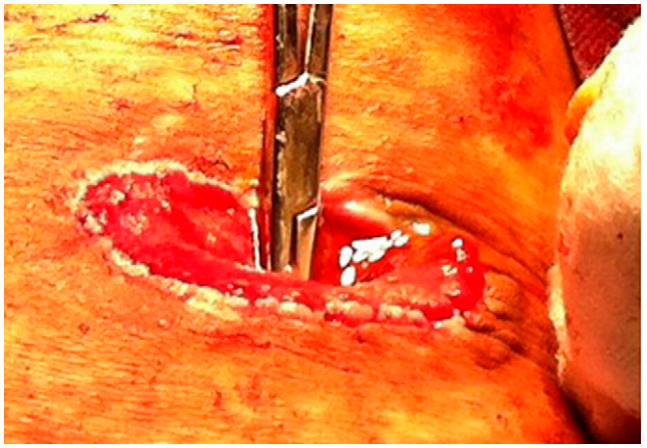

FIG. 3. End result of colostomy.

Stomal prolapse is defined as an increase in the size of stoma after maturation or a full-thickness protrusion of intestine through the stoma that requires a change in the appliance or subsequent surgical treatment.[1] Stomal prolapse occurs when a proximal segment of the bowel intussuscepts and slides to protrude through the stomal orifice.[2] The incidence of stoma prolapse varies from 1 to 16 per cent.[1] All stoma are susceptible to prolapse but the highest incidence has been reported for transverse loop colostomy. The reported incidence of prolapse for transverse loop colostomy is 7 to 25 per cent. End colostomy prolapse is relatively rare. Two to three per cent of end colostomies are generally thought to prolapse. A single-center study has shown that with long-term follow-up, the prolapse rate for end colostomies at their center is 11.8 per cent.[3] Leong et al.[4] from the same center reported the prolapse rate for loop ileostomies to be 11 per cent in a study similar to Londono-Schimmer et al.

Many risk factors have been postulated for stomal prolapse, including obesity, a large opening in the abdominal wall at the time of stoma formation, conditions causing increased intra-abdominal pressure, a poorly fitting ostomy bag, an improper stoma site outside the rectus muscle, chronic obstructive pulmonary disease, weak fascia, and a redundant loop of bowel proximal to the stoma.[1, 2] Interestingly, it was reported that mesenteric fixation at the time of creation of a stoma does not reduce the incidence of stoma prolapse.[3, 4] However, the exact etiology of stomal prolapse remains unknown. In this case, morbid obesity, poor ostomy care, and a colonoscopy procedure may be the contributing factors. The prolapsed stoma is usually of no clinical or functional significance but may be distressful for the patient.[2] Rarely a prolapsed stoma can cause ischemia or strangulation resulting from excessive edema of the prolapsed loop.[2] Simple prolapse can be managed conservatively. Conservative measures include reassurance for the patient and the fitting of a new stoma appliance. Patients with a prolapsed ostomy should be warned about signs of deterioration; any change in the color of the stoma or engorgement requires a specialist consultation.[2] In this case, the length of the prolapsed segment and significant edema made the bowel highly susceptible to ischemia and strangulation, so surgical intervention was pursued. If there are any signs of ischemia or gangrene, then surgery is the only treatment option, which may require reversal if indicated or refashioning of the new stoma after excising the redundant prolapsed bowel.

Thai On Wong, D.O.
Michael Paul Betler, D.O.
Skye Heston III, M.S.
Akella Chendrasekhar, M.D.

Department of Surgery
Wyckoff Heights Medical Center
Brooklyn, New York

REFERENCES

1. Kim JT, Kumar RR. Reoperation for stoma-related complications. Clin Colon Rectal Surg 2006;19:207–12.
2. McErlain D, Kane M, McMgrogan M, Haughey S. Prolapsed stoma. Nurs Stand 2004;18:41–2.
3. Londono-Schimmer EE, Leong APK, Philips RKS. Life table analysis of stomal complications following colostomy. Dis Colon Rectum 1994;37:916–20.
4. Leong APK, Londono-Schimmer EE, Philips RKS. Life table analysis of stomal complications following ileostomy. Br J Surg 1994;81:727–9.