Current Trends in the Management of Blunt Solid Organ Injuries

Korhan Taviloglu, Hakan Yanar[1]

Abstract

The management of patients with solid organ injuries has changed since the introduction of technically advanced imaging tools, such as ultrasonography and multiple scan computerized tomography, interventional radiological techniques and modern intensive care units. In spite of this development in the management of these patients, major solid organ traumas can still be challenging. There has been great improvement in the non-operative management (NOM) of intra-abdominal solid organ injury in recent decades. In most cases treatment of injuries has shifted from early surgical treatment to NOM.

Key Words

Solid organ injury · Blunt abdominal trauma · Non-operative management · Angioembolization · Surgery

Eur J Trauma Emerg Surg 2009;35:90–4

DOI 10.1007/s00068-009-9051-y

Introduction

NOM of blunt abdominal injuries is well established, and strategies based on hemodynamic stability and CT scan findings are now being widely used in the treatment of solid organ injuries, including liver, spleen, kidneys and pancreas injuries [1]. Over the past three decades, multiple studies have shown that NOM of solid organ injuries is effective, with a success rate of more than 90% having been reported [2–7]. Advanced age, injury severity score (ISS), and head injury are important factors that can affect the success rate of NOM [2, 5, 8]. Bee et al. [8] reported 558 patients from a single institution with blunt splenic injury and observed 22% failure in patients older than 55 years of age as compared to 6% failure in patients younger than 55 years old. Malhotra et al. [2, 8] and Bee et al. showed in almost all reports that ISS was an independent predictor of failure. Yanar et al. [9] reported that the Glasgow Coma Scale (GCS) and ISS were significantly higher in the failed-NOM group, but there was no significant difference in terms of age between the groups. Shapiro et al. [10] stated that NOM of neurologically impaired, hemodynamically stable patients with blunt injuries of the liver, spleen or kidney is commonly practiced and is successful in more than 90% of cases. No differences were noted in the rates of delayed laparotomy or survival between normal, mild to moderate, and severely head-injured patients. However, the non-operative approach was initiated less frequently in patients with more impaired mental status: GCS 15: 71%, GCS 8–14: 62% and GCS less than or equal to 7: 50%. In our study GCS and ISS were significantly higher in the failed-NOM group, but there was no significant difference in terms of age between the groups [9].

Rodrigues et al. [11] showed age-related changes in the human splenic capsule in cadavers. In their study, a progressive decrease in the amount of elastic fibers in the splenic capsule was found with aging. Therefore, there is limited contraction and retraction of damaged vessels within the injured parenchyma. Restricted splenic distention may contribute to the failure of NOM in the spleens of the elderly.

Various predictors of NOM failure, including the need for blood transfusion, hypotension on admission, high CT grade of injury and the presence of blush on the CT scan, have been described in the literature [1, 2, 8, 10, 12]. The literature shows that the failure rate is higher in patients who receive more than four units of blood transfusion [13–15]. Maull [16] suggested that blood transfusion can be administered, but should be limited to four units to achieve a stable hematocrit. Velmahos et al. [17] showed that in patients with high-grade splenic injuries who require a transfusion of

[1]Department of Surgery, Istanbul School of Medicine, Trauma and Emergency Surgery Service, Istanbul University, Istanbul, Turkey.

Received: March 12, 2009; accepted: March 12, 2009;
Published Online: March 31, 2009

more than one unit of blood, NOM is very likely to fail. Although it is not routine in many institutions, we order another hematocrit one hour after the first hematocrit. We believe that the second hematocrit after the initial resuscitation and primary survey in the emergency room is the most reliable way of obtaining the patient's actual hematocrit level. In our study, logistic regression revealed the following three independent risk factors for operative intervention: more than 20% drop in hematocrit level in one hour, lactate and solid viscus score (SVS). These risk factors and the predictive model planned around them can help the clinician make decisions with respect to NOM [9]. The causes of failure have been described in different ways in various studies. Velmahos et al. [7] showed that failure occurred in one-third of patients for reasons other than the solid organ injury. In another study, Holmes et al. [6] reported that bicycle crashes were associated with an increased risk of NOM failure, and they also found that the rate of NOM failure was 10.9–38.2% in isolated organ injury, but 54.4–70.0% in multiple organ injury. Malhotra et al. [18] successfully managed nonoperatively four of the 11 patients (36%) with high grade injury to both the liver and spleen. Although the number is quite small, this may support the theory that selected patients with higher grade injuries to multiple solid organs can also be managed nonoperatively. We found the following independent risk factors of failure in multiple solid organ injuries after blunt abdominal trauma: hypotension on admission and higher amounts of PRBC transfusion within the first 6 h following admission. In our study we did not find multiplicity of solid organ injury to be a predictive marker of NOM failure, and subset analysis of organ combination revealed no association with NOM failure [9]. The frequency of delayed bleeding is higher in splenic injury than in hepatic injury, and this may decrease the success rate of NOM [7, 10, 19, 20]. The literature reports that NOM failed in 0–3.5% of patients because of delayed bleeding [2, 21, 22]. The diagnosis and initial management of hemodynamically stable blunt pancreatic trauma should include a high index of suspicion when a patient has sustained a severe force vector in the anterior-posterior direction of the abdominal cavity. In patients experiencing blunt trauma, CT scans provide the best overall method for diagnosis and recognition of a pancreatic injury [23]. Retroperitoneal hematoma, retroperitoneal fluid, free abdominal fluid and pancreatic edema frequently accompany injuries to the pancreas. In patients with penetrating trauma, visualization of perforation, hemorrhage or fluid leak (e.g., bile, pancreatic fluid), or retroperitoneal hematoma around the pancreas suggests the need for further evaluation. If CT shows any suggestion of injury to the pancreas, such as fluid between the splenic vein and the posterior border of the pancreas, follow-up endoscopic retrograde pancreatography (ERP) should be done [24, 25].

In patients with a significant retroperitoneal hematoma, ERP should be followed by noncontrast CT for the evaluation of extravasation of contrast material. If ERP shows ductal disruption or follow-up CT shows extravasation of contrast, operative management is indicated. ERP is useful in determining the presence or absence of pancreatic ductal injury and thus assists in the evaluation of these injuries, allowing nonoperative management if the ductal structures are intact in the diagnosis and may even be normal in the presence of a ductal disruption [26].

In conclusion, changing methods of evaluating and treating blunt abdominal trauma and expanding selection criteria for nonoperative management (NOM) of solid organs can increase the number of patients managed nonoperatively without affecting success rates.

Kidneys have been injured in approximately 10% of trauma cases, and blunt trauma accounts for 90% of renal injuries. Most blunt renal injuries can be managed nonoperativaly. In our trauma center, the only absolute criterion for immediate laparatomy for renal trauma is hemodynamic instability and major urinary extravasation, especially around the renal pelvis [27]. Renal exploration is also indicated during the operation for all suspected renal injuries in patients without complete preoperative imaging. The goal should be maximum renal preservation with minimum complications. Unnecessary exploration results in higher nephrectomy rate, especially in more severe blunt trauma. Ongoing bleeding may be managed by selective embolization [28]. Patients with a vascular pedicle and renal pelvis and ureteral injuries require immediate surgical exploration. The percentage of kidney stab wounds amenable to NOM ranges between 51 and 77%, with success rates of higher than 95% [29, 30].

Operative and Angiographic Approach to Complex Injuries

In the 1970s, perihepatic packing emerged as a successful adjunct in controlling the bleeding and achieving hemostasis. Since then, it has been used extensively with promising results. Once the initial control of the hemorrhage is done with packing, patients are stabilized in intensive care units until the packs are removed

after 24–48 h. In case of rebleeding, repacking is carried out and angiography is performed in order to see if angio-embolization is of value in controlling the bleeding. In many cases, angio-embolization is successful and a valuable adjunct to surgery; however, it is not without any complications in the short and long term. Bile leak and hemobilia, liver or spleen necrosis, renal failure due to contrast toxicity, late pseudoaneurysm and abscess formation are some of the complications that may be encountered [31–33].

The decision to perform laparotomy is based on the initial examination of the patient. Generalized peritonitis and hemodynamic instability in spite of adequate resuscitation are absolute indications for immediate abdominal exploration. On the other hand, less severe signs, such as localized abdominal tenderness or diffuse tenderness without peritoneal signs, are indications for further investigations. In our clinics, after initial evaluation and resuscitation, focused abdominal sonography for trauma (FAST) examination is used for interrogation of the peritoneal cavity. When solid organ injury or free peritoneal fluid is detected, computed tomography (CT) is performed to detect the source, and the visceral injury is graded using the organ injury scale (OIS) [34].

We have been treating our patients with liver or spleen injuries in accordance with the treatment policy shown in figure 1.

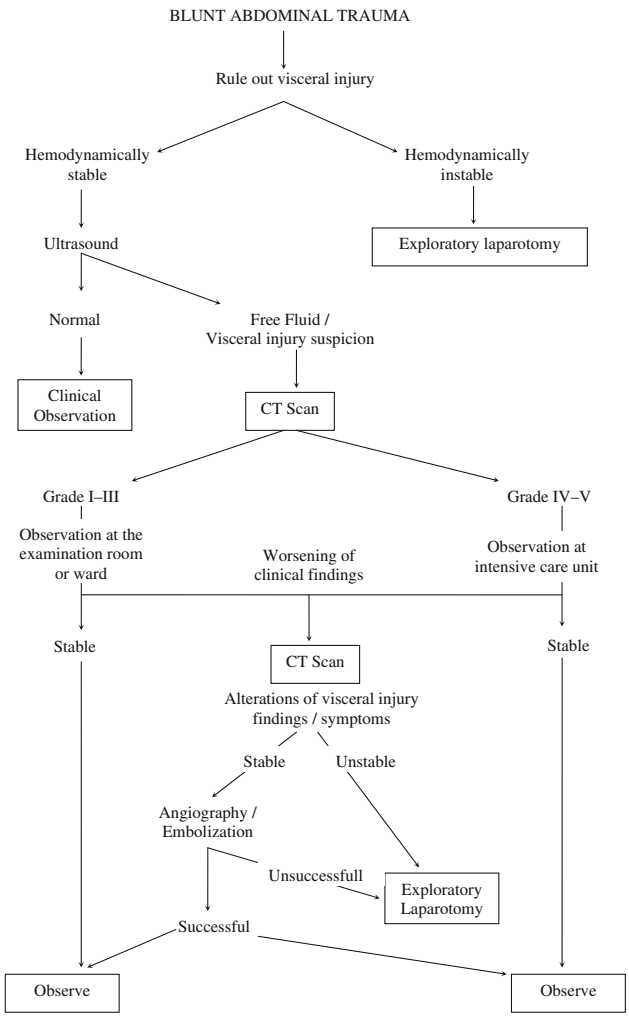

Figure 1. Treatment policy – Blunt Abdominal Trauma.

Operative Approach

A midline incision is preferable for trauma operations in the abdomen. The priority is to obtain hemostasis and control bowel contamination. After palpation and inspection of the liver and spleen, all four quadrants of the abdomen should be checked for any concomitant injuries. Definitive repair is not necessary during the initial operation, and the goal is to stop bleeding. Low-grade injuries of liver (OIS Grades I–III) are often easy to control with compression, packing and argon beam hemostasis. Large liver sutures should not be placed in the hepatic parenchyma because they may cause intraparenchymal hematoma and hemobilia. Some hemostatic agents (microfibrillar collagen, etc.) may be helpful in this condition [35].

In severe injuries of the liver (grade IV-V-VI), hemostasis should be achieved with packing. Major liver resections should not be attempted because it may cause further bleeding. When coagulapathy, acidosis and hypothermia are treated in the intensive care unit, the packs may be removed usually after 24–48 h [36]. Any patients with spleen injury can be managed nonoperatively if they are hemodynamically stabile [37]. Age or grade of injury according to OIS spleen injury scale is not a contraindication for nonoperative management. It must be kept in mind that the presence of splenic parenchymal blush should prompt angio-embolization, and it is a higher index for failure of nonoperative management. Once the spleen has been mobilized, a decision must be made regarding splenic salvage procedures or splenectomy.

Angiography and Angio-embolization

The remaining minority of patients may lose their stability and may need further intervention because of ongoing bleeding. These patients are ideal candidates for angiography and angio-embolization. Even in this group, surgery may be mandatory for life-threatening sudden bleeding. Otherwise, these are mostly managed solely by conservative means; however, some of them

may need to be embolized to stop non-life-threatening bleeding. Angiography is performed with the standard Seldinger technique at the femoral artery. During the interventions, a hydrophilic 4F catheter and a hydrophilic 0.035-inch guide wire are used. The lesions are embolized if a free contrast extravasation or a contrast extravasation in a confined space (such as a pseudoaneurysm or arteriovenous fistula) exists. Angioembolization is performed after selective images of the injured areas were identified by selective catheterization with guide-wire insertion under fluoroscopic control, after assurance that the blood supply distal to the arterial injury was sufficient. A spring coil or gelatin sponge is used during angio-embolization. During the preparation of the procedure, the patient is fluoroscopically monitored, and embolization is stopped when the flow has slowed and before reflux occurs. The procedure is terminated if there is no extravasation at the final angiogram. There is no technique described for portal vein embolization in the traumatized patient at present.

Initial resuscitation during the surgical management has two purposes in these critically injured patients. The first purpose is to control the damage in the abdomen and then to stop bleeding with packing. In poly-traumatized patients, this is the only method of management for diagnosis and treatment. This is a fast and highly effective life-saving procedure that competes with time. It is obvious and logical that angiography and angio-embolization play no role in these poly-traumatized patients.

The second group of injured patients is stable patients with diagnosed rupture of the liver and/or spleen; the degree of abdominal injury may be evaluated with a CT scanner. The CT reveals information regarding evidence of contrast extravasation, the presence of hemoperitoneum, associated injuries and the overall degree of solid organ injury. The management of the patients may be adjusted according to grading of the solid organ injury, which is evaluated by CT. If the grades of these injuries are IV or V according to the abbreviated injury scale (AIS), patients are mostly followed conservatively in the intensive care unit because of expected high rates of complications. Grade I, II and III injuries can be followed in the observation room with low morbidity, and these patients usually (80%) need no further treatment and can be discharged with an uneventful follow-up.

It is clear that angio-embolization (AE) fails as a primary treatment strategy in a certain percentage of patients who are critically injured and cannot be hemodynamically stabilized in spite of an aggressive resuscitation. The rate of such patients may rise up to 64% of patients who would not benefit from AE. Hence, AE may fail in almost half of these patients if it is used as a primary treatment tool. In the report of the Maryland group, 280 out of 648 patients with splenic injury required an immediate operation, and 132 (20.3%) patients underwent AE during the study period [38]. The authors conclude that AE is a valuable adjunct in NOM of splenic injuries in lieu of a primary management tool. It is also stated that in patients with arteriovenous fistula, the failure rate of AE was 40%. Therefore, limitations of using AE exist. Dent et al. [39] also state that a high rate of NOM can be achieved with observation and selective use of arteriography with or without embolization in the management of blunt splenic injuries.

Conclusion

In summary, solid organ injuries can be managed surgically or conservatively with or without angioembolization. None of the options is always the best for every patient. A prioritized manner in regard to the patient's characteristics is the most adequate one.

In conclusion, non-operative management in blunt abdominal trauma is challenging owing to the diversity of presentation and wide range of visceral injuries. However, it is quite satisfying to manage the injuries by a conservative approach that is highly successful in selective cases. The advent of sophisticated imaging and the availability of interventional radiologists has somewhat lightened the trauma surgeons' operative burden. However, even today, nothing surpasses the value of repeated clinical examination by an experienced surgeon in guiding the ultimate therapeutic decision.

References

1. Schwab CW. Selection of nonoperative management candidates. World J Surg 2001;25:1389–92.
2. Malhotra AK, Fabian TC, Croce MA, et al. Blunt hepatic injury: a paradigm shift from operative to nonoperative management in the 1990s. Ann Surg 2000;231:804–13.
3. Buyukunal C, Danismend N, Yeker D. Spleen-saving procedures in pediatric splenic trauma. Br J Surg 1987;74:350–2.
4. Coburn MC, Pfeifer J, DeLuca FG. Nonoperative management of splenic and hepatic trauma in the multiply injured pediatric and adolescent patient. Arch Surg 1995;130:332–8.
5. Myers GL, Dent DL, Stewart RM, et al. Blunt splenic injuries: dedicated trauma surgeons can achieve a high rate of nonoperative success in patients of all ages. J Trauma 2000;48:801–6.
6. Holmes JH 4th, Wiebe DJ, Tataria M, et al. The failure of nonoperative management in pediatric solid organ injury: a multiinstitutional experience. J Trauma 2005;59:1309–13.

7. Velmahos GC, Toutouzas KG, Radin R, et al. Nonoperative treatment of blunt injury to solid abdominal organs: a prospective study. Arch Surg 2003;138:844–51.
8. Bee TK, Croce MA, Miller PR, et al. Failures of splenic nonoperative management: is the glass half empty or half full? J Trauma 2001;50:230–6.
9. Yanar H, Ertekin C, Taviloglu K, et al. Nonoperative treatment of multiple intra-abdominal solid organ injury after blunt abdominal trauma. J Trauma 2008;64:943–8.
10. Shapiro MB, Nance ML, Schiller HJ, et al. Nonoperative management of solid abdominal organ injuries from blunt trauma: impact of neurologic impairment. Am Surg 2001;67:793–6.
11. Rodrigues CJ, Sacchetti JC, Rodrigues AJ Jr. Age-related changes in the elastic fiber network of the human splenic capsule. Lymphology 1999;32:64–9.
12. Knudson MM, Maull KI. Nonoperative management of solid organ injuries: past, present, and future. Surg Clin North Am 1999;79:1357–71.
13. Ekiz F, Yucel T, Ermergen I, et al. The comparison of the results of the conservative treatment between isolated solid organ injuries and those injuries associated with extraabdominal injuries after blunt abdominal trauma. Ulus Travma Derg 2003;9:23–9.
14. Rutledge R, Hunt JP, Lentz CW, et al. A statewide, population-based time-series analysis of the increasing frequency of nonoperative management of abdominal solid organ injury. Ann Surg 1995;222:311–26.
15. Sartorelli KH, Frumiento C, Rogers FB, et al. Nonoperative management of hepatic, splenic and renal injures in adults with multiple injuries. J Trauma 2000;49:56–66.
16. Maull KI. Current status of nonoperative management of liver injuries. World J Surg 2001;25:1403–4.
17. Velmahos GC, Chan LS, Kamel E, et al. Nonoperative management of splenic injuries: have we gone too far? Arch Surg 2000;135:674–9, discussion 679–81.
18. Malhotra AK, Latifi R, Fabian TC, Ivatury RR, Dhage S, Bee TK, et al. Multiplicity of solid organ injury: influence on management and outcomes after blunt abdominal trauma. J Trauma 2003;54:925–9.
19. McIntyre LK, Schiff M, Jurkovich GJ. Failure of nonoperative management of splenic injuries: causes and consequences. Arch Surg 2005;140:563–8, discussion 568-9.
20. Wasvary H, Howells G, Villalba M, et al. Nonoperative management of adult blunt splenic trauma: a 15-year experience. Am Surg 1997;63:694–9.
21. Velmahos GC, Toutouzas K, Radin R, et al. High success with nonoperative management of blunt hepatic trauma: the liver is a sturdy organ. Arch Surg 2004;139:800–1.
22. Pachter HL, Guth AA, Hofstetter SR, et al. Changing patterns in the management of splenic trauma: the impact of nonoperative management. Ann Surg 1998;227:708–17, discussion 717-9.
23. Cirillo RL Jr, Koniaris LG. Detecting blunt pancreatic injuries. J Gastrointest Surg 2002;6:587–98.
24. Bozymski E, Orlando RC, Holt JWRD. Traumatic disruption of the pancreatic duct demonstrated by endoscopic retrograde pancreatography. J Trauma 1981;21:244–45.
25. Kim HS, Lee DK, Kim IW, Baik SK, Kwon SO, Park JW, Cho NC, Rhoe BS. The role of endoscopic retrograde pancreatography in the treatment of traumatic pancreatic duct injury. Gastrointest Endosc 2001;54:49–55.
26. Bradley EL 3rd, Young PR Jr, Chang MC, Allen JE, Baker CC, Meredith W, et al. Diagnosis and initial management of blunt pancreatic trauma: guidelines from a multiinstitutional review. Ann Surg 1998;227:861–9.
27. Güloğlu R, Berber E, Günay K, et al. Conservative management of penetrating renal trauma. Eur J Emerg Surg Intensive Care 1997;20:96–101.
28. DeFade BP, Tierney JP, Stone PA, Truxillo RR. Selective renal artery embolization following blunt renal trauma: case report and current treatment recommendations for renal trauma. WV Med J 2009;105:20–2.
29. Davis KA, Reed RL 2nd, Santaniello J, et al. Predictors of the need for nephrectomy after renal trauma. J Trauma 2006;60:164–9.
30. Shariat SF, Roehrborn CG, Karakiewicz PI, et al. Evidence based validation of the predictive value of the American Association for the Surgery of Trauma Kidney Injury Scale. J Trauma 2007;62:933–9.
31. Hagiwara A, Taruhi T, Murata A, et al. Relationship between pseudoaneurism formation and biloma after successful transarterial embolisation for severe hepatic injury: permanent embolization using stainless steel coils prevents pseudoaneurism formation. J Trauma 2005;59:49–55.
32. Akpofure PE, McCarthy MC, Woods RJ, et al. Complications arising from splenic embolisation after blunt splenic trauma. Am J Surg 2005;189:335–9.
33. Millan MAD, Deballon PO. Computed tomography, angiography, and endoscopic retrograde cholangiopancreatography in the nonoperative management of hepatic and splenic trauma. World J Surg 2001;25:1397–402.
34. Moore EE, Shackford SR, Pachter HL, et al. Organ injury scaling—spleen, liver and kidney. J Trauma 1989;29:1664–66.
35. Recinos G, Inaba K, Dubose J, et al. Local and systemic hemostatics in trauma: a review. Ulus Travma Acil Cerrahi Derg 2008;14:175–81, Review.
36. Kurtoğlu M, Yanar H, Aksoy M. Embolisation rather than surgery in isolated splenic and liver injuries is preferable every time: more vascular and endovascular controversies, In: Greenhalgh RM ed 2006, p: 346–52, BIBA Publishing, UK. (ISBN: 0-9544687-3-2).
37. Uranues S, Pfeifer J. Nonoperative treatment of blunt splenic injury. World J Surg 2001;25:1405–7.
38. Haan J, Scott J, Boyd-Kranis RL, et al. Admission angiography for blunt splenic injury: advantages and pitfalls. J Trauma 2001;51:1161–5.
39. Dent D, Alsabrook G, Erickson BA, Myers J, Wholey M, Stewart R, Root H, Ferral H, Postoak D, Napier D, Pruitt BA Jr. Blunt splenic injuries: high nonoperative management rate can be achieved with selective embolization. J Trauma 2004;56:1063–7.

Address for Correspondence
Korhan Taviloglu, MD, FACS
Department of Surgery
Istanbul School of Medicine
Trauma and Emergency Surgery Service
Istanbul University
34390, Istanbul
Turkey
e-mail: korhan@taviloglu.com