Is the Grading of Liver Injuries a Useful Clinical Tool in the Initial Management of Blunt Trauma Patients?

Thomas S. Helling, Michael R. Ward, Jennifer Balon[1]

Abstract

Background: Computed tomography (CT) has become the preferred method for evaluation of the abdomen for victims of blunt trauma. Grading of liver injuries, primarily by CT, has been advocated as a measure of severity and, by implication, the likelihood for intervention or complications. We have sought to determine if grading of liver injuries, as a clinical tool, affects immediate or extended management of patients.

Methods: We have retrospectively reviewed all patients sustaining blunt liver injuries as diagnosed by CT over a five-year period at a Level I trauma center to determine if grading of injury influenced management. The AAST organ scaling system was utilized (major grade 4–5, minor grade 1–3), as well as the ISS, AIS, mortality, morbidity, and treatment. There were 133 patients available for review. The patients were grouped into major (n = 20) and minor (n = 113) liver injuries and operative (n = 12) and nonoperative (n = 121) management.

Results: Major liver injuries had a higher ISS (39 + 13 vs. 27 + 15, p = 0.001) and were more likely to require operative intervention (5/20 vs. 7/113, p = 0.02). Mortality in this group was not different (major vs. minor), and there were no differences in the incidence of complications. Twelve patients (9%) required operation, all for hemodynamic instability, all within 24 h, and 11/12 within 6 h. At operation 8/12 patients had other sources of bleeding beside the liver injury, and 7/12 had minor hepatic injuries. The operative patients had higher ISS and AIS scores (head/neck, chest, abdomen, extremities) than those managed nonoperatively. More patients died in the operative group (6/12 vs. 8/121, p = 0.0003). There were more pulmonary (6/12 vs. 16/121, p = 0.005), cardiovascular (6/12 vs. 19/121, p = 0.01), and infectious (5/12 vs. 20/121, p = 0.049) complications in the operative group. There were 14 deaths overall; 13/14 were due to traumatic brain injury, and 8/14 required urgent operation for hemorrhage.

Conclusions: In conclusion, grading of liver injuries does not seem to influence immediate management. Physiologic behavior dictated management and need for operative intervention, as well as prognosis. However, both major hepatic injuries and need for early operation reflected overall severity and the possibility of associated injuries.

Key Words
Liver trauma · Hepatic injuries · Blunt trauma · Trauma

Eur J Trauma Emerg Surg 2009;35:95–101

DOI 10.1007/s00068-008-8156-z

Introduction

Until the widespread use of computed tomography (CT) in evaluating victims of trauma, the diagnosis and management of liver injuries was largely based on clinical evaluation. The overriding prompter for operation was hemodynamic instablility. Almost a century ago the German surgeon Thöle [1] demonstrated the need for urgency in controlling hemorrhage from liver wounds by describing the relentless rise in mortality by delaying operation. For the most severe liver wound – he termed these liver ruptures – a delay in operation of longer than six hours resulted in 50% mortality, and for delays longer than 24 h, an 86% mortality rate. Even with less extensive injuries, stabbing-type wounds, half the victims died with a delay in operation exceeding 24 h. Hemorrhage was clearly the immediate threat.

[1]Department of Surgery, Conemaugh Memorial Medical Center, Johnstown, PA, USA.

Received: August 18, 2008; revision accepted: October 2, 2008; Published Online: November 12, 2008

In 1935 Shedden and Johnston [2] summarized known experience in treating injuries to the liver. Their remarks have become rather prophetic, even with today's understanding of hepatic trauma. They acknowledged that hemorrhage was a significant consequence of injury, due to one of three mechanisms of injury: rupture of liver tissue with laceration of Glisson's capsule; separation of Glisson's capsule with subcapsular hematoma; or central rupture leading to intraparenchymal hematoma. As the authors pointed out, diagnosis of liver trauma up to 1935 was, of course, largely clinical: right upper quadrant pain, peritoneal signs, and shock were dominant findings. ''Immediate operation'' was essential, as ''spontaneous hemostasis of a traumatized liver is rare.'' And, importantly, they recognized the frequent occurrence of other abdominal visceral or thoracic injuries, which could contribute to a critical clinical condition.

Following the Second World War, reports began appearing describing civilian liver injuries. Sparkman and Fogelman [3] described 100 such injuries over an eight-year period. Ninety-two percent were penetrating. Mortality was 10% and steadily increased as the number of associated injuries rose. Interestingly, 30 patients sustained thoracoabdominal injuries, attesting to the multisystem nature of many of these injuries. The authors commented that ''…98 (of 100 patients) underwent operation upon admission or shortly thereafter,'' and acknowledged that hemorrhage was the overriding concern in initial management. Nonoperative management was attempted in two cases, but eventual exploration was needed for ''unrecognized abdominal injury'' in both instances.

Perhaps the largest series of patients suffering hepatic trauma in the operative era was reported by Feliciano et al. [4]. One thousand cases over a five-and-a–half-year period, 1979–1984, were accumulated by the authors, 86% of which were penetrating injuries. In addition to evidence of hemorrhage (''symptomatic patients''), the use of diagnostic peritoneal lavage in ''asymptomatic'' or obtunded patients also prompted operation. Many patients (64%) required simple repair of hepatic injuries, but it is not mentioned how many of these patients needed an operation at all. Somewhat surprising was the observation that the mortality was 10.5% – the same as that reported over 20 years before.

Over the past 20 years there has been two significant developments in the management of liver injuries. First, there has been a distinct increase in the number of injuries from blunt trauma, and second, there has been the introduction of noninvasive imaging techniques to aid in the diagnosis of blunt intraabdominal trauma [5]. From the identification of so many heretofore unrecognized liver injuries, a grading system has emerged to assign severity of injury [6, 7]. However, the fundamental question in grading liver injuries is: for what purpose? The authors of these CT-based classification systems express that ''the results…have increased the confidence of our surgical staff in delaying celiotomy in isolated or predominately blunt liver injury demonstrated with the help of preoperative CT in hemodynamically stable patients'' [5], and that ''the fundamental objective of the OIS (organ injury scaling)…is not to assign prognostic value…but rather to provide a clearer description to facilitate comparison of an equivalent injury managed in one fashion versus another'' [7].

But has CT altered management of liver injuries? Is the approach to blunt abdominal trauma any different in the twenty-first century than a century ago? Or are we simply more aware of those injuries that produce relatively little bleeding and otherwise would have escaped detection? We have attempted to answer these questions by examining our recent experience in managing blunt liver trauma at a regional trauma center.

Materials and Methods

All patients suffering blunt liver trauma from 2000–2006 were queried from the trauma registry of our Level I Regional Resource Trauma Center, accredited by the Pennsylvania Trauma Systems Foundation. During this time, a philosophy of nonoperative management of solid visceral injuries was followed in stable blunt trauma patients who could be reliably evaluated. Initial decision-making involved hemodynamic behavior, routine emergency department (ED) roentgenograms, and focused abdominal sonography for trauma (FAST). Failure of nonoperative management was arbitrarily decided as evidence of ongoing bleeding requiring exploration beyond 6 h of ED admission, because this amount of time is thought to be needed for adequate evaluation and fluid resuscitation and to detect evidence of continued bleeding despite resuscitation. CT scans were obtained, when possible, in patients suspected of suffering abdominal trauma as a primary means of assessing solid organ injury. The primary means of identification of liver injuries was by International Classification of Disease, Ninth Edition (ICD-9). The following codes were used for identification: 864.1, 864.2, 864.3, 864.4, 864.5, 864.9.

In the identified patients, liver injuries were graded, using CT scans and/or operative findings. If the grade of injury was not indicated in the dictated radiology report, the CT scan was re-examined by one of the authors and grading was assigned. Other variables

assessed included the abbreviated injury severity (AIS) score, the injury severity score (ISS), the Glasgow coma scale (GCS), chronicling of other torso injuries, heart rate and systolic blood pressure in the ED, blood utilization (pRBCs), timing of abdominal surgery, reason for abdominal exploration, operative findings, use of radiologic interventional treatment, mortality and cause of death, complications, and intensive care unit (ICU) length of stay (LOS) and hospital LOS. Complications include pulmonary, cardiovascular, renal, hepatic, gastrointestinal, infectious, hemorrhagic, and neurologic events. Patients were also grouped into those who were managed nonoperatively versus operatively and those with American Association for the Surgery of Trauma (AAST) [7] grades I–III (minor injuries) and grades IV and V (major injuries), for comparison purposes. Results are expressed as mean ± standard deviation. Statistical methodology consisted of Student's t-test for continuous variables and χ-square or Fisher's exact test for dichotomous variables. A p value of < 0.05 was considered significant. This study was approved by our institutional review board and conformed to the protection of private health information as required by the Health Insurance Portability and Accountability Act.

Results

During this time period 148 patients were identified as suffering blunt hepatic injuries. However, 15 patients were excluded because grading of liver injuries could not be confirmed, and CT scans were not available. Therefore, the evaluable study group comprised 133 subjects. There were 77 males and 56 females. Mean age was 34 ± 17 years with a range of 7–84 years. Patients were graded according to the severity of their liver injury as follows: grade I, 29 patients; grade II, 50 patients; grade III, 34 patients; grade IV, 18 patients; and grade V, 2 patients. Grouped according to severity, there were 113 patients with minor (grades I–III) injuries and 20 patients with major (grades IV–V) injuries.

In patients with major liver injuries there were significantly higher ISS scores (39 ± 13 vs. 27 ± 15, p = 0.001), higher abdomen AIS, and more units of blood transfused (Table 1). They were more likely to undergo operation (5/20 vs. 7/113, p = 0.02). However, hemodynamic parameters demonstrated a lower heart rate and no difference in ED systolic blood pressure in major liver injuries. In addition, there was no difference in mortality between the major and minor groups. There were no differences in the rates of complications between the two groups (Table 2). There was also no difference in ICU LOS and hospital LOS between the two groups.

Fourteen patients underwent an exploratory celiotomy. Four patients were taken directly to the OR without CT. Two patients had liver injuries, which were not bleeding at the time of operation. One patient had a splenectomy and repair of diaphragm and pancreas. The other had control of bleeding mesenteric vessels and splenectomy and diaphragm repair. These two patients were considered as nonoperative man-

Table 1. Comparison of clinical variables encountered in minor and major liver injuries (NS: not statistically significant, p ≥ 0.05).

Independent variable	Minor (grades I–III)			Major (grades IV–V)			p
	n	mean	SD	n	mean	SD	
Age	113	33.8	17.29	20	35.05	15.34	NS
ISS	113	26.58	14.94	20	39.05	12.66	0.001
AIS head/neck	113	2.15	1.66	20	2.4	1.70	NS
AIS face	113	0.42	0.86	20	0.4	1.00	NS
AIS chest	113	2.46	1.83	20	2.95	1.64	NS
AIS extremity	113	1.31	1.34	20	1.7	1.56	NS
AIS external	113	0.87	0.34	20	0.75	0.44	NS
AIS abdomen	113	2.74	0.95	20	4.15	0.67	0.0001
ED heartrate	113	100.99	24.66	20	87.4	24.88	0.025
ED systolic BP	113	120.63	23.73	20	121.25	18.80	NS
# Units pRBCs pre-op	113	0.14	0.68	20	2.35	6.91	0.001
# Units pRBCs total	113	2.97	5.56	20	8	17.38	0.048
ICU LOS	81	3.59	7.28	13	4.69	5.36	NS
Total LOS	81	7.47	8.39	13	9.62	5.67	NS
Operative management	113	7		20	5		0.018
Mortality	113	12		20	2		NS

Table 2. Complications identified in the treatment of minor and major liver injuries (NS: not statistically significant, $p \geq 0.05$).

Complication	Minor (grades I–III) (N = 113)	Major (grades IV–V) (N = 20)	p value
Pulmonary	16	6	NS
Cardiovascular	19	6	NS
Renal	5	2	NS
Hepatic	1	0	NS
Infection/sepsis	19	6	NS
Gastrointestinal	4	1	NS
Neurologic	6	0	NS
Hemorrhagic	0	0	NS

agement of their liver injuries. Twelve patients (9%) received an operation for their liver injury, 121 patients were managed nonoperatively. Two patients had a grade V injury, three a grade IV injury, four a grade III injury, one a grade II injury and two a grade I injury. Patients requiring operation had a significantly higher ISS (49.92 ± 10.83 vs. 26.33 ± 13.93, $p = 0.0001$), higher grade of liver injury, higher AIS for head/neck, chest, extremity, and abdomen, a significantly lower ED systolic blood pressure, and more blood transfusions (Table 3). In 11/12 patients treated operatively, the operation was performed within six hours of ED admission, and all were performed for evidence of ongoing intra-abdominal bleeding manifested by persistent hypotension or transient responses to fluid resuscitation followed by recurring hypotension. The twelfth patient received an operation after 24 hours of nonoperative management because of continued evidence of bleeding, and represents the only failure of nonoperative management. In 4/12 patients the liver was the only visceral injury bleeding. Of the 12 operated patients, 11 required procedures on the liver to stop bleeding: three required packing (two grade IV and one grade II), two of whom were taken directly to the OR because of nonresponse to fluid resuscitation in the ED; in three patients, suturing was required (two grade III, one grade I); in two patients electrocautery only of the lacerations was performed (grade III); in one patient partial hepatectomy was performed (grade IV); in one patient ligation of bleeding hepatic veins (grade V); and in one patient a combination of suturing and packing was required (grade V). There were six patients who required splenectomies and four patients with mesenteric or retroperitoneal bleeding. Three additional patients had thoracic injuries requiring thoracotomy. Of the 12 operated patients, five had major and seven had minor hepatic injuries. There were six deaths in this group, significantly more ($p = 0.0003$) than in the nonoperated group. There were more pulmonary (6/12 vs. 16/121, $p = 0.005$), cardiovascular (6/12 vs. 19/121, $p = 0.01$), and infectious/septic (5/12 vs. 20/121, $p = 0.049$) complications in the operative group (Table 4). One patient in the nonoperative group experienced a hepatic-related complication; there were no hepatic complications in

Table 3. Comparison of clinical variables encountered in operated and nonoperative patients (# units pRBCs: number of units of pRBCs administered before *any* operation; NS: not statistically significant, $p \geq 0.05$).

Independent variable	Operative patients			Non-operative patients			p
	n	Mean	SD	n	Mean	SD	
Age	12	39.75	16.587	121	33.41	16.963	NS
ISS	12	49.92	10.833	121	26.33	13.934	0.0001
Grade of liver injury	12	3.17	1.337	121	2.27	0.949	0.014
AIS head/neck	12	3.33	1.775	121	2.07	1.613	0.016
AIS face	12	0.33	0.888	121	0.42	0.883	NS
AIS chest	12	3.67	1.435	121	2.42	1.806	0.02
AIS extremity	12	2.08	1.311	121	1.3	1.37	0.048
AIS external	12	0.92	0.289	121	0.84	0.365	NS
AIS abdomen	12	4.17	1.03	121	2.83	0.969	0.0001
ED heartrate	12	104.67	29.441	121	98.38	24.674	NS
ED systolic BP	12	103.5	20.712	121	122.43	22.574	0.005
# Units pRBCs pre-op	12	4.33	8.616	121	0.09	0.483	0.0001
# Units pRBCs total	12	14.92	20.87	121	2.62	5.153	0.0001
ICU LOS	6	12	17.332	88	3.18	5.524	NS
Total LOS	6	15.83	19.954	88	7.22	6.49	NS
Mortality	6			8			0.0003

Table 4. Complications identified in patients managed operatively and nonoperatively (NS: not statistically significant, $p \geq 0.05$).

Complication	Operative cases (N = 12)	Nonoperative cases (N = 121)	p Value
Pulmonary	6	16	0.005
Cardiovascular	6	19	0.01
Renal	2	5	NS
Hepatic	0	1	NS
Infection/sepsis	5	20	0.049
Gastrointestinal	2	3	NS
Neurologic	2	4	NS
Hemorrhagic	0	0	NS

the operative group. There was no difference in ICU LOS and hospital LOS between the two groups.

Nine patients had arteriograms by interventional radiology. There were four grade III injuries and five grade IV injuries in this group ($p = 0.007$). Seven of these patients also had angioembolization for bleeding: all five grade IV injuries and two grade III injuries ($p = 0.002$). Three patients had arteriography more than 24 h after injury (post-injury days 4, 7, and 13). Six patients had arteriography within 6 h of admission. In three patients (two grade IV, one grade III), arteriography and embolization was preceded by exploratory celiotomy. Two of these patients died (one grade IV, one grade III). In only one patient did embolization precede celiotomy, and this patient developed abdominal compartment syndrome 24 h after embolization. This patient subsequently died of traumatic brain injury.

Overall, there were 14 deaths. Twelve of the 14 patients died from traumatic brain injury. One patient died from attempts to repair a torn thoracic aorta, and one patient died on the operating table in an attempt to control intra-abdominal bleeding, largely from a Grade II liver laceration (clinical, not radiographic, assessment). Of interest is the significantly higher mortality in operated patients (9/12 vs. 3/121, $p < 0.0001$) (Table 2).

Discussion

In the immediate management of the injured patient, operative intervention is governed by physical examination, clinical behavior, and directed by gross assessment of body cavities, often using bedside tools such as the FAST. Mandatory exploration of the abdomen is no longer advocated for the presence of hemoperitoneum alone, previously detected by diagnostic peritoneal lavage or clinical suspicion. Rapid CT scanning has instead allowed a detailed ''peek'' into the trauma abdomen without disturbing hemostasis, but cannot always indicate the rapidity or extent of hemorrhage. Our study illustrates this point. All but one patient needing operation were taken to the OR within hours of arrival, due to evidence of ongoing abdominal bleeding. The present study also highlights the severity and multiplicity of injuries in patients who are physiologically unstable, as ten of the 12 operated patients had other sources of bleeding beside the liver injury. While patients later determined to have major (grade IV and V) hepatic injuries were more likely to undergo operation in our series, a significant number of operated patients (7/12) had minor hepatic injuries – bleeding was from other abdominal sources. Similar findings were reported by Velmahos et al. [8], who found that 11/23 patients (48%) requiring immediate operation had nonhepatic sources of hemorrhage. CT scan was obtained in hemodynamically stable patients, but, despite findings, was not used as a criterion for exploration. However, the presence of contrast extravasation on CT prompted attempts to radiographically determine ongoing *arterial* bleeding, which, if discovered, was treated by angioembolization. Likewise, we employed angioembolization when contrast extravasation was appreciated on CT. Whether this was instrumental in forestalling bleeding is difficult to say, as there was no ''control'' group for comparison. It is not clear if contrast extravasation portends continued bleeding in liver trauma, as it seems to in splenic injuries [9]. It also is not clear whether embolization truly reduces the need for operation in either splenic injuries [10, 11] or liver trauma [12], as properly controlled studies have not yet been performed.

In fact, the use of grading of liver injury for determination of operability by imaging is distinctly controversial. Early on, only low-grade injuries (grade I–III), as judged by CT scanning, were managed nonoperatively [13]. However, it was soon realized that even extensive injuries by CT scanning could be similarly treated if hemodynamically stable. Sherman et al. [14] have demonstrated that patients could be managed nonoperatively, based on hemodynamic criteria, regardless of grade of liver injury by CT scanning, when matched with operative controls. Others [15] have shown that even a large amount of hemoperitoneum is not an absolute indication for operation, provided the patient is stable hemodynamically (Figure 1). Of 80 patients with grade IV or V liver injuries, Duane et al. [16] managed 36 nonoperatively and used hemodynamic criteria as a guide. They acknowledged that parameters to aid in management were elusive and that ''decision-making of the severe liver injury is a dynamic process,'' presumably independent of grading. Interestingly, a prospective study by Croce et al. [17]



Figure 1. Extravasation from the retrohepatic inferior vena cave, indicating a grade V injury. The hemorrhage eventually stopped, perhaps contained by the weight of the liver, allowing for nonoperative management of this injury, despite the amount of free intraperitoneal blood.

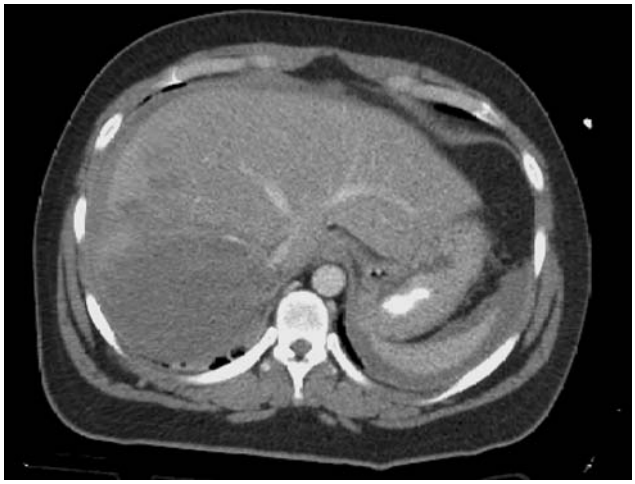

Figure 2. One of the grade IV liver injuries managed nonoperatively. Note the contrast extravasation, seemingly arising from a major hepatic vein. The consequent hemorrhage appears confined in the substance of the liver.

demonstrated that grade of liver injury did not correlate with failure of nonoperative management. Liver-related failure rates were 20 percent for grade I and 12% for grade V. In fact, in this series, the majority (70%) of patients managed nonoperatively had major grade (grade III–V) injuries. Finding no correlation with CT grade of liver injury and need for operation, Becker et al. [18] concluded that ''injury grading with CT may reflect the degree of hepatic parenchymal damage but does not indicate patients in whom complications may develop or surgery is necessary.''

It is noteworthy, from our series, that the overall severity of injury dictated the degree of intra-abdominal injuries. In both the major/minor and operative/nonoperative groupings, ISS and abdominal AIS were statistically linked to the presence of major liver injuries and need for operation. This association is probably due, in turn, to the traumatic forces to which the victim was subjected.

Our study also attests to the remarkable stability of liver injuries in the absence of ongoing bleeding. Only one of 122 patients (0.8%) who were initially physiologically stable eventually required operation. Rather surprisingly, there was no difference in physiologic presentation of major liver injuries compared to minor injuries when initial ED parameters, heart rate and systolic blood pressure were examined. In patients with major liver injuries, Grade IV and V (n = 20), only five required operation despite a sometimes alarming appearance on CT (Figures 1, 2). However, in those five patients, rather elaborate measures were needed to stop bleeding – packing, hepatorrhaphy, hepatic resection, and exposure and ligation of hepatic veins. The number of units of pRBCs administered during nonoperative management averaged 2.62, even in the presence of multisystem trauma. Others [5, 8] have commented on this, indicating that low-pressure hepatic or portal vein bleeding is more likely to spontaneously stop, and that such clots are probably best left undisturbed. We might add that the integrity of liver parenchyma also contributes to hemostasis. Disruptions of Glisson's capsule and parenchymal rents, exposing underlying venous and arterial injuries, are more likely to result in ongoing intraperitoneal bleeding (Figure 3). Intact capsule can contain intraparenchymal hemorrhage and eventually cause cessation of bleeding, although CT appearance may show extensive distruction of hepatic tissue. This speculation has been supported by Fang et al. [19], who demonstrated that intraperitoneal

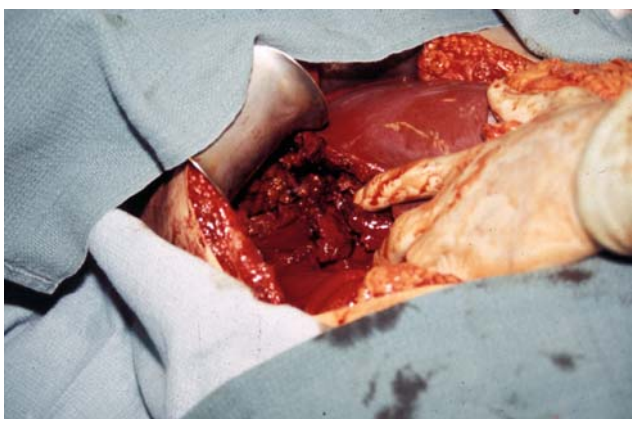

Figure 3. Example of a grade IV liver injury requiring operation. Note the extensive capsular and parenchymal disruption, allowing for free egress of blood into the peritoneal cavity and unchecked hemorrhage.

contrast extravasation seen on CT was independently associated with the need for operative treatment. Nevertheless, these injuries were worrisome. Significantly more patients underwent hepatic arteriography and embolization than in lower grade injuries.

Complications were actually lower in the nonoperative group, although the sole liver-related complication was in this group. There is no clear explanation for the higher rates of pulmonary, cardiovascular, and infectious complications in the nonoperative group. One might expect higher rates in the operative group, particularly with respect to infections, as six splenectomies were performed in this group. Whatever the reason, it does not appear from these data that immediate operation avoids later complications.

In conclusion, are we able to answer the questions posed at the outset? While CT can portray the anatomic extent of injury, it is not a physiologic tool to assess need for operation. In this sense, and in our series, it did not alter the initial management of liver injuries. As is repeatedly emphasized in the trauma literature, management is governed by the need to control hemorrhage, and hemorrhage is determined by cardiovascular changes caused by volume loss. This is reiterated in the present study. While the liver is of interest in terms of its particular ability to contain bleeding, liver injury does not often exist in a vacuum. The blunt trauma abdomen can harbor other sites of injury, and there can be abundant extra-abdominal sources as well. Grading of liver injuries, primarily by CT in the present era, serves to describe the extent of injury, perhaps evidence of potential bleeding, but has not substituted for clinical management. CT, of course, may also be helpful in determining other sites of intra-abdominal injury. Perhaps most interestingly, CT has enabled us to appreciate the resiliency of the human condition to absorb and repair extensive trauma without the (sometimes) meddlesome intrusions of well-meaning trauma surgeons.

References

1. Thöle F. Verletzungen der Leber und Gallenwege. Stuttgart: Ferdinand Enke, 1912.
2. Shedden WM, Johnston F. Traumatic rupture of the liver. N Engl J Med 1935;213:960–5.
3. Sparkman RS, Fogelman MJ. Wounds of the liver: review of 100 cases. Ann Surg 1954;139:690–714.
4. Feliciano DV, Mattox KL, Jordan GL Jr, Burch JM, Bitondo CG, Cruse PA. Management of 1000 consecutive cases of hepatic trauma (1979–1984). Ann Surg 1986;204:438–45.
5. Richardson JD. Changes in the management of injuries to the liver and spleen. J Am Coll Surg 2005;200:648–69.
6. Mirvis SE, Whitley NO, Vainwright JR, Gens DR. Blunt hepatic trauma in adults: CT-based classification and correlation with prognosis and treatment. Radiology 1989;171:27–32.
7. Moore EE, Cogbill TH, Jurkovich GJ, Shackford SR, Malangoni MA, Champion HR. Organ injury scaling: spleen and liver (1994 revision). J Trauma 1995;38:323–4.
8. Velmahos FC, Toutouzas K, Radin R, Chan L, Rhee P, Tillou A, Demetriades D. High success with nonoperative management of blunt hepatic trauma. Arch Surg 2003;138:475–81.
9. Marmery H, Shanmuganathan K, Mirvis SE, Richard H, Sliker C, Miller LA, Haan JM, Witlus D, Scalea TM. Correlation of multidetector CT findings with splenic arteriography and surgery: prospective study in 392 patients. J Am Coll Surg 2008;206:685–93.
10. Harbrecht BG, Ko SH, Watson GA, Forsythe RM, Rosengart MR, Peitzman AB. Angiography for blunt splenic trauma does not improve the success rate of nonoperative management. J Trauma 2007;63:44–9.
11. Smith HE, Biffl WL, Majercik SD, Jednacz J, Lambiase R, Cioffi WG. Splenic artery embolization: have we gone too far? J Trauma 2006;61:541–4.
12. Mohr AM, Lavery RF, Barone A, Bahramipour P, Magnotti LF, Osband AJ, Sifri Z, Livingston DH. Angiographic embolization for liver injuries: low mortality, high morbidity. J Trauma 2003;55:1077–81.
13. Pachter HL, Knudson MM, Esrig B, Ross S, Hoyt D, Cogbill T, Sherman H, Scalea T, Harrison P, Shackford S, Ochsner MG, Mucha P, Hofstetter SR, Guth A, Coffey S, Kataju S, Marburger R, Garcia J, Savage B, Henry S, Lippold D, Trevesani G, Steinig J. Status of nonoperative management of blunt hepatic injuries in 1995: a multicenter experience with 404 patients. J Trauma 1996;40:31–8.
14. Sherman HF, Savage BA, Jones LM, Barrette RR, Latenser BA, Varcelotti JR, McAuley CE, Jones RT, Myers AH. Nonoperative management of blunt hepatic injuries: safe at any grade? J Trauma 1994;37:616–21.
15. Goan Y-G, Huang M-S, Lin J-M. Nonoperative management for extensive hepatic and splenic injuries with significant hemoperitoneum in adults. J Trauma 1998;45:360–4.
16. Duane TM, Como JJ, Bochicchio GV, Scalea TM. Reevaluating the management and outcomes of severe blunt liver injury. J Trauma 2004;57:494–500.
17. Croce MA, Fabian TC, Menke PG, Waddle-Smith L, Minard G, Kudsk KA, Patton JH Jr, Schurr MJ, Pritchard FE. Nonoperative management of blunt hepatic trauma is the treatment of choice for hemodynamically stable patients. Results of a prospective trial. Ann Surg 1995;221:744–53.
18. Becker CD, Gal I, Baer HU, Vock P. Blunt hepatic trauma in adults: correlation of CT injury grade with outcome. Radiology 1996;201:215–20.
19. Fang J-F, Wong Y-C, Lin B-C, Hsu Y-P, Chen M-F. The CT risk factors for the need of operative treatment in initially hemodynamically stable patients after blunt hepatic trauma. J Trauma 2006;61:547–554.

Address for Correspondence
Thomas S. Helling, MD, FACS
Department of Surgery
Conemaugh Memorial Medical Center
1086 Franklin Street
Johnstown
PA 15905
USA
Phone (+1/814) 534-3670, Fax -3279
e-mail: thelling@conemaugh.org