J Neurosurg 117:288–294, 2012

Superficial temporal artery–middle cerebral artery bypass using local anesthesia and a sedative without endotracheal general anesthesia

Clinical article

Yasuhiko Kaku, M.D., Kentaro Yamashita, M.D., Jouji Kokuzawa, M.D., Kiyomitsu Kanou, M.D., and Masanori Tsujimoto, M.D.

Department of Neurosurgery, Asahi University Murakami Memorial Hospital, Gifu, Japan

Object. Superficial temporal artery (STA)–middle cerebral artery (MCA) bypasses have continually evolved, and new strategies have been advocated for reducing anesthetic or surgical morbidity and mortality. Further simplifying, and decreasing the invasiveness of, STA-MCA bypass by performing this operation without endotracheal general anesthesia was believed to be feasible in certain subsets of patients.

Methods. The authors performed STA-MCA bypass using local anesthesia with a sedative in 10 patients with hemodynamically compromised occlusive cerebrovascular disease, as well as multiple comorbidities, between February 2010 and September 2011. The technique is based on the preoperative identification of the point at which the donor and recipient vessels are in closest proximity. Preoperative use of CT angiography allowed the authors to identify the target point precisely and use a minimally invasive procedure. All patients received dexmedetomidine as the sole sedative agent, together with scalp-blocking local anesthesia, with an unsecured airway.

Results. Successful STA-MCA bypass surgeries were achieved via a preselected minimally invasive approach in all cases. There was good hemodynamic stability throughout surgery. No airway or ventilation complications occurred, and no patients were converted to general anesthesia. Subjectively, patients tolerated the technique well with a high rate of satisfaction. There were no perioperative morbidities or deaths. Postoperative MR angiography confirmed a patent bypass in all patients. All patients remained symptom free and returned to normal daily life following the operation.

Conclusions. This initial experience confirms the feasibility of performing STA-MCA bypass without endotracheal general anesthesia. This novel technique produced a high degree of patient satisfaction.
(http://thejns.org/doi/abs/10.3171/2012.4.JNS111958)

Key Words • **superficial temporal artery** • **middle cerebral artery** • **bypass** • **local anesthesia** • **minimally invasive technique** • **vascular disorders**

The STA-MCA bypass is an established cerebral revascularization procedure that is used in the treatment of selected cases of occlusive cerebrovascular disease, moyamoya disease, cerebral aneurysms, and skull base tumors. Over the past several years, less invasive STA-MCA bypass techniques for surgical treatment of occlusive cerebrovascular disease have been gaining favor.[3,4,8,9,13] The use of a smaller scalp incision and craniotomy has reduced the surgical trauma associated with the procedure.

However, among patients with comorbidities, there exists a considerable population with severe systemic disease (such as COPD) who are predicted to be at high risk of postoperative complications associated with general anesthesia and positive pressure ventilation. Avoiding general anesthesia and mechanical ventilation would be another way to decrease the invasiveness of the STA-MCA bypass. Further simplifying and decreasing the invasiveness of STA-MCA bypass by performing this operation without endotracheal general anesthesia was believed to be feasible in certain subsets of patients.

This report describes our initial experiences in performing STA-MCA bypass using local anesthesia with a sedative instead of endotracheal general anesthesia. To the best of our knowledge, this is the first clinical series in which local anesthesia with a sedative was used for STA-MCA bypass.

Abbreviations used in this paper: BP = blood pressure; CAD = coronary artery disease; COPD = chronic obstructive pulmonary disease; CVR = cerebrovascular reserve; FEV_1 = forced expiratory volume in 1 second; ICA = internal carotid artery; ^{123}I-IMP = *N*-isopropyl-*p*-[^{123}I]iodoamphetamine; MCA = middle cerebral artery; rCBF = regional cerebral blood flow; STA = superficial temporal artery; TIA = transient ischemic attack.

Methods

Patient Selection

During the 20-month period between February 2010 and September 2011, patients with symptomatic cerebrovascular disease were prospectively enrolled in this study. The patient selection criteria included the following: 1) ischemic neurological symptoms such as TIA or minor completed stroke; 2) hemodynamically significant occlusive cerebrovascular disease in the MCA territory (resting rCBF < 90% of the normal value and CVR capacity < 15% on acetazolamide challenge using ^{123}I-IMP SPECT); 3) pulmonary dysfunction such as COPD or other multiple systemic comorbidities; 4) ≥ 20 years of age; and 5) no cognitive deficits and cooperation with the study. The Global Initiative for Chronic Obstructive Lung Disease (GOLD) classification system[18] was used to assess COPD as follows: 0 = normal spirometry; I = mild (FEV_1% < 70% and FEV_1 ≥ 80% predicted); and II = moderate (FEV_1% < 70% and 80% > FEV_1 ≥ 50% predicted). Coronary artery disease was graded according to the New York Heart Association (NYHA) classification system as follows:[6] I = mild, II = mild to moderate.

The exclusion criteria for this study were: 1) patient refusal; 2) severe obesity (body mass index ≥ 40%); 3) significantly impaired cardiac dysfunction (ejection fraction < 40% on echocardiography; and 4) significantly impaired lung function (flow volume < 50% or FEV_1 < 50%). The presence of diabetes, chronic renal failure, advanced age, or any other comorbidities did not affect patient selection. Full written informed consent was obtained in all patients. Institutional Review Board approval was not required for this study.

Preoperative Examinations

Patients were selected as candidates for STA-MCA bypass using MR imaging/angiography, 3D CT angiography, and SPECT with acetazolamide challenge. Conventional angiography is not routinely used for preoperative evaluation.

A 3D CT angiogram used for preoperative planning of a craniotomy was obtained with a 16-channel multidetector-row spiral CT scanner (Ultra Light Speed, GE Medical Systems) and a slice thickness of 0.6 mm to target a recipient and a donor artery. The original images of the 3D CT angiography principally described only arteries, because the timing of the scanning was chosen to demonstrate the arteries in each patient individually. On the original 3D CT angiography images, the closest point of the appropriate donor branch of the STA, and the most suitable recipient M_3 or M_4 segment of the MCA with a diameter of approximately 1 mm, could be identified within the scalp and on the brain surface, respectively. This segment provided both the donor (Fig. 1 upper, *arrow*) and recipient arteries (Fig. 1 upper, *arrowhead*) for STA-MCA bypass. This segment could be considered as the center of a minicraniotomy, and the distance between this segment of the donor artery and the rostral attachment of the ear was calculated (Fig. 1 lower).

Sedation, Local Anesthesia, and Monitoring

All patients received dexmedetomidine as the sole sedative agent, together with scalp-blocking local anesthesia and intravenous bolus administration of buprenorphine (0.4 mg) for analgesia. Dexmedetomidine was started with an initial dose of 1 μg/kg for 10 minutes and followed by infusions of 0.2–0.7 μg/kg/hr, which were continued throughout the procedures.

Spontaneous ventilation was preserved, and no endotracheal tube or laryngeal mask airway was used. Oxygen (50%) was administered via a facial mask (GE Healthcare) at 4–5 L/minute. Monitoring consisted of electrocardiography, heart rate, systolic and diastolic BP, respiratory rate, percutaneous O_2 saturation, and end-tidal CO_2. An arterial catheter was inserted into the radial artery for BP monitoring and blood sampling. Data including the systolic and diastolic BP, heart rate, percutaneous O_2 saturation, and end-tidal CO_2 were recorded every 5 minutes.

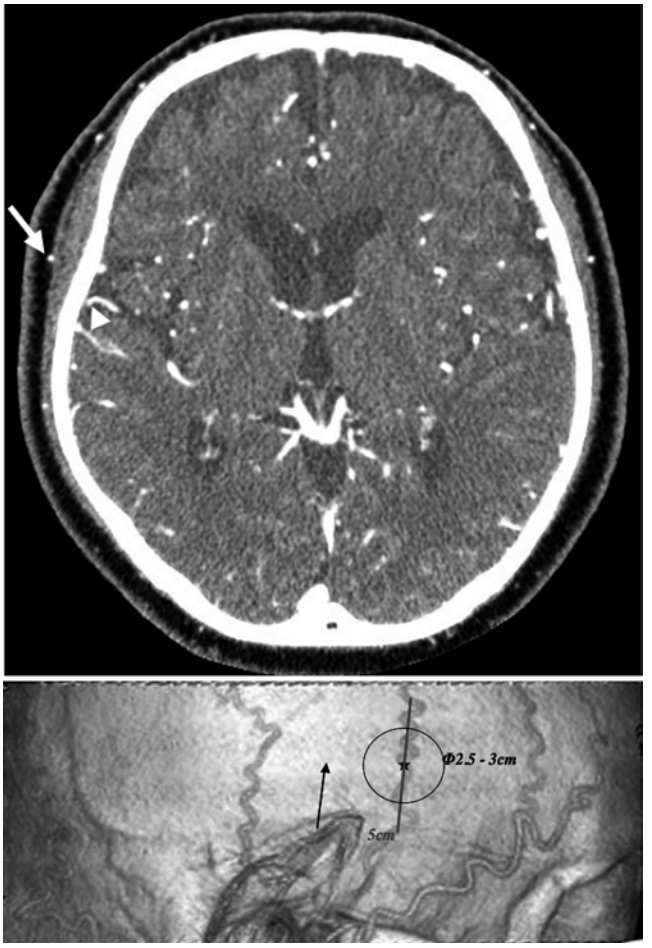

Fig. 1. Case 4. **Upper:** The 3D CT angiogram demonstrates a parietal branch of the STA within the scalp and a cortical artery on the brain surface. The most suitable segment of both the artery provided as the donor *(arrow)* and the recipient *(arrowhead)* arteries for extracranial-intracranial bypass is demonstrated. The distance between the previously noted segment of the donor artery and the superior border of the helix can be calculated. **Lower:** The image of the craniotomy is shown superimposed on the skull image of the preoperative 3D CT angiogram. The *star* indicates the previously noted segment of the donor artery as the center of the craniotomy. The *arrow* indicates the distance between the segment of the donor artery and the rostral attachment of the ear.

No pin fixation was applied, but each patient's head was fixed with a pillow adjusted to fit its shape (Fig. 2 left). All patients received local anesthetic infiltration immediately after induction of the sedative before surgery: first to the superficial layer of the preselected scalp incision line on the STA, then as a circular scalp block around the scalp incision line throughout the entire thickness of the scalp, and finally to the temporal muscle, with approximately 35–40 ml of a combined solution of 2% lidocaine and 0.25% bupivacaine (Fig. 2 right).

Surgical Technique

The surgical technique used proceeded in the following steps. First, a 5-cm linear skin incision on the preselected segment of the parietal or frontal branch of the STA was made, and the center of this branch was the point measured on preoperative 3D CT angiography (Fig. 3A). The temporal muscle was divided in the same fashion, and a 2.5- to 3-cm small craniotomy was performed (Fig. 3B). The dura was opened in a cruciate fashion in the center of the craniotomy. The recipient artery could be identified at the center of the craniotomy (Fig. 3C). End-to-side anastomosis was performed in the usual fashion (Fig. 3D). Two anchoring sutures at the apices of the incision and an additional 10 interrupted sutures were placed with 10-0 nylon sutures. The dura was loosely closed, and the bone flap was replaced with titanium plates. The temporal muscle and subcutaneous tissue were reapproximated with absorbable sutures layer by layer, and surgical tape was applied to the surface of the scalp.

Postoperative Examinations

We conducted postoperative examinations using MR imaging/angiography and/or 3D CT angiography, and SPECT with acetazolamide challenge.

Results

Ten patients with symptomatic cerebrovascular disease were prospectively enrolled in this study and underwent STA-MCA bypass using local anesthesia and a sedative without general anesthesia. (By contrast, during the same time interval as the study, another 13 patients underwent STA-MCA bypass after induction of general anesthesia.) Of the 10 patients in this study, 9 were male and 1 was female, and their ages ranged from 62 to 84 years (mean 72.5 years; Table 1). Four of the patients had COPD: 2 patients with Stage I (mild), and 2 with Stage II (moderate), according to the Global Initiative for Chronic Obstructive Lung Disease classification. Seven patients had CAD: 4 with Class I (mild), and 3 with Class II (mild to moderate), according to the New York Heart Association classification. Six patients had diabetes mellitus, and all 10 had hypertension. Five of the patients had suffered minor completed strokes, and another 5 patients had suffered a TIA. All stroke patients had favorable functional recovery (modified Rankin Scale disability score of 0 or 1). All operations were performed by the same surgeon (Y.K.).

Successful STA-MCA bypass surgeries were achieved via a preselected minimally invasive approach in all cases. Subsequent enlargement of the craniotomy was not necessary. Each aspect of the operation was well tolerated by the patients, including scalp incision and craniotomy, as well as arterial anastomosis.



Fig. 2. Case 4. Intraoperative photographs of the anesthesia procedure. **Left:** The head of the patient is fixed with an adjustable pillow, and the airway is left unsecured. **Right:** A sufficient amount of local anesthesia (35–40 ml of a combined solution of 2% lidocaine and 0.25% bupivacaine) is first infiltrated to the superficial layer of the preselected scalp incision line on the STA, then as a circular scalp block around the scalp incision line throughout the entire thickness of the scalp, and finally to the temporal muscle.

There was good hemodynamic stability throughout the surgery (Table 2). Patients' BP and heart rate were maintained within 20% of the initial values. There were no episodes of bradycardia (defined as less than 45 beats per minute) or hypotension (defined as systolic arterial pressure of less than 100 mm Hg). No airway or ventilation complications occurred, and no patients were converted to general anesthesia. Oxygen saturation levels were maintained between 99% and 100% in all patients throughout the procedure. End-tidal CO_2 was maintained within 25% of the initial value, although a mild accumulation of CO_2 was noted. The duration of the whole procedure ranged from 121 to 151 minutes (mean 134 minutes). The lack of endotracheal general anesthesia and muscle paralysis did not compromise the quality of the anastomoses.

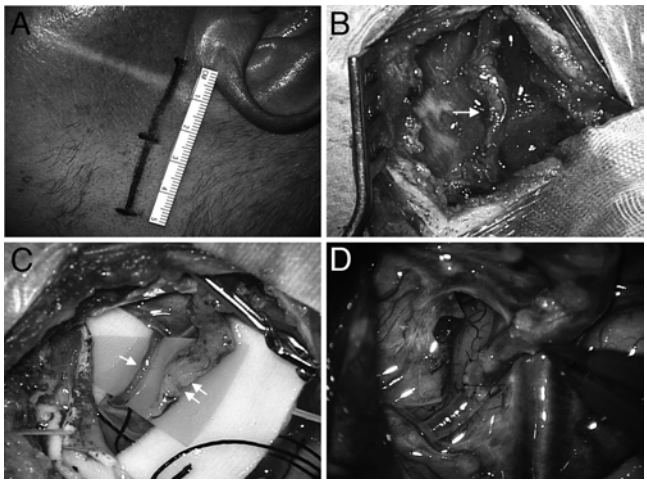

Fig. 3. Case 4. Intraoperative photographs of the surgical procedure. **A:** A 5-cm linear skin incision is made over the parietal branch of the STA, the center of which was the point that was measured on the preoperative 3D CT angiogram. **B:** The donor artery, which is the parietal branch of the STA *(arrow)*, is dissected. **C:** The recipient artery *(single arrow)* can be identified at the center of the craniotomy. The *double arrow* indicates the donor artery. **D:** The end-to-side anastomosis is completed using interrupted sutures.

TABLE 1: Summary of patients undergoing STA-MCA bypass using local anesthesia and a sedative*

Case No.	Age (yrs), Sex	Disease Onset Symptom	Occlusive Cerebrovascular Disease	Comorbidity†		
				COPD Stage	CAD Class	DM
1	84, M	TIA	lt MCA tandem stenosis	0	I	no
2	62, M	minor completed stroke	rt ICA occlusion & lt ICA near occlusion	II	no CAD	yes
3	80, M	minor completed stroke	bilat ICA occlusion	II	II	no
4	73, M	minor completed stroke	rt ICA occlusion & lt ICA stenosis	0	I	yes
5	65, M	minor completed stroke	lt MCA occlusion	I	no CAD	no
6	65, F	TIA	lt MCA occlusion	0	I	yes
7	80, M	minor completed stroke	rt ICA occlusion	0	II	yes
8	70, M	TIA	bilat ICA occlusion & lt VA occlusion	0	II	yes
9	70, M	TIA	lt MCA occlusion	I	no CAD	no
10	76, M	TIA	rt ICA occlusion	0	I	yes

* DM = diabetes mellitus; VA = vertebral artery.
† All patients had hypertension.

The perioperative course of the patients was uneventful. There was no perioperative morbidity or death. All patients were highly satisfied with the procedure, and they discussed their positive experience with this new technique. All patients have remained symptom free and returned to normal daily life following the operation. The mean follow-up period was 11.8 months (range 2–21 months). In all patients, postoperative MR angiography confirmed patent anastomoses, and the improvement of rCBF was confirmed on postoperative SPECT.

Illustrative Case

Case 4

This 73-year-old man presented with a minor completed stroke and transient left hemiparesis 6 months prior to the operation. Magnetic resonance imaging revealed a small cortical infarction in the right frontal lobe. Magnetic resonance angiography demonstrated a right ICA occlusion with stenosis of the right proximal A_1 segment of the anterior cerebral artery (Fig. 4A), and also with moderate stenosis of the left proximal ICA (Fig. 4B). ^{123}I-IMP SPECT demonstrated a resting rCBF decreased to 80% of the normal value and a CVR capacity decreased to 10% in the right MCA territory (Fig. 4C). The patient had diabetes mellitus, hypertension, and CAD. These findings suggested that the patient might be a potential candidate for STA-MCA bypass under local anesthesia. A 3D CT angiogram was used for preoperative planning of the craniotomy. Immediately after the induction of the sedative (dexmedetomidine) and intravenous bolus administration of the analgesic (0.4 mg of buprenorphine) before surgery, he received a sufficient scalp infiltration of local anesthesia, using 40 ml of a combined solution of 2% lidocaine and 0.25% bupivacaine.

An STA-MCA bypass was performed through a target minicraniotomy using the previously noted technique. The patient tolerated the operation well and was highly satisfied with the results. He was discharged on postop-

TABLE 2: Summary of intraoperative respiratory and hemodynamic variables and other events*

Case No.	Percutaneous O_2 Saturation (%)	End-Tidal CO_2 (mm Hg)		Systolic BP (mm Hg)		Heart Rate (beats/min)		Patient Movement	Operative Duration (min)
		Preop	High/Low Value	Preop	High/Low Value	Preop	High/Low Value		
1	99–100	49	58/41	135	145/105	55	55/48	no	126
2	99–100	45	46/40	150	166/115	70	70/50	no	151
3	99–100	29	31/29	140	160/120	55	75/50	yes	138
4	99–100	28	33/27	150	150/105	70	70/60	no	139
5	99–100	31	36/30	150	150/125	50	65/48	no	143
6	100	35	47/35	165	180/150	50	55/45	no	124
7	100	44	46/40	165	175/120	45	65/45	no	126
8	100	47	57/43	170	170/120	70	100/60	no	124
9	100	45	56/44	130	130/105	65	80/65	no	121
10	100	45	56/37	155	180/130	70	100/65	no	148

* High/Low Value = the highest and the lowest value during the operation; Operative Duration = time from the first skin incision until skin closure.

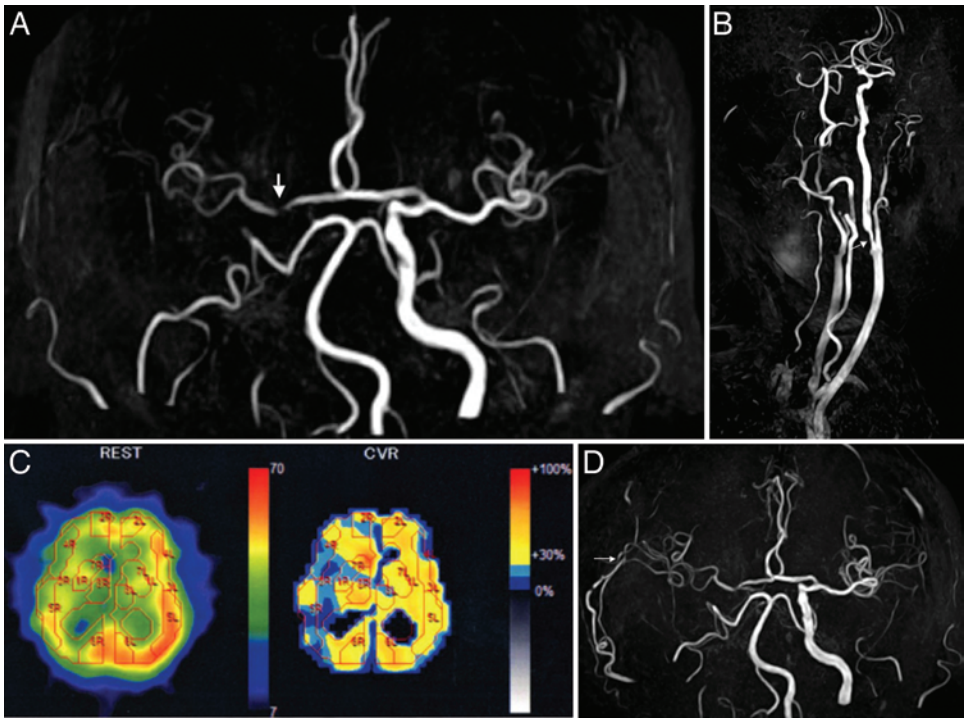

Fig. 4. Case 4. **A:** Preoperative MR angiogram demonstrating the right ICA occlusion with stenosis of the right proximal A_1 segment of the anterior cerebral artery *(arrow)*. **B:** Magnetic resonance angiography demonstrating moderate stenosis of the left proximal ICA *(arrow)*. **C:** ^{123}I-IMP SPECT demonstrating a resting rCBF decreased to 80% of the normal value *(left)* and a CVR capacity decreased to 10% in the right MCA territory *(right)*. **D:** Postoperative MR angiography confirming the patency of the STA-MCA bypass. The *arrow* indicates the anastomotic site.

erative Day 7 after an uneventful postoperative course. Postoperative MR angiography confirmed the patency of the STA-MCA bypass (Fig. 4D), and the improvement of rCBF was confirmed by postoperative SPECT.

Discussion

The STA-MCA bypass was first applied in the treatment of occlusive cerebrovascular disease in 1967 by Yaşargil.[24] This surgical technique remained an important tool in the neurosurgeon's armamentarium for the management of occlusive cerebrovascular disease, moyamoya disease, cerebral aneurysms, and skull base tumors. There was a demonstrable reversal of misery perfusion and marked improvement in the rCBF and cerebral metabolism in the subpopulation of patients with hemodynamic impairment who had undergone STA-MCA bypass.

While STA-MCA bypass is known for its relatively low rate of perioperative complications, procedures to reduce anesthetic or surgical mortality and morbidity during this bypass have continually evolved and new strategies have been advocated. Recently, less invasive STA-MCA bypass techniques for surgical treatment of occlusive cerebrovascular disease have been gaining favor.[3,4,8,9,13] The use of smaller scalp incisions and craniotomies have reduced the surgical trauma related to the procedure. The conventional STA-MCA bypass technique, however, cannot solve the problems associated with general anesthesia and positive pressure ventilation. Among patients with comorbidities, there exists a considerable population with severe systemic disease, such as pulmonary dysfunction, who are predicted to be at high risk of postoperative complications associated with general anesthesia and positive pressure ventilation. For these high-risk cases, avoiding general anesthesia and mechanical ventilation appears to be another way to decrease the invasiveness and risk of the STA-MCA bypass.

Recent studies on conscious sedation compared with general anesthesia during endovascular therapy for acute anterior circulation stroke showed that intraarterial therapy patients undergoing conscious sedation may have improved outcomes and lower mortality in comparison with patients undergoing general anesthesia.[1,7] The effects of the medications used for general anesthesia versus conscious sedation on the CNS may have an impact on the procedural outcomes. There was a significant variation in BP during the induction of anesthesia, especially hypotension, resulting in a more rapid incorporation of the penumbra into the core. In addition, agents used for general anesthesia, especially gases, are known to have vasodilator properties that can trigger the steal phenomenon, with steal of blood from the affected to the unaffected brain territories, thus further compromising the flow in the ischemic vascular bed. The effects of all of these changes may result in decreased cerebral perfusion, the potentiation of ischemic injury, and the possibility of direct neuronal toxicity.

It has been suggested that performing the operation under local anesthesia, rather than general anesthesia, may be safer. The potential benefits of local anesthesia

in a wider range of surgical procedures are supported by an overview of randomized trials of spinal and epidural anesthesia versus general anesthesia.[5,19] The overall mortality rate was reduced by about one-third in the patients allocated to a neuraxial block. Furthermore, neuraxial blockade reduced the odds of deep vein thrombosis by 44%, pulmonary embolism by 55%, pneumonia by 39%, and respiratory depression by 59% (all $p < 0.001$). A reduction also occurred in myocardial infarction and renal failure. The benefits observed for neuraxial blockade may be conferred by multifactorial mechanisms, including an improved ability to breathe, altered coagulation, increased blood flow, and a reduction in surgical stress responses.

Awake cardiac surgery was first described in 2000 in an article by Karagöz et al.,[10] in which a coronary artery bypass graft was performed in awake patients without general anesthesia using only thoracic epidural anesthesia. The awake coronary artery bypass graft is now a well-established technique, and it is known to decrease the adverse side effects typically associated with general anesthesia and mechanical ventilation.[11,14,16,17,23]

Awake craniotomies have traditionally been performed for epilepsy surgery and neurooncological operations for tumors involving the eloquent cortex.[12,20] With the development of improved anesthetic techniques and more sophisticated neuronavigation equipment, awake craniotomy has become a fast, safe, and effective procedure with good patient tolerance.[2]

We proceeded with our minimally invasive STA-MCA bypass with local anesthesia to determine whether it was possible to avoid the risks of general anesthesia and mechanical ventilation for patients with hemodynamically compromised occlusive cerebrovascular disease, as well multiple comorbidities. The procedure was performed with the use of a local anesthetic agent in combination with a sedative. Spontaneous respiration was preserved, no endotracheal tube or laryngeal mask airway was used, and no skull fixation was adopted.

Our regional block technique of using a mixture of 0.25% bupivacaine and 2% lidocaine without epinephrine appeared to efficiently block the innervations of the scalp. Sufficient scalp infiltration of the 0.25% bupivacaine/2% lidocaine mixture provided both an immediate and long-lasting scalp-blocking effect. Bupivacaine, a popular local anesthetic, has a long duration of action, with an approximate half-life of 120 minutes when it is used in highly vascularized tissues such as the scalp.[15] We observed that this scalp block provides sufficient analgesia and is also an effective hemodynamic control throughout the procedure.

The patients received dexmedetomidine as the sole sedative agent, together with the scalp block. Dexmedetomidine is a lipophilic imidazole derivative, which acts as an α-2 agonist. It can induce anesthesia via its effect on the α-2a receptor subtype and has analgesic properties as well. Dexmedetomidine has a rapid onset of action and has a large volume of distribution with a consequent clinical effect half-life of 6 minutes and a clearance half-life of 2 hours.[22] It has little to no effect on respiration at clinically relevant doses and allows arousal from a state mimicking sleep to permit cognitive engagement and facilitate communication during diagnostic and surgical procedures, which renders it uniquely useful in its sedative profile. It has been used in a wide variety of clinical situations, including the provision of sedation in awake craniotomies.[21] Other beneficial qualities of dexmedetomidine were its effect on hemodynamic stability and its anxiolytic effect. As dexmedetomidine provides sedation that resembles natural sleep and a certain extent of analgesia without respiratory depression, this sedative may be a suitable agent for STA-MCA bypass under local anesthesia.

In our initial experience, there was good hemodynamic stability throughout surgery, and no airway/ventilation complications developed in any of our patients. The patients subjectively tolerated this technique well, with a high rate of satisfaction. These results might encourage a wider application of this technique to also include patients without significant comorbidities. This procedure did not compromise the quality of the anastomoses. However, the procedure is necessarily more delicate than traditional STA-MCA bypass because the working surgical field is much smaller and the anastomosis is therefore more difficult to achieve. As with all new techniques, many questions arise, such as the question of benefit for the patient (including improvement of outcome) and whether the procedure can decrease a patient's stress. Further studies are required to determine the safety and efficacy of this technique in comparison with conventional STA-MCA anastomosis under general anesthesia.

Conclusions

Our initial experience confirms the feasibility of performing STA-MCA bypass under local anesthesia with a sedative, thereby representing an alternative to performing the procedure under endotracheal general anesthesia. This method could be recommended specifically for patients with systemic comorbidities such as COPD.

Disclosure

The authors report no conflict of interest concerning the materials or methods used in this study or the findings specified in this paper.

Author contributions to the study and manuscript preparation include the following. Conception and design: Kaku. Acquisition of data: Kaku, Yamashita, Kokuzawa, Kanou. Analysis and interpretation of data: Kaku. Drafting the article: Kaku. Critically revising the article: all authors. Reviewed submitted version of manuscript: all authors. Approved the final version of the manuscript on behalf of all authors: Kaku.

References

1. Abou-Chebl A, Lin R, Hussain MS, Jovin TG, Levy EI, Liebeskind DS, et al: Conscious sedation versus general anesthesia during endovascular therapy for acute anterior circulation stroke: preliminary results from a retrospective, multicenter study. **Stroke 41:**1175–1179, 2010
2. Bilotta F, Rosa G: 'Anesthesia' for awake neurosurgery. **Curr Opin Anaesthesiol 22:**560–565, 2009
3. Coppens JR, Cantando JD, Abdulrauf SI: Minimally invasive

superficial temporal artery to middle cerebral artery bypass through an enlarged bur hole: the use of computed tomography angiography neuronavigation in surgical planning. Technical note. **J Neurosurg 109:**553–558, 2008
4. Fischer G, Stadie A, Schwandt E, Gawehn J, Boor S, Marx J, et al: Minimally invasive superficial temporal artery to middle cerebral artery bypass through a minicraniotomy: benefit of three-dimensional virtual reality planning using magnetic resonance angiography. **Neurosurg Focus 26(5):**E20, 2009
5. Gough MJ, Bodenham A, Horrocks M, Colam B, Lewis SC, Rothwell PM, et al: GALA: an international multicentre randomised trial comparing general anaesthesia versus local anaesthesia for carotid surgery. **Trials 9:**28, 2008
6. Hunt SA, Abraham WT, Chin MH, Feldman AM, Francis GS, Ganiats TG, et al: ACC/AHA 2005 Guideline update for the diagnosis and management of chronic heart failure in the adult: a report of the American College of Cardiology/American Heart Association Task Force on Practice Guidelines. **Circulation 112:**e154–e235, 2005
7. Jumaa MA, Zhang F, Ruiz-Ares G, Gelzinis T, Malik AM, Aleu A, et al: Comparison of safety and clinical and radiographic outcomes in endovascular acute stroke therapy for proximal middle cerebral artery occlusion with intubation and general anesthesia versus the nonintubated state. **Stroke 41:** 1180–1184, 2010
8. Kaku Y, Watarai H, Kokuzawa J, Tanaka T, Andoh T: Less invasive technique for EC-IC bypass, in **13th European Congress of Neurosurgery.** Glasgow: MEDIMOND International Proceedings, 2007, pp 527–532
9. Kaku Y, Watarai H, Kokuzawa J, Tanaka T, Andoh T: Less invasive technique for EC-IC bypass. **Acta Neurochir Suppl 103:**83–86, 2008
10. Karagöz HY, Sönmez B, Bakkaloglu B, Kurtoglu M, Erdinç M, Türkeli A, et al: Coronary artery bypass grafting in the conscious patient without endotracheal general anesthesia. **Ann Thorac Surg 70:**91–96, 2000
11. Kessler P, Neidhart G, Bremerich DH, Aybek T, Dogan S, Lischke V, et al: High thoracic epidural anesthesia for coronary artery bypass grafting using two different surgical approaches in conscious patients. **Anesth Analg 95:**791–797, 2002
12. Khu KJ, Doglietto F, Radovanovic I, Taleb F, Mendelsohn D, Zadeh G, et al: Patients' perceptions of awake and outpatient craniotomy for brain tumor: a qualitative study. Clinical article. **J Neurosurg 112:**1056–1060, 2010
13. Kikuta K, Takagi Y, Fushimi Y, Ishizu K, Okada T, Hanakawa T, at al: "Target Bypass": a method for preoperative targeting of a recipient artery in superficial temporal artery-to-middle cerebral artery anastomoses. **Neurosurgery 62 (6 Suppl 3):** 1434–1441, 2008
14. Kurtoğlu M, Ateş S, Bakkaloğlu B, Beşbaş S, Duvan I, Akdaş H, et al: Epidural anesthesia versus general anesthesia in patients undergoing minimally invasive direct coronary artery bypass surgery. **Anadolu Kardiyol Derg 9:**54–58, 2009
15. Lee EJ, Lee MY, Shyr MH, Cheng JT, Toung TJK, Mirski MA, et al: Adjuvant bupivacaine scalp block facilitates stabilization of hemodynamics in patients undergoing craniotomy with general anesthesia: a preliminary report. **J Clin Anesth 18:**490–494, 2006
16. Lucchetti V, Moscariello C, Catapano D, Angelini GD: Coronary artery bypass grafting in the awake patient: combined thoracic epidural and lumbar subarachnoid block. **Eur J Cardiothorac Surg 26:**658–659, 2004
17. Noiseux N, Prieto I, Bracco D, Basile F, Hemmerling T: Coronary artery bypass grafting in the awake patient combining high thoracic epidural and femoral nerve block: first series of 15 patients. **Br J Anaesth 100:**184–189, 2008
18. Pauwels RA, Buist AS, Calverley PM, Jenkins CR, Hurd SS, GOLD Scientific Committee: Global strategy for the diagnosis, management, and prevention of chronic obstructive pulmonary disease. NHLBI/WHO Global Initiative for Chronic Obstructive Lung Disease (GOLD) Workshop summary. **Am J Respir Crit Care Med 163:**1256–1276, 2001
19. Rodgers A, Walker N, Schug S, McKee A, Kehlet H, van Zundert A, et al: Reduction of postoperative mortality and morbidity with epidural or spinal anaesthesia: results from overview of randomised trials. A review. **BMJ 321:**1493, 2000
20. Skucas AP, Artru AA: Anesthetic complications of awake craniotomies for epilepsy surgery. **Anesth Analg 102:**882–887, 2006
21. Souter MJ, Rozet I, Ojemann JG, Souter KJ, Holmes MD, Lee L, et al: Dexmedetomidine sedation during awake craniotomy for seizure resection: effects on electrocorticography. **J Neurosurg Anesthesiol 19:**38–44, 2007
22. Triltsch AE, Welte M, von Homeyer P, Grosse J, Genähr A, Moshirzadeh M, et al: Bispectral index-guided sedation with dexmedetomidine in intensive care: a prospective, randomized, double blind, placebo-controlled phase II study. **Crit Care Med 30:**1007–1014, 2002
23. Watanabe G, Yamaguchi S, Tomiya S, Ohtake H: Awake subxyphoid minimally invasive direct coronary artery bypass grafting yielded minimum invasive cardiac surgery for high risk patients. **Interact Cardiovasc Thorac Surg 7:**910–912, 2008
24. Yaşargil MG: **Microsurgery Applied to Neurosurgery.** Stuttgart: Georg Thieme, 1969, pp 105–115

Manuscript submitted November 2, 2011.
Accepted April 16, 2012.
Portions of this work were presented in abstract form at the 14th European Congress of Neurosurgery in Rome, Italy, on October 11, 2011.
Please include this information when citing this paper: published online May 25, 2012; DOI: 10.3171/2012.4.JNS111958.
Address correspondence to: Yasuhiko Kaku, M.D., Department of Neurosurgery, Asahi University Murakami Memorial Hospital, Hashimoto-cho 3-23, Gifu, Japan 500-8523. email: kaku@murakami.asahi-u.ac.jp.