ORIGINAL ARTICLE

Single-Incision Laparoscopic Cholecystectomy Using a Flexible Endoscope

Steven J. Binenbaum, MD; Julio A. Teixeira, MD; Glenn J. Forrester, MD; E. John Harvey, MD; John Afthinos, MD; Grace J. Kim, MD; Ninan Koshy, MD; James McGinty, MD; Scott J. Belsley, MD; George J. Todd, MD

Objective: To describe our experience with a single-incision laparoscopic cholecystectomy (SILC) performed using a flexible endoscope as the means of visualization and surgical dissection. The use of flexible endoscopy in intra-abdominal surgery has never been described.

Design: Prospective observational case series.

Patients: Eleven patients with symptomatic cholelithiasis were selected based on age, clinical presentation, body habitus, and history of previous abdominal surgery. Patients with acute or chronic cholecystitis were excluded.

Results: All procedures were completed laparoscopically via the single umbilical incision without the need to convert to an open operation and without introduction of any additional laparoscopic instruments or trocars. The mean operative time was 149.5 minutes (range, 99-240 minutes). The mean length of hospital stay was 0.36 days. There were no associated intraoperative or postoperative complications.

Conclusions: In our experience, SILC performed with a flexible endoscope is feasible and safe. Further studies are needed to determine its advantages in reference to postoperative pain and complication rate in juxtaposition with the current standard laparoscopic cholecystectomy.

Arch Surg. 2009;144(8):734-738

LAPAROSCOPIC CHOLECYSTECTOMY (LC) became the criterion standard in the treatment of symptomatic cholelithiasis[1,2] because it was associated with decreased postoperative pain, shorter length of hospital stay, fast return to physical activity and work, and overall greater patient satisfaction.[1-3] Its success and popularity among surgeons was also largely attributed to the decreased incidence of wound infections, incisional hernias, and pulmonary complications.[4-6] Despite these advantages, LC has its shortcomings. Significant complications associated with LC such as biliary tract injuries and a variety of trocar-related injuries have been described.[7-18] Whether reducing the number of trocars used during LC results in a decreased number of complications remains to be determined.

See Invited Critique at end of article

The technique of single-incision LC (SILC) has been previously described by other authors.[19-21] However, the techniques they applied used the standard laparoscopic instruments and laparoscopes. Those procedures were technically challenging and failed to gain widespread acceptance. In addition, Marescaux and colleagues[22] have reported on transvaginal natural orifice transluminal endoscopic surgery (NOTES) cholecystectomy, and several NOTES trials have begun. Although natural orifice surgery is less invasive and may result in less postoperative pain, thus far all reported cases have required some form of transabdominal laparoscopic assistance. Use of NOTES cholecystectomy has great potential, but its safety and efficacy has yet to be determined. To date however, no one has described a single-incision transumbilical cholecystectomy using a flexible endoscope as the means for visualization and surgical dissection.

We describe our experience with a SILC performed using a flexible endoscope as the means for visualization and surgical dissection. The use of flexible endoscopy in intra-abdominal surgery has never been described.

Author Affiliations:
Department of Surgery, St Luke's-Roosevelt Hospital Center, New York, New York.

Downloaded from www.archsurg.com at COLEGIO BRASILEIRO CIRURGIOES, on August 25, 2009
©2009 American Medical Association. All rights reserved.

METHODS

BACKGROUND

Prior to proceeding with SILC in humans, we underwent extensive training in the animal laboratory. Our first SILC operation on a human was performed in August 2007. Between then and February 2008, a total of 11 patients have undergone SILC under institutional review board–approved protocol 07-142. Patients were carefully selected based on subjective criteria such as age, clinical presentation, body habitus, and history of previous abdominal surgery. Patients with acute or chronic cholecystitis were excluded from this study. Since the beginning, the SILC technique has undergone a series of modifications. Certain aspects of the procedure remained constant throughout, while others were altered as we learned from our experience. We will attempt to describe each of these changes as they were introduced to give a sense of the evolution of the procedure.

OPERATIVE TECHNIQUE

After the administration of local anesthesia, a small (approximately 15-mm) skin incision is made in the infraumbilical region. The peritoneal cavity is entered using a 12-mm optical viewing trocar placed to the right of the umbilical stalk. The flexible endoscope is inserted through the 12-mm port, which is then retracted from the abdominal wall. A 5-mm trocar is then inserted through the same incision to the left of the umbilical stalk. Pneumoperitoneum is maintained through the 5-mm port. The surgeon performs the dissection by manipulating the control dials on the endoscope, and the first assistant maintains the position of the endoscope while retracting the gallbladder by grasping its fundus through the 5-mm port. A second assistant stands on the opposite side of the table and controls the flexible endoscopic instruments.

In our initial 3 cases, we used a right-angled operative laparoscope. Either electrocautery (hook or spatula) or the harmonic scalpel was used to dissect the gallbladder in a retrograde fashion from the liver bed. To expose the triangle of Calot, the gall bladder was retracted cephalad with a 2-0 nylon transabdominal suture introduced on a straight Keith needle. The suture was placed subcostally in the right upper quadrant.

In the remaining 9 cases, a flexible endoscope was used as a means of visualization and dissection. In these patients, dissection of the cystic duct and artery was performed bluntly using an endoscopic rat-toothed forceps and biopsy forceps. The cystic duct was ligated with standard laparoscopic endoclips (5-mm), and the cystic artery was ligated and divided with either endoclips or a Harmonic scalpel. As the last step, the gallbladder was removed through the umbilicus in an EndoCatch bag (Covidien, Mansfield, Massachusetts) and the fascia was closed with interrupted 0 Vicryl sutures (Ethicon Inc, Somerville, New Jersey).

During the initial 3 cases, we encountered several technical challenges. The rigid operative laparoscope narrowed our field of view and greatly restricted our range of motion. To overcome these challenges we performed all of the subsequent operations with either a single- or double-channel flexible endoscope (KARL STORZ GmbH & Co KG, Tuttlingen, Germany and Olympus America, Inc, Center Valley, Pennsylvania). The introduction of a flexible endoscope led to a number of other modifications to our technique and added new instruments:

- Hydro-dissection with subserosal saline injection
- Partial dissection of the gall bladder dome from the liver edge
- Flexible endoscopic tools
- Flexible high-dexterity laparoscopic instruments (Novare Surgical Systems, Cupertino, California)

We used an endoscopic needle to inject saline medially and laterally between the gall bladder and the liver bed, similar to the endoscopic mucosal resection technique. Hydrostatic saline pressure partially separated the gall bladder surface from the liver, allowing access to a wide target area for dissection.

To overcome the challenges of liver retraction, the technique of retrograde gall bladder dissection was modified. The dome of the gall bladder was only partially freed from its attachments to the liver to allow retraction and expose the hilar structures without having to lift the liver. Thereafter, following the ligation and division of the hilar structures, the remainder of the liver bed dissection proceeded in an antegrade fashion.

Instead of the standard laparoscopic instruments, the last 4 procedures were performed with the flexible laparoscopic instruments introduced through a 5-mm port. This greatly facilitated our dissection by providing a greater degree of freedom.

PATIENT CHARACTERISTICS

Most of our patients were female (11:1), with an average age of 33 years (range, 19-55 years). All had the symptoms and signs consistent with biliary colic and had undergone an ultrasonographic confirmation of cholelithiasis. Patients with any clinical or radiological evidence of acute or chronic cholecystitis were excluded from this study. The SILC procedure was performed on an elective basis on all the patients, except for the 2 patients who were admitted to the hospital by the emergency department for biliary colic. They were operated on within 24 hours of admission.

RESULTS

All procedures were completed laparoscopically via the single umbilical incision without the need to convert to an open operation and without introduction of any additional laparoscopic instruments or trocars. The mean operative time was 149.5 minutes (range, 99-240 minutes). Seven patients (64%) went home on the day of surgery. Four patients were admitted to the hospital. Two patients were admitted overnight, as their procedures ended late in the evening. They were discharged in the morning on their postoperative day 1. The other 2 patients were admitted by the emergency department in the evening prior to surgery. The mean length of hospital stay was 0.36 days. There were no associated intraoperative or postoperative complications.

COMMENT

Laparoscopic cholecystectomy has become the criterion standard for the treatment of symptomatic gallstone disease.[1,2] The advantages of LC, such as decreased postoperative pain, shorter length of hospital stay, faster return to normal physical activity, and lower incidence of wound infections and incisional hernias make this a more desirable procedure.[1-6] In addition, according to Zacks et al,[7] the mortality rate associated with LC is significantly less than that of the open procedure. On the other hand, there are also many articles in the surgical literature emphasizing the significance of trocar-related complications during LC that can result in severe morbidity and higher mortality.[11,12,14-18] However, with increased experience in performing LC and improvement in tech-

Downloaded from www.archsurg.com at COLEGIO BRASILEIRO CIRURGIOES, on August 25, 2009
©2009 American Medical Association. All rights reserved.

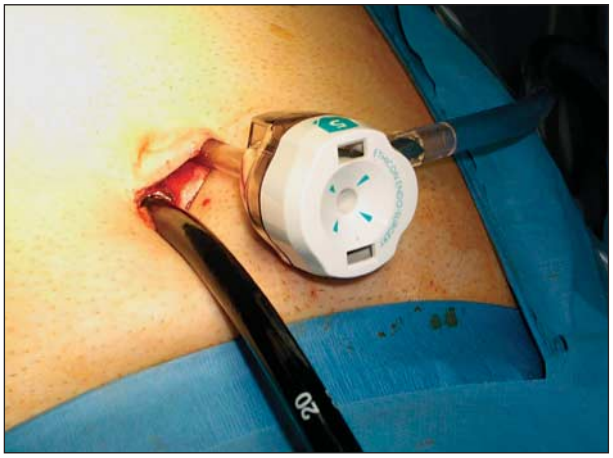

Figure 1. Flexible endoscope (right), with 5-mm trocar positioned on the left side of the incision.

nique, the incidence of complications has substantially decreased. Nevertheless, investigators continue to pursue the development of less invasive techniques such as 2-port cholecystectomy and transvaginal or transgastric NOTES cholecystectomy, which require fewer and smaller-caliber trocars.[23-25]

Studies of LC performed with fewer ports than the traditional four-port technique for the removal of the gallbladder first appeared in the literature approximately 10 years ago.[19-21,26] Navarra et al[19] described a small series of patients who had LC using only 2 trocars introduced through an umbilical incision. They gained exposure with 3 transabdominal sutures that were passed through the gallbladder to assist with exposure. We used a similar technique with only 1 suture. Piskun et al[20] and, most recently, Cuesta et al[21] devised a modified technique of LC using 2 transumbilical trocars in an attempt to reduce operative trauma and improve cosmetic results. Unfortunately, these advantages were difficult to reproduce because of instrument limitations, decreased range of motion, and longer operative times. As a result they have not been widely accepted nor included in the scope of the current surgical practice.

The development of NOTES may one day lead to painless surgery without abdominal incisions and minimal surgical trauma. Although several human NOTES trials have begun, to date no NOTES cholecystectomy series has been reported. Reddy and Rao[27] first described their transgastric appendectomy experience in 2004. Since then, Marescaux and colleagues[22] described transvaginal cholecystectomy in 2007. It was performed through a small incision in the posterior vaginal cul-de-sac with a double-channel flexible gastroscope and a 2-mm transabdominal needle port. However, before the potential advantages of natural orifice surgery can be appreciated, several obstacles must first be overcome such as limitations of endoscopic instruments, lack of triangulation, and unsafe gastrotomy closure. Flexible endoscopes and instruments were not designed for intra-abdominal surgery. Current limitations include the lack of precise translation of force to accomplish basic surgical tasks such as traction–counter-traction. Furthermore, the design of a flexible endoscope does not allow for triangulation and provides an unstable platform for surgical activity. Lastly, as there is no method yet developed to accurately monitor the insufflating pressures, every NOTES procedure requires percutaneous transabdominal assistance in the form of additional laparoscopic ports. Therefore, clinical advantages of NOTES are difficult to demonstrate vis-à-vis single port/incision approach. Thus, the benefits of NOTES cholecystectomy must be further evaluated within the confines of institutional review board protocols.

Single-incision LC is a hybrid procedure similar to NOTES cholecystectomy in that it uses a flexible endoscope and 5-mm transabdominal port (**Figure 1**). Unlike NOTES, however, there is no operative trauma to the hollow viscus, as sustained during the transluminal method of access, eliminating the need for closure. On the other hand, SILC is similar to LC in that we used analogous methods to ligate and divide the cystic duct and artery. In our experience, SILC resulted in reduced pain and an excellent cosmetic result. In our series we did not objectively compare the decrease in postoperative pain vs traditional LC, as this was a safety and feasibility study only. The reduction of postoperative pain is a subjective observation, and whether reducing the number of trocars results in decreased postoperative pain or has any clinical significance remains to be determined. However, our observations indicate that there appears to be a decrease in pain in the immediate postoperative period. Cosmetically, SILC required only a single 15-mm incision that was barely visible within the umbilicus (**Figure 2**). Although the skin incision is 15 mm in length, the fascial incision is much smaller. Fascia needs a snug fit around the flexible endoscope to prevent an air leak during the procedure. Such an incision should not increase the risk of an incisional hernia.

In this small series, there were no intraoperative or postoperative complications. However, as the volume and the number of surgeons performing SILC procedure increases, potential new complications may arise. Therefore, the safety of SILC cholecystectomy is not yet able to be established. During SILC, the instruments and the 5-mm port pass through the same incision and are always in the direct field of vision, thereby decreasing the risk of iatrogenic injury.

Our approach to LC using a single umbilical incision and a flexible endoscope has not been described in surgical literature to date. Our technique underwent a series of evolutionary changes as our experience grew. At first we used a right-angled rigid operative laparoscope that was inserted through the same umbilical incision as the 5-mm trocar. Cuesta et al[21] used a similar technique using a 5-mm rigid 30° laparoscope. The rigidity of the instruments, however, did not allow triangulation and limited our field of view. Unidirectional movement of the instruments also limited transabdominal organ manipulation and traction–counter traction maneuvers. Working with the flexible endoscope proved to have several advantages over the rigid scope. The flexible endoscope was ergonomically easier to maneuver and provided excellent image quality. Also, the flexibility of the endoscope increased the degree of freedom of movement during the dissection. Another surprising advantage was that the endoscope did not have to be removed from the ab-

Downloaded from www.archsurg.com at COLEGIO BRASILEIRO CIRURGIOES, on August 25, 2009
©2009 American Medical Association. All rights reserved.

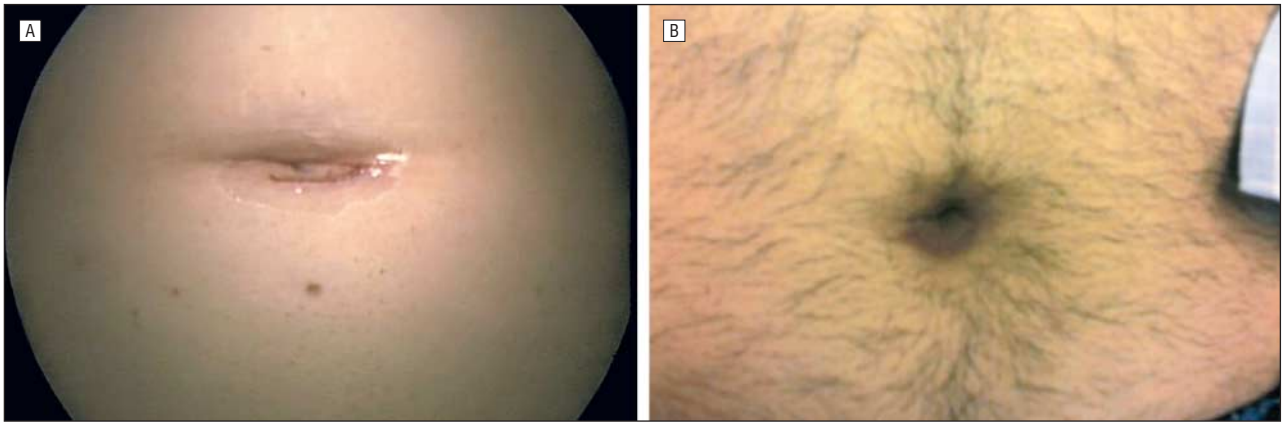

Figure 2. Incision on postoperative day 0 (A) and 3 months after operation (B).

dominal cavity to clean the lens. Although introduction of the flexible endoscope had its benefits, it also presented certain disadvantages, such as an unstable surgical platform that required multiple operators manipulating the endoscope and controlling the wheels in conjunction with endoscopic instruments. Triangulation was still very limited, but it was improved between the 5-mm laparoscopic instruments and the biopsy channels. To further enhance triangulation and exposure of the structures, we began to use the high-dexterity flexible laparoscopic instruments. This allowed additional freedom of movement during the dissection and enabled better tissue manipulation, which was not possible with rigid laparoscopic instruments. Another important consideration is that the flexible endoscopes were not designed for use in the sterile environment of the operating room. There is no reliable method that assures effective sterilization. Current devices such as Steris system 1, steam, plasma gas, and ethylene oxide autoclaves operate at higher than 50°C, which could damage the endoscopes. Handling of the endoscope on the operating field is also somewhat cumbersome. The cable connecting the endoscope to the video processor and a light source is short, rendering it ergonomically difficult. Flushing the scope with sterile water that comes from an unsterile irrigation container creates breaks in sterility.

Our operative times were longer than historic cohorts in literature. This may be attributed to a steep learning curve. However, our operative times have consistently decreased as our experience increased.

One of the benefits of performing SILC is that it provides the opportunity to develop the skills needed for NOTES. The ability to perform SILC allows us to participate in NOTES research and help develop new operative methods and techniques in using flexible endoscopic instruments in the intraabdominal environment. Although NOTES cholecystectomy has great potential, it still has significant barriers to safety related to closure of the stomach, vagina, colon, and other potential access sites. The question that needs to be addressed is whether SILC is a competitive or complementary procedure to NOTES cholecystectomy.

As long as SILC is performed with rigid laparoscopic instruments, it will be challenged by the outcomes of standard LC. However, with the introduction of flexible endoscopic instrumentation, SILC may assume a complementary role as an alternative procedure to NOTES until the safety of NOTES is firmly established. In our view, SILC is a less invasive form of LC and may serve as a transition between laparoscopy and natural orifice surgery.

In our experience, SILC performed with the flexible endoscope is feasible and safe. Further studies are needed to determine its advantages in reference to postoperative pain and complication rate in juxtaposition with the current standard LC. Flexible endoscopy can be a safe and effective tool in performing laparoscopic abdominal procedures. However, the use of this technique warrants further investigation.

Submitted for Publication: April 3, 2008; final revision received May 30, 2008; accepted June 2, 2008.
Correspondence: Julio A. Teixeira, MD, 1090 Amsterdam Ave, Side 10A, New York, NY 10025 (jteixeira@chpnet.org).
Author Contributions: *Study concept and design:* Teixeira, Forrester, Harvey, and Koshy. *Acquisition of data:* Binenbaum, Teixeira, Forrester, Harvey, Afthinos, Kim, Koshy, McGinty, Belsley, and Todd. *Analysis and interpretation of data:* Binenbaum, Teixeira, Forrester, Harvey, and Koshy. *Drafting of the manuscript:* Binenbaum, Teixeira, Forrester, Harvey, Afthinos, Koshy, and Belsley. *Critical revision of the manuscript for important intellectual content:* Binenbaum, Teixeira, Harvey, Kim, McGinty, and Todd. *Statistical analysis:* Harvey. *Administrative, technical, and material support:* Binenbaum, Forrester, Harvey, Afthinos, and Belsley. *Study supervision:* Teixeira, Harvey, and Koshy.
Financial Disclosure: None reported.

REFERENCES

1. Lichten JB, Reid JJ, Zahalsky MP, Friedman RL. Laparoscopic cholecystectomy in the new millennium. *Surg Endosc.* 2001;15(8):867-872.
2. Sarli L, Pietra N, Sansebastiano G, et al. Reduced postoperative morbidity after elective laparoscopic cholecystectomy: stratified matched case-control study. *World J Surg.* 1997;21(8):872-878, discussion 879.
3. Kum CK, Wong CW, Goh PM, Ti TK. Comparative study of pain level and analgesic requirement after laparoscopic and open cholecystectomy. *Surg Laparosc Endosc.* 1994;4(2):139-141.

Downloaded from www.archsurg.com at COLEGIO BRASILEIRO CIRURGIOES, on August 25, 2009
©2009 American Medical Association. All rights reserved.

4. Boni L, Benevento A, Rovera F, et al. Infective complications in laparoscopic surgery. *Surg Infect (Larchmt).* 2006;7(suppl 2):S109-S111.
5. den Hoed PT, Boelhouwer RU, Veen HF, Hop WC, Bruining HA. Infections and bacteriological data after laparoscopic and open gallbladder surgery. *J Hosp Infect.* 1998;39(1):27-37.
6. Sanz-López R, Martínez-Ramos C, Núñez-Peña JR, Ruiz de Gopegui M, Pastor-Sirera L, Tamames-Escobar S. Incisional hernias after laparoscopic vs open cholecystectomy. *Surg Endosc.* 1999;13(9):922-924.
7. Zacks SL, Sandler RS, Rutledge R, Brown RS Jr. A population-based cohort study comparing laparoscopic cholecystectomy and open cholecystectomy. *Am J Gastroenterol.* 2002;97(2):334-340.
8. Ress AM, Sarr MG, Nagorney DM, Farnell MB, Donohue JH, McIlrath DC. Spectrum and management of major complications of laparoscopic cholecystectomy. *Am J Surg.* 1993;165(6):655-662.
9. Roviaro GC, Maciocco M, Rebuffat C, et al. Complications following cholecystectomy. *J R Coll Surg Edinb.* 1997;42(5):324-328.
10. Massoumi H, Kiyici N, Hertan H. Bile leak after laparoscopic cholecystectomy. *J Clin Gastroenterol.* 2007;41(3):301-305.
11. Saville LE, Woods MS. Laparoscopy and major retroperitoneal vascular injuries (MRVI). *Surg Endosc.* 1995;9(10):1096-1100.
12. Geraci G, Sciume C, Pisello F, Li Volsi F, Facella T, Modica G. Trocar-related abdominal wall bleeding in 200 patients after laparoscopic cholecystectomy: personal experience. *World J Gastroenterol.* 2006;12(44):7165-7167.
13. Binenbaum SJ, Goldfarb MA. Inadvertent enterotomy in minimally invasive abdominal surgery. *JSLS.* 2006;10(3):336-340.
14. Corson SL, Chandler JG, Way LW. Survey of laparoscopic entry injuries provoking litigation. *J Am Assoc Gynecol Laparosc.* 2001;8(3):341-347.
15. Schafer M, Lauper M, Krahenbuhl L. Trocar and Veress needle injuries during laparoscopy [published online ahead of print December 12, 2000]. *Surg Endosc.* 2001;15(3):275-280.
16. Orlando R, Palatini P, Lirussi F. Needle and Trocar injuries in diagnostic laparoscopy under local anesthesia: what is the true incidence of these complications? *J Laparoendosc Adv Surg Tech A.* 2003;13(3):181-184.
17. Hashizume M, Sugimachi K. Needle and trocar injury during laparoscopic surgery in Japan. *Surg Endosc.* 1997;11(12):1198-1201.
18. Bhoyrul S, Vierra MA, Nezhat CR, Krummel TM, Way LW. Trocar injuries in laparoscopic surgery. *J Am Coll Surg.* 2001;192(6):677-683.
19. Navarra G, Pozza E, Occhionorelli S, Carcoforo P, Donini I. One-wound laparoscopic cholecystectomy. *Br J Surg.* 1997;84(5):695.
20. Piskun G, Rajpal S. Transumbilical laparoscopic cholecystectomy utilizes no incisions outside the umbilicus. *J Laparoendosc Adv Surg Tech A.* 1999;9(4):361-364.
21. Cuesta MA, Berends F, Veenhof AA. The "invisible cholecystectomy": a transumbilical laparoscopic operation without a scar [published online October 18, 2007]. *Surg Endosc.* doi:10.1007/s00464-007-9588-y.
22. Marescaux J, Dallemagne B, Perretta S, Wattiez A, Mutter D, Coumaros D. Surgery without scars: report of transluminal cholecystectomy in a human being. *Arch Surg.* 2007;142(9):823-827.
23. Kumar M, Agrawal CS, Gupta RK. Three-port versus standard four-port laparoscopic cholecystectomy: a randomized controlled clinical trial in a community-based teaching hospital in eastern Nepal. *JSLS.* 2007;11(3):358-362.
24. Leung KF, Lee KW, Cheung TY, Leung LC, Lau KW. Laparoscopic cholecystectomy: two-port technique. *Endoscopy.* 1996;28(6):505-507.
25. Kagaya T. Laparoscopic cholecystectomy via two ports, using the "Twin-Port" system. *J Hepatobiliary Pancreat Surg.* 2001;8(1):76-80.
26. Leggett PL, Bissell CD, Churchman-Winn R. Cosmetic minilaparoscopic cholecystectomy. *Surg Endosc.* 2001;15(10):1229-1231.
27. Reddy N, Rao P. Per oral transgastric endoscopic appendectomy in human. Presented at: the 45th Annual Conference of the Society of Gastrointestinal Endoscopy of India; February 28-29, 2004; Jaipur, India.

INVITED CRITIQUE

Laparoscopic cholecystectomy revolutionized not only surgery but all of health care. Its development is also a study in how medicine can be transformed against the best advice of content experts. The first 100 LC operations were performed using rigid cystoscopy instrumentation by Eric Mühe, MD, in Germany. Because of severely limited exposure, the operation was considered dangerous and Dr Mühe was severely criticized by his colleagues. Shortly thereafter, the French developed a videoscopic approach to the operation that was somewhat better but still not well accepted by the surgical community. Experts in biliary surgery were concerned about the lack of exposure and the potential for serious bile duct injuries. They predicted that this new approach was a fad and would disappear once the higher complication rate become evident. The first publications describing the new approach reported a bile duct injury rate that was 10-fold higher than expected, whereupon the experts anticipated the early demise of LC.

It did not happen that way. Patients were intrigued by the notion that they could undergo major abdominal surgery without a large incision. Whereas the quoted complication rates that could occur following a laparoscopic operation were low and, therefore, of remote interest to patients, the prospect of a large, painful scar was very real. Cholecystectomy is common and patients went in droves to those surgeons offering the new approach. Oftentimes, they bypassed traditional, well-respected institutions and surgeons when seeking this new form of treatment.

We learned a great deal from this. Patients pay little attention to the facts and figures that we quibble about in academic meetings. They do care about painful scars. They will go to the practitioners who offer what patients want, irrespective what the experts say. Laparoscopic cholecystectomy also taught us that patients do not need to linger in hospitals for days on end when recovering from surgery. They could eat immediately following major abdominal surgery. The move toward outpatient surgery and shorter hospital stays for all types of operations are a direct extension of the lesson learned from LC. We also learned that the most transformative changes in health care come not necessarily from government-funded research enterprises but from the ideas and operating rooms of individual clinicians interested in finding better ways to take care of patients.

Laparoscopic cholecystectomy revolutionized surgery 2 decades ago. In an era that has witnessed the advent of personal computers, cell phones, wireless communication, and other major engineering advances, the approach to and instrumentation used for LC has remained remarkably stagnant. Progress is made in periodic upheavals rather than by evolutionary change. It is time for another major improvement in the approach to laparoscopic surgery.

Enter single-incision operations. Binenbaum and colleagues describe the use of a flexible endoscope to facilitate cholecystectomy. This article is important in 2 ways. It is one of the first studies to describes a series of SILCs. Given the limitations in exposure and mobility, does the reduction in three 5-mm port sites really improve matters? Our patients' answer will be a resounding "yes." Whether it is rational or not, the promise of fewer scars will appeal to our patients' imaginations. Perhaps this is

Downloaded from www.archsurg.com at COLEGIO BRASILEIRO CIRURGIOES, on August 25, 2009
©2009 American Medical Association. All rights reserved.