

Pediatric Polytrauma Management

Heike Jakob, Thomas Lustenberger, Dorien Schneidmüller, Anna L. Sander, Felix Walcher, Ingo Marzi¹

Abstract

Caring for pediatric trauma patients requires an understanding of the distinct anatomy and pathophysiology of the pediatric population compared to adult trauma patients. Initial evaluation, management, and resuscitation are performed as a multidisciplinary approach including pediatric physicians, trauma surgeons, and pediatric intensive care physicians. Head injury severity is the principle determinant of outcome and mortality in polytraumatized children. Abdominal injuries rarely require surgery in contrast to adults, but need to be detected. Spine and pelvic injuries as well as injuries of the extremities require age-adapted surgical procedures. However, the degree of recovery in polytraumatized children is often remarkable, even after apparently devastating injuries. Maximal care should, therefore, be rendered under the assumption that a complete recovery will be made.

Key Words

Pediatric polytrauma · Injury pattern · Trauma room management · Critical care

Eur J Trauma Emerg Surg 2010;36:325–38

DOI 10.1007/s00068-010-1125-3

Introduction

Pediatric trauma is the number one cause of death in children, exceeding all other causes of death combined [1, 2]; trauma is also the leading cause of permanent disability in this population [1, 3]. Motor vehicle crashes (38%), pedestrian-related trauma (28%), and bicycle-related injuries (26%) account for a high proportion of pediatric trauma deaths [4, 5]. Other areas of concern include falls, drowning, and burns [6].

Although the principles of trauma care are identical for children and adults, the differences in care required for the optimal treatment of the injured pediatric patient necessitate special knowledge and attention to the unique anatomy and physiology of the growing child or adolescent [7]. The body of a child is very elastic, and internal injuries without significant external signs can occur. Children are at special risk for severe injuries due to their close proximity of vital organs, their unfavorable head-to-body ratio, and their lower weight and height. Clinicians must be aware of the characteristics that require specialized strategies for the assessment and management of injuries in polytraumatized children [8].

Initial Assessment and Resuscitation

The Advanced Trauma Life Support (ATLS)-based primary survey with simultaneous resuscitation addresses life-threatening injuries that compromise oxygenation and circulation [9]. Upon arrival at the hospital, the child's airway, breathing, and circulation are evaluated. Use of the Broselow Pediatric Emergency Tape has become standard for determining height, weight, the appropriate size for resuscitative equipment, and correct drug doses and drip concentrations in a child [10, 11].

Airway control is the first priority for any trauma patient, but a child's airway is anatomically distinct from an adult's. A child's neck is shorter, the epiglottis is large and floppy, and the vocal cords are located higher and more anterior. For a child, intubation is easier with a straight laryngoscope blade, and the endotracheal tube size can be estimated using the child's fifth digit. The subglottic trachea is the narrowest portion of the pediatric airway and provides a physiological cuff; thus, uncuffed endotracheal tubes in children less than 8 years of age should be used in

¹Department of Trauma, Hand and Reconstructive Surgery, Johann Wolfgang Goethe University Medical School, Frankfurt/Main, Germany.

Received: June 14, 2010; accepted: June 15, 2010;
Published Online: July 29, 2010

order to avoid subglottic edema and injury. The tube position should always be checked with a chest X-ray, since a high incidence of right mainstem intubation is found in emergency intubations [12]. Surgical cricothyroidotomy should be avoided in children younger than 6 years of age due to the high association with secondary subglottic stenosis.

Assessment of the patient's breathing follows establishment of the airway. Infants and small children are primarily diaphragmatic breathers; consequently, any compromise of diaphragmatic excursion significantly limits the child's ability to ventilate. Severe gastric dilation due to the swallowing of air may cause respiratory difficulties or complicate the abdominal examination. Gastric decompression with a naso- or orogastric tube should be employed in appropriate cases.

Children are known to have an amazing cardiovascular reserve; therefore, initial normal vital signs should not impart any sense of security with regard to the status of the child's circulating volume. Obvious signs of shock, such as hypotension or a decrease in urinary output, may not occur until more than 30% of the blood volume has been lost [13].

As in adults, a focused assessment sonography in trauma (FAST) is performed during the primary evaluation of the injured child [14]. A recent review demonstrated the sensitivity of FAST examination to be 30–88% and the specificity to be 42–100% in

pediatric trauma patients [15]. In children in particular, a lack of free intraperitoneal fluid does not exclude significant organ injuries. The majority of children with hemoperitoneum do not necessarily require operative intervention [16, 17].

Computed tomography (CT) scanning of the head, chest, abdomen, spine, and pelvis is the preferred technique for imaging hemodynamically stable injured children or for imaging hemodynamically stable, intubated patients with suspicious injury mechanisms (Table 1) [18]. However – in particular in the awake patient – a thorough physical examination and evaluation of the trauma mechanism may permit the avoidance of a complete CT diagnostic, reducing the radiation burden. Nevertheless, despite the seven times increased radiation exposure in polytrauma CT scans compared to conventional X-rays, long-term adverse effects have not been proven yet. In particular in the severely injured patient, the shorter diagnostic work-up time and valuable information on intracorporal injuries may beneficially influence outcome [19] (Figures 1 and 2).

Pediatric Scoring Systems

Many trauma scoring systems have been used to assess children following polytrauma. The Injury Severity Score (ISS), an anatomical scoring system that pro-

Table 1. Computed tomography (CT) diagnostic during the initial assessment.

	Technical considerations	Specific diagnostic considerations
CT brain and cervical spine	Age-based CT slice thickness Sequential technique i.v. contrast if clinical suspicion of vascular injury Coronary reconstruction of skull and facial bones	Brain and skull • Intracranial hemorrhage • Edema • Vascular injury • Fracture Cervical spine • Fracture, assessment of stability • Luxation
CT chest and thoracic spine	Age-based i.v. contrast dosage Age-based CT slice thickness Multiplanar reconstruction of the spine	Parenchymal injuries Contusions Pneumo-/hemothorax Position of thoracostomy tube Pericardial fluid Vascular injury Fracture, assessment of stability Luxation
CT abdomen, lumbar spine, and pelvis	Weight-based i.v. contrast dosage Adequate delay times (early phase for arterial injuries, portal venous phase as standard, late phase for kidney injuries)	Solid organ injuries Free fluid Retroperitoneal injuries and retroperitoneal bleeding Hollow viscus injuries Fracture, assessment of stability

Figure 1. Standardized initial assessment and resuscitation of the polytraumatized pediatric patient (adapted from Frank et al. [62] and Helm et al. [63]).

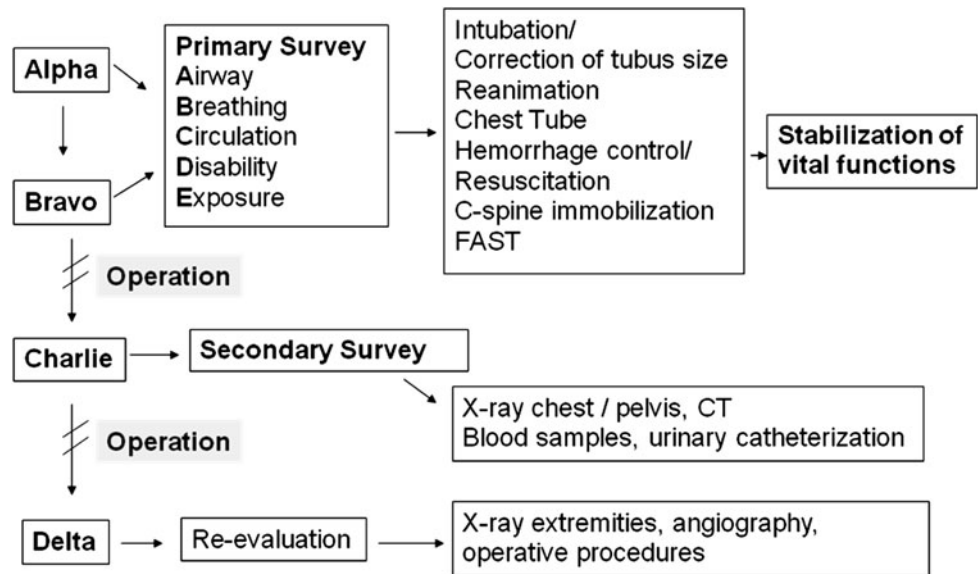


Table 2. The pediatric Glasgow Coma Scale (GCS) [58, 59].

Score	Eye opening	Verbal response	Motor response
6	–	–	Normal, spontaneous, obeys commands
5	–	Age-appropriate words, social smile, fixes and follows	Localizes pain
4	Spontaneous	Cries, but consolable	Withdraws from pain
3	To voice	Persistently irritable	Flexion posture to pain
2	To pain	Restless, agitated	Extension posture to pain
1	None	None	None

vides an overall score for patients with multiple injuries, is reproducible and useful in pediatric trauma patients [20–22]. An ISS of 16 or more is usually taken to indicate a polytrauma.

The Pediatric Trauma Score (PTS) is a physiological score emphasizing the child’s weight and airway. Several studies have confirmed that the PTS is a valid tool for predicting the mortality of a traumatically injured child [23–25]. Mortality is estimated at 9% with a PTS > 8 and at 100% with a PTS ≤ 0.

The Glasgow Coma Scale (GCS) score is a universal tool for the rapid assessment of an injured child’s consciousness level. A modified verbal and motor version has been developed to aid in the evaluation of the consciousness level of infants and young children (Table 2).

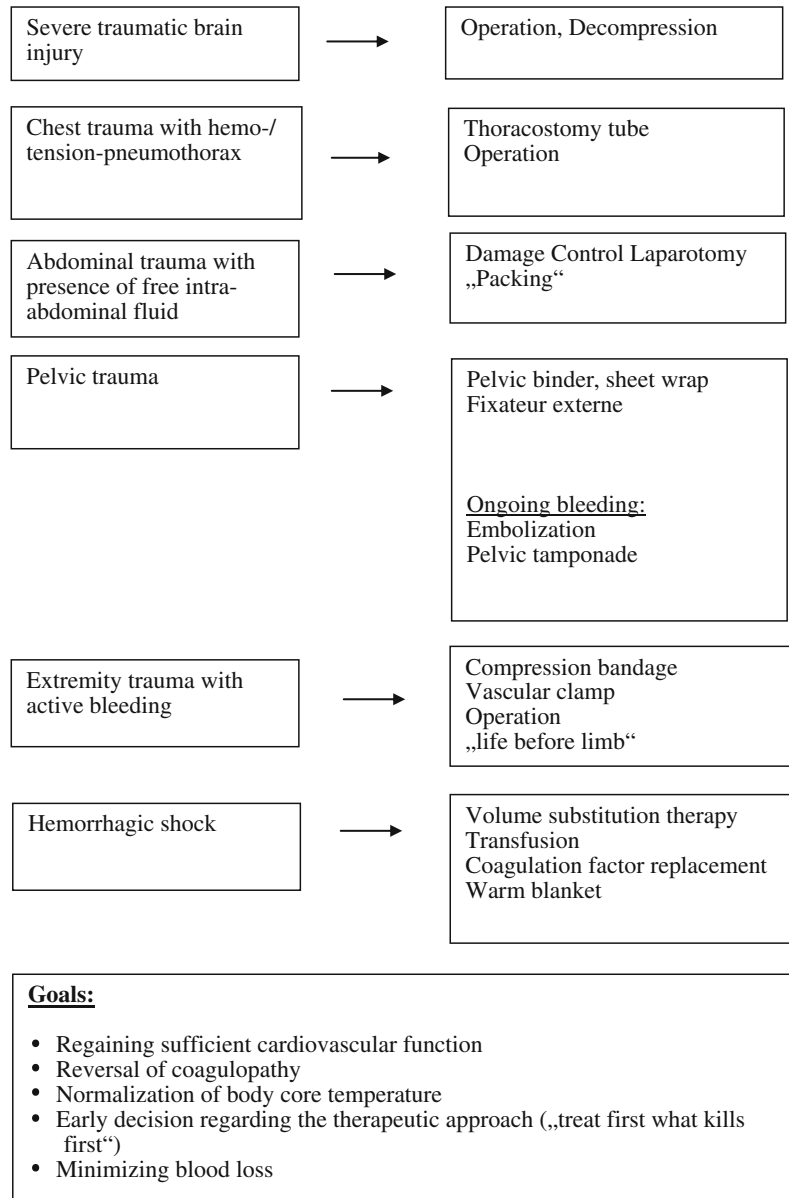
Head Injuries

Head injuries have been reported in 17% of children with polytrauma [26], representing the most common cause of long-term disability [27, 28]. Compared to

adults, the pediatric population is more susceptible to traumatic brain injury (TBI) because the more pliable, thinner, immature skull provides less protection to the intracranial contents. Weak cervical musculature and a proportionally increased head mass also bias the pediatric population toward TBI. In addition, myelination occurs between 6 and 24 months of age, making the brain very soft and prone to disruption prior to the completion of this process.

Injuries to the brain are classified as primary or secondary. Primary injuries are inflicted immediately by trauma, while secondary injuries result from hypoxia, hypotension, hypercarbia, anemia, hyperglycemia, infections, seizures, or increased intracranial pressure (ICP) in addition to the primary injury. Following TBI, the incidence of increased ICP is far higher in children than in adults (80 vs. 50%) [29], constituting a significant source of secondary brain injury (Figure 3). Elevated ICP may be caused by hematoma, increased cerebral blood volume, or increased brain volume, and may cause a reduction in cerebral perfusion pressure (CPP). Target CPP levels are 60–80 mmHg in older

Figure 2. Acute management of life-threatening injuries and hemodynamically unstable pediatric patients.



children and at least 50 mmHg in children less than 8 years of age. The ICP should ideally be maintained below 20 mmHg. Table 3 depicts age-appropriate CPP thresholds.

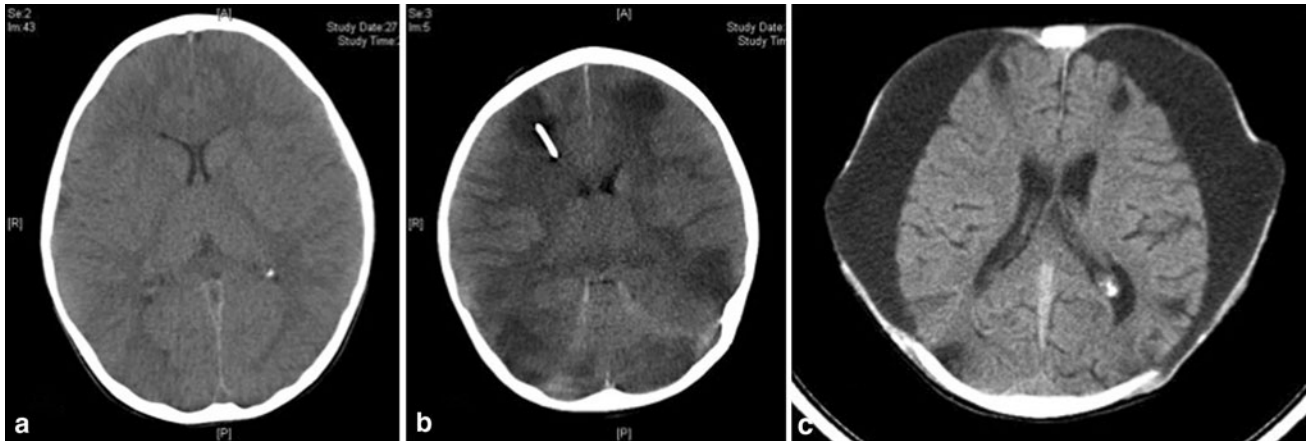
Children often sustain severe TBI, which is an important prognostic factor. In the intubated pediatric patient, a CT scan of the head is essential to allow early operative intervention.

Acute management of children with head injuries includes elevation of the head of the bed, the rare use of hyperventilation of the intubated patient, fluid restriction, and the administration of barbiturates. ICP monitoring is recommended in infants and

Table 3. Age-appropriate CPP thresholds in severe traumatic brain injury (according to Fritz et al. [60] and Jöhr et al. [61]). (CPP: cerebral perfusion pressure).

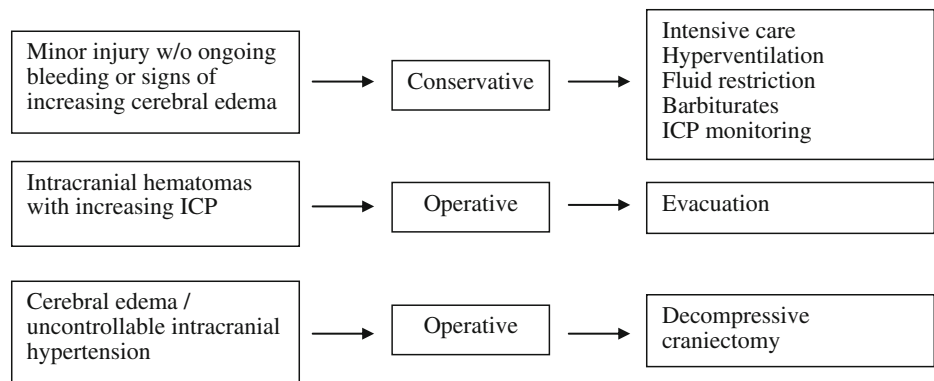
Age group (years)	CPP threshold (mmHg)
0–1	60
1–6	60–65
6–13	70
> 13	70–80

children with a GCS score of 8 or less, particularly in children with closed cranial sutures. Optimally, intracranial hematomas – subdural as well as epidural



Figures 3a to 3c. A 3 years and 3 months old girl was airlifted to our hospital after a fall from the fourth floor of a building. Admission computed tomography (CT) scan of the head demonstrates traumatic brain injury with severe brain edema obliterating the ventricles (a). Intracranial pressure (ICP) monitoring was initiated on admission day (b). Due to increasing brain edema and subsequent uncontrollable intracranial hypertension, bilateral decompressive craniectomy was performed on day 2 after trauma (c).

Figure 4. Current treatment procedures for pediatric brain injuries.



hematomas – resulting in intracranial hypertension should be evacuated within the first 3 h following injury, as long-term results significantly worsen thereafter [30]. A decompressive craniectomy should be considered in children with cerebral edema and medically uncontrolled intracranial hypertension [31]. Nutritional support and treatment of postinjury seizures are further important aspects of the care of the brain-injured child.

After initial hemodynamic stabilization, a TBI requiring operative intervention takes priority. As in adults, the severe TBI in children is the most common cause of death and is an important determinant predicting outcome (Figure 4).

Indications for operative interventions in pediatric traumatic brain injuries (TBIs):

- Increased ICP due to space-occupying intracranial hemorrhages requires immediate operative intervention.

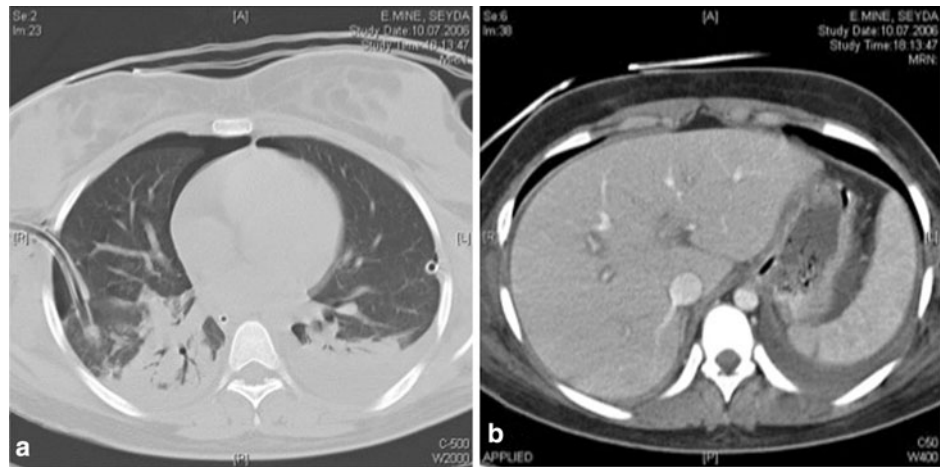
- Aggressive ICP monitoring in cases of severe TBI and GCS < 8 allows the early detection of diffuse brain swelling with the consecutive risk of brain ischemia and brain infarction.

Chest Injuries

Chest injuries account for 5 to 12% of admissions to pediatric trauma centers [32] and thoracic trauma has been reported in 8 to 62% of pediatric polytrauma cases [26, 27]. While a 5% mortality rate for isolated chest trauma has been reported, this figure increases to 25% in the presence of concomitant head or abdominal injuries [32]. Thoracic injuries are important variables predicting outcome and play a cornerstone role in the management of pediatric trauma [33].

Children exhibit distinct patterns of chest injuries compared to adults [34]. The pediatric thorax has a greater cartilage content and incomplete rib ossification,

Figures 5a and 5b. Severe bilateral lung contusions and pneumothorax (a) in a 16-year old girl following a motor vehicle accident. Abdominal CT scan additionally shows free intraperitoneal fluid and a splenic laceration (b), which was successfully treated non-operatively.



making fractures of the ribs and sternum less common. Severe parenchymal thoracic injuries may be present with minimal or no signs of external trauma and with a normal admission chest X-ray. Finally, the mobility of the heart and mediastinum may result in heart dislocation, transection, or angulation of the great vessels, and tracheal compression and angulation. Injuries to the heart and great vessels, while rare, are highly morbid and require rapid diagnosis and treatment. The diagnosis is suggested by the observation of a widened mediastinum on plain film, but mostly may be recognized in contrast media enhanced CT.

Isolated rib fractures are generally of little concern, although they often indicate more severe chest injuries, including lung and cardiac contusion or laceration, hemo- and pneumothorax, or mediastinal injury (Figure 5). Multiple rib fractures are associated with severe trauma to other body areas.

Pulmonary contusions remain the most common form of pediatric thoracic trauma; the diagnosis is made by chest X-rays in approximately 90% of cases, with half of the cases demonstrating rib fractures, hemothorax, and/or pneumothorax on radiographs [32]. Pulmonary contusions may lead to atelectasis, consolidation, and progressive inflammation, possibly resulting in pneumonia, ventilation-perfusion mismatch, and respiratory insufficiency. The risk of developing pneumonia in cases of severe pulmonary contusions is 20–30%, supporting the use of early antibiotic treatment. In contrast to adults, a kinetic therapy is, in general, not necessary.

Pneumo- and/or hemothorax are managed by prompt chest tube placement. Approximately 5% of children with a hemothorax will require surgical drainage due to ongoing bleeding from the thoracostomy tube; however, the indications for surgery remain controversial.

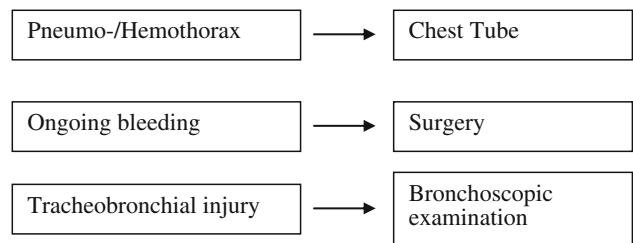


Figure 6. Current treatment procedures for pediatric chest trauma.

Tracheobronchial injuries are usually located in the lower trachea or upper bronchus. Multiple findings may include pneumothorax, hemothorax, pneumomediastinum, subcutaneous emphysema, or persistent air leak from a chest tube. If the injury involves less than one-fourth of the bronchus diameter, nonoperative therapy with frequent bronchoscopic examination may be suitable (Figure 6).

Indications for operative intervention in pediatric chest trauma:

- Persisting hemodynamics compromising thoracostomy tube output.
- Cardiac tamponade.
- Massive air leak from the thoracostomy tube.
- Penetrating object with injury of lung parenchyma.

Abdominal Injuries

Abdominal injuries are reported in 8 to 27% of pediatric polytrauma patients [26, 35]. Because children are generally healthy, with good physiological reserves, they may initially remain clinically stable, despite significant injuries. Tachycardia is the earliest (and often the only) sign of hemorrhagic shock with imminent hemodynamic decompensation.

Anatomical differences in children make them more vulnerable to major abdominal injuries from minor forces. Compared with the adult patient, the child’s intra-abdominal organs are proportionally larger and in closer proximity to each other. The child’s small and pliable rib cage and the undeveloped abdominal musculature provide little protection for major organs.

In the hemodynamically unstable patient, immediate operative intervention is indicated following completion of the primary or secondary surveys, respectively. In less critically ill patients, further diagnostic evaluation for intra-abdominal injuries is generally performed by CT scan.

Liver and spleen injuries are commonly seen in polytraumatized children. The vast majority of these injuries can be managed non-operatively with success rates of up to 95% [36–38]. Selective, non-operative management requires hemodynamic stability and absence of peritoneal signs. Those patients should be monitored closely with serial clinical examinations and serial hematocrits for evidence of ongoing bleeding. Failure of non-operative treatment usually occurs within the first few hours of admission. Although the majority of children do not require surgery for splenic or hepatic injuries, children presenting hemodynamic instability belong in the operating room for hemorrhage control. Organ-preserving techniques are preferred in adequately resuscitated patients that do not demonstrate ongoing hemorrhagic shock. Splenorrhaphy and partial splenectomy are techniques to control bleeding while preserving splenic parenchyma. Splenectomy may be required in the critically ill child or in the case of a completely shattered spleen. Hepatorrhaphy, perihepatic packing, or suture ligation of bleeding vessels are preferred over extensive hepatic resections.

The operative management of liver injuries is based on the “damage control” concept. Patients with

a major hepatic laceration, surgically uncontrollable bleeding, coagulopathy, or hypothermia require perihepatic packing [36]. Definitive operative treatment of injured liver vessels or bile ducts is performed after achieving hemodynamic stabilization and reversal of coagulopathy.

Following primary life-saving operative interventions of abdominal injuries, the diagnostic evaluation should be completed.

Hollow viscus injuries are frequently encountered in restrained children involved in a motor vehicle accident. This injury mechanism is often indicated by abdominal wall ecchymosis (“seatbelt sign”), with a sudden increase in the intraluminal pressure resulting in “blowout” or perforation of the intestine. CT scanning is diagnostic in only 60% of bowel perforation cases and may reveal free fluid without evidence of solid organ injuries [39]. Close observation and serial physical examination should guide ambiguous findings, and fluid around the duodenum and pancreas may be a predictive sign. Once diagnosed, the surgical treatment of perforations involving greater than 50% of the circumference usually requires segmental resection with primary anastomosis, whereas perforations of less than 50% of the circumference can be repaired primarily. Only in cases of severe abdominal contamination or rectal injuries is a two-stage procedure with temporary creation of a colostomy indicated.

Pancreatic injuries are rare, comprising less than 5% of all pediatric abdominal injuries, and whose diagnoses are frequently delayed. The diagnosis of pancreatic injury is suggested by an elevated amylase level and the clinical sign of significant epigastric pain. Only in extensive pancreatic injuries was early partial resection associated with improved outcomes as compared to conservative management [40] (Figure 7).

Figure 7. Current treatment procedures for pediatric abdominal trauma.

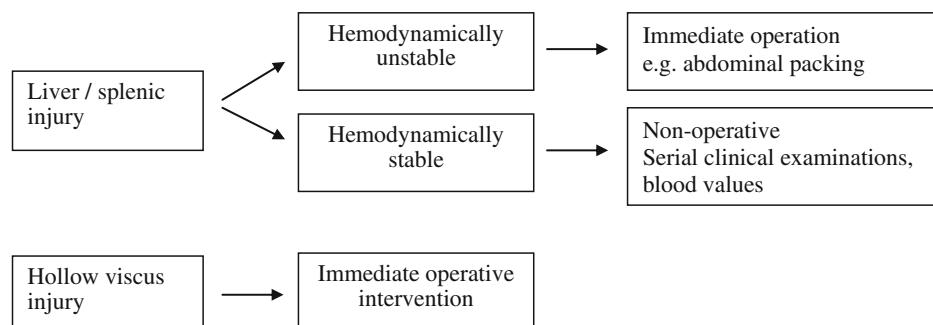
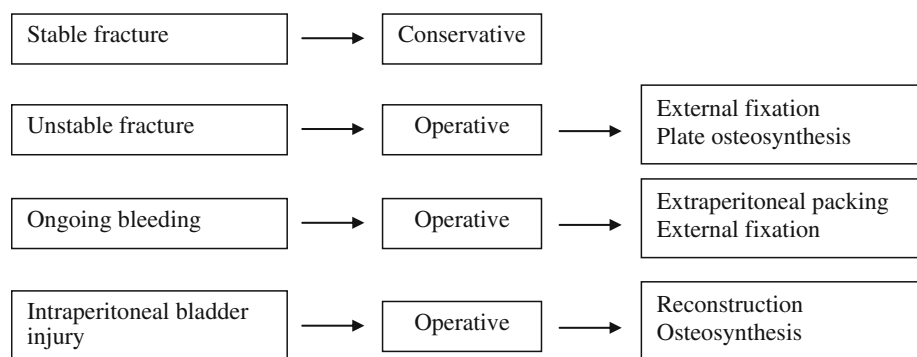


Figure 8. Current treatment procedures for pediatric pelvic trauma.



Pelvic Trauma

The immature pelvis has greater elasticity in the sacroiliac joint and the symphysis, making fractures dependent on higher energy forces. Pediatric pelvic fractures consequently accompany multiple injuries [41, 42]. Clinical signs of pelvic fractures include superficial hematomas above the inguinal ligament or the scrotum (Destot’s sign), a decrease in the distance between the greater trochanter and the pubic spine as compared to the contralateral side (Roux’s sign) in lateral compression fractures, and a large hematoma or a palpable fracture line discovered on rectal examination (Earle’s sign).

Most pelvic fractures are stable and can be managed non-operatively, except overriding bus or car accidents. Unlike pelvic fractures in adults, pediatric pelvic fractures are generally not hemodynamically significant [43]. In most cases, pediatric avulsion fractures and type A fractures are treated conservatively, aiming at pain relief and early mobilization. General indications for surgery include unstable type C fractures and rotationally unstable type B fractures. Abdominal and retroperitoneal concomitant injuries influence the therapeutic approach in those cases [44]. Operative management includes anterior external fixation, which can be a definitive approach in children, and open reduction and internal fixation with a plate osteosynthesis. The C-clamp for emergent external posterior fixation has no role in the acute management of pelvic fractures in children, as bounding the patient’s knees and ankles loosely together to aid in reduction is sufficient [45]. Displacement of large fragments of more than 1 cm, a diastasis of the symphysis pubis of more than 2 cm, and open pelvic ring fractures represent further indications for operative intervention. Closed fractures of the anterior pelvic ring with a dislocation of less than 5 mm and a diastasis of the symphysis pubis of less than 1 cm can be treated non-operatively.

Acetabular fractures in children are infrequent and evidence-based studies regarding the treatment of pediatric acetabular fractures are rare. Injury of the growth plate might result in growth arrest and subsequent subluxation of the femoral head. Consequently, an adequate diagnostic evaluation is necessary to determine the management strategy on an individual basis.

Treatment of pediatric acetabular fractures:


- In acetabular fractures, anatomical reduction is necessary to achieve good long-term results. The preferred approach is screw osteosynthesis [44].
- To avoid the risk of growth disturbances, early removal of the implant should be performed [41].

Head, chest, and visceral trauma are often combined with pediatric pelvic fractures [46]. The urogenital system, especially the perineum, vagina, rectum, and bladder, should receive specific evaluation during the initial physical examination, as those injuries are often missed and can lead to potentially serious consequences. Bladder injuries may require urgent repair in the case of intraperitoneal rupture, or delayed repair versus observation for extraperitoneal injury (Figure 8).

Spinal Trauma

Spine fractures are rare in children, representing only 1–2% of all pediatric fractures [47]. This low incidence is due not only to the plasticity of the pediatric spine, but also to the usually severe (if not fatal) associated injuries. The disproportionately large head size and relatively weak neck muscles, the horizontal orientation of the upper cervical facet joints, and ligamentous laxity place the upper cervical spine (C0–C2) at

Figure 9. Current treatment procedures for pediatric spinal trauma.



high risk for injury in children younger than 12 years of age.

Incomplete ossification and physiological hypermobility of the pediatric cervical spine contribute to imaging findings that can be confused with pathological conditions. Increased anterior displacement of C2 on C3 (pseudosubluxation) may be mistaken for a cervical spine injury; this condition may be found in patients up to 16 years old. Pseudosubluxation of C3 on C4 occurs less frequently, while an increased distance between the dens and the anterior arch of C1 occurs in approximately 20% of young children. Normal wedging of an intervertebral space or the C3 body and normal translucencies of the dens may also be mistaken as spinal trauma and fractures, respectively [48].

Atlanto-occipital dislocation is a rare and often fatal injury [49]. These patients are usually polytrauma victims with severe head injuries who present with a range of clinical neurological issues, from cranial nerve dysfunction to varying degrees of quadriplegia and complete loss of neurological function below the brain stem [50]. Early reduction and definitive immobilization using a halo cast alone or with supplemental internal fixation and posterior fusion should be performed [51, 52].

Odontoid fractures are a common pediatric cervical spine injury; however, neurological deficits are rare [53]. These fractures usually displace anteriorly, with the dens posteriorly angulated. Displaced odontoid fractures in children reduce easily following mild extension and posterior translation. Healing is rapid and immobilization with a halo cast can be completed in 6–10 weeks.

Traumatic ligamentous instability usually occurs in the upper cervical spine (C2/C3) in younger children. Treatment consists of closed reduction and halo immobilization for approximately 8 weeks. However, in rare cases, posterior cervical fusion with subsequent Minerva jackets or halo immobilization is necessary.

C3–C7 fractures are more common in older children and adolescents than in younger children [54]. The typical injury patterns include compression fractures of the vertebral body, which can be treated with Philadelphia immobilization. Persistent instabil-

ity, neurological deficits, or increasing cyphosis represent indications for posterior cervical fusion.

The majority of thoracolumbar spine fractures in children and younger adolescents are minor, stable, and without neurological deficit [53]. Older adolescents sustain injuries similar to those seen in adults, and should be managed accordingly. Compression fractures, mostly occurring in the thoracic spine, are seen in 90% of the cases. Treatment usually consists of bed rest with gradual resumption of activities. Surgical decompression by ligamentotaxis with reduction of retropulsed fragments, posterior distraction, and instrumentation are recommended for neurologically compromised patients. End plate damage may result in an increase in deformity, especially during the rapid adolescent growth spurt.

Type B and C spine injuries are rare in children below the age of 12 years. However, up to 50% of cases are associated with severe chest, abdominal, or retroperitoneal injuries. Operative intervention is recommended, but the treatment of concomitant intrathoracic or intra-abdominal injuries takes priority.

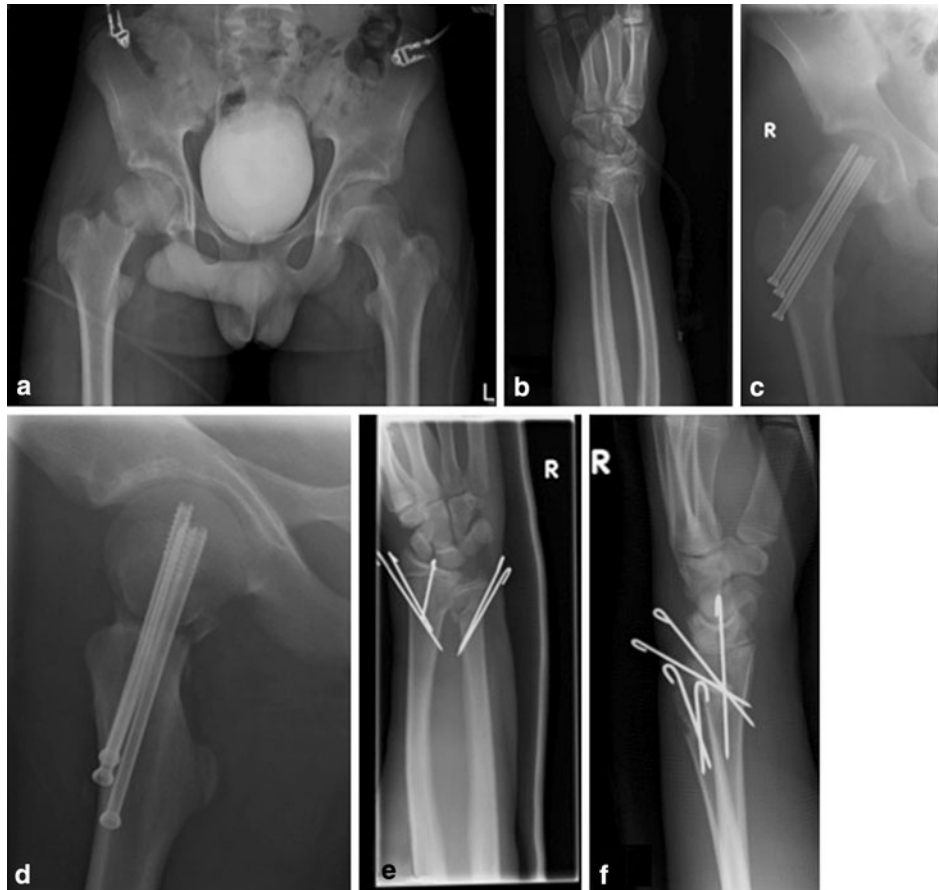Neurologic deficits due to a narrowing of the spinal canal are – as in adults – treated by dorsal decompression by laminectomy, distraction, and stabilization by internal fixation. The goal of the operative management of spinal injuries is a stable osteosynthesis, allowing early mobilization, facilitating care of the patient, and avoiding secondary spinal cord damage (Figure 9).

Extremity Trauma

Extremity fractures have been reported in up to 76% of children following polytrauma, implying that orthopedic injuries must be viewed in the context of the overall status of the multiply injured child [6, 27].

Definitive care of extremity injuries in the pediatric polytrauma is usually undertaken within the first 24 h of injury (Figure 10). In cases of clinical suspicion of vascular injuries, color flow Doppler imaging and/or angiography are the investigations of choice. Open fractures, fractures with associated vascular injuries, compartment syndromes, and amputation injuries re-

Figures 10a to 10f. A 16-year-old boy was admitted to the trauma room after a jump from the second floor of a building. Shock room CT revealed severe traumatic brain injury with subarachnoid hemorrhage, intraparenchymal hematomas, and skull fracture, as well as severe chest trauma with lung contusions on the right side. Admission X-rays demonstrate a fracture of the right femoral neck (a), and a right distal radius fracture (b). During the initial procedure, intracranial pressure (ICP) monitoring was installed, a thoracostomy tube was inserted, the femoral neck fracture was stabilized by screw osteosynthesis (c, d), and a stabilization of the distal radius fracture using K-wires was performed (e, f).



quire emergency care. Stable osteosynthesis of the fracture is performed by, firstly, repair of the extremity artery, veins secondly, and, finally, tissue coverage is performed.

Fractures of the epi- and metaphysis are mostly treated by K-wire osteosynthesis. Some cases require additional or alternative application of an external fixator. Depending on the fracture pattern and characteristics, as well as the age of the child, open reduction and internal fixation using screw and/or plate osteosynthesis may be an option. Diaphyseal fractures are predominantly fixed using flexible intramedullary rods, such as elastic stable intramedullary nailing. Plate osteosynthesis of diaphyseal fractures during adolescence should, at most, be considered as a temporary stabilization using minimally invasive techniques [55]. However, early definitive osteosynthesis of extremity fractures should be a goal of pediatric patient management.

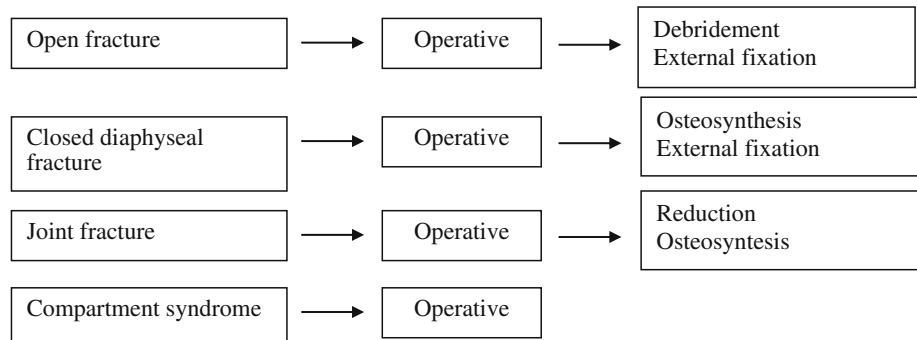
Compartmental hypertension is a potentially devastating complication of extremity injury, which is

treated by decompression of the afflicted compartments by the incision of their fascia. The stabilization of fractures is subsequently performed as described above. Vacuum-assisted closure devices or artificial skin are used to temporarily cover tissue defects or fasciotomy sites.

Open fractures and open joint injuries are primarily washed out, debrided, and subsequently stabilized. In cases of severe, open articular fractures, a two-stage management may be necessary.

Early fracture stabilization reduces the systemic effects of fractures, including a systemic inflammatory response syndrome, sepsis, multiple organ failure, and acute respiratory distress syndrome, even the latter, are less important in children. Early stabilization also reduces pain, the risk of secondary neurovascular damage, and promotes mobilization of the patient. In general, initial definitive surgical care should be undertaken in fractures of the humerus, forearm shaft fractures, and fractures of femur and tibia. Non-dis-

Figure 11. Current treatment procedures for pediatric extremity trauma.



placed distal forearm fractures can be addressed by casting.

Polytrauma patients have a severely deranged immune response, characterized by an early excessive activation of innate immunity (hyperinflammation), followed by a delayed immunosuppression and enhanced susceptibility to infection, sepsis, and multiple organ failure [56]. Due to the hyperinflammation observed on day 2 to 5, surgical interventions during this intermediate phase should ideally be avoided.

Children often recover remarkably well from what initially appear to be devastating injuries to the central nervous system or other organ systems. Consequently, optimal orthopedic care must be undertaken with the assumption that the injured child will completely recover (Figure 11).

The complications after trauma are given in Table 4.

Pediatric Critical Care

Once the patient leaves the emergency department or the operating room, the pediatric intensive care unit (PICU) provides an optimal environment in which patient outcome can be improved through the recognition of acute changes in clinical status followed by immediate treatment. Pediatric trauma victims benefit from care under a multidisciplinary team, including a pediatric critical care physician, the trauma surgeon, PICU nurses, respiratory therapists, and further pediatric subspecialists. Recent data suggest that the care of injured children in a dedicated PICU improves survival [57].

In the severely head-injured pediatric trauma patient, optimizing the CPP is of utmost importance, either by decreasing the ICP or augmenting the mean arterial pressure (MAP). ICP management may

include sedation, osmotic therapy (including mannitol and hypertonic saline solutions), and pentobarbital coma for refractory cases. Adequate CPP may also be maintained through MAP support, using norepinephrine if the central venous pressure is adequately high, or epinephrine in case of insufficient myocardial contraction. The use of a PiCCO system allows the monitoring of intravascular volume and catecholamine therapy.

To avoid secondary lung damage (pneumothorax or acute respiratory distress syndrome), ventilation is based on pressure control, which provides peak inspiratory pressure throughout inspiration. Initially, relaxation may be required to reach the therapeutic target of arterial pO₂ > 100 mmHg. In brain-injured patients, the positive end-expiratory pressure should be minimized to allow sufficient drainage from the cervical venous system; however, the pressure should not fall below 3 cm H₂O. Again, PiCCO monitoring may be a valuable tool in patient management.

Conclusion

Caring for pediatric trauma patients requires an understanding of the distinct anatomy and pathophysiology of the pediatric population compared to adult trauma patients. Initial evaluation, management, and resuscitation require a multidisciplinary approach including trauma surgeons, anesthesiologists, and pediatric intensive care physicians. Head injury severity is the principle determinant of outcome and mortality in polytraumatized children. Nevertheless, the degree of recovery in polytraumatized children is often remarkable, even after apparently devastating injuries. Maximal care should, therefore, be rendered under the assumption that a complete recovery will be made.

Table 4. Complications after trauma in the pediatric patient.

Traumatic brain injury	<p>Diffuse brain edema Coagulopathy Thromboembolic events Apallic syndrome Posttraumatic epilepsy Postoperatively:</p> <ul style="list-style-type: none"> • Increase of ICP • Bleeding <p>Increased risk of complications with GCS < 8</p>
Chest trauma	<p>Pneumonia Acute respiratory distress syndrome (ARDS) Abscess, empyema</p>
Abdominal trauma	<p>Postinjury organ failure due to abdominal malperfusion during hemorrhagic shock Secondary hemodynamic instability in cases of non-operatively treated liver and splenic injuries Peritonitis due to hollow viscus injuries or protracted intestinal wall necrosis Delayed solid organ rupture Postoperatively:</p> <ul style="list-style-type: none"> • Re-bleeding • Infections/wound dehiscence (abdominal wall) • Abscess • Adhesions, posttraumatic ileus • Abdominal wall hernia <p>Late complications: Mainly due to missed injuries, mostly of the intestine, following blunt abdominal trauma</p>
Spinal trauma	<p>Growth disturbance/deformity in cases of injured growth plate Progressive deformity in case of persisting instability and neurological symptoms Posttraumatic paralysis Fusion of spinal segments following damage of end plates Postoperatively:</p> <ul style="list-style-type: none"> • Progression of neurological deficits • Re-bleeding • Implant dislocation
Pelvic trauma	<p>Early complications:</p> <ul style="list-style-type: none"> • Blood loss due to intra-abdominal or retroperitoneal injuries (fracture, presacral venous plexus) • Peritonitis following disruption of the pelvic floor, rectal injuries • Urinary incontinence <p>Late complications:</p> <ul style="list-style-type: none"> • Growth disturbance (fusion of pubic symphysis or iliosacral gap) • Acetabular dysplasia with hip luxation <p>Postoperatively:</p> <ul style="list-style-type: none"> • Re-bleeding • Neurovascular injury • Implant dislocation
Extremity trauma	<p>Compartment syndrome Infection Soft tissue defect Implant failure Premature growth plate closure, growth arrest Non-union Leg length discrepancy Nerve injury, motoric dysfunction</p>

Conflict of interest statement

The authors declare that there is no actual or potential conflict of interest in relation to this article.

References

- American Academy of Pediatrics Section on Orthopaedics; American Academy of Pediatrics Committee on Pediatric Emergency Medicine; American Academy of Pediatrics Section on Critical Care; American Academy of Pediatrics Section on Surgery; American Academy of Pediatrics Section on Transport Medicine; American Academy of Pediatrics Committee on Pediatric Emergency Medicine; Pediatric Orthopaedic Society of North America, Krug SE, Tuggle DW. Management of pediatric trauma. *Pediatrics* 2008;121:849–54.
- Arias E, MacDorman MF, Strobino DM, Guyer B. Annual summary of vital statistics—2002. *Pediatrics* 2003;112:1215–30.
- Mazurek A. Pediatric injury patterns. *Int Anesthesiol Clin* 1994;32:11–25.
- Jakob H, Brand J, Marzi I. Multiple trauma in pediatric patients. *Unfallchirurg* 2009;112:951–8.
- Gatzka C, Begemann PG, Wolff A, Zörb J, Rueger JM, Windolf J. Injury pattern and clinical course of children with multiple injuries in comparison to adults, Ab 11-year analysis at a clinic of maximum utilization. *Unfallchirurg* 2005;108:470–80.
- Kay RM, Skaggs DL. Pediatric polytrauma management. *J Pediatr Orthop* 2006;26:268–77.
- Sharples PM, Storey A, Aynsley-Green A, Eyre JA. Avoidable factors contributing to death of children with head injury. *BMJ* 1990;300:87–91.
- Laurer H, Wutzler S, Wyen H, Westhoff J, Lehnert M, Lefering R, Marzi I; Sektion NIS der DGU. Quality of prehospital and early clinical care of pediatric trauma patients of school age compared to an adult cohort. A matched-pair analysis of 624 patients from the DGU trauma registry. *Unfallchirurg* 2009;112:771–7.
- Bouillon B, Kanz KG, Lackner CK, Mutschler W, Sturm J. The importance of advanced trauma life support (ATLS) in the emergency room. *Unfallchirurg* 2004;107:844–50.
- Agarwal S, Swanson S, Murphy A, Yaeger K, Sharek P, Halamek LP. Comparing the utility of a standard pediatric resuscitation cart with a pediatric resuscitation cart based on the Broselow tape: a randomized, controlled, crossover trial involving simulated resuscitation scenarios. *Pediatrics* 2005;116:e326–33.
- So TY, Farrington E, Absher RK. Evaluation of the accuracy of different methods used to estimate weights in the pediatric population. *Pediatrics* 2009;123:e1045–51.
- Nakayama DK, Gardner MJ, Rowe MI. Emergency endotracheal intubation in pediatric trauma. *Ann Surg* 1990;211:218–23.
- American College of Surgeons. Hemorrhagic shock classification. In: *Advanced Trauma Life Support for Physicians: Instructor's Manual*. Chicago, 1993.
- Ruesseler M, Kirschning T, Breitzkreutz R, Marzi I, Walcher F. Prehospital and emergency department ultrasound in blunt abdominal trauma. *Eur J Trauma Emerg Surg* 2009;35:341–46.
- Murphy R, Ghosh A. Towards evidence based emergency medicine: best BETs from the Manchester Royal Infirmary. The accuracy of abdominal ultrasound in paediatric trauma. *Emerg Med J* 2001;18:208–9.
- Beierle EA, Chen MK, Whalen TV, Doolin EJ. Free fluid on abdominal computed tomography scan after blunt trauma does not mandate exploratory laparotomy in children. *J Pediatr Surg* 2000;35:990–2; (discussion 993).
- Dowd MD. Effect of emergency department care on outcomes in pediatric trauma: what approaches make a difference in quality of care? *J Trauma* 2007;63:5136–9.
- Kanz KG, Körner M, Linsenmaier U, Kay MV, Huber-Wagner SM, Kreimeier U, Pfeifer KJ, Reiser M, Mutschler W. Priority-oriented shock trauma room management with the integration of multiple-view spiral computed tomography. *Unfallchirurg* 2004;107:937–44.
- Strohm PC, Uhl M, Hauschild O, Stankovic Z, Reising KJ, Lesniak M, Südkamp NP. What is the value of the whole body spiral CT in the primary radiological imaging of severely injured children? *Z Orthop Unfall* 2008;146:38–43.
- Wesson DE, Spence LJ, Williams JI, Armstrong PF. Injury scoring systems in children. *Can J Surg* 1987;30:398–400.
- Nayduch DA, Moylan J, Rutledge R, Baker CC, Meredith W, Thomason M, Cunningham PG, Oller D, Azizkhan RG, Mason T. Comparison of the ability of adult and pediatric trauma scores to predict pediatric outcome following major trauma. *J Trauma* 1991;31:452–7; (discussion 457–8).
- Ott R, Krämer R, Martus P, Bussenius-Kammerer M, Carbon R, Rupperecht H. Prognostic value of trauma scores in pediatric patients with multiple injuries. *J Trauma* 2000;49:729–36.
- Scavarda D, Gabaudan C, Ughetto F, Lamy F, Imada V, Lena G, Paut O. Initial predictive factors of outcome in severe non-accidental head trauma in children. *Childs Nerv Syst* 2010 (in press).
- Eichelberger MR, Gotschall CS, Sacco WJ, Bowman LM, Mangubat EA, Lowenstein AD. A comparison of the trauma score, the revised trauma score, and the pediatric trauma score. *Ann Emerg Med* 1989;18:1053–8.
- Ramenofsky ML, Ramenofsky MB, Jurkovich GJ, Threadgill D, Dierking BH, Powell RW. The predictive validity of the Pediatric Trauma Score. *J Trauma* 1988;28:1038–42.
- Letts M, Davidson D, Lapner P. Multiple trauma in children: Predicting outcome and long-term results. *Can J Surg* 2002;45:126–31.
- Schalamon J, v Bismarck S, Schober PH, Höllwarth ME. Multiple trauma in pediatric patients. *Pediatr Surg Int* 2003;19:417–23.
- van der Sluis CK, Kingma J, Eisma WH, ten Duis HJ. Pediatric polytrauma: short-term and long-term outcomes. *J Trauma* 1997;43:501–6.
- Sookplung P, Vavilala MS. What is new in pediatric traumatic brain injury? *Curr Opin Anaesthesiol* 2009;22:572–8.
- Ruchholtz S, Nast-Kolb D. Craniocerebral trauma. *Chirurg* 2002;73:194–207; (quiz 208–9).
- Taylor A, Butt W, Rosenfeld J, Shann F, Ditchfield M, Lewis E, Klug G, Wallace D, Henning R, Tibballs J. A randomized trial of very early decompressive craniectomy in children with traumatic brain injury and sustained intracranial hypertension. *Childs Nerv Syst* 2001;17:154–62.
- Bliss D, Silen M. Pediatric thoracic trauma. *Crit Care Med* 2002;30:5409–15.
- Till H. Das thoraxtrauma im Kindesalter. In: Rueger JM, Schlickewei W, Engert J, Sommerfeldt DW, eds. *Das Kindliche Polytrauma*. Darmstadt: Steinkopff; 2004:75–81.
- Ceran S, Sunam GS, Aribas OK, Gormus N, Solak H. Chest trauma in children. *Eur J Cardiothorac Surg* 2002;21:57–9.

35. Dereeper E, Ciardelli R, Vincent JL. Fatal outcome after polytrauma: Multiple organ failure or cerebral damage? *Resuscitation* 1998;36:15–8.
36. Landau A, van As AB, Numanoglu A, Millar AJ, Rode H. Liver injuries in children: the role of selective non-operative management. *Injury* 2006;37:66–71.
37. Peitzman AB, Ford HR, Harbrecht BG, Potoka DA, Townsend RN. Injury to the spleen. *Curr Probl Surg* 2001;38:932–1008.
38. Tinkoff G, Esposito TJ, Reed J, Kilgo P, Fildes J, Pasquale M, Meredith JW. American Association for the Surgery of Trauma Organ Injury Scale I: spleen, liver, and kidney, validation based on the National Trauma Data Bank. *J Am Coll Surg* 2008;207:646–55.
39. Gaines BA, Ford HR. Abdominal and pelvic trauma in children. *Crit Care Med* 2002;30:S416–23.
40. Meier DE, Coln CD, Hicks BA, Guzzetta PC. Early operation in children with pancreas transection. *J Pediatr Surg* 2001;36:341–4.
41. Schlickewei W, Keck T. Pelvic and acetabular fractures in childhood. *Injury* 2005;36:A57–63.
42. Smith WR, Oakley M, Morgan SJ. Pediatric pelvic fractures. *J Pediatr Orthop* 2004;24:130–5.
43. Demetriades D, Karaiskakis M, Velmahos GC, Alo K, Murray J, Chan L. Pelvic fractures in pediatric and adult trauma patients: are they different injuries? *J Trauma* 2003;54:1146–51; (discussion 1151).
44. Thannheimer A, Buehren V. Becken. In: Marzi I, ed. *Kindertraumatologie*. Darmstadt: Steinkopff; 2006:249–68.
45. Holt GE, Mencio GA. Pelvic C-clamp in a pediatric patient. *J Orthop Trauma* 2003;17:525–7.
46. Spiguel L, Glynn L, Liu D, Statter M. Pediatric pelvic fractures: a marker for injury severity. *Am Surg* 2006;72:481–4.
47. Leonard M, Sproule J, McCormack D. Paediatric spinal trauma and associated injuries. *Injury* 2007;38:188–93.
48. Gore PA, Chang S, Theodore N. Cervical spine injuries in children: attention to radiographic differences and stability compared to those in the adult patient. *Semin Pediatr Neurol* 2009;16:42–58.
49. Bulas DI, Fitz CR, Johnson DL. Traumatic atlanto-occipital dislocation in children. *Radiology* 1993;188:155–8.
50. Rose S, Marzi I. Wirbelsäule. In: Marzi I, ed. *Kindertraumatologie*. Darmstadt: Steinkopff; 2006:397–430.
51. Blauth M, Schmidt U. Wirbelsäulenverletzungen bei Kindern. In: Tscherne H, ed. *Unfallchirurgie—Wirbelsäule*. Berlin: Springer; 1998:383–99.
52. Blauth M, Schmidt U, Lange U. Injuries of the cervical spine in children. *Unfallchirurg* 1998;101:590–612.
53. Vialle LR, Vialle E. Pediatric spine injuries. *Injury* 2005;36:B104–12.
54. Platzer P, Jandl M, Thalhammer G, Dittrich S, Kutscha-Lissberg F, Vecsei V, Gaebler C. Cervical spine injuries in pediatric patients. *J Trauma* 2007;62:389–96; (discussion 394–6).
55. Jakob H, Marzi I. Das polytrauma im Kindesalter. In: Oestern HJ, ed. *Das Polytrauma. Präklinisches und Klinisches Management*. München: Elsevier; 2008:321–43.
56. Keel M, Trentz O. Pathophysiology of polytrauma. *Injury* 2005;36:691–709.
57. Odetola FO, Miller WC, Davis MM, Bratton SL. The relationship between the location of pediatric intensive care unit facilities and child death from trauma: a county-level ecologic study. *J Pediatr* 2005;147:74–7.
58. Hahn YS, Fuchs S, Flannery AM, Barthel MJ, McLone DG. Factors influencing posttraumatic seizures in children. *Neurosurgery* 1988;22:864–7.
59. Raimondi AJ, Hirschauer J. Head injury in the infant and toddler. Coma scoring and outcome scale. *Childs Brain* 1984;11:12–35.
60. Fritz H, Bauer R. Prehospital immediate care of severe traumatic brain injury in children. *Notfall Rettungsmedizin* 2002;5:335–40.
61. Jöhr M. Schädelhirntrauma. In: Jöhr M, ed. *Kinderanästhesie*. Lübeck: Fischer; 1998:207–12.
62. Frank J, Marzi I, Mutschler W. Shock room management of polytrauma. *Zentralbl Chir* 1996;121:943–9.
63. Helm M, Kulla M, Lampl L. Advanced Trauma Life Support. A training concept also for Europe. *Anaesthesist* 2007;56:1142–6.

Address for Correspondence

Prof. Dr. Ingo Marzi
 Department of Trauma, Hand
 and Reconstructive Surgery
 Johann Wolfgang Goethe University Medical School
 Theodor-Stern-kai 7
 60590 Frankfurt/Main
 Germany
 Phone (+49/69) 6301-6123, Fax -6439
 e-mail: marzi@trauma.uni-frankfurt.de