Surg Endosc (2010) 24:2085–2091
DOI 10.1007/s00464-010-0902-8

ORIGINAL ARTICLES

Comparison of short- and medium-term results between laparoscopically assisted and totally laparoscopic right hemicolectomy: a case-control study

Massimiliano Fabozzi · Rosaldo Allieta · Riccardo Brachet Contul · Manuela Grivon · Paolo Millo · Elena Lale-Murix · Mario Nardi Jr.

Received: 6 September 2009 / Accepted: 11 January 2010 / Published online: 21 February 2010
© Springer Science+Business Media, LLC 2010

Abstract
Background This study aimed to compare the short- and medium-term results obtained by totally laparoscopic right colectomy (TL) with those obtained by laparoscopically assisted right colectomy (LAC) for the treatment of right colon cancer.
Methods A retrospective study compared two nonstatistically different groups (50 TL and 50 LAC cases) managed for nonmetastatic malignant tumors. The study outcomes included operative time, length of minilaparotomy, intraoperative complications, postoperative pain, time to resumption of the gastrointestinal functions, permanence of abdominal drain, analgesic therapy duration, postoperative complications, hospitalization time, number of harvested lymph nodes, and distant metastases onset.
Results The mean operative times were 78 ± 25 min (TL group) and 92 ± 22 min (LAC group) ($p < 0.05$). The findings showed a lower postoperative pain level associated with a reduction in analgesic consumption ($p > 0.05$) and earlier restoration of digestive function in the TL group than in the LAC group. The mean hospital stays were approximately 5 days (TL) and 7 days (LAC) ($p < 0.05$). No complications occurred either intra- or postoperatively, and similarly, the TL group experienced no mortality. In comparison, the LAC group had a 30% complication rate ($p < 0.05$). The complications included one case of intraoperative small bowel lesion, three cases of postoperative respiratory infections, three cases of anastomotic leakage, two cases of intestinal occlusion, three cases of minilaparotomy infection, one case of postoperative femoral neurosis, one case of postoperative heart attack, and one case of postoperative pancreatitis. The mortality rate was 0%. Neither group had a recurrence of the neoplastic disease during a 4-year follow-up period.
Conclusions The findings seem to demonstrate that TL right colectomy is feasible and safe, yielding results comparable with those of the open approach but offering improved postoperative patient comfort. The limits of this retrospective comparative study do not allow definitive conclusions to be drawn despite the encouraging data for the next prospective randomized studies.

Keywords Intracorporeal anastomosis · Laparoscopic right colectomy · Laparoscopically assisted right colectomy

M. Fabozzi (✉) · R. Allieta · R. B. Contul · M. Grivon · P. Millo · E. Lale-Murix · M. Nardi Jr.
Department of General Surgery,
Aosta Valley Regional Hospital "Umberto Parini",
via Adamello, 16, 11100 Aosta, Italy
e-mail: maxfabozzi@yahoo.fr

Right colectomy is indicated for malignant pathologies involving the intestinal tract between the ileocecal Bahuino valve and the colic hepatic flexure. Laparoscopic resection must respect the same oncologic criteria as the open approach including the no-touch isolation technique, isolation and ligation of the vascular pedicles at the origin, oncologic lymphadenectomy, and distal and radial clearance of the neoplasm from resection margins [1, 2].

Laparoscopic surgery is universally accepted and validated for the treatment of left colonic and rectal oncologic pathologies, but it has been applied only recently to the right colon [3–7] for two main reasons: anatomic variability of the viscera (the cecum may be detected in the subhepatic or periumbilical region or in the right iliac fossa) and, most importantly, the anatomic variability of

vascular pedicles. In fact, the right or middle colic arteries may be absent and an accessory middle colic artery or an accessory branch of the middle colic artery for the splenic flexure may be found. We also have found a common origin for the right colic artery and the ileocolic arteries or for the right and middle colic arteries. Another possibility is Riolan's arcade between the middle and left colic arteries and an anomalous origin of the middle colic artery from a branch of the celiac trunk [8, 9].

Two major procedures have been described for the treatment of right colon tumors: video-assisted right colectomy (LAC), involving vascular ligation and ileocolic mobilization by laparoscopy followed by extracorporeal intestinal resection and anastomosis [1, 10, 11], and totally laparoscopic (TL) resection, with the whole procedure performed by laparoscopy [12–14].

This study aimed to compare, in the short and medium term, the results obtained by TL right colectomy with those achieved by the laparoscopically assisted right colectomy for the treatment of right colon cancer.

Materials and methods

From January 2001 to March 2009, we performed 139 laparoscopic right colectomies: 16 (11.5%) for benign pathologies and 123 (88.5%) for neoplastic diseases.

A retrospective study compared 50 TL and 50 LAC cases managed for nonmetastatic malignant tumors. The exclusion criteria specified patients treated before 2001 because they were part of our learning curve and could have altered the study, an American Society of Anesthesiology (ASA) classification higher than 2, immunodepression, history of abdominal surgery, previous neoplastic disease, and acute complications of the tumor (perforation).

The two groups were not statistically different in terms of age, gender, body mass index (BMI), ASA score, indwelling time of the urinary catheter (UC), indwelling time of the nasogastric (NG) tube, or time of refeeding (Table 1). The study outcomes included operative time, length of minilaparotomy, intraoperative complications, postoperative pain, time to resumption of gastrointestinal functions (peristalsis, oral intake, defecation), permanence of the abdominal drain, duration of analgesic therapy, postoperative complications, hospitalization time (Table 2), number of harvested lymph nodes, and distant metastases onset during a 4-year follow-up period (Table 3).

Colonic preoperative washout for both groups was performed with 2 l of polyethylene glycol (PEG) per day for the 2 days before the operation in association with a fiber-free diet. Deep venous thrombosis prophylaxis was achieved with low-molecular-weight heparin (4,000 IU) from the evening before the procedure until postoperative day (POD) 30, antithromboembolic graduated compression stockings (18 mmHg), and an intermittent pneumatic compression (IPC) device from the day of surgery until complete mobilization of the patients.

The day before the operation, all the patients underwent placement of an antalgic peridural catheter with 0.5% levobupivacaine (4 ml/h). The next day, in the operating room after anesthetic induction, we also placed an NG tube and a UC catheter according to Kehlet protocols [15, 16]. Furthermore, all the patients received antibiotic prophylaxis with 2 g of cefotaxime 1 h before the incision and 500 mg of metronidazole 1 h before the induction and then 8 and 16 h after the operation.

With LAC, the extraction of the operative specimen and the anastomosis were performed through a 12 ± 2-cm incision in the right superior abdominal quadrant. In contrast, TL colectomy required the 6 ± 1-cm suprapubic minilaparotomy only for the specimen extraction. The procedures were considered curative only when no secondary locations were evident intraoperatively.

The NG tube and the UC were removed the morning after surgery in accordance with the Kehlet protocols. On POD 1, endovenous hydrations were suspended, and the patients were allowed to drink liquids with oral assumption of medicines. On day 2, the patients began oral intake of a light fiber-free diet, which was continued until day 20. In

Table 1 Patient data and operative parameters[a]

	Laparoscopically assisted	Totally laparoscopic	*p* Value
Patients (*n*)	50	50	NS
Age (years)	59.4 ± 9.5	62.1 ± 8.3	NS
Sex (F/M)	33/17	29/21	NS
BMI (kg/m^2)	22.1 ± 1.6	21.4 ± 2.3	NS
ASA 1	12	13	NS
ASA 2	38	37	NS
NG tube removal	POD 1	POD 1	NS
Urinary catheter	POD 1	POD 1	NS
Time of refeeding	POD 1	POD 1	NS

NS not statistically significant (>0.05), *BMI* body mass index, *ASA* American Society of Anesthesiology, *NG* nasogastric, *POD* postoperative day

[a] The data are expressed as mean ± standard deviation

Table 2 Outcomes

Outcomes	Laparoscopically assisted	Totally laparoscopic	*p* Value
Operative time (min)	92 ± 22	78 ± 25	<0.05
Intraoperative complications (small bowel lesion)	1	0	NS
Minilaparotomy size (cm)	12 ± 2	6 ± 1	<0.05
Time to first peristalsis (days)	2.6 ± 0.6	1.3 ± 0.7	NS
Time to first defecation (days)	4.4 ± 1.6	3.1 ± 1.2	NS
Permanence of drain (days)	3.3 ± 1.7	2.1 ± 1.3	NS
Postoperative pain (VAS pain scale)	6.6	3.2	<0.05
Analgesic therapy duration (days)	5. 8 ± 1.6	3.2 ± 1.2	<0.05
Postoperative complications: *n* (%)	14 (28)	0	<0.05
Hospital stay (days)	7.6 ± 1.2	5.3 ± 1.6	<0.05
Mortality	0	0	NS

NS not statistically significant (>0.05), *VAS* visual analog scale

Data are expressed as mean ± standard deviation

Table 3 Number of patients followed up

Follow-up period (years)	Laparoscopically assisted *n* (%)	Totally laparoscopic *n* (%)
4	50 (100)	8 (16)
3	50 (100)	19 (38)
2	50 (100)	28 (56)
1	50 (100)	38 (76)

addition to peridural analgesia, the antalgic protocol included administration of paracetamol 1,000 mg three times a day and morphine 5 mg subcutaneously on demand during POD 1. The antalgic peridural catheter was removed on POD 3, and antalgic therapy was continued orally with paracetamol-codeine 1 g three times a day and morphine 5 mg subcutaneously on demand until complete resolution of the pain.

All the patients underwent a cycle of postoperative physiokinesis therapy. They were discharged when they became autonomous in movements and walking, ate with a good appetite, and recovered good bowel function without fever or pain.

Table 4 Results of patients during a 4-year follow-up period

	Laparoscopically assisted	Totally laparoscopic	*p* Value
Lymph nodes (*n*)	17.2 ± 2.3	16.1 ± 2.5	NS
Resection margin infiltration	0	0	NS
Anastomotic recurrence	0	0	NS
Trocar-site recurrence	0	0	NS
Distant metastasis	0	0	NS

NS not statistically significant (>0.05)

Data are expressed as mean ± standard deviation

The patients were followed up for at least 1 year, starting on POD 30 and followed by assessments 3, 6, and 12 months after the operation, which involved clinical examination, blood tests including neoplasm markers, and ultrasonography every 6 months. Chest radiography and colonscopy were performed each year. After the first year, the patients were followed up every 6 months (by clinical examination, blood tests including neoplasm markers, and ultrasonography) until postoperative year 4 (Tables 3, 4). Computed tomography (CT) scanning was required in cases showing alteration of these tests (or diagnostic doubts) with suspicion of oncologic recurrence.

Statistical analysis

All the analyses were performed using SPSS as statistical software (version 13.0 for Windows). The Kolmogorov-Smirnov test was used to evaluate the data distribution. Student's *t*-test for unpaired samples was used to compare the results between the two groups when they were in a normal distribution model. Otherwise, the Mann–Whitney *U* test was used. A *p* value less than 0.05 was set as the criterion for statistical significance.

Results

The two groups were not statistically different in terms of demographic character ($p > 0.05$). The mean operative time was 78 ± 25 min in the TL group and 92 ± 22 min in the LAC group ($p < 0.05$), whereas the mean hospital stay was approximately 5 days for the TL group and 7 days for the LAC group ($p < 0.05$). We noted less postoperative pain associated with a reduction of analgesic consumption in the TL group ($p > 0.05$). An earlier restoration of digestive function was demonstrated by the precocious onset of peristalsis in the TL group (on POD 1) compared

with the LAC group (on POD 2). The drain was removed earlier in the TL group than in the LAC group due to a faster peristalsis restart (Table 2).

We had five cases (10%) of conversion to laparotomy in the TL group: two for tenacious adhesions, two for difficult identification of the tumor because of its small dimensions, and one for intestinal occlusion with dilated intestinal loops. There were no complications either intra- or postoperatively, and similarly, there was no intra- or perioperative mortality in the TL group (Table 2).

In contrast, the LAC group had a 30% complication rate. One accidental intraoperative perforation of a jejunal loop occurred during lysis of adhesions. During the postoperative period, there were three cases of respiratory infections, three anastomotic leakages in manual anastomosis performed by three different surgeons, two cases of intestinal occlusion caused by internal intermesenteric hernias, and three minilaparotomy infections ($p < 0.05$) (Fig. 1). Moreover, we had one case of postoperative femoral neurosis, one case of postoperative heart attack, and one case of postoperative pancreatitis, with a 0% mortality rate (Table 2).

The pathologic stages of resected tumors were found in the LA group and included 4 pT1N0M0 cases, 42 pT2N0M0 cases, and 4 pT3N0M0 cases, whereas the TL group had 3 pT1N0M0 cases, 45 pT2N0M0 cases, and 2 pT3N0M0 cases. There was no recurrence of the neoplastic disease at either the anastomotic site or the port site, or at the peritoneum or distant site in either of the two groups after a follow-up period of at least 1 year (Tables 3, 4).

Discussion

In our surgery division, right colon cancer was treated exclusively by LAC until 2003. In 2004, we began to perform TL right colectomies. It is important to underscore that after 2004, the open colectomies drastically declined, whereas TL colectomies accounted more than 90% of the total. This probably happened because we were not very sure about the real effectiveness and benefits of LAC compared with the "open" approach for right colon surgery [17]. On the contrary, the TL procedure improved patients' comfort and (after standardization of the technique) reduced operative times (Fig. 2).

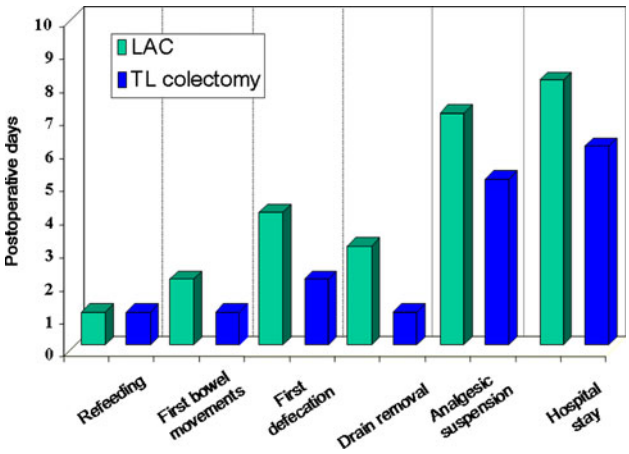

Fig. 2 Laparoscopically assisted versus totally laparoscopic right colectomy outcomes

The NG tube and the UC were removed on POD 1 in both groups, with low gastric stagnation (< 70 ml/24 h) and valid diuresis (>50 ml/h), whereas the abdominal drain was removed earlier in the TL group for the faster recovery of peristalsis (POD 1 for the TL vs POD 3 for the LAC; $p < 0.05$) (Fig. 2).

Although the same antalgic protocol was applied for all the patients, the postoperative pain was greater for the patients who underwent LAC because the incision in the right superior abdominal quadrant (Photo 1) was larger and

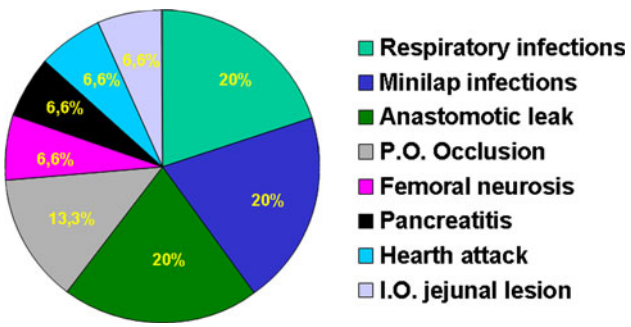

Fig. 1 Laparoscopically assisted laparoscopic right colectomy complications

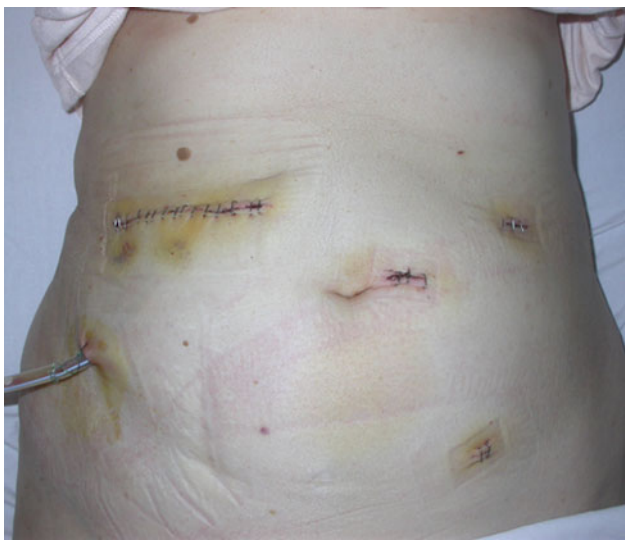

Photo 1 Minilaparotomy in laparoscopically assisted right colectomy

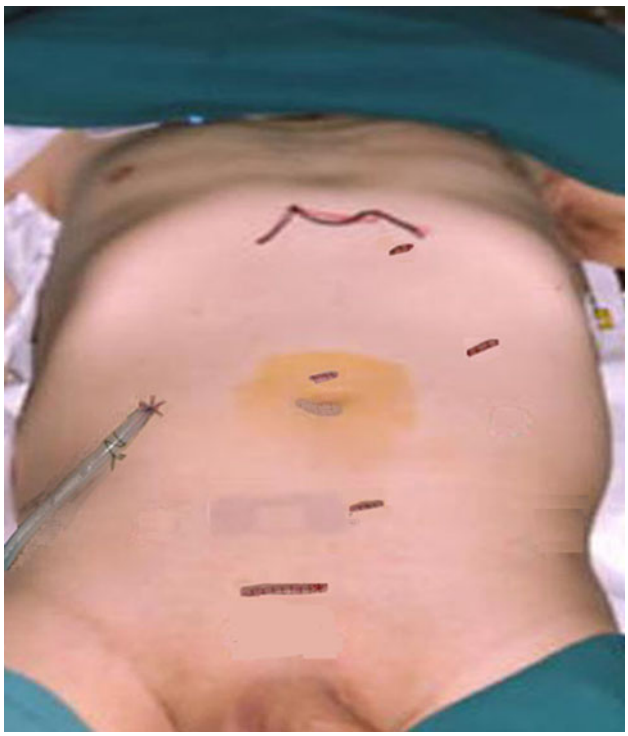

Photo 2 Minilaparotomy in totally laparoscopic right colectomy

during respiratory movements was subjected to a greater tension than the TL suprapubic incision (Photo 2).

We had three cases of wound infections among the patients treated using LAC, probably due to the larger size of the incision and the reduced tissue oxygenation [18]. In fact, the strong pain due to the minilaparotomy located in the right superior abdominal quadrant decreased respiratory excursions and led to basal atelectasia. This hypothesis was confirmed by the evidence that most LAC patients presented hypoxia at the arterial hemogas analysis and right basal atelectasia at pulmonary X-Ray. Likely, these same factors played an important role in causing the three respiratory infections that occurred in this group (Fig. 1).

On the contrary, in the TL procedure, the smaller dimensions of the incision (6–8 cm for TL vs 10–12 cm for LAC), its suprapubic position, and the absence of muscular sections reduced postoperative pain and the risk of incisional hernias, allowing a rapid wall suturing (fewer muscle layers) with reduced operative time. Restored gastrointestinal functions occurred earlier in the TL patients, even if oral intake of liquids began on POD 1 in both groups, in which the same stimulus resulted in a different response, with a reduction of postoperative hospitalization in TL group (Table 2).

Both approaches respect the oncologic principles of no manipulation of the neoplastic mass, proximal ligation of the vessels, oncologic lymphadenectomy, and "distal and radial clearance" of the tumor from resection margins as well as open surgery [1, 2, 12–14, 21, 22], but the TL approach seems to be confirmed as presenting some advantages:

- Oncologic: The removal of the operative specimen from the TL minilaparotomy is performed by a 15-mm Endocatch, preventing the peritoneal spreading of neoplastic cells (Photo 3).
- Technical: The facilitated closure of the mesos by laparoscopy in TL right colectomy avoids internal hernias, and the absence of mesos traction during the laparoscopic anastomosis allows a faster restoration of peristalsis (Photo 4).
- Aesthetic and functional: The smaller size of TL minilaparotomy (Photos 1, 2), with a low risk of infection and incisional hernias, reduced postoperative pain, inferior risk of respiratory infection, a better postoperative course, and shorter hospitalization, results in diminished assistance costs.

Laparoscopically assisted right colectomy may represent a valid alternative to total laparoscopic right colectomy such as the hand-assisted left colectomy for the laparoscopic left colectomy [19, 20]. Until 2003, we did not notice real advantages in right LAC for the right

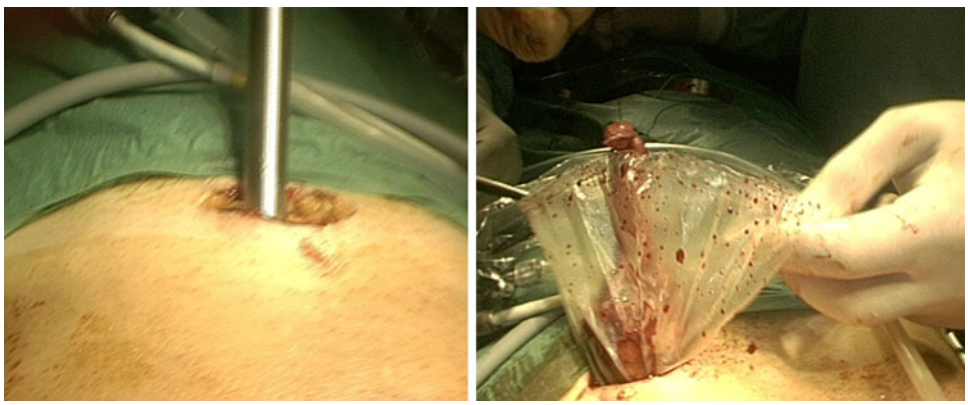

Photo 3 Specimen extraction through suprapubic minilaparotomy by Endocatch

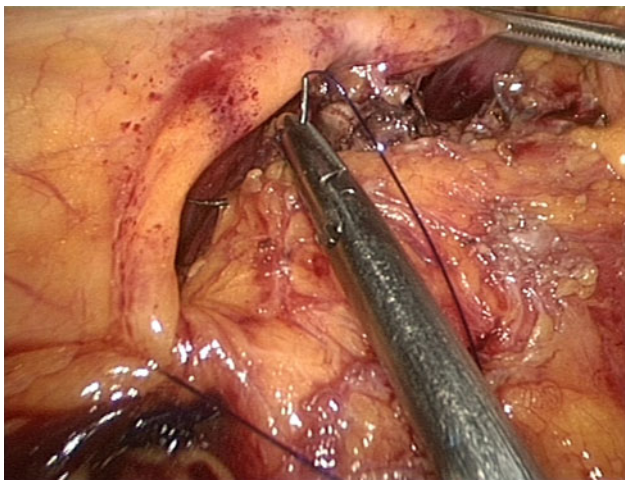

Photo 4 Laparoscopic ileocolic mesos suturing in totally laparoscopic right colectomy

Table 5 Comparison between the different laparotomies

Laparotomy	Suprapubic	Right hypocondrium
Dimension	↓	↑
Wound infection	↓	↑
Incisional hernia	↓	↑
Postoperative pain	↓	↑
Respiratory function	↓	↑

colon, with open right colectomy achieving surgically equivalent results but posing laparoscopic technical difficulties. Instead, after 2004, with the standardization of right TL colectomy, we found, as demonstrated in this study, it had more clinical advantages than LAC including better postoperative results in terms of patient comfort. Moreover, the oncologic results seem comparable with those for open surgery, as shown in laparoscopy during the treatment of left colonic and rectal pathologies, considering that laparoscopy is only a different abdominal approach.

As shown by the current findings, TL right colectomy is a feasible and safe procedure that achieves oncologic results comparable with those for the open approach and improved postoperative patient comfort (Table 5; Photo 1). However, great surgical experience, advanced technology, and continuous-technique performance are necessary to standardize and make the technique reproducible [12–14, 21, 22].

The limitations of our retrospective comparative study obviously do not allow us to draw definitive conclusions, and further prospective randomized studies are necessary to confirm our data, which, however, remain encouraging.

Disclosure Massimiliano Fabozzi, Rosaldo Allieta, Riccardo Brachet Contul, Manuela Grivon, Paolo Millo, Elena Lale-Murix, and Mario Nardi Jr have no conflicts of interest or financial ties to disclose.

References

1. Bretagnol F, Alves A, Panis Y (2007) Tecnica della colectomia destra in laparoascopia. Encycl Méd Chir (EMC). Elsevier Masson SAS, Paris, Tecniche Chirurgiche Addominale, pp 40–563
2. Liang JT, Lai HS, Lee PH (2007) Laparoscopic medial-to-lateral approach for the curative resection of right-sided colon cancer. Ann Surg Oncol 14:1878–1879
3. Zheng MH, Feng B, Lu AG, Li JW, Wang ML, Mao ZH, Hu YY, Dong F, Hu WG, Li DH, Zang L, Peng YF, Yu BM (2005) Laparoscopic versus open right hemicolectomy with curative intent for colon carcinoma. World J Gastroenterol 11:323–326
4. Kuhry E, Schwenk WF, Gaupset R, Romild U, Bonjer HJ (2008) Long-term results of laparoscopic colorectal cancer resection. Cochrane Database Syst Rev 16(2):CD003432
5. Buunen M, Veldkamp R, Hop WC, Kuhry E, Jeekel J, Haglind E, Påhlman L, Cuesta MA, Msika S, Morino M, Lacy A, Bonjer HJ, Colon Cancer Laparoscopic or Open Resection Study Group (2009) Survival after laparoscopic surgery versus open surgery for colon cancer: long-term outcome of a randomised clinical trial. Lancet Oncol 10:44–52
6. Kahnamoui K, Cadeddu M, Farrokhyar F, Anvari M (2007) Laparoscopic surgery for colon cancer: a systematic review. Can J Surg 50:48–57
7. Lelong B, Bege T, Guiramand J, Turrini O, Delpero JR (2007) Colon cancer and laparoscopy: state of the art in 2007. Bull Cancer 94:1053–1058
8. Shatari T, Fujita M, Nozawa K, Haku K, Niimi M, Ikeda Y, Kann S, Kodaira S (2003) Vascular anatomy for right colon lymphadenectomy. Surg Radiol Anat 25:86–88
9. Netter FH; Atlante di Anatomia Fisiopatologia e Clinica (2002) Anatomia Fisiopatologia e clinica del Colon destro. Vol 6. Tomo 2. Ed. Elsevier Masson, Milano
10. Ramacciato G, D'Angelo F, Aurello P, Nigri G, Valabrega S, Pezzoli F, Ravaioli M, Cescon M, Cucchetti A, Lauro A, Del Gaudio M, Ercolani G (2008) Right hemicolectomy for colon cancer: a prospective randomised study comparing laparoscopic vs open technique. Chir Ital 60:1–7
11. Chung CC, Ng DC, Tsang WW, Tang WL, Yau KK, Cheung HY, Wong JC, Li MK (2007) Hand-assisted laparoscopic versus open right colectomy: a randomized controlled trial. Ann Surg 246:728–733
12. Casciola L, Ceccarelli G, Di Zitti L, Valeri R, Bellochi R, Bartoli A, Barbieri F, Spaziani A, D'Ajello M (2003) Laparoscopic right hemicolectomy with intracorporeal anastomosis: technical aspects and personal experience. Minerva Chir 58:621–627
13. Raftopoulos I, Courcoulas AP, Blumberg D (2006) Should completely intracorporeal anastomosis be considered in obese patients who undergo laparoscopic colectomy for benign or malignant disease of the colon? Surgery 140:675–682
14. Bergamaschi R, Schochet E, Haughn C, Burke M, Reed JF, Arnaud JP (2008) Standardized laparoscopic intracorporeal right colectomy for cancer: short-term outcome in 111 unselected patients. Dis Colon Rectum 51:1350–1355
15. Kehlet H, Wilmore DW (2002) Multimodal strategies to improve surgical outcome. Am J Surg 183:630–641

16. Kehlet H (2009) Multimodal approach to postoperative recovery. Curr Opin Crit Care 15:355–358
17. Lohsiriwat V, Lohsiriwat D, Chinswangwatanakul V, Akaraviputh T, Lert-Akyamanee N (2007) Comparison of short-term outcomes between laparoscopically assisted vs transverse-incision open right hemicolectomy for right-sided colon cancer: a retrospective study. World J Surg Oncol 5:49
18. Nakamura T, Mitomi H, Ihara A, Onozato W, Sato T, Ozawa H, Hatade K, Watanabe M (2008) Risk factors for wound infection after surgery for colorectal cancer. World J Surg 32:1138–1141
19. Lee SW, Yoo J, Dujovny N, Sonoda T, Milsom JW (2006) Laparoscopic vs hand-assisted laparoscopic sigmoidectomy for diverticulitis. Dis Colon Rectum 49:464–469
20. Aalbers AG, Biere SS, van Berge Henegouwen MI, Bemelman WA (2008) Hand-assisted or laparoscopic-assisted approach in colorectal surgery: a systematic review and meta-analysis. Surg Endosc 22:1769–1780
21. Li JC, Hon SS, Ng SS, Lee JF, Yiu RY, Leung KL (2009) The learning curve for laparoscopic colectomy: experience of a surgical fellow in an university colorectal unit. Surg Endosc 23:1603–1608
22. Koopmann MC, Heise CP (2008) Laparoscopic and minimally invasive resection of malignant colorectal disease. Surg Clin North Am 88:1047–1072