Vascular and Endovascular Surgery
45(7) 631-635
© The Author(s) 2011
Reprints and permission:
sagepub.com/journalsPermissions.nav
DOI: 10.1177/1538574411413938
http://ves.sagepub.com
SAGE

Cyanoacrylate Adhesive for the Closure of Truncal Veins: 60-Day Swine Model Results

Jose I. Almeida, MD[1], Robert J. Min, MD[2], Rod Raabe, MD[3], D. J. McLean, PhD[4], and Monte Madsen, RVT[5]

Abstract

Background: The introduction of cyanoacrylate (CA) within a blood vessel triggers polymerization, followed by an inflammatory reaction. *Methods*: A sheath was positioned 2.0 cm caudad to the junction of the superficial epigastric and abdominus rectus veins in 2 swine, followed by ultrasound-guided injection of 0.16 mL of CA glue. After glue delivery, the catheter was pulled back 3 cm, compression was applied to the treatment site, and the process was repeated for the entire length. At 60 days postimplantation, the veins were harvested surgically and examined histologically. *Results*: The histologic changes were consistent with a chronic foreign-body-type inflammatory response. Venous closure, segmental wall thickening, and fibrosis were observed. *Conclusion*: Injection of CA is feasible for closure of superficial veins in animal models. Vein closure is achieved via an inflammatory process which ultimately leads to fibrosis.

Keywords

varicose veins, chronic venous disease, thermal ablation, endovenous laser, cyanoacrylate glue

Introduction

Cyanoacrylate (CA), commonly referred to as "superglue," has gained momentum in recent years for intravascular use to treat conditions such as arteriovenous malformations (AVMs), pelvic congestion syndrome, and varicoceles. Although permitted for use in endovascular procedures in Europe for several decades, CA was not approved in the United States until 2000 when Trufill CA (Cordis, Miami Lakes, Florida) received US Food and Drug Administration (FDA) clearance for the devascularization of cerebral AVMs.[1] While its use is off-label for peripheral applications, the properties of CA make it ideal for a number of vascular occlusion procedures. When used intravascularly, CA triggers a robust inflammatory reaction in the vessel wall.

Anionic substances such as plasma, blood, or saline stimulate polymerization of the CA adhesive upon contact, leading to occlusion. The resultant polymerization damages the vascular intima and induces an acute immunological response.[2] After polymerization is complete, gradual resorption of the occlusive polymer takes place. Within approximately 1 month, the response progresses to granuloma formation with giant cells and eventually fibrosis.[3,4]

Introduction of CA into a vessel requires precise control of the rate of polymerization. Variables that can affect this rate include blood flow, vessel diameter, the velocity of injection, and the viscosity of CA. An overdiluted solution (polymerization rate too slow) can result in migration of a low-viscosity CA into unwanted areas. Conversely, a polymerization rate which is too rapid may induce overly viscous CA which may aggressively adhere the delivery catheter to the vessel wall. Currently, ethiodol is a commonly used agent for dilution of CA, largely due to its quick polymerization upon contact with ionic solutions.

The ability of the operator to control the rate of the reaction makes CA an ideal substance vascular work. One such application is closure of incompetent veins. Venous incompetence of the great saphenous vein, small saphenous vein, accessory saphenous veins is a prevalent cause of chronic venous disease. Venous reflux of the lower extremities occurs in an estimated 15% of all men and 28% of all women.[5] Treatment for this disease has evolved over the past 10 years from surgical saphenectomy (stripping), to the advent of minimally invasive radiofrequency ablation and endovenous laser ablation.

Radiofrequency ablation employs an electrode which delivers electromagnetic energy to the vein wall, producing heat, collagen contraction, and eventually fibrosis. Alternatively,

[1] Miami Vein Center, Miami, FL, USA
[2] Weill Cornell Medical College, New York City, NY, USA
[3] Sacred Heart Medical Center, Spokane, WA, USA
[4] Washington State University, Pullman, WA, USA
[5] Inland Imaging, Spokane, WA, USA

Corresponding Author:
Jose I. Almeida, Miami Vein Center, 1501 South Miami Avenue, Miami, FL, 33129, USA
Email: dralmeida@mac.com

Downloaded from ves.sagepub.com at Ebsco Electronic Journals Service (EJS) on December 2, 2011

endovenous laser ablation delivers photons intravascularly via a fiber-optic cable. After the photons are absorbed by chromophores, heat is produced causing vein wall damage and ultimately fibrosis. Both radiofrequency and endovenous laser ablation require large amounts of perivenous tumescent anesthesia to shrink the vein diameter and create a thermal barrier to prevent heat damage to adjacent structures. Numerous needle punctures into the perivenous space are used to deliver the tumescent. While thermal ablation has demonstrated efficacy rates >90%, postoperative pain and bruising are common side effects that cause patient discomfort.[6-8]

Alternative minimally invasive treatments for varicose veins are continually evolving to increase patient comfort, reduce risk, and control costs. Ultrasound-guided sclerotherapy has gained worldwide popularity; however, it embolizes systemically into the venous system with every injection. Venous embolization of foamed sclerosants is generally well tolerated; however, arterial embolization, seen rarely, can be devastating.[9]

Based on the success and safety of CAs in the occlusion of vascular malformations, this agent may be a viable treatment for lower extremity chronic venous disease. The aim of this study was to assess the feasibility of CA adhesive for vein closure in an animal model including its efficacy and effect on the vein wall.

Materials and Methods

A MicroMaxx (SonoSite, Bothell, Washington) high-resolution ultrasound system with a 7.5-MHz transducer was used for imaging. A 5F Micro Introducer Kit (Vascular Solutions, Minneapolis, Minnesota) was used to gain venous access. Insertion of the 5F CA adhesive delivery catheter (Sapheon, Santa Rosa, California) was facilitated with a 5F introducer sheath (Vascular Solutions). Along with a 5F delivery catheter, the venous closure system consisted of a 3-cc syringe, a dispenser tip, and a dispenser gun (Sapheon). The delivery catheter incorporated a 5-cm spacer for precise alignment within the sheath, as well as a spin-lock mechanism which enabled the catheter and sheath to be locked together. The dispenser gun was configured to deliver 0.16 cc of glue per trigger pull. The glue was delivered into the target vessel by advancing through the connected syringe and 5F delivery catheter tubing. The CA adhesive (Sapheon) is a proprietary glue formulation created specifically for this indication. The CA was mixed with a thickening agent to attain optimal viscosity and a curing retardant to control the rate of polymerization.

The right and left superficial epigastric veins (SEVs) of 2 swine, weighing 170 and 186 lbs, respectively, were chosen due to the vein's ideal diameter and length, as well as its likeness to the human great saphenous vein. The paired SEVs course along the abdominal wall and empty into the abdominus rectus vein (ARV) at the costal margin. The procedure was performed under general anesthesia administered and monitored by a veterinarian. Care of the live swine complied with the National Institutes of Health guidelines for laboratory animals and they were housed in accordance with United States Department of Agriculture (USDA) regulations and care.

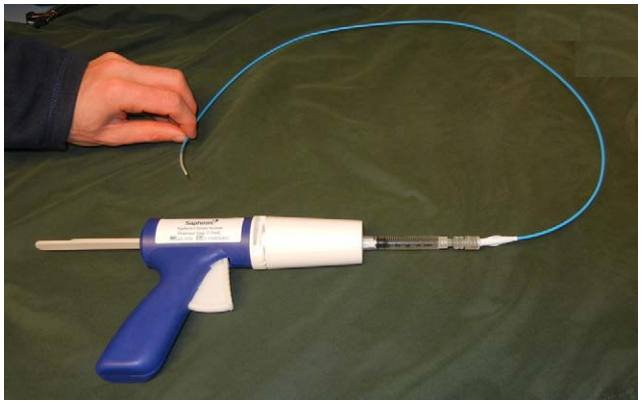

Figure 1. CA glue delivery system. CA indicates cyanoacrylate.

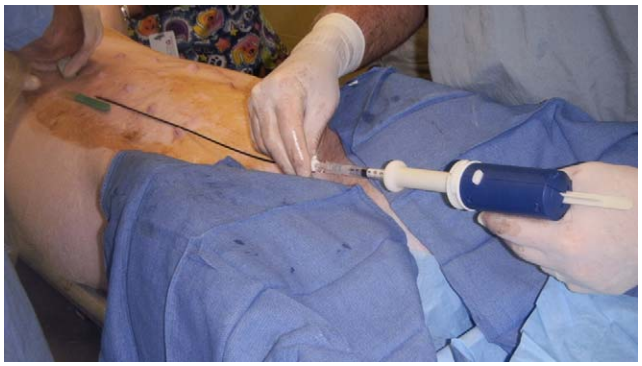

Figure 2. Positioning CA delivery system in swine specimen.

After prepping the abdominal wall, ultrasound was used to locate the SEV and determine a site for access. Standard micropuncture technique was used under ultrasound control, advancing a 0.018″ wire into the vein. A 5F micropuncture sheath/dilator was exchanged for a 0.035″ J guide wire (Vascular Solutions). Using real-time ultrasound, the guide wire was positioned just caudad to the junction of the SEV and ARV, and a 5F introducer sheath/dilator was advanced.

The CA glue was extracted from its glass vial and loaded into a syringe and attached to the 5F delivery catheter. The combined syringe and catheter were then connected to a dispenser gun, as shown in Figure 1. The catheter was then primed by advancing the glue with the dispenser gun to within 3 cm of the catheter tip.

The 5F introducer sheath was positioned 2.0 cm caudad from the SEV-ARV junction. The primed 5F delivery catheter was inserted into the sheath and advanced to the level of the 5-cm peel-away spacer on the catheter. The spacer was removed, enabling the sheath to be pulled back, exposing 5 cm of the catheter tip. Once locked into place with a spin-lock mechanism, the catheter tip was positioned 2.0 cm from the junction (Figure 2).

Downloaded from ves.sagepub.com at Ebsco Electronic Journals Service (EJS) on December 2, 2011

The ultrasound transducer was positioned transversely just cephalad to the catheter tip and pressure was applied to compress the SEV-ARV junction. Using a slow deliberate trigger pull of 3-second duration, 0.16 mL of CA was delivered to the target vein. The delivery system (sheath and catheter) was immediately pulled back 3 cm after this initial injection and transverse venous compression applied for 30 seconds to allow interaction between the CA glue and the vein wall.

In preparation for the next injection, the ultrasound probe was repositioned at the catheter tip. Once in place, the vein was compressed with the ultrasound probe caudad to the initial injection site but cephalad to the catheter tip. As with the first injection, the trigger was depressed for 3 seconds, delivering 0.16 mL into the vein. After completing the injection, the delivery system was pulled back another 3 cm and compression was applied at the injection site. These steps were repeated until the entire vein segment was treated. After the last CA injection was administered, the delivery system was removed and vein closure was confirmed under ultrasound.

Two SEVs were treated per animal. Both swine had uneventful postprocedure courses and were sacrificed 60 days postimplantation. An independent pathologist harvested the right and left epigastric veins of each animal model. Cross-sections of both the cephalad and the caudal ends of the SEV were studied, as well as side branches arising from the treated SEV. The effects of the adhesive on the epithelium, the presence, or absence of the adhesive within the lumen, and the degree of inflammation were assessed microscopically. In addition, a noninjected segment of each SEV was studied histologically as a control.

Results

Swine Model #1

The left SEV of this model measured 4.4 mm in diameter and received 11 continuous injections for a total of 1.7 cc of CA. Most of the vein showed a pale color, with CA present in the lumen. Some areas of the vein presented with a dark color, which was a result of blood mixing with CA during injection (Figure 3). However, this dark color was not visible through the skin. Explanted segments from the caudad, middle, and cephalad areas were completely occluded with no patent segments.

Histologically, fibrous tissue and inflammatory cells were present, with 1 of the 3 examined sections exhibiting fibrotic projections which caused occlusion of nearly the entire lumen (Figure 4a and b). The wall was segmentally thickened by fibrous tissue and the lumen was dilated by an abundant clear space containing moderate amounts of debris and coalescing, arborizing bands of microphages and spindle cells. The clear space was often surrounded by multinucleated giant cells, which were presumed to be reacting toward foreign material. Spindle cells with dense eosinophilic matrix replaced the tunica intima and disrupted the tunica media. Additionally, the wall was disrupted by numerous aggregates of histiocytes and lymphocytes with lymphoid follicles.

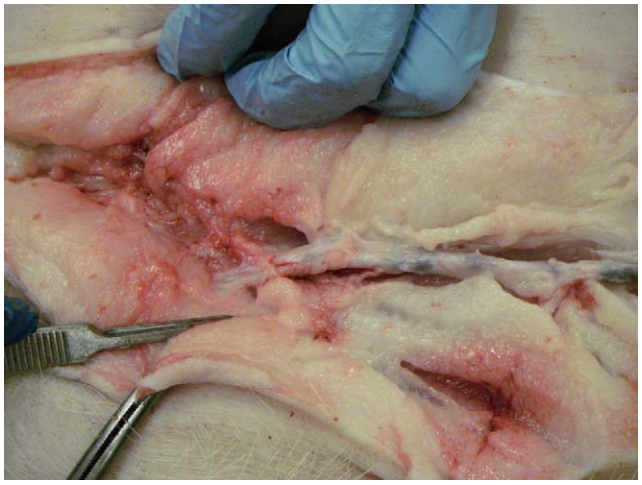

Figure 3. Injected, occluded vein with dark areas as a result of cyanoacrylate mixing with blood.

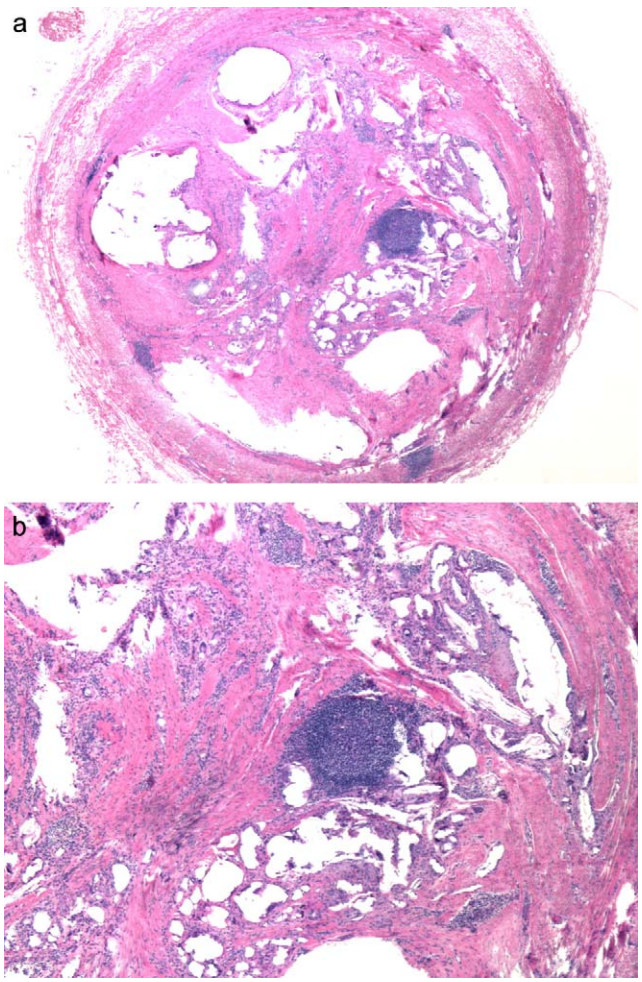

Figure 4. a, 4b(50×). Partial occlusion of vein lumen by projections of fibrous tissue and inflammation.

Downloaded from ves.sagepub.com at Ebsco Electronic Journals Service (EJS) on December 2, 2011

Figure 5. A short segment of entrapped blood (dark bulge).

Similarly, the right SEV of this model measured 4.5 mm in diameter and received 9 continuous injections for a total of 1.4 cc of CA. Gross inspection revealed findings analogous to the left vein, a pale color with occasional dark areas resulting from the pooling of blood and CA. At the caudad end of the treated vein, there were 2-side branches which were not injected with CA and remained patent. Examination of 4 cross-sections demonstrated histology comparable to that of the left SEV.

Swine Model #2

The diameter of the left SEV from this model was recorded at 4.2 mm, with a total CA injection of 1.8 cc with 10 continuous injections. This vein was completely occluded with no visible patency in the vein. Cyanoacrylate was present throughout the segment, with most of the vein exhibiting a pale color. Although not visible on the skin, a dark-colored bulge (entrapped blood) in the vein was observed (Figure 5). Microscopically, this left SEV was similar to that observed in the left and right SEV of model #1.

The right SEV had the largest diameter of the treated veins at 4.5 mm but was the shortest in length with a resultant 1.2 cc of CA delivered over 8 injections. Comparable to the other treated veins, this vein was totally occluded with CA in the lumen, presenting as a pale color with intermittent dark areas. As with the right vein of model #1, 2 patent side branches were identified at the caudad end of the injected segment. Histological findings mirrored that of the other 3 treated veins.

The changes observed in the 4 treated veins are consistent with chronic foreign-body-type inflammatory response. Unwanted migration of CA was not found, nor was recanalization present in any of the treated veins. Evaluation of control segments lacked any significant histologic changes.

Discussion

Cyanoacrylate polymerization-binding mechanics have been investigated previously in animal models. The use of CA for closure of a swine SEV in this small study proved to be feasible and well tolerated for 60 days. The acute inflammation, the formation of foreign body giant cells and granulomas, followed by fibrosis—was histologically seen in this study and previously by others.[8,10]

In an explanted swine common carotid artery model, Kailasnath and Chaloupka[11] identified 3 phases of polymerization: (1) initial rapid polymerization with increasing tensile forces lasting approximately 10 seconds; (2) a second phase which displayed a constant tensile force and spanned up to 1 minute in length; and (3) a final phase characterized by a rapid, exponential rise of tensile force that completed the polymerization. The polymerization times varied based on the formulation and type of CA and the amount of intravascular blood or saline.

This multiphasic concept coincides with our procedural approach. Our protocol was to inject 0.16 cc into the vein and retract the catheter 3 cm before the initial polymerization phase was complete. To ensure coaptation of the vein walls, compression was applied for 30 seconds, allowing polymerization to advance well into the second phase or possibly to completion before administering the next CA injection. The manual compression technique creates a bloodless intravascular environment; hence, we deduce that vessel closure in the current study was achieved mostly by CA adhesion to the vein wall, as opposed to a reaction with blood causing occlusion.

Intravascular injection of CA has been previously reported using a continuous pullback method.[12] Overly aggressive adhesion of the catheter tip to the vein wall by the CA glue is a fundamental concern, and therefore the technique described here incorporated immediate catheter pullback after injection and a proprietary CA to prevent premature curing of the adhesive. A hydrophobic delivery catheter was created to further retard interaction with the CA glue.

Grossly, the surrounding tissues in our swine models did not show any visible damage. Although we did not analyze the perivenous tissue histologically, other investigators[13] have studied various CA formulations and reported that the inflammatory reaction was contained within the vessel lumen and did not affect perivascular tissues. Current ablation devices emit heat directly or indirectly into the vessel lumen and may damage perivenous tissue and lead to complications such as skin burns or paresthesia.[14] To avoid these injuries, tumescent anesthesia is injected around the vein and creates a heat sink.

Although perivenous tumescent anesthesia has been largely successful in preventing heat-related damage, it requires numerous needle sticks and can cause vessel perforation from unintentional needle sticks of the vein wall, resulting in postoperative bruising and pain.[15-17] An advantage of CA delivery is the elimination of perivenous tumescent anesthesia, but further studies are needed to assess its effects on perivenous tissue.

This 60-day study successfully validated that the use of CA for superficial vein closure is feasible in animal models. Delivery of the CA was easy. The CA adhesive behavior was consistent in this small sample, and no complications were observed. The presence of fibrotic tissue was an indicator that durable closure was likely. Future evaluations of this technology should

Downloaded from ves.sagepub.com at Ebsco Electronic Journals Service (EJS) on December 2, 2011

include a comprehensive assessment of CA's effect on bordering tissues. A small pilot study on human subjects is underway.

Declaration of Conflicting Interests

The authors declared no potential conflicts of interest with respect to the research, authorship, and/or publication of this article.

Funding

The authors disclosed receipt of the following financial support for the research, authorship, and/or publication of this article:The authors received research grant financial support from Sapheon, Inc.

References

1. Pollak JS, White RI. The use of cyanoacrylate adhesives in peripheral embolization. *J Vasc Interv Radiol*. 2001;12(8): 907-913.
2. Levrier O, Mekkaoui C, Rolland PH, et al. Efficacy and low vascular toxicity of embolization with radical versus anionic polymerization of n-butyl-2-cyanoacrylate (NBCA): an experimental study in the swine. *J Neuroradiol*. 2003;30(2):95-102.
3. Vinters HV, Galil KA, Lundie MJ, Kaufmann JC. The histotoxicity of cyanoacrylates: a selective review. *Neuroradiology*. 1985;27(4): 279-291.
4. Spiegel SM, Vinuela F, Goldwasser JM, Fox AJ, Pelz DM. Adjusting the polymerization time of isobutyl-2 cyanoacrylate. *Am J Neuroradiol*. 1986;7(1):109-112.
5. Criqui MH, Jamosmos M, Fronek A, et al. Chronic venous disease in an ethnically diverse population: the San Diego population study. *Am J Epidemiol*. 2003;158(5):448-456.
6. Almeida JI, Kaufmann J, Gockeritz O, et al. Radiofrequency endovenous closure FAST versus laser ablation for the treatment of great saphenous vein reflux: a multicenter, single-blinded, randomized study (RECOVERY study). *J Vasc Interv Radiol*. 2009; 20(6):752-759.
7. Proebstle TM, Vago B, Alm J, et al. Treatment of the incompetent great saphenous vein by endovenous radiofrequency powered segmental thermal ablation: first clinical experience. *J Vasc Surg*. 2008;47(1):151-156.
8. Wang YM, Cheng LF, Li N. Histopathological study of vascular changes after intra-arterial and intravenous injection of Nbutyl-2-cyanoacrylate. *Chin J Dig Dis*. 2006;7(3):175-179.
9. Forlee MV, Grouden M, Moore DJ, Shanick G. Stroke after varicose vein foam injection sclerotherapy. *J Vasc Surg*. 2006;43(1): 162-164.
10. Gupta K, Vasishta RK, Dutta U, Kochhar RK, Singh K. Embolization of cyanoacrylate glue in systemic circulation in a case of hepatocellular carcinoma: an autopsy report. *Diag Path*. 2009;4:45.
11. Kailasnath P, Chaloupka JC. Quantitative assessment of polymerization-binding mechanics of cyanoacrylates: model development and validation. *Am J Neuroradiol*. 2002;23(5): 772-778.
12. Gounis MJ, Leiber BB, Wakhloo AK, Siekmann R, Hopkins LN. Effect of glacial acetic acid and ethiodized oil concentration on embolization with N-butyl 2-cyanoacrylate: an in vivo investigation. *Am J Neuroradiol*. 2002;23(6):938-944.
13. Freeny PC, Mennemeyer R, Kidd R, Bush WH. Long-term radiographic-pathologic follow-up of patients treated with visceral transcatheter occlusion using isobutyl 2-cyanoacrylate (bucrylate). *Radiology*. 1979;132(1):51-60.
14. Sichlau MJ, Ryu RK. Cutaneous thermal injury after endovenous laser ablation of the great saphenous vein. *J Vasc Interv Radiol*. 2004;15(8):865-867.
15. Kabnick L. Outcome of different endovenous laser wavelengths for great saphenous vein ablation. *J Vasc Surg*. 2006;43(1):88-93.
16. Min RJ, Khilnani N, Zimmet SE. Endovenous laser treatment of saphenous vein reflux: long-term results. *J Vasc Interv Radiol*. 2003;14(8):991-996.
17. Lurie F, Creton D, Eklof B, et al. Prospective randomized study of endovenous radiofrequency obliteration (Closure procedure) versus ligation and stripping in a selected patient population (EVOLVeS Study). *J Vasc Surg*. 2003;38(2):207-214.

Downloaded from ves.sagepub.com at Ebsco Electronic Journals Service (EJS) on December 2, 2011