Original Article

Response of Borderline Resectable Pancreatic Cancer to Neoadjuvant Therapy Is Not Reflected by Radiographic Indicators

Matthew H. G. Katz, MD[1]; Jason B. Fleming, MD[1]; Priya Bhosale, MD[2]; Gauri Varadhachary, MD[3]; Jeffrey E. Lee, MD[1]; Robert Wolff, MD[3]; Huamin Wang, MD[4]; James Abbruzzese, MD[3]; Peter W. T. Pisters, MD[1]; Jean-Nicolas Vauthey, MD[1]; Chusilp Charnsangavej, MD[2]; Eric Tamm, MD[2]; Christopher H. Crane, MD[5]; and Aparna Balachandran, MD[2]

BACKGROUND: Experience with preoperative therapy for other cancers has led to an assumption that borderline resectable pancreatic cancers can be converted to resectable cancers with preoperative therapy. In this study, the authors sought to determine the rate at which neoadjuvant therapy is associated with a reduction in the size or stage of borderline resectable tumors. **METHODS:** Patients who had borderline resectable pancreatic cancer and received neoadjuvant therapy before potentially undergoing surgery at the authors' institution between 2005 and 2010 were identified. The patients' pretreatment and post-treatment pancreatic protocol computed tomography images were rereviewed to determine changes in tumor size or stage using modified Response Evaluation Criteria in Solid Tumors (RECIST) (version 1.1) and standardized anatomic criteria. **RESULTS:** The authors identified 129 patients who met inclusion criteria. Of the 122 patients who had their disease restaged after receiving preoperative therapy, 84 patients (69%) had stable disease, 15 patients (12%) had a partial response to therapy, and 23 patients (19%) had progressive disease. Although only 1 patient (0.8%) had their disease downstaged to resectable status after receiving neoadjuvant therapy, 85 patients (66%) underwent pancreatectomy. The median overall survival duration for all 129 patients was 22 months (95% confidence interval, 14-30 months). The median overall survival duration for the patients who underwent pancreatectomy was 33 months (95% confidence interval, 25-41 months) and was not associated with RECIST response ($P = .78$). **CONCLUSIONS:** Radiographic downstaging was rare after neoadjuvant therapy, and RECIST response was not an effective treatment endpoint for patients with borderline resectable pancreatic cancer. The authors concluded that these patients should undergo pancreatectomy after initial therapy in the absence of metastases. ***Cancer* 2012;118:5749-56.** © *2012 American Cancer Society.*

KEYWORDS: pancreatic cancer, borderline resectable, pancreaticoduodenectomy, neoadjuvant therapy.

INTRODUCTION

The ability of preoperative therapy to reduce the size and anatomic extent of locally advanced breast and rectal cancers with the objective of improving resectability has been well described.[1,2] Similar treatment strategies have been used in an attempt to *downstage* locally advanced pancreatic cancers, which cannot be resected de novo because of their proximity to the superior mesenteric artery (SMA), celiac axis, and/or aorta.[3] In practice, however, significant downstaging of locally advanced pancreatic ductal adenocarcinoma (PDAC) using chemotherapy and/or chemoradiation is uncommon.[4]

Primary pancreatic cancers with radiographic characteristics suggesting limited involvement of the superior mesenteric vein (SMV), portal vein (PV), SMA, or celiac axis in the absence of metastatic disease have recently been defined as *borderline resectable*.[5,6] High rates of successful pancreatectomy and favorable survival in patients with borderline resectable PDACs have led to the assumption that such tumors often can be reduced in size and converted to anatomically resectable tumors with preoperative therapy.[7-9] However, in part because stage definitions, staging algorithms, clinical decision-making processes, and technical procedures differ among pancreatic cancer treatment centers, the extent to which this assumption is justified is unclear.[10] Such ambiguity may cause both patients and physicians to have unrealistic expectations about the results of preoperative therapy for borderline resectable PDAC.

The primary objective of the current study was to determine the rates at which neoadjuvant therapy is associated with a reduction in the size and anatomic extent of borderline resectable PDACs. To meet this aim, we used well defined,

Corresponding author: Matthew H. G. Katz, MD, Department of Surgical Oncology, Unit 1484, The University of Texas MD Anderson Cancer Center, 1400 Pressler Street, Houston, TX 77030; Fax: (713) 745-5235; mhgkatz@mdanderson.org

[1]Department of Surgical Oncology, The University of Texas MD Anderson Cancer Center, Houston, Texas; [2]Department of Diagnostic Radiology, The University of Texas MD Anderson Cancer Center, Houston, Texas; [3]Department of Gastrointestinal Medical Oncology, The University of Texas MD Anderson Cancer Center, Houston, Texas; [4]Department of Pathology, The University of Texas MD Anderson Cancer Center, Houston, Texas; [5]Department of Radiation Oncology, The University of Texas MD Anderson Cancer Center, Houston, Texas

DOI: 10.1002/cncr.27636, **Received:** March 6, 2012; **Revised:** April 6, 2012; **Accepted:** April 9, 2012, **Published online** May 17, 2012 in Wiley Online Library (wileyonlinelibrary.com)

anatomic disease stage classifications and Response Evaluation Criteria in Solid Tumors (RECIST) and re-evaluated the imaging studies of all patients with borderline resectable cancers who received treatment at our center over a 6-year period.

MATERIALS AND METHODS

The University of Texas MD Anderson Cancer Center (MD Anderson) Institutional Review Board approved this retrospective study. We used a prospectively maintained institutional pancreatic tumor database to identify all patients who were evaluated for localized, biopsy-proven PDAC at MD Anderson between 2005 and 2010 and reviewed their clinical data.[11] We excluded patients who received chemotherapy or chemoradiation before referral and patients whose final diagnosis was invasive adenocarcinoma arising in an intraductal, papillary, mucinous neoplasm or mucinous cystadenocarcinoma.

Radiographic Staging and Rereview

Anatomic disease staging before and after chemotherapy and/or chemoradiation was accomplished with multidetector computed tomography (CT) using a 16-detector or 64-detector row scanner (General Electric Medical Systems, Milwaukee, Wis) and a standard protocol optimized for imaging pancreatic tumors. Oral contrast material was administered orally 90 to 120 minutes before imaging, and 120 to 150 mL of iodinated contrast was administered intravenously immediately before imaging at the rate of 4 to 5 mL per second. The pancreatic parenchymal and portal venous phases were obtained 35 to 40 seconds and 50 to 70 seconds, respectively, after the start of the contrast injection. Images were reconstructed at either 0.625-mm or 1.25-mm slice thickness for analysis. Multiplanar reconstructions were used as necessary to identify vascular anatomy.

For the current study, we sought to evaluate radiographic changes in patients with borderline resectable disease using as broad a definition for this disease stage as possible. Therefore, we identified patients with primary tumors that either abutted (≤180 degrees of the circumference) or encased (>180 degrees of the circumference) the SMV, PV, or common hepatic artery and—at most—abutted the SMA or celiac artery before treatment. Such tumors met the anatomic definition of borderline resectable disease proposed by the Americas Hepatopancreatobiliary Association (AHPBA), Society of Surgical Oncology (SSO), and Society for Surgery of the Alimentary Tract (SSAT) and endorsed by the National Comprehensive Cancer Network (NCCN)[12,13] and/or the

Table 1. Americas Hepatopancreaticobiliary Association/Society of Surgical Oncology/Society for Surgery of the Alimentary Tract and The University of Texas M. D. Anderson Cancer Center Classifications of Localized Pancreatic Cancer

	AHPBA/SSO/SSAT Classification: Callery 2009[12]			MD Anderson Classification: Varadhachary 2006,[5] Katz 2008[8]		
Localization	Potentially Resectable	Borderline Resectable	Locally Advanced	Potentially Resectable	Borderline Resectable	Locally Advanced
SMV/PV	No abutment[a] or encasement[b]	Abutment, encasement or occlusion	Not reconstructible	Abutment or encasement without occlusion	Short-segment occlusion	Not reconstructible
SMA	No abutment or encasement	Abutment	Encasement	No abutment or encasement	Abutment	Encasement
CHA	No abutment or encasement	Abutment or short-segment encasement	Long-segment encasement	No abutment or encasement	Abutment or short-segment encasement	Long-segment encasement
Celiac Trunk	No abutment or encasement	No abutment or encasement	Abutment	No abutment or encasement	Abutment	Encasement

Abbreviations: AHPBA/SSO/SSAT, Hepatopancreaticobiliary Association/Society of Surgical Oncology/Society for Surgery of the Alimentary Tract; CHA, common hepatic artery; MD Anderson, The University of Texas M. D. Anderson Cancer Center; PV, portal vein; SMA, superior mesenteric artery; SMV, superior mesenteric vein.

[a] Less than 180 degrees of vascular circumference.

[b] At least 180 degrees of vascular circumference.

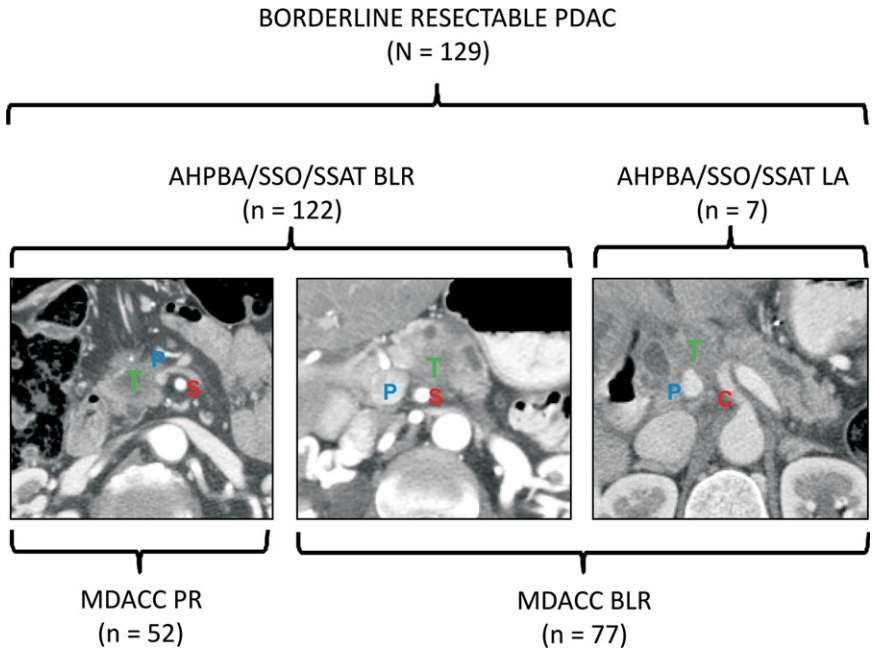

Figure 1. All patients had borderline resectable (BLR) pancreatic ductal adenocarcinoma (PDAC) based on at least 1 of 2 sets of anatomic criteria. Patients who had tumors that abutted or encased the superior mesenteric vein (SMV) or the portal vein (PV) without evidence of arterial involvement or occlusion of the SMV-PV had BLR disease according to Americas Hepatopancreatobiliary Association (AHPBA), Society of Surgical Oncology (SSO), and Society for Surgery of the Alimentary Tract (SSAT) (AHPBA/SSO/SSAT) criteria but had potentially resectable (PR) disease according to The University of Texas M. D. Anderson Cancer Center (MDACC) criteria. Patients with celiac artery abutment had locally advanced (LA) disease according to AHPBA/SSO/SSAT criteria but had BLR disease according to MDACC criteria. Red S indicates the superior mesenteric artery; green T, tumor; blue P, portal vein; red C, celiac artery.

anatomic definition of borderline resectable disease proposed by MD Anderson (Table 1).[5,8] We included patients with venous occlusion but excluded those in whom a sufficient cuff of patent vein suitable for reconstruction both above and below the primary tumor was absent. We identified all patients who had received chemotherapy and/or chemoradiation with curative intent before potential surgery.

Patients who were staged or restaged using a CT scanning protocol other than that described above were excluded from analysis. The CT images of the remaining patients were rereviewed for this study by a faculty-level gastrointestinal radiologist (A.B.) who was blinded to patient treatment and outcome. The radiologist measured the interface between the tumor and each mesenteric vascular structure and characterized this interface as either abutment or encasement. To characterize the changes in tumor size and disease stage associated with preoperative therapy, the radiologist compared the greatest dimension of the primary tumor and each tumor-vessel interface depicted in pretreatment images with those in post-treatment images. Changes were described using the anatomic staging definitions described above and modified RECIST (version 1.1).[14] Progressive disease (PD) was defined as either the development of metastases or an increase $\geq$20% in the greatest dimension (with a minimum increase of at least 5mm) of the primary tumor. A partial response (PR) was defined as a decrease $\geq$30% in the greatest dimension of the primary tumor. Stable disease (SD) was defined as neither sufficient shrinkage to qualify for PR nor sufficient growth to qualify for PD. A complete response (CR) was defined as complete disappearance of the primary tumor.

Neoadjuvant Regimens

Two primary neoadjuvant treatment strategies were used: 1) gemcitabine-based, systemic chemotherapy followed by planned chemoradiation (external-beam radiation with 30 grays [Gy] in 10 fractions or 50.4 Gy in 28 fractions with concurrent gemcitabine, fluorouracil or capecitabine) or 2) chemoradiation alone.

Surgical and Histopathologic Techniques

Standardized indications for pancreatectomy after the completion of neoadjuvant therapy included a Karnofsky performance status $\geq$70, adequately evaluated and optimized comorbidities, and no radiographic or intraoperative evidence of tumor progression to locally advanced or metastatic disease as defined using our anatomic criteria

(Table 1). Patients underwent pancreatectomy with standardized techniques,[15] and surgical margins were designated in accordance with the criteria of the seventh edition of the American Joint Committee on Cancer Staging Manual.[3] The closest distance to the nearest millimeter between cancer cells and the SMA margin was measured microscopically and prospectively recorded.[15] The grade of neoadjuvant chemoradiation treatment effect was assessed on permanent sections.[16]

Surveillance

After surgery, patients underwent physical examination, chest radiograph, and an abdominal CT scan every 4 months. For patients who had no evidence of disease after 2 years and 5 years of follow-up, the intervals between these evaluations were increased to 6 months and 12 months, respectively.[17]

Statistical Analysis

We defined overall survival (OS) as the interval between the date of histopathologic diagnosis of PDAC and the date of death from any cause, and progression-free survival (PFS) was defined as the interval between the date of histopathologic diagnosis of PDAC and the date of either first recurrence or death from disease, whichever occurred first. Patient data were censored at last follow-up. We used the Kaplan-Meier method to estimate OS and PFS probabilities and the log-rank test to assess differences among subgroups. All statistical tests were 2-tailed, and P values $< .05$ were considered statistically significant. We used SPSS statistical software (version 17; SPSS, Inc., Chicago, Ill) for all statistical analyses.

RESULTS

Patients and Initial Staging

One hundred forty patients had borderline resectable PDAC and received chemotherapy and/or chemoradiation before potential pancreatectomy. A pancreatic protocol CT scan was not performed at the initial or restaging visit in 6 and 5 of these patients, respectively. The remaining 129 patients met all inclusion criteria of the current study.

Radiologic rereview confirmed that all 129 patients had initial tumor anatomy consistent with borderline resectable PDAC. Of the 122 patients whose PDAC met AHPBA/SSO/SSAT criteria for borderline resectable disease, 52 (43%) had cancers that neither approximated an artery nor occluded the SMV or PV and, thus, were characterized as potentially resectable according to MD Anderson criteria. Of the 77 patients whose PDAC met MD Anderson criteria for borderline resectable disease, 7 (9%) had cancers that abutted the celiac artery and, thus, were considered locally advanced according to AHPBA/SSO/SSAT criteria (Fig. 1). The demographic and pretreatment characteristics of and initial treatment strategy used for the 129 patients are reported in Table 2.

Table 2. Demographic and Initial Treatment Characteristics of 129 Patients With Borderline Resectable Pancreatic Ductal Adenocarcinoma

Characteristic	No. of Patients (%)
No. of patients	129 (100)
Age: Median [range], y	65 [34-81]
Radiographic greatest tumor dimension: Median [range], mm	3.4 [1.8-5.8]
Evaluable pretreatment serum CA 19-9 level[a]	84 (65)
Evaluable pretreatment serum CA 19-9 level: Median [range], U/mL	218 [11-4546]
Treatment[b]	
Chemotherapy	98 (76)
Gemcitabine-platinum	84 (86)
Gemcitabine with or without other	14 (14)
Chemoradiation	113 (88)
Chemosensitizer	
Gemcitabine	51 (45)
5-FU	62 (55)
EBRT dose	
30 Gy	17 (15)
Standard[c]	96 (85)

Abbreviations: EBRT, external beam radiation therapy;. 5-FU, 5-fluorouracil; Gy, grays.
[a] CA 19-9 levels for patients who had all levels <1 U/mL or that were measured in association with a total bilirubin level >1.5 mg/dL were excluded.
[b] The number of patients who received each treatment is indicated. All patients who received chemotherapy were planned to receive subsequent chemoradiation. Of the patients who received chemoradiation, 31 received it as the only planned preoperative treatment. The overall survival duration ($P = .83$) and the rate of metastases ($P = .61$) did not differ between groups that received treatment with these 2 strategies (chemotherapy with planned chemoradiation vs chemoradiation alone).
[c] The standard EBRT dose typically was 50.4 Gy.

Clinical Course

One hundred twenty-two patients (95%) were restaged after undergoing preoperative therapy. Of these, the clinical assessment indicated that 98 patients (80%) had no radiologic evidence of disease progression. The CT images of the remaining 24 patients (20%) were assessed as representative of metastatic (n = 21) or locally advanced disease (n = 3).

Ninety-two of the 98 patients without disease progression were brought to the operating room for intended pancreatectomy; 5 patients had a performance status insufficient for surgery, and 1 patient chose not to undergo resection. Intraoperatively, intended resection was aborted because of the identification of metastases

Table 3. Clinicopathologic Profile of 85 Patients Who Underwent Resection of Borderline Resectable Pancreatic Ductal Adenocarcinoma

Characteristic	No. of Patients (%)
No. of patients	85 (100)
Neoadjuvant therapy	
Chemotherapy	65 (76)
Gemcitabine-platinum	56 (86)
Gemcitabine with or without other	9 (14)
Chemoradiation	81 (95)
Chemosensitizer	
Gemcitabine	40 (49)
5-FU	41 (51)
EBRT dose	
30 Gy	13 (16)
Standard[a]	68 (84)
Procedure	
Pancreaticoduodenectomy	76 (90)
Distal pancreatectomy	8 (9)
Total pancreatectomy	1 (1)
Vascular resection	51 (60)
Venous	44 (86)
Arterial	1 (2)
Both	6 (12)
Greatest tumor dimension: Median [range], mm	2.5 [0-6.0]
Treatment effect score	
I	2 (2)
IIA	32 (39)
IIB	35 (42)
III	12 (15)
IV	2 (2)
Not assessed	2
Resection status	
R0	81 (95)
R1	4 (5)
SMA length if R0, mm	
≤1	18 (26)
>1-10	44 (63)
>10	8 (11)
Not assessed	6
No. of lymph nodes assessed: Median [range]	22 [3-55]
Lymph node status	
N0	41 (48)
N1	44 (52)

Abbreviations: 5-FU, 5-fluorouracil; EBRT, external beam radiation therapy; Gy, grays; SMA, superior mesenteric artery.
[a] Percentages refer to the number assessed.
[b] The standard EBRT dose typically was 50.4 Gy.

(n = 4) or local tumor anatomy that reportedly precluded safe resection (n = 3). The remaining 85 patients (66% of the 129 patients included in the current study) underwent pancreatectomy; their clinicopathologic profile is included in Table 3. Eighty-one of those resections (95%) achieved negative resection margins (R0). There was no perioperative mortality.

Response Evaluation Criteria in Solid Tumors Response and Change in Tumor Stage by Radiographic Rereview

Upon rereview, 84 patients (69%) had SD according to RECIST: 15 patients (12%) had a PR, and 23 patients (19%) had PD because of an increase in the greatest dimension of the primary tumor (n = 2) or the development of metastases (n = 21). No patient had a CR.

According to AHPBA/SSO/SSAT criteria, PDAC was downstaged in 1 patient (1%) and upstaged in 23 patients (19%) after treatment, and the tumor stage in 98 patients (80%) remained the same (Table 4). According to MD Anderson criteria, PDAC was downstaged in 1 patient (1%) and upstaged in 26 patients (21%) after treatment, and the tumor stage in 95 patients (78%) remained the same.

The interpretation of CT images differed significantly in only 3 patients between the clinical assessment and the radiographic rereview. These were the 3 patients who were assessed by the operating surgeon with locally advanced disease after preoperative therapy according to MD Anderson criteria; none of their tumors changed in stage according to the radiographic rereview, and all had SD according to RECIST.

All 15 patients who had a PR underwent resection, as did 70 of the 84 patients (83%) who had SD. No patient with PD underwent resection. One patient (100%) whose disease was downstaged, 2 patients (100%) whose disease was upstaged in the absence of metastases, and 82 of the 98 patients (84%) in whom disease stage did not change according to AHPBA/SSO/SSAT criteria underwent resection. One patient (100%) patient whose disease was downstaged, 3 of 5 patients (60%) whose disease was upstaged in the absence of metastases, and 81 of 95 patients (85%) in whom disease stage did not change according to MD Anderson criteria underwent resection.

Survival

At the time of last follow-up, 82 of the 129 patients (64%) who were included in the current study had died. Their median overall survival duration was 22.0 months (95% confidence interval, 13.8-30.2 months). Of the patients who underwent resection, 57 (67%) had recurrent disease and/or died of disease recurrence. The median PFS and OS for the patients who underwent resection were 17.6 months (95% confidence interval, 12.0-23.2 months) and 33.0 months (95% confidence interval, 25.4-40.6 months), respectively. RECIST response was not associated with a longer median OS duration (P = .78). The median OS duration of patients who did not

Table 4. Disease Stage Before and After the Administration of Neoadjuvant Therapy

			No. of Patients (%)						
			Post-Treatment Stage[a]						
				PR		BL		LA	
Pretreatment Stage	No. of Patients	Metastatic Disease	Total	No. Resected	Total	No. Resected	Total	No. Resected	Total No. Resected
AHPBA/SSO/SSAT classification									
BL	115	20 (17)	1 (1)	1 (100)	92 (80)	77 (84)	2 (2)	2 (100)	80
LA	7	1 (14)	0 (0)	0 (0)	0 (0)	0 (0)	6 (86)	5 (83)	5
MD Anderson classification									
PR	50	8 (16)	37 (74)	36 (97)	5 (10)	3 (60)	0 (0)	0 (0)	39
BL	72	13 (18)	1 (1)	1 (100)	58 (81)	45 (78)	0 (0)	0 (0)	46

Abbreviations: AHPBA/SSO/SSAT, Hepatopancreaticobiliary Association/Society of Surgical Oncology/Society for Surgery of the Alimentary Tract; BL, borderline resectable; LA, locally advanced; MD Anderson, The University of Texas M. D. Anderson Cancer Center; PR, potentially resectable.
[a] According to corresponding staging classification from AHPBA/SSO/SSAT or MD Anderson.

undergo resection was 12.0 months (95% confidence interval, 9.5-14.5 months).

DISCUSSION

In this study, we rereviewed the pancreatic protocol CT scans of all patients with borderline resectable PDAC who were treated at our institution with curative intent over a 6-year period to determine the rate of radiographic downstaging after preoperative therapy and to describe any association between radiographic response and OS. We observed that only 1 of the 129 patients (<1%) included in the study had radiographic evidence of a reduction in vascular involvement sufficient to improve their anatomic stage and that only 15 of the 122 patients (12%) whose PDACs were restaged after preoperative therapy had disease that met established RECIST for treatment response. Nevertheless, margin-negative (R0) pancreatectomy was achieved in 81 of the 101 patients (80%) in whom metastatic disease was not observed after treatment, and the median OS duration of the patients who underwent resection and had no radiographic evidence of disease response to therapy was similar to that of the patients who did respond.

Several groups have reported that radiographic downstaging of unresectable PDAC may occur after preoperative therapy and have suggested that such therapy may be used to improve resectability—just as it may for patients with advanced breast and rectal cancers. However, those studies were limited, because they lacked standardized metrics of therapeutic response, resection criteria, surgical techniques, and staging definitions and algorithms.[10] Two small, single-institution series recently demonstrated that OS after preoperative therapy and pancreatectomy in highly selected patients initially believed to have unresectable disease was similar to that of patients with resectable disease, but neither study reported the total number of patients treated or used standardized definitions or methods of staging.[18,19] A systematic analysis of 13 studies in which patients with unresectable PDAC were uniformly evaluated for resection after preoperative therapy reported that resection rates varied from 8% to 64%, suggesting that disease staging and/or surgery indications were inconsistent.[20] A meta-analysis of retrospective and prospective studies of neoadjuvant therapy in patients with localized PDAC reported that 35% of patients with unresectable disease had PRs or CRs to preoperative therapy and that 33% of patients underwent resection.[21] Fifty-three percent of the studies that were included in the meta-analysis did not state the criteria used to stage disease, and only 40% of the studies reported the criteria used to measure treatment response. In addition, the studies' preoperative regimens were inconsistent, and the studies did not evaluate the precise indications for surgery after therapy. Nevertheless, the authors of the meta-analysis concluded that approximately 33% of unresectable cancers were downstaged to resectable after neoadjuvant therapy.

On the basis of strict anatomic definitions of disease stage, however, we report here that radiographic downstaging is rare after chemotherapy and/or chemoradiation, even among patients with borderline resectable PDAC—a highly selected population of patients with limited vascular involvement in whom such an event might be expected. Indeed, after preoperative therapy, a borderline resectable cancer was converted to a resectable cancer with no radiographic evidence of vascular involvement in only 1 of 129 evaluated patients. Nonetheless, 84% of the patients who did not have metastatic disease after therapy underwent resection. Resection and reconstruction of the SMV, PV, and/or hepatic artery was required in 60% of

the operations performed—a rate that reflects not only the complex tumor anatomy and vascular relationships that remain after neoadjuvant therapy but also our aggressive use of both venous and hepatic arterial resection in patients in whom we suspect relatively indolent cancer biology exists after selection with chemotherapy, chemoradiation, and time.[22] Both the infrequency with which radiographic downstaging is observed after neoadjuvant therapy and the frequency with which complex vascular reconstructions need be performed to achieve the margin-negative resection rate reported here must be recognized by oncologists who plan to treat patients with borderline resectable PDAC successfully.

Although changes in the critical anatomic relationships of patients' primary tumors after therapy were rare, it would be a mistake to conclude that the neoadjuvant therapy regimens administered were ineffective or unnecessary. Indeed, our histopathologic review of the pancreatectomy specimens revealed a histopathologic grade III or IV response—a metric we previously associated with a favorable prognosis—in 17% of patients who underwent resection.[23] Furthermore, although CT images revealed that a close relationship between the tumor and mesenteric vasculature (often the SMA) remained after neoadjuvant therapy in all patients, only 1 patient's pancreatectomy specimen had a positive SMA margin, and the distance between the primary tumor and the inked SMA margin was >1 mm in 74% of patients whose pancreatectomy specimen had a negative SMA margin. These findings suggest that clinically significant cytotoxic activity may occur at the peripheral tumor-vessel interface despite the absence of radiographic findings indicating changes in the tumor.

RECIST are well accepted criteria for treatment response in many clinical settings. In this study, however, we observed no association between RECIST response and OS duration. Given this finding and the infrequency with which radiographic downstaging occurs, we conclude that: 1) aggressive surgery should not be withheld from patients with borderline resectable PDAC whose CT studies do not reveal a reduction in the size of the primary tumor after chemotherapy and/or chemoradiation, and 2) such changes should not be viewed as an endpoint of therapy (ie, that treatment should not be administered until such changes are observed or maximized). We typically treat borderline resectable cancers with systemic chemotherapy for 2 months to 4 months followed by chemoradiation and deviate from this course only in the event of radiographic evidence of disease progression or a decline in the patient's performance status.

The current study had several potential limitations. The treatment regimens these patients received were similar but not identical. Moreover, although the patients in the current study had received modern, gemcitabine-based regimens, no patient had received combined oxaliplatin, irinotecan, fluorouracil, and leucovorin (FOLFIRINOX),[24] which has been associated with a higher therapy response rate than gemcitabine in patients with advanced disease; however, the activity of FOLFIRINOX in the preoperative setting is unknown. Furthermore, given the toxicity profile associated with this regimen, gemcitabine-based treatments likely will remain routine for the foreseeable future. The current study also was clearly subject to institutional bias, and the extent to which the therapeutic strategies reported here can be exported to treatment centers at which the physicians have less experience treating PDAC patients with preoperative therapy and vascular resection is unclear.

The current study also had several fundamental strengths. The study was conducted using an intent-to-treat analysis, and we evaluated all patients who were treated with curative intent for borderline resectable PDAC, whether or not they underwent resection. All patients had disease that met objective anatomic staging definitions, and all patients received neoadjuvant chemotherapy and/or chemoradiation before disease restaging and potential surgery. Furthermore, all patients were evaluated using an identical, high-quality vascular imaging protocol. We used standardized indications for surgery after treatment, standard operative techniques, and uniform methods of histopathologic analysis of the surgical specimen. Finally, all imaging studies were rereviewed for this analysis by a single, faculty-level gastrointestinal radiologist.

In summary, although radiographic downstaging of disease in patients with borderline resectable PDAC after neoadjuvant therapy is rare, margin-negative pancreatectomy with favorable long-term results can be achieved in these patients with aggressive multimodality therapy. Furthermore, current radiographic measures of treatment response in patients with borderline resectable PDAC appear to be of little clinical value. Therefore, we recommend the aggressive use of surgery in patients who have borderline resectable PDAC with a suitable performance status, completely optimized comorbidities, and an absence of metastatic disease after neoadjuvant therapy.

FUNDING SOURCES

This work was supported by the Khalifa Bin Zayed Al Nahyan Foundation and by the Various Donor Pancreatic Research

Fund at The University of Texas MD Anderson Cancer Center.

CONFLICT OF INTEREST DISCLOSURES

The authors made no disclosures.

REFERENCES

1. Sadetzki S, Oberman B, Zipple D, et al. Breast conservation after neoadjuvant chemotherapy. *Ann Surg Oncol*. 2005;12:480-487.
2. Gerard JP, Rostom Y, Gal J, et al. Can we increase the chance of sphincter saving surgery in rectal cancer with neoadjuvant treatments: lessons from a systematic review of recent randomized trials. *Rev Oncol Hematol*. 2012;81:21-28.
3. American Joint Committee on Cancer (AJCC). Exocrine and endocrine pancreas. In: Edge SB, Byrd DR, Compton CC, Fritz AG, Greene FL, Trotti A, eds. AJCC Cancer Staging Manual. 7th ed. New York: Springer; 2010:241-249.
4. Kim HJ, Czischke K, Brennan MF, Conlon KC. Does neoadjuvant chemoradiation downstage locally advanced pancreatic cancer? *J Gastrointest Surg*. 2002;6:763-769.
5. Varadhachary GR, Tamm EP, Abbruzzese JL, et al. Borderline resectable pancreatic cancer: definitions, management, and role of preoperative therapy. *Ann Surg Oncol*. 2006;13:1035-1046.
6. Abrams RA, Lowy AM, O'Reilly EM, Wolff RA, Picozzi VJ, Pisters PW. Combined modality treatment of resectable and borderline resectable pancreas cancer: expert consensus statement. *Ann Surg Oncol*. 2009;16:1751-1756.
7. Stokes JB, Nolan NJ, Stelow EB, et al. Preoperative capecitabine and concurrent radiation for borderline resectable pancreatic cancer. *Ann Surg Oncol*. 2011;18:619-627.
8. Katz MH, Pisters PW, Evans DB, et al. Borderline resectable pancreatic cancer: the importance of this emerging stage of disease. *J Am Coll Surg*. 2008;206:833-846.
9. Chun YS, Milestone BN, Watson JC, et al. Defining venous involvement in borderline resectable pancreatic cancer. *Ann Surg Oncol*. 2010;17:2822-2838.
10. Katz MH, Pisters PW, Lee JE, Fleming JB. Borderline resectable pancreatic cancer: what have we learned and where do we go from here? *Ann Surg Oncol*. 2011;18:608-610.
11. Hwang RG, Wang H, Lara A, et al. Development of an integrated biospecimen bank and multidisciplinary clinical database for pancreatic cancer. *Ann Surg Oncol*. 2008;15:1356-1366.
12. Callery MP, Chang KJ, Fishman EK, Talamonti MS, William Traverso L, Linehan DC. Pretreatment assessment of resectable and borderline resectable pancreatic cancer: expert consensus statement. *Ann Surg Oncol*. 2009;16:1727-1733.
13. National Comprehensive Cancer Network (NCCN). NCCN Clinical Practice Guidelines in Oncology. Pancreatic Adenocarcinoma. Available at: http://www.nccn.org/professionals/physician_gls/pdf/pancreatic.pdf. Accessed February 10, 2012.
14. Eisenhauer EA, Therasse P, Bogaerts J, et al. New Response Evaluation Criteria in Solid Tumours: revised RECIST guideline (version 1.1). *Eur J Cancer*. 2009;45:228-247.
15. Katz MH, Wang H, Balachandran A, et al. Effect of neoadjuvant chemoradiation and surgical technique on recurrence of localized pancreatic cancer. *J Gastrointest Surg*. 2011;16:68-79.
16. Evans DB, Rich TA, Byrd DR, et al. Preoperative chemoradiation and pancreaticoduodenectomy for adenocarcinoma of the pancreas. *Arch Surg*. 1992;127:1335-1339.
17. Tzeng CW, Fleming JB, Lee JE, et al. Yield of clinical and radiographic surveillance in patients with resected pancreatic adenocarcinoma following multimodal therapy. *HPB*. In press.
18. Donahue TR, Isacoff WH, Hines OJ, et al. Downstaging chemotherapy and alteration in the classic computed tomography/magnetic resonance imaging signs of vascular involvement in patients with pancreaticobiliary malignant tumors: influence on patient selection for surgery. *Arch Surg*. 2011;146:836-843.
19. Bickenbach KA, Gonen M, Tang LH, et al. Downstaging in pancreatic cancer: a matched analysis of patients resected following systemic treatment of initially locally unresectable disease [published online ahead of print December 1, 2011]. *Ann Surg Oncol*. 2011.
20. Morganti AG, Massaccesi M, La Torre G, et al. A systematic review of resectability and survival after concurrent chemoradiation in primarily unresectable pancreatic cancer. *Ann Surg Oncol*. 2010;17:194-205.
21. Gillen S, Schuster T, Meyer Zum Buschenfelde C, Friess H, Kleeff J. Preoperative/neoadjuvant therapy in pancreatic cancer: a systematic review and meta-analysis of response and resection percentages [serial online]. *PLoS Med*. 2010;7:e1000267.
22. Tzeng CW, Fleming JB, Lee JE, et al. Defined clinical classifications are associated with outcome of patients with anatomically resectable pancreatic adenocarcinoma treated with neoadjuvant therapy [published online ahead of print January 19, 2012]. *Ann Surg Oncol*. 2012.
23. Chatterjee D, Katz MH, Rashid A, et al. Histologic grading the extent of residual carcinoma following neoadjuvant chemoradiation in pancreatic ductal adenocarcinoma: a predictor for patient outcome [published online ahead of print October 25, 2011]. *Cancer*. 2011.
24. Conroy T, Desseigne F, Ychou M, et al. FOLFIRINOX versus gemcitabine for metastatic pancreatic cancer. *N Engl J Med*. 2011;364:1817-1825.