Journal of Surgical Research **149,** 214–218 (2008)
doi:10.1016/j.jss.2008.01.010

Tissue-Engineered Spleen Protects Against Overwhelming Pneumococcal Sepsis in a Rodent Model

Tracy C. Grikscheit, M.D.,*,[1] Frédéric G. Sala, Ph.D.,* Jennifer Ogilvie, M.D.,† Kate A. Bower, M.D.,‡ Erin R. Ochoa, M.D.,§ Eben Alsberg, Ph.D.,¶ David Mooney, Ph.D.,‖ and Joseph P. Vacanti, M.D.€

*Department of Surgery and Saban Research Institute, Children's Hospital Los Angeles, Los Angeles, California; †Department of Surgery, University of Pittsburgh Medical Center, Pittsburgh, Pennsylvania; ‡Department of Pediatrics, C. S. Mott's Children's Hospital, Ann Arbor, Michigan; §Department of Pathology, University of Pittsburgh Medical Center, Pittsburgh, Pennsylvania; ¶Departments of Biomedical Engineering and Orthopaedic Surgery, Case Western Reserve University, Cleveland, Ohio; ‖Department of Engineering and Applied Science, Harvard University, Boston, Massachusetts; €Department of Surgery, MassGeneral Hospital for Children, Boston, Massachusetts

Submitted for publication July 12, 2007

Background/Purpose. **Solid organs production is an ultimate goal of tissue engineering. After refining a technique for intestinal engineering, we applied it to a solid organ, the spleen. Overwhelming postsplenectomy sepsis results in death in nearly half of all cases. This risk is pronounced in children. Necrosis of autotransplanted spleen slices occurs prior to regeneration. We postulate that tissue engineering techniques might be superior.**

Methods. **Four groups of Lewis rats were compared: sham laparotomy, tissue-engineered spleen (TES), traditional spleen slices, and splenectomy. TES was generated from splenic units, multicellular components of juvenile spleen implanted on a biodegradable polymer scaffold, and spleen slices were derived from age-matched juveniles. Pneumococcal sepsis was induced at wk 16, and survival curves were constructed.**

Results. **Tissue-engineered spleen protected against pneumococcal septicemia with a survival proportion of 85.7% compared with 41.17% of splenectomized animals. Spleen slice was also protective with 71.43% survival. Compared with splenectomy, control and TES groups were statistically significant ($P = 0.0002$, $P = 0.0087$; hazard ratio of splenectomy = 5.493) and the Slice group was nearly statistically significant ($P = 0.0642$, hazard ratio of splenectomy = 2.673).**

Conclusions. **TES is a novel application of tissue engineering to splenic regeneration and creates a functional spleen. This approach could be advantageous in severe pediatric trauma.** © 2008 Elsevier Inc. All rights reserved.

Key Words: **tissue engineering; tissue-engineered intestine; tissue-engineered spleen; solid organ tissue engineering; overwhelming postsplenectomy sepsis; pneumococcal sepsis.**

INTRODUCTION

Death results from overwhelming postsplenectomy sepsis in greater than half of all cases [1–5]. This high risk of mortality is pronounced in children, and despite modern vaccines and critical care, lack of splenic function in children is also associated with decreased quality-adjusted life expectancy [6, 7]. Altered opsonic function, decreased serum IgM, decreased response to antigen challenge, and less complement, T lymphocytes, tuftsin, and properdin are observed [4]. The spleen's ability to regenerate has been known as useful since Griffin and Tizzoni's appreciation of this capacity in 1883. They first observed splenosis, as named by Buchbinder and Lipkoff in 1939, in the peritoneum of splenectomized dogs [8, 9].

The histological regeneration of the spleen from fragments implanted either subcutaneously or intraperitoneally has been documented to occur with an initial necrosis of the tissue down to a rudimentary connective tissue structure with hypocellularity and a loss of lymphoid elements [10–12]. This is followed by repopulation of the connective tissue structure, regrowth of blood vessels, and eventual regeneration of red and white pulp by 5 to 7 wk [10–12]. Regeneration of spleen in the peritoneum has been favorable over other sites,

[1] To whom correspondence and reprint requests should be addressed at Department of Surgery and Saban Research Institute, Childrens' Hospital Los Angeles, 4650 Sunset Boulevard Mailstop #100, Los Angeles, CA 90027. E-mail: tgrikscheit@chla.usc.edu.

0022-4804/08 $34.00
© 2008 Elsevier Inc. All rights reserved.

and the omentum has been favored for the possibility of venous portal circulation for hepatic participation in antigen processing [13]. Experimental studies of the protective effect of various techniques (homogenized spleen, thin or thick slices, grated tissue, diverse cubes) of splenic autotransplantation have yielded a protective effect from splenic regeneration [10]. The most common model used to test regenerated splenic function is the omental pouch. This model was first shown to be protective in Sprague Dawley rats challenged by pneumococcal peritonitis [14].

In the case of the spleen slice, successful regeneration occurs on the rudimentary connective tissue scaffold that results from major necrosis [10–12]. We hypothesized that supplying a splenic construct ready to supply a proxy for this scaffold might result in more successful splenic regeneration from a greater number of viable cells and, therefore, could be protective. We proposed to supply the connective tissue framework in the form of a biodegradable polymer and the regenerative cells in the form of splenic units (SU), multicellular splenic aggregates sized to survive on a the polymer by imbibition prior to vascular ingrowth.

We first reported making tissue-engineered small intestine by the transplantation of organoid units on a polymer scaffold into the omentum of the Lewis rat [15]. Organoid units are multicellular units derived from neonatal rat intestine containing a mesenchymal core surrounded by a polarized intestinal epithelium, and contain all of the cells of a full-thickness intestinal section [16]. This protocol has been significantly transformed to yield greater numbers of organoid units more efficiently from an additional area of the gastrointestinal tract, the sigmoid colon. The protocol changes lead to some evidence of increased viability, as production of tissue-engineered colon (TEC) occurs 100% of the time [17]. In addition, there is some initial evidence of *in vivo* physiological replication of major functions by the TEC, which produces short-chain fatty acids and absorbs moisture and sodium compared with animals that lack TEC [17]. In the case of TEC, the model in which much of the protocol refinement was done, the histology was indistinguishable from native colon with an appropriate epithelial layer, actin-positive muscularis propria containing S100 positive cells in the distribution of Meissner and Auerbach's plexi as well as lucent adjacent ganglion cells [18].

Tissue-engineered small intestine generated in this fashion has markedly improved tissue architecture including ganglion cells and a mucosal immune system with an immunocyte population similar to that of native small intestine [19]. When used as a "rescue" following massive small bowel resection, Lewis rats with tissue-engineered small intestine regain weight at a more rapid rate up to their preoperative weights, while animals without the engineered intestine fail to thrive [20]. The "rescued" animals also had normal serum levels of B12 while those in the control group were subnormal. Tissue-engineered esophagus has also been generated and successfully used in a replacement model with this approach [21].

We hypothesized that these techniques could be translated to the production of a functional, solid organ, tissue-engineered spleen (TES) that could be used in replacement in a juvenile model.

Solid organ tissue engineering *in vivo* has been severely limited by the problem of the large metabolic demand of compact cells as the radius expands. Oxygen diffusion only allows a few hundred μm of tissue to be supported before the oxygen is consumed, and this has been a major design constraint for solid organs [22]. Because tissue-engineered intestine is a hollow viscus organ with less tissue density that must be supported while angiogenesis and vasculogenesis occur in parallel, it can be generated with the strategy of scaffold implantation into a vascularized space. The quantity of engineered intestine produced by our improved protocols has become so much larger as a result of faster processing and presumably less cellular insult that we hypothesized that some solid organs could be produced by this method.

Understanding the mechanisms that support this growth of solid organs *in vivo* after tissue processing could help to identify the regenerative pathways that support tissue growth in both these models and *in vivo* after injury or during organogenesis.

MATERIALS AND METHODS

Spleen—Four Surgical Groups

Animals were cared for in compliance with the Institute of Laboratory Animal Resources Guide. Sixty-eight male 150 g Lewis rats were divided into four groups of 17 animals each: Control, Splenectomy, Spleen Slice, and TES. The animals were housed under normal laboratory conditions with free access to food and water.

Specific surgeries were carried out contemporaneously. Control rats underwent sham laparotomy. Splenectomy rats underwent splenectomy through a midline incision. Spleen Slice animals underwent splenectomy and implantation of two 3 mm slices of spleen next to each other in the manner of Patel *et al*., [14] but derived from syngeneic 6-d old rat pups into an omental pouch sutured with one 6-0 Prolene at the point where all flaps of omentum overlay each other like an envelope. TES Animals underwent implantation of the TES construct, a biodegradable polymer loaded with syngeneic SU in the same fashion in the omentum.

Generating TES from SU

SU were produced by dissecting the spleens from 6-d-old Lewis rat pups (n = 20). The resected specimens were washed two times in 4°C Hank's balanced salt solution, sedimenting between washes, and digested with dispase 0.25 mg/mL (Boehringer Ingelheim, Ingelheim, Germany) and collagenase Type 1 (Worthington, Lakewood, NJ) 800 U/mL on an orbital shaker at 37°C for 18 min. The digestion was immediately stopped with three 4°C washes of a solution of high glucose Dulbecco's modified Eagle's medium, 4% heat-inactivated fetal bovine serum, and 4% sorbitol. The SU were centrifuged between

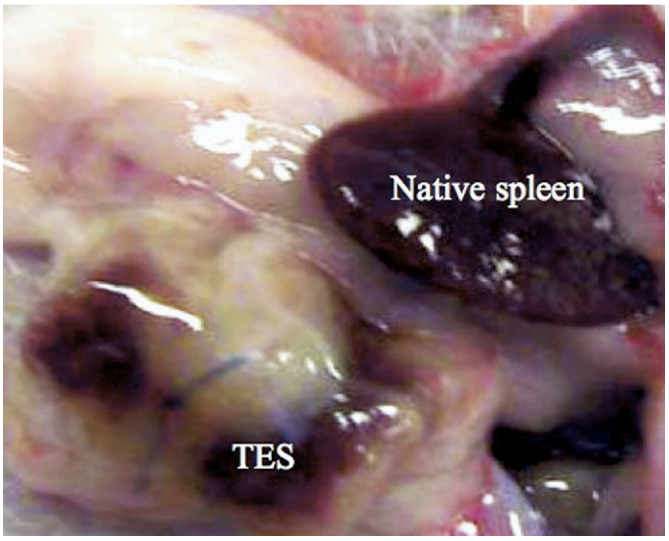

FIG. 1. Gross examination of tissue-engineered spleen (TES) compared with native spleen at 8 wk in a rat that did not undergo splenectomy at construct implantation.

washes at 150 *g* for 5 min, and the supernatant removed. SU were reconstituted in high glucose Dulbecco's modified Eagle's medium with 10% inactivated fetal bovine serum, counted by hemocytometer, and loaded, 100,000 units per polymer at 4°C, and maintained at that temperature until implantation, which occurred in less than 1.5 h.

Polymer Design

Scaffold polymers were constructed of 2 mm thick nonwoven polyglycolic acid (fiber diameter: 15 μm; mesh thickness: 2 mm; bulk density: 60 mg/cm^3; porosity: $>$ 95%) (Smith and Nephew, Heslington, York, United Kingdom), formed into 1 cm tubes (o.d. = 0.5 cm, i.d. = 0.2 cm), and sealed with 5% poly-L-lactic acid (Sigma-Aldrich, St. Louis, MO) in chloroform. Polymer tubes were sterilized in 100% ethanol at room temperature for 20 min, then washed with 500 mL of phosphate-buffered saline (PBS), coated with 1:100 collagen Type1:PBS solution for 20 min at 4°C, and washed again with 500 mL PBS. Polymer tubes were internally loaded with splenic units by micropipette.

Pneumococcal Infection

Sixteen wk after operation, three animals in the spleen slice and three animals in the TES groups had died. All of these deaths occurred within 1 d of the initial surgery. Necropsy did not reveal surgical error or infection, making anesthesia or aspiration likely candidates. The remaining animals were healthy and weighed 425 to 470 g. *Streptococcus pneumoniae* type 25 (ATCC) was maintained on soy trypticase agar plates, and grown up overnight in brain-heart infusion broth. Serial dilution experiments were carried out to determine the absorbance and growing conditions that corresponded to 1×10^7 CFU. This amount was diluted in 2 cc PBS and injected intraperitoneally in each rat at time 0. Animals were observed every 12 h for the next 21 d. Necropsy was performed on all animals that succumbed, and blood smears were obtained as well as tissue to confirm bacterial sepsis. At d 21 all animals were humanely euthanized and their tissues collected. In addition to hematoxylin and eosin (H&E) histology, immunohistochemistry for von Willebrand factor and CD3 was performed as were DNA assays. Survival curves were generated with the equivalent of the Mantel-Haenszel logrank test excluding the postoperative deaths at the beginning of the experiment.

TES Study Groups

To further characterize TES, the construct was implanted in 8 additional rats with (TES+, $n = 8$) or without splenectomy (TES−, $n = 8$). Constructs were harvested at wk 2, 3, and 8, analyzed by H&E, immunohistochemistry, dry weight, and DNA assay. Statistics were performed by Mann-Whitney and analysis of variance, reported +/− SEM.

RESULTS

By 2 mo all animals implanted with TES generated visible deep purple TES (Fig. 1) from SU histology revealed organized spleen parenchyma (Fig. 2) with white pulp lacking germinal centers organized around arteries that stain for von Willebrand Factor (Fig. 3) and red pulp with venous sinuses. Immunohistochemical staining for the antigen CD3 was detected in the interfollicular zone (data not shown). In early TES (wk 2 and 3), there was developing splenic architecture without evidence of necrosis. Pitted erythrocytes were seen on blood smear at 16 wk. The harvested TES was approximately twice the size of the spleen slice (Fig. 4). No animal in the Splenectomy group had evidence of splenosis at necropsy. The polymer was completely resorbed in the TES animals, as shown by the lack of refractive polymer seen on histology and on gross inspection.

Animals implanted with the spleen slices also generated organized splenic parenchyma (Fig. 5) and had pitted erythrocytes on blood smear at 16 wk. Survival proportions varied following inoculation with *S. Pneumoniae* (Fig. 6). Control animals (100%) were followed by TES (85.7%, death on d 3 and 4), Spleen Slice (71.43%, d 2 to 4) and Splenectomy (41.17%, d 1 to 4). Compared to Splenectomy, Control and TES groups were statistically significant ($P = 0.0002$, $P = 0.0087$; hazard ratio of splenectomy = 5.493) and the Slice

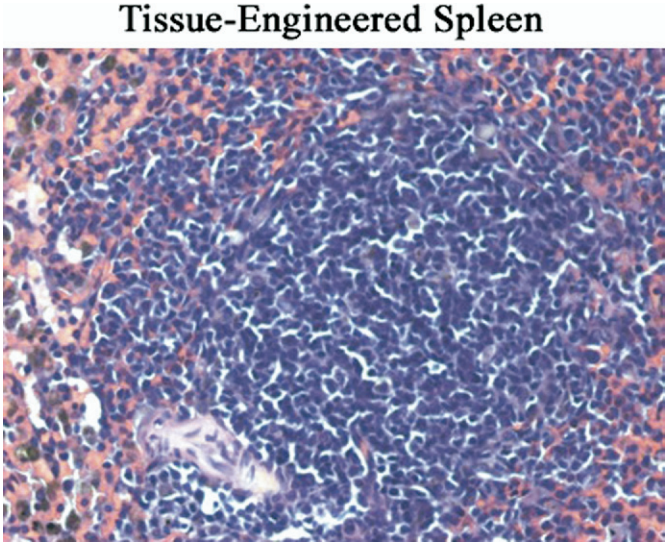

FIG. 2. H&E TES at 16 wk, original magnification.

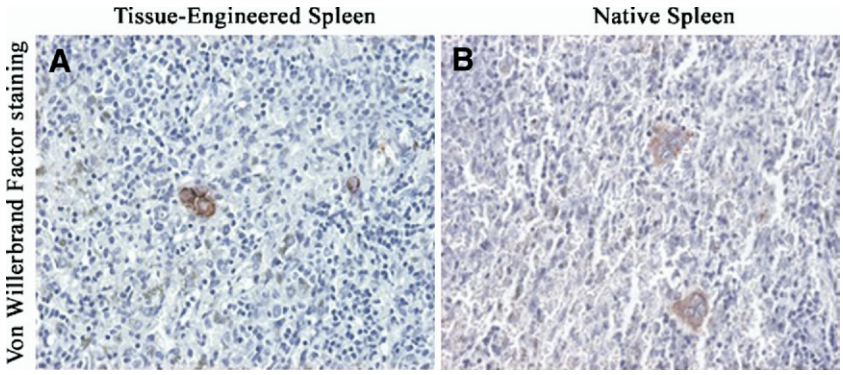

FIG. 3. TES (A) and native spleen (B) stain for immunohistochemical detection of the antigen von Willebrand Factor in central arterioles, original magnification 10×.

group was nearly statistically significant ($P = 0.0642$, hazard ratio of splenectomy = 2.673). DNA assays of the preimplant TES construct and the preimplant spleen slices were not statistically different significantly in ng DNA/mg dry weight. DNA content of the harvested TES, TES without splenectomy, spleen slice, and native spleen were not significantly different, at 7.836, 9.456, 8.764, and 8.223 ng DNA/mg dry weight.

DISCUSSION

This is the first report of the use of tissue engineering techniques to replace the juvenile spleen after splenectomy. The omental implantation of the TES protected against pneumococcal septicemia with a survival proportion of 85.7% compared with 41.17% of splenectomized animals. Spleen slice was also protective with 71.43% survival. The sequence of deaths in this study was different from previous studies [14] in which the spleen slice deaths have been later than the deaths of splenectomized animals. In addition, pitted erythrocytes persisted in all groups except the controls. The hazard ratio of splenectomy compared with TES (5.493) was nearly double that of spleen slice (2.673), with larger volumes of splenic tissue harvested from TES animals. Size of splenic implants has not been definitively correlated with function, and critical splenic mass therefore remains theoretical [10].

We report this finding as a model in which to pursue the pathways that allow solid organs to regenerate, and in the case of the tissue-engineered spleen, to function appropriately. Twenty years ago, in the earliest investigations of a similar technique by the senior author, selective cell transplantation using a bioabsorbable artificial polymer as a matrix resulted in three of 66 matrixes seeded with hepatocytes showing viable hepatocytes, and no pancreatic cells survived implantation [23]. In 23 implantations of intestinal cells, there were three cases of engraftment, and one 6 mm cyst formed [23]. Tissue-engineered intestine has now progressed in the rodent model to usable quantities that function in replacement models with high fidelity, and the specificity of each portion of the gastrointestinal tract. A similar rate of progress with solid organs would be clinically important.

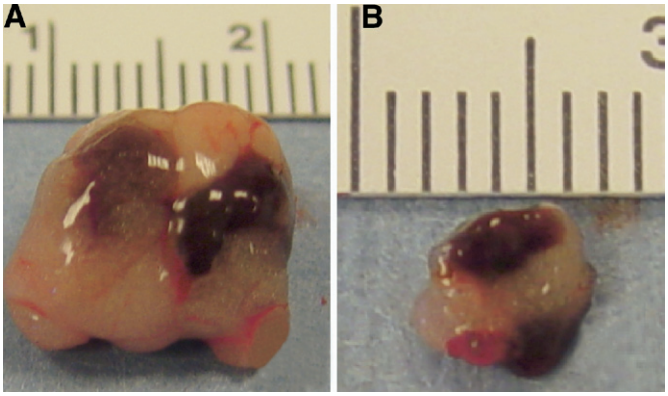

FIG. 4. Gross examination of TES (A) and spleen slice (B) at 16 wk.

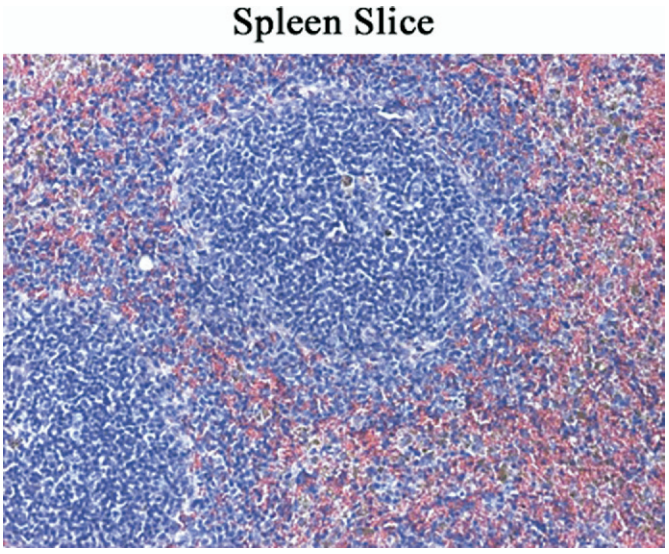

FIG. 5. H&E spleen slice at 16 wk, original magnification 4×.

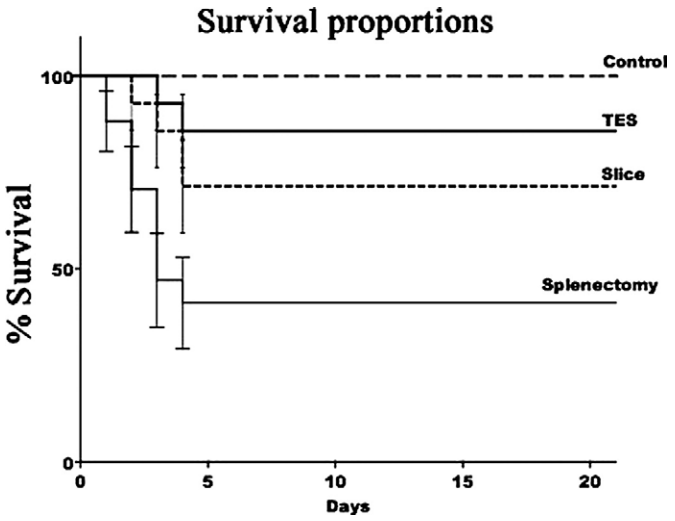

FIG. 6. Survival proportions of Control, TES, Spleen Slice, and Splenectomy groups over 21 d after pneumococcal infection.

Direct comparison of TES and spleen slice techniques requires further study of specific immune function. However, it can be unequivocally stated that the formation of TES is a successful novel strategy for producing functional spleen, and in the case of severe pediatric trauma, it could be an attractive strategy for the preservation of splenic mass. Early authors reported the failure of splenosis when the native spleen is present, but as shown in Fig. 1, TES grew under these conditions. It may be advantageous to avoid the primary phase of almost complete necrosis that occurs after transplant of a spleen slice.

Uniform processing and a biodegradable reticular framework produces greater splenic mass with appropriate splenic architecture and function. This report of successful engineering of a functional solid organ through cellular transplantation on a biodegradable scaffold indicates an exciting future direction. The next step forward would be a careful dissection of the mechanism of this solid organ tissue formation. The steps that occur from seeding to development of the engineered construct have not been evaluated, especially with reference to the necessary contributions of the donor and the host.

ACKNOWLEDGMENTS

This study was funded by the Center for the Integration of Medicine and Innovation in Technology, Department of Defense DAMDIT-99-2-9001.

REFERENCES

1. Singer DB. Postsplenectomy sepsis. In: Rosenberg HS, Bolande RP, Eds. Perspectives in Pediatric Pathology. Chicago: Yearbook Medical Publishers, Inc., 1973:285.
2. Shaw JH, Print CG. Postsplenectomy sepsis. Br J Surg 1989; 76:1074.
3. Green JB, Shackford SR, Sise MJ, et al. Late septic complications in adults following splenectomy for trauma: A prospective analysis in 144 patients. J Trauma 1986;26:999.
4. Krivit W, Giebink GS, Leonard AS. Overwhelming postsplenectomy infection. Surg Clin North Am 1979;59:223.
5. Leonard AS, Giebink GS, Basel JJ, et al. The overwhelming postsplenectomy sepsis problem. World J Surg 1980;4:423.
6. Velanovich V, Tapper D. Decision analysis in children with blunt splenic trauma: The effects of observation, splenorrhaphy, or splenectomy on quality-adjusted life expectancy. J Ped Surg 1993;28:179.
7. Culligford GK, Watkins DN, Watts ADJ, et al. Severe late postsplenectomy infection. Br J Surg 1991;78:716.
8. Griffini L, Tizzoni G. Etude expérimentale sur la réproduction partielle de la rate. Arch Ital Biol 1883;4:303.
9. Buchbinder JH, Lipkoff CJ. Splenosis: Multiple peritoneal splenic implants following abdominal injury. A report of a case and review of the literature. Surgery 1939;6:927.
10. Holdsworth RJ. Regeneration of the spleen and splenic autotransplantation. Br J Surg 1991;78:270.
11. Gagnon RF, MacLennan ICM. Immune transfer using spleen fragments. J Clin Lab Immunol 1982;9:7.
12. Tavassoli M, Ratzam RJ, Crosby WH. Studies on regeneration of heterotopic splenic autotransplants. Blood 1973;41:701.
13. Vega A, Howell C, Krasna I, et al. Splenic autotransplantation: optimal functional factors. J Pediatr Surg 1981;16:898.
14. Patel J, Williams JS, Naim JO, et al. Protection against pneumococcal sepsis in splenectomized rats by implantation of splenic tissue into an omental pouch. Surgery 1982;91:638.
15. Choi RS, Vacanti JP. Preliminary studies of tissue-engineered intestine using isolated epithelial organoid units on tubular synthetic biodegradable scaffolds. Trans Proc 1997;29:848.
16. Evans GS, Flint N, Somers AS, et al. The development of a method for the preparation of rat intestinal epithelial cell primary cultures. J Cell Sci 1992;101:219.
17. Grikscheit TC, Ogilvie JB, Ochoa ER, et al. Tissue-engineered colon functions in vivo. Surgery Aug 2002;132:200.
18. Grikscheit T, Ochoa ER, Ramsanahie A, et al. Tissue-engineered large intestine resembles native colon with appropriate in vitro physiology and architecture. Ann Surg 2003;238:35.
19. Perez A, Grikscheit TC, Blumberg RS, et al. Tissue-engineered small intestine: Ontogeny of the immune system. Transplantation 2002;74:619.
20. Grikscheit TC, Siddique A, Ochoa ER, et al. Tissue-engineered small intestine improves recovery after massive small bowel resection. Ann Surg 2004;240:748.
21. Grikscheit T, Ochoa ER, Srinivasan A, et al. Tissue-engineered esophagus: Experimental substitution by onlay patch or interposition. J Thorac Cardiovasc Surg 2003;126:537.
22. Griffith LG, Naughton G. Tissue engineering—current challenges and expanding opportunities. Science 2002;295:1009.
23. Vacanti JP, Morse MA, Salteman WM, et al. Selective cell transplantation using bioabsorbable artificial polymers as matrices. 1988;23:(1 Pt 2):3.