Surg Endosc (2011) 25:1723–1729
DOI 10.1007/s00464-010-1502-3

Video-assisted thoracoscopic solitary pulmonary nodule resection after CT-guided hookwire localization: 43 cases report and literature review

Sufeng Chen · Jianhua Zhou · Jie Zhang · Hong Hu · Xiaoyang Luo · Yawei Zhang · Haiquan Chen

Received: 29 September 2009 / Accepted: 3 September 2010 / Published online: 22 December 2010

Abstract
Background Peripheral subpleural solitary pulmonary nodules can be visualized and resected easily at thoracoscopy, but it is very difficult to localize deep nonpalpable pulmonary nodules that lie in lung parenchyma. The purpose of this article was to study the effectiveness of video-assisted thoracoscopic solitary pulmonary nodules resection after computed tomography (CT)-guided hookwire localization and to review the literature related to solitary pulmonary nodule diagnosis and treatment.
Methods From April 2008 to June 2009, 43 patients with a solitary pulmonary nodule who had undergone CT-guided hookwire localization and video-assisted thoracoscopic surgery (VATS) were studied.
Results Two cases were considered unsuccessful, other patients underwent CT-guided hookwire localization successfully, and ten patients had an asymptomatic minimal pneumothorax that did not require any intervention. The diameter of nodules ranged from 5 to 30 mm as measured by CT (mean 17.2 ± 7.5 mm). The distance between the center of nodule and visceral pleural ranged from 2 to 40 mm (mean 18.5 ± 9.3 mm). Of the 41 scheduled VATS procedures, 38 patients underwent thoracoscopic wedge resection. Twenty-two of 41 patients who revealed primary lung cancer after frozen-section examination underwent VATS lobectomy and lymphadenectomy. Three patients were converted to thoracotomy, and a major postoperative hemothorax occurred in one patient. No intra- or postoperative mortality or morbidity was recorded.
Conclusions Video-assisted thoracoscopic solitary pulmonary nodule resection after CT-guided hookwire localization is a safe and effective procedure for accurate diagnosis and resection of indeterminate solitary pulmonary nodules.

Keywords CT guidance · Hookwire · Solitary pulmonary nodule · Video-assisted thoracoscopic surgery

A solitary pulmonary nodule (SPN) presents clinicians with diagnostic and therapeutic challenges. Deciding whether to choose surgery as a treatment option is one of the many important decisions that both surgeons and patients alike have to make. When it becomes clear that surgery is the only viable option, video-assisted thoracoscopic surgery (VATS) is the optimal choice, because it has been proven to be both safe and technically feasible [1]. It provides increased comfort for the patient and lower morbidity compared with standard thoracotomy procedures [2]. However, the disadvantage of VATS is the difficulty in detecting subpleural nodules, which are frequently neither visible nor palpable. Despite the fact that there are many techniques for preoperative localization of pulmonary nodules, computed tomography (CT)-guided hookwire localization may be the most appropriate method for patients with solitary pulmonary nodules.

Sufeng Chen, Jianhua Zhou and Jie Zhang contributed equally to this paper.

S. Chen · J. Zhou · J. Zhang · H. Hu · X. Luo · Y. Zhang · H. Chen (✉)
Department of Thoracic Surgery, Cancer Hospital of Fudan University, Shanghai, China
e-mail: hqchen1@yahoo.com

Y. Zhang
e-mail: zhangyawei68@hotmail.com

S. Chen · J. Zhou · J. Zhang · H. Hu · X. Luo · Y. Zhang · H. Chen
Department of Oncology, Shanghai Medical College, Fudan University, Shanghai 200032, China

We describe the procedures and assess the usefulness of the CT-guided hookwire localization technique based on our experiences, as well as review the current available literature regarding SPN diagnosis and treatment.

Patients and methods

From April 2008 to June 2009, 43 patients (24 men, 19 women; age range, 21–65 (mean, 54.2 ± 7.9) years) with a solitary pulmonary nodule underwent CT-guided hookwire localization and VATS. Only a nodule with a size <30 mm in diameter and a distance between the center of the nodule and visceral pleural <40 mm were included in the study. Patients who were diagnosed with pleurisy were excluded. The consent form was signed by every patient or his/her legal representative. The study was approved by the Ethics Committee of Shanghai Cancer Hospital of Fudan University.

On the day of the operation, the CT-guided hookwire localization was performed in the patient at the CT room. The hookwire is composed of a 21-gauge, 10-cm long, calibrated cannula, and a 20-cm long calibrated wire with a thorn (Angiotech, Medical Device Technologies US; Fig. 1A). After the CT scan (Fig. 1B), a needle puncture site was selected and the distance between the puncture site and the center of the nodule was measured. After sterilization of skin around the puncture site and local anesthesia, the cannula needle housing the hookwire was inserted gradually through the chest wall and pulmonary parenchyma and pierced the nodule with sequential CT guidance. Then, when the outer cannula needle was withdrawn, the horn of the hookwire would be released and anchor the nodule. During the procedure, blood pressure, breathing rate, and arterial oxygen saturation (SaO_2) of the patient were monitored. In addition, the related potential complications were scrutinized, especially for pneumothorax and hemorrhage. If there were no complications, a control CT scan was performed to verify correct positioning (Fig. 1C, D). The hookwire extending outside the chest wall was positioned carefully on the skin under gauze dressings. The patient was then transferred to the operating room directly after localization.

Video-assisted thoracoscopic resection of the lesion was performed under general anesthesia using single lung ventilation via a double-lumen endobronchial tube. The gauze dressings of the hookwire were unpacked before collapse of the ipsilateral lung. The procedures involved making two thoracic ports of 11.5 mm, one for the thoracoscope, and the other for the endoscopic stapler, and a 5.5-mm thoracic port for the lung forceps (Fig. 2A). Thoracoscopic wedge resections were performed using an endoscopic stapler (Fig. 2B, C). The resected wedge of lung tissue with the hookwire was packed into sterile gloves to prevent chest wall implantation of malignant disease and was withdrawn from the chest via one of the intercostal incisions. All resected lung specimens were sent for frozen-section examination immediately. If these section results were benign, a chest tube was inserted and VATS was completed after excluding bleeding and air leak. If the diagnosis was primary lung cancer, VATS lobectomy and lymphadenectomy were performed. If

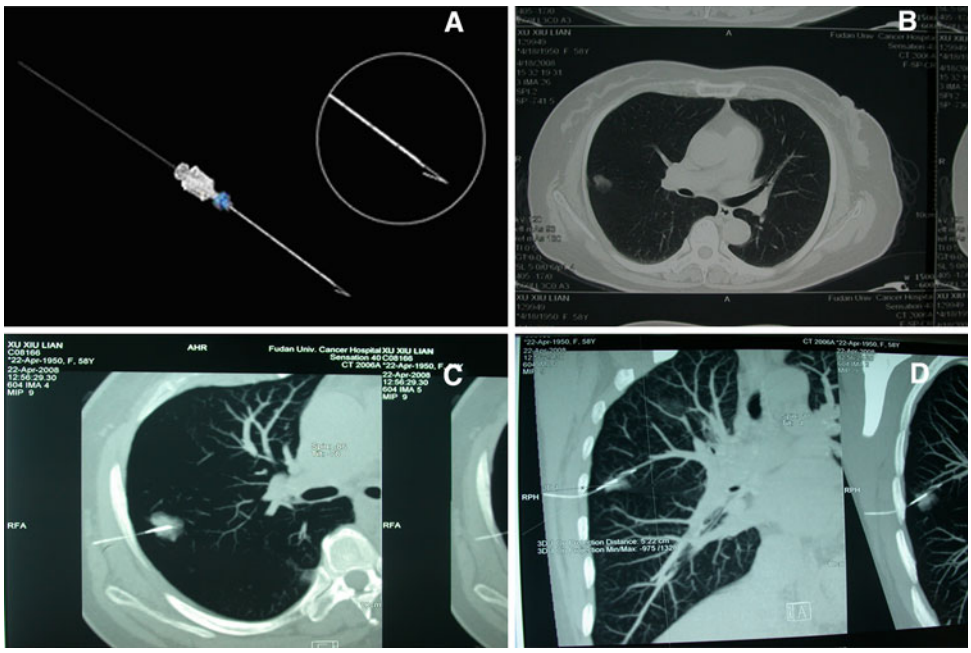

Fig. 1 **A** Angiotech, US Medical Device Technologies, Inc. 21-gauge × 10-cm. **B** CT scan indicated a solitude pulmonary nodule in the right upper lobe. **C, D** CT scan shows that the hookwire is positioned in the nodule; no pneumothorax and hemothorax were detected

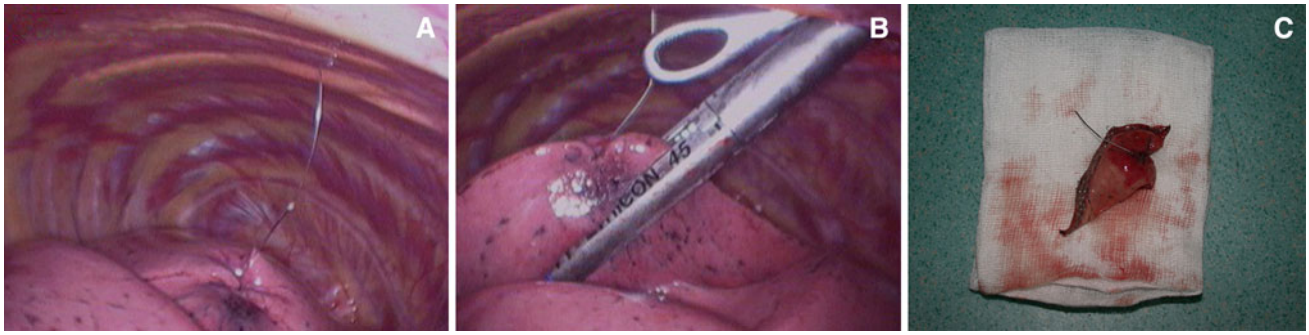

Fig. 2 **A** Right lateral approach video-assisted thoracoscopic view of the right upper lung. **B** Ongoing wedge resection directly guided by hookwire with no obviously visible subpleural lesion. **C** Resected wedge of lung tissue with the hookwire still in place

necessary, another thoracic incision could be made to facilitate the subsequent thoracoscopic resection. However, in rare cases, we converted to a thoracotomy and performed a formal lobectomy if it was difficult to proceed with thoracoscopic resection due to problems, such as adhesion and hookwire dislodgement. When lesions proved to be metastases, the procedure was terminated.

Results

Two cases of hookwire localization failed, each due to a nodule that was difficult to locate and puncture. The other patients underwent CT-guided hookwire localization successfully. Of the 41 patients, 26 lesions occurred in the right lung and 15 in the left lung. The diameter of nodule ranged from 5 to 30 mm as measured by CT (mean 17.2 ± 7.5 mm), and the distance between the center of nodule and visceral pleural ranged from 2 to 40 mm (mean 18.5 ± 9.3 mm).

The time to execute the surgical procedures ranged from 28 to 175 min (mean 91.9 ± 48.2 min). Thirty-eight patients underwent thoracoscopic wedge resection, and for 22 of 41 patients, frozen-section examination revealed primary lung cancers and it was deemed necessary for these patients to undergo VATS lobectomy and lymphadenectomy. Thoracoscopic wedge resection was impossible and was converted to thoracotomy in three patients because of the dislodgement of the hookwire and strong pleural adhesions. There was one case in which frozen-section examination indicated a benign nodule, but permanent-section analysis confirmed adenocarcinoma 1 week later. This patient was admitted to the hospital and received an emergency formal lobectomy and lymphadenectomy.

Hence, malignant disease was found in 70.7% (29/41) of all patients, including the patient who was treated by thoracotomy after exploring the conflicting results between the frozen-section and permanent-section diagnoses and confirming malignancy. Primary malignancy occurred in 56.1% (23/41) of patients and of the primary malignancies, adenocarcinoma was the commonest (41.5%), Table 1

Table 1 Historical comparison between open chest surgery and CT-guided hookwire localization for VATS

Histology	Hookwire localization (n)	Open surgery (n)
Adenocarcinoma	17	141
Squamous cell carcinoma	1	127
Large cell carcinoma	2	21
Small cell lung carcinoma	1	11
Mucoepidermoid carcinoma	1	4
Mixed cell carcinoma	1	15
Leiomyosarcoma	0	1
Poorly differentiated cancer	0	19
Metastatic lung tumor	6	3
Benign disease	12	78
	41	421

Patients' data come from the same period of time

Table 2 Demographic features of patients

Characteristics	Benign	Malignant	*P* value
Age (year)			0.28
>55	4	15	
≤55	8	14	
Gender			0.76
Male	6	16	
Female	6	13	
Cigarette smoking			0.82
Current and former	7	18	
Never	5	11	
Cancer history			0.02
Yes	4	21	
No	8	8	

Two failed cases are excluded

Table 3 Complications

Complication	No. of cases	%	Treatment
Asymptomatic pneumothorax	10	24.4	Nontreatment
Hookwire dislodgments	2	4.9	Convert to thoracotomy
Hemothorax (postoperation)	1	2.4	Reoperation and hemostasis

shows the historical results and the comparison between open chest surgery and CT-guided hookwire localization for VATS. We also found that SPNs were probable pulmonary malignant neoplasm in patients with cancer history ($P = 0.02$; Table 2).

Ten patients (24.4%) were identified with asymptomatic minimal pneumothorax, which did not require immediate preoperative chest tube drainage. In two cases, the hookwire dislodged while tenting of the lung surface to facilitate resection; the VATS was converted to thoracotomy, and resection was successfully performed. A major postoperative hemothorax, which required reoperation and hemostasis, occurred in one patient; the bleeding originated from an intercostal vessel of the thoracic port, and the patient recovered without further incident. The complications are listed in Table 3. The postoperative hospitalization ranged from 3 to 7 days (mean 5.2 ± 1.1) days. No intra- or postoperative mortality or morbidity was recorded. In our group, five patients were lost to follow-up (1 with benign disease, 4 with malignant disease). Of the other 36 patients, 11 patients with benign pathology are alive, and 6 patients with malignant disease died during the follow-up period. The median follow-up time was 13.5 months by the end of April 2010 for the entire study.

Literature review and discussion

A solitary pulmonary nodule or "coin lesion" is an approximately round lesion that is < 3 cm in diameter and that is completely surrounded by pulmonary parenchyma, without other abnormalities [3]. When faced with this pulmonary lesion, the first step is to make a definitive diagnosis of the nodule. At present, the process of diagnosis may include CT scanning, positron emission tomography (PET) with 18-fluorodeoxyglucose (FDG), flexible bronchoscopy, percutaneous needle aspiration biopsy, and transbronchic needle biopsy; there are additional, less frequently used procedures. Percutaneous needle aspiration biopsy and transbronchic needle biopsy are well-established, useful procedures for diagnosing lung tumors; both are much less invasive than surgery but are less reliable for ruling out malignancy because of inadequate tissue sample or failure of biopsy [4]. Moreover, there have been some reports on tumor dissemination after transthoracic needle biopsy [5, 6]. Furthermore, there are some patients with a new SPN without benign-appearing calcifications, and these should be considered potentially malignant until proven otherwise. For these patients, surgical resection is the ideal approach, because it is both diagnostic and therapeutic [7]. Due to the fact that an SPN in a patient with a history of cancer is most probably a primary lung neoplasm [8, 9], we recommend surgical resection as the first choice.

As far as surgery is concerned, VATS may be the best choice. With thoracoscopic technology development and surgical instrument refinement, many institutions excise these small growing nodules by using VATS to minimize postoperative morbidity and to save as much of the volume of lung tissue as possible; in the meantime, the survival is no less than or superior to open surgery in patients with stage Ia disease [10–12]. VATS has become routine and widely accepted for the resection of solitary pulmonary nodules. However, some patients need conversion to thoracotomy, and the most common reason for the conversion is failure to localize the lesion. This conversion occurs in 63% of patients if the nodule is $\leq$10 mm in diameter and $>$5 mm from the pleural surface [13]. Therefore, it is very important to locate the SPN before the operation, especially for some nodules that are situated in lung parenchyma or cannot be palpable after lung deflation.

There are several techniques to locate SPN, such as preoperative or intraoperative injection of methylene blue dye at the site of an SPN [14, 15], intraoperative ultrasound, or radioguided detection and CT-guided positioning of a metal wire [16–20]. Each of these localization methods has its own advantages and drawbacks. Due to overinfusion of the methylene blue dye or an error in nodule localization, the failure rate of the methylene blue injection is approximately 13% [21]. Intraoperative ultrasound localization of SPN also has some limitations: it is operator-dependent and requires a special flexible probe and complete collapse of the assessed lung [18]. Davini et al. [22] and Gonfiotti et al. [23] introduced the method of radioguided localization of SPN; the disadvantages of this technique are the requirement of radionuclide injection, a magnetic probe connected to a gamma camera, and increased exposure to radiation.

At present, the technique most commonly used is CT-guided hookwire localization. Preoperative CT-guided hookwire localization is an effective and useful technique that helps in precise lesion localization and makes VATS resection of an SPN easy and fast; it also is well suited for the localization of small and deep-seated lesions [19, 23–27]. Light traction on the suture thread during VATS resection renders deep-seated lesions more superficial and

facilitates complete excision by endostapler [24]. In our limited experience, we believe that the combination of CT-guided hookwire localization and VATS has some merits: it is accurate in localizing the lesion, simple to operate, and there are generally no serious complications. Another merit is that the collapse of the lung does not modify the position of the hookwire, which remains anchored to the nodule. The presence of the wire hook makes it possible to exert a slight traction, and thus facilitate the positioning of the endostapler. In addition, this technique is associated with less postoperative pain, an earlier return to normal pulmonary function, and shortened hospital stay. In particular, the choice of incision for VATS is flexible after localization. We encountered five patients with SPN who were treated with radiation for breast cancer, and care must be taken to avoid injuring the tissue of the radiotherapy region when selecting the incision. CT-guided hookwire localization highlights the main advantage: the thoracic incision can be made in the normal healthy chest wall after localization without worrying about the failure of localization of the lesion. However, in any situation, if the distance between the center of nodule and visceral pleural is further than 40 mm, because the risk of puncture-related complications is increased and VATS wedge resection becomes difficult, regular lobectomy is recommended.

The CT-guided hookwire localization is a very safe procedure. Absolute contraindications include history of unexplained bleeding, inability to identify an appropriate puncture site, and the uncooperative patient. Relative contraindications include anticoagulation therapy, puncture of only one functional lung, cardiac insufficiency, severe emphysema, and chronic respiratory insufficiency. At times the pulmonary nodule is located far below the pleural surface or in strict contact with hilar structures; therefore, this condition should be considered a contraindication to this technique.

Moreover, there are some specific anatomic locations that would prohibit this technique. For instance, if the SPN is in close association with the mediastinal great vessels, although it is technically feasible to perform CT-guided localization, the risk of hemorrhage is increased because of the sharp point of the hookwire. Sometimes, the SPN is inaccessible due to the blockage of the skeletal structure.

The most common complication is pneumothorax, which can occur during localization of the hookwire. The incidence of pneumothorax as reported by Chen et al. [25] is 18.6% (8/43); in our study, asymptomatic minimal pneumothorax not requiring any intervention was found in 10 of 41 (24.4%) patients. In most cases, the pneumothorax is asymptomatic and does not need chest tube drainage; however, symptomatic pneumothorax or a small pneumothorax in a patient with marked emphysema may require chest tube evacuation.

Dislodgement occurred in two patients in our series (4.9%) when hookwire manipulation caused tenting of the lung surface to facilitate resection, after which the VATS was converted to thoracotomy and resection was successfully performed. The rate of hookwire dislodgement in our experience was less than that of Davini and colleagues have reported [22]. Thaete et al. [28] have reported that wire dislodgement occurred in 6 of 52 (12%) cases without an initial pneumothorax and in 16 of 48 (33%) cases if a pneumothorax occurred. Three situations may be responsible for dislodgment of the hookwire. First, as the patient is transferred to surgery, the hookwire can be pulled as the chest wall and shoulder girdle move in relation to the lung. Second, the friction between the chest wall and the hookwire makes the hookwire dislodge during surgical deflation of the lung. Third, when the surgeons apply traction on the hookwire to tent the lung to facilitate resection it can dislodge. Apart from the above-mentioned reasons, we feel that dislodgement of the hookwire is related to the size and depth of the lesion. The larger the nodule is and the deeper it occurs, the greater the force that is required to tent the lung; hence, the risk of dislodgement is increased.

We take the following measures to prevent such incidents from occurring. The patient is told to breathe calmly and keep the upper body stationary after the localization of the hookwire. The free end of wire is cutoff, leaving a 2–3 cm tail, before collapse of the lung. Furthermore, caution must be taken to apply light traction on the wire to tent the lung during wedge resection. Caution is advised because the hookwire dislodgement can lead to the loss of any intraoperative reference.

Localized hemorrhage was not found in our CT-guided hookwire localization procedures, but a major postoperative hemothorax occurred in one patient on the same day of the operation, for which reoperation and hemostasis were performed immediately. We found that the bleeding originated from an intercostal vessel of the thoracic port. There was another case in which frozen-section examination indicated a benign nodule, but permanent-section analysis confirmed adenocarcinoma 1 week later. The patient was admitted to the hospital and received an emergency formal lobectomy and lymph node dissection. The two complications have no direct relationship with the procedure of CT-guided hookwire localization and are not typical complications associated with VATS.

Malignant lesions accounted for approximately 70.7% of the patients in our series, much higher than Alzahouri et al. [4], who reported 26% because metastatic lesions occupied a certain proportion of the diseases; however, our work was similar to what had been reported by other surgeons [29, 30]. These data illustrate the fact that it is necessary for us to aggressively deal with these diseases.

Some clues are good indications of malignancy. Malignant SPN tends to have lobulated or shaggy borders; other characteristic features that may appear on the X-ray include a tail on the lesion and a corona radiata. Moreover, a history of malignant disease is probably the most important indicator about whether an SPN is cancerous.

From our experience and according to available literature, we conclude that video-assisted thoracoscopic solitary pulmonary nodule resection after CT-guided hookwire localization is a safe and effective procedure for accurate diagnosis and resection of indeterminate solitary pulmonary nodules, with no associated mortality or significant morbidity.

Acknowledgments We thank the Department of Histopathology and the Department of Medical Imaging at the Shanghai Cancer Hospital, Shang, China, for their assistance with this work.

Disclosures Drs. Sufeng Chen, Jianhua Zhou, Jie Zhang, Hong Hu, Xiaoyang Luo, Yawei Zhang, and Haiquan Chen have no conflicts of interest or financial ties to disclose.

References

1. Congregado M, Merchan RJ, Gallardo G, Ayarra J, Loscertales J (2008) Video-assisted thoracic surgery (VATS) lobectomy: 13 years' experience. Surg Endosc 22:1852–1857
2. Eichfeld U, Dietrich A, Ott R, Kloeppel R (2005) Video-assisted thoracoscopic surgery for pulmonary nodules after computed tomography-guided marking with a spiral wire. Ann Thorac Surg 79:313–316; discussion 316–317
3. Ost D, Fein AM, Feinsilver SH (2003) Clinical practice. The solitary pulmonary nodule. N Engl J Med 348:2535–2542
4. Alzahouri K, Velten M, Arveux P, Woronoff-Lemsi MC, Jolly D, Guillemin F (2008) Management of SPN in France. Pathways for definitive diagnosis of solitary pulmonary nodule: a multicentre study in 18 French districts. BMC Cancer 8:93
5. Raftopoulos Y, Furey WW, Kacey DJ, Podbielski FJ (2000) Tumor implantation after computed tomography-guided biopsy of lung cancer. J Thorac Cardiovasc Surg 119:1288–1289
6. Kim JH, Kim YT, Lim HK, Kim YH, Sung SW (2003) Management for chest wall implantation of non-small cell lung cancer after fine-needle aspiration biopsy. Eur J Cardiothorac Surg 23:828–832
7. Tan BB, Flaherty KR, Kazerooni EA, Iannettoni MD (2003) The solitary pulmonary nodule. Chest 123:89S–96S
8. Laisaar T, Vooder T, Umbleja T (2008) Thoracoscopic resection of a solitary pulmonary nodule in patients with a known history of malignancy. Thorac Cardiovasc Surg 56:418–421
9. Mery CM, Pappas AN, Bueno R, Mentzer SJ, Lukanich JM, Sugarbaker DJ, Jaklitsch MT (2004) Relationship between a history of antecedent cancer and the probability of malignancy for a solitary pulmonary nodule. Chest 125:2175–2181
10. Walker WS, Codispoti M, Soon SY, Stamenkovic S, Carnochan F, Pugh G (2003) Long-term outcomes following VATS lobectomy for non-small cell bronchogenic carcinoma. Eur J Cardiothorac Surg 23:397–402
11. Oda M, Matsumoto I, Tamura M, Fujimori H, Shimizu Y, Matsunoki A, Ishikawa N, Ohtake H, Watanabe G (2009) Video-assisted thoracic surgery for clinical stage I lung cancer. Kyobu Geka 62:281–284
12. Yan TD, Black D, Bannon PG, McCaughan BC (2009) Systematic review and meta-analysis of randomized and nonrandomized trials on safety and efficacy of video-assisted thoracic surgery lobectomy for early-stage non-small-cell lung cancer. J Clin Oncol 27:2553–2562
13. Suzuki K, Nagai K, Yoshida J, Ohmatsu H, Takahashi K, Nishimura M, Nishiwaki Y (1999) Video-assisted thoracoscopic surgery for small indeterminate pulmonary nodules: indications for preoperative marking. Chest 115:563–568
14. Lenglinger FX, Schwarz CD, Artmann W (1994) Localization of pulmonary nodules before thoracoscopic surgery: value of percutaneous staining with methylene blue. AJR Am J Roentgenol 163:297–300
15. Willekes L, Boutros C, Goldfarb MA (2008) VATS intraoperative tattooing to facilitate solitary pulmonary nodule resection. J Cardiothorac Surg 3:13
16. Miyoshi T, Kondo K, Takizawa H, Kenzaki K, Fujino H, Sakiyama S, Tangoku A (2006) Fluoroscopy-assisted thoracoscopic resection of pulmonary nodules after computed tomography-guided bronchoscopic metallic coil marking. J Thorac Cardiovasc Surg 131:704–710
17. Nakano N, Miyauchi K, Imagawa H, Kawachi K (2004) Immediate localization using ultrasound-guided hookwire marking of peripheral lung tumors in the operating room. Interact Cardiovasc Thorac Surg 3:104–106
18. Santambrogio R, Montorsi M, Bianchi P, Mantovani A, Ghelma F, Mezzetti M (1999) Intraoperative ultrasound during thoracoscopic procedures for solitary pulmonary nodules. Ann Thorac Surg 68:218–222
19. Kastl S, Langwieler TE, Krupski-Berdien G, Demir E, Izbicki JR (2006) Percutaneous localization of pulmonary nodules prior to thoracoscopic surgery by CT-guided hook-wire. Anticancer Res 26:3123–3126
20. Chen W, Chen L, Qiang G, Chen Z, Jing J, Xiong S (2007) Using an image-guided navigation system for localization of small pulmonary nodules before thoracoscopic surgery: a feasibility study. Surg Endosc 21:1883–1886
21. Kerrigan DC, Spence PA, Crittenden MD, Tripp MD (1992) Methylene blue guidance for simplified resection of a lung lesion. Ann Thorac Surg 53:163–164
22. Davini F, Gonfiotti A, Vaggelli L, De Francisci A, Gigli P, Janni A (2006) Thoracoscopic localization techniques for patients with solitary pulmonary nodule: radioguided surgery versus hookwire localization. J Cardiovasc Surg (Torino) 47:355–359
23. Gonfiotti A, Davini F, Vaggelli L, De Francisci A, Caldarella A, Gigli PM, Janni A (2007) Thoracoscopic localization techniques for patients with solitary pulmonary nodule: hookwire versus radio-guided surgery. Eur J Cardiothorac Surg 32:843–847
24. Pittet O, Christodoulou M, Pezzetta E, Schmidt S, Schnyder P, Ris HB (2007) Video-assisted thoracoscopic resection of a small pulmonary nodule after computed tomography-guided localization with a hook-wire system. Experience in 45 consecutive patients. World J Surg 31:575–578
25. Chen YR, Yeow KM, Lee JY, Su IH, Chu SY, Lee CH, Cheung YC, Liu HP (2007) CT-guided hook wire localization of subpleural lung lesions for video-assisted thoracoscopic surgery (VATS). J Formos Med Assoc 106:911–918
26. Poretti FP, Brunner E, Vorwerk D (2002) Simple localization of peripheral pulmonary nodules: CT-guided percutaneous hookwire localization. Rofo 174:202–207
27. Guermazi A, Miaux Y, Genant HK, Peterfy CG (2002) Be sure to insert—appropriately and safely—a hookwire!. AJR Am J Roentgenol 178:764–765
28. Thaete FL, Peterson MS, Plunkett MB, Ferson PF, Keenan RJ, Landreneau RJ (1999) Computed tomography-guided wire

localization of pulmonary lesions before thoracoscopic resection: results in 101 cases. J Thorac Imaging 14:90–98
29. Ciriaco P, Negri G, Puglisi A, Nicoletti R, Del Maschio A, Zannini P (2004) Video-assisted thoracoscopic surgery for pulmonary nodules: rationale for preoperative computed tomography-guided hookwire localization. Eur J Cardiothorac Surg 25:429–433
30. Hirai S, Hamanaka Y, Mitsui N, Morifuji K, Uegami S (2006) Role of video-assisted thoracic surgery for the diagnosis of indeterminate pulmonary nodule. Ann Thorac Cardiovasc Surg 12:388–392