The Laryngoscope
© 2012 The American Laryngological,
Rhinological and Otological Society, Inc.

Is the Use of Topical Fluorescein Helpful for Management of CSF Leakage?

Kayhan Ozturk, MD; Hakan Karabagli, MD; Serap Bulut, MD; Meryem Egilmez, MD; Mutlu Duran, MD

Objectives/Hypothesis: We aimed to evaluate the effectiveness of topical intranasal fluorescence application together with high-resolution computed tomography and magnetic resonance imaging and/or magnetic resonance cisternography for the preoperative diagnosis of cerebrospinal fluid (CSF) leakage and for intraoperative localization of CSF fistulas. We also assessed postoperative recurrence.

Study Design: Descriptive study.

Methods: Twenty-four cases underwent endonasal endoscopic repair for CSF leakage. Following intranasal topical application of fluorescein 10% to the middle turbinate-cribriform plate region and anterior wall of the sphenoid sinus, a color change of the fluorescein from yellow-brown to green was accepted as evidence of CSF leakage. A nasoseptal flap, collagen matrix, or fascia lata and septal cartilage graft were used for reconstruction of the CSF fistula.

Results: The use of topical fluorescein application was helpful in diagnosing CSF rhinorrhea preoperatively and locating the CSF fistula intraoperatively. One case had both ethmoid roof and sphenoid sinus defects, and this case underwent a second operation for closure of the sphenoid defect. All CSF leakages were successfully repaired by endoscopic endonasal surgery using a nasoseptal flap.

Conclusions: Cases with traumatic CSF leakage pose a higher risk of meningitis than the cases with spontaneous CSF leakage. Topical application of fluorescein is highly specific and sensitive in identifying preoperative, intraoperative, and postoperative CSF leakage. It is a simple, quick, and sensitive technique. The surgeon should be vigilant for multiple defects.

Key Words: Cerebrospinal fluid leak, cisternography, fluorescein, nasoseptal flap, rhinorrhea.

Level of Evidence: 2c

***Laryngoscope,* 122:1215–1218, 2012**

INTRODUCTION

Cerebrospinal fluid (CSF) leakage from the nose means there is a defect between the subarachnoid space and upper respiratory tract. CSF leakages can be spontaneous, traumatic, or iatrogenic. Traumatic CSF leakages can occur as a result of blunt or penetrating trauma or generally as a result of skull base surgery.[1–4] CSF leakage can cause significant life-threatening complications. To establish perfect closure without complications, it is crucial to identify the dural and bone defects. Multiple imaging examinations have been used to help localize these defects. Currently, intrathecal fluorescein injection using a blue-light cobalt filter and a yellow filter on the endoscope lens is the most common technique to localize the site of the leak. Significant side effects of intrathecal fluorescein have been published, because fluorescein is considered toxic to the central nervous system structures.[4–6] Jones et al.[7] reported the possibility of using intraoperative, topical, intranasal fluorescein to precisely locate the site of CSF leakage in three cases. In the current literature, there are limited studies of administration of topical intranasal fluorescein.[7–9] In the present study, we aimed to evaluate the effectiveness of topical intranasal fluorescence for the preoperative diagnosis of CSF leakage and for intraoperative localization of CSF. We also assessed postoperative recurrence.

MATERIALS AND METHODS

After local ethical committee approval (No: 2011/55), the data of 24 cases undergoing endonasal endoscopic repair for CSF leakage were presented. All surgical procedures and examinations were conducted by the senior author. Fourteen patients were male and 10 patients were female. Their ages ranged from 14 to 68 years (median age, 36.7 ± 13.3 years). Ten leaks were post-traumatic (three were postoperative), and 12 leaks were idiopathic. One case presented with a meningocele, and one case presented with an encephalocele. There was a history of initial surgery for CSF leakage in four cases. All patients were admitted to our clinic with clear sweet nasal discharge. To determine CSF leakage, the following procedure was followed. An oxymetazoline hydrochloride (0.5 mg/mL^{-1}) solution spray and 4% lidocaine solution spray were puffed into the each nostril twice for decongestion and topical anesthesia of the nasal cavity. Five minutes later, an examination by a 0°- and 30°-telescope of the whole nasal cavity was done and recorded using a high-resolution recording system. Two cotton pledgets soaked with 10% fluorescein (Fluorescite; Alcon Laboratories,

From the Department of Otolaryngology, Selcuklu Faculty of Medicine, Selcuk University, Konya, Turkey.

Editor's Note: This Manuscript was accepted for publication February 10, 2012.

The authors have no funding, financial relationships, or conflicts of interest to disclose.

Send correspondence to Kayhan Ozturk, MD, Assoicate Professor, Department of Otolaryngology, Selcuklu Faculty of Medicine, Selcuk University, Campus of Alaeddin Keykubat, 42075, Selcuklu, Konya, Turkey.
E-mail: kayhanozturk@selcuk.edu.tr

DOI: 10.1002/lary.23277

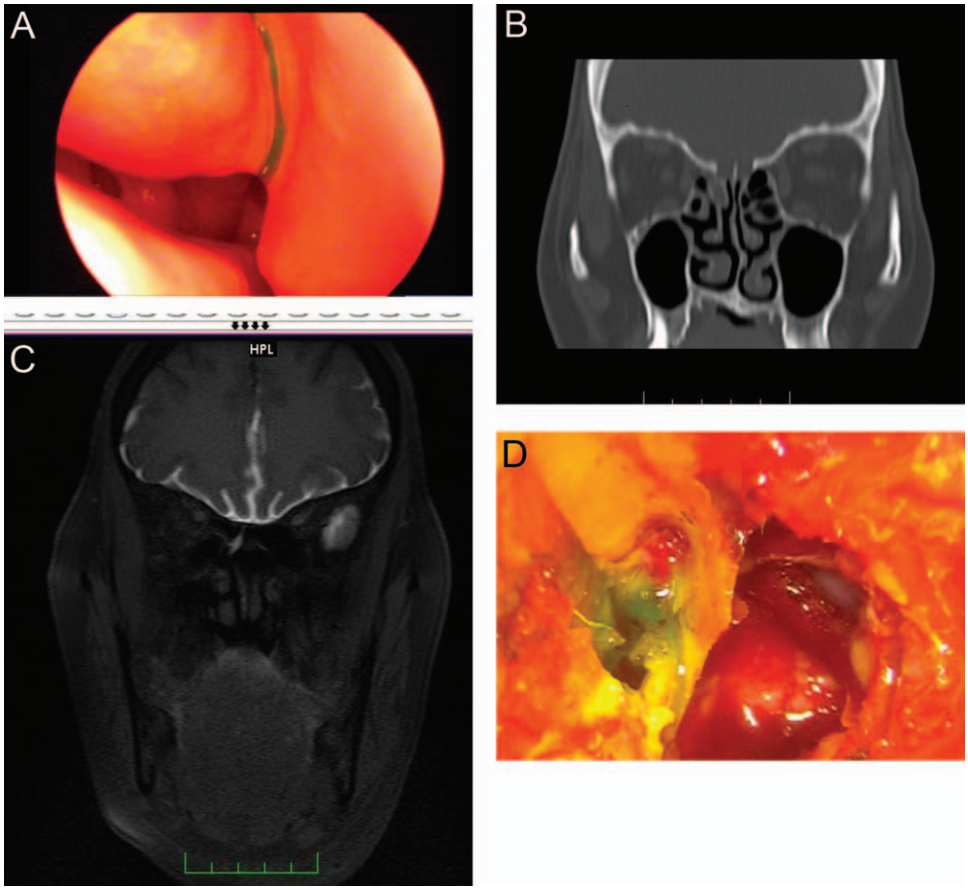

Fig. 1. Pictures obtained from the 62-year-old female with spontaneous CSF leakage from the right cribriform plate. (A) After topical application of fluorescein 10% for preoperative diagnosis, a change in the color from yellow-brown to green fluorescence over the nasal mucosa was considered as the presence of CSF. On the endoscopic picture, there is a change in the color from yellow-brown to green fluorescence over the nasal mucosa, which indicates the presence of CSF from the right cribriform plate. (B) On the coronal section of the high-resolution computed tomography, there is a defect on the right cribriform plate. (C) The coronal section of the magnetic resonance cisternography shows the CSF leakage from the right cribriform plate. (D) Intraoperative endoscopic picture shows a change in the color from yellow-brown to green fluorescence over the nasal mucosa that shows a dural defect.

Inc., Fort Worth, TX) were inserted into the nasal cavity and placed at the middle turbinate-cribriform plate region and anterior wall of the sphenoid sinus under endoscopic view. Cotton pledgets were removed after 5 minutes of application. Endoscopic examination of the nasal cavity were repeated again carefully by Valsalva maneuver and/or leaning forward. A color change of the fluorescein from yellow-brown to green was accepted an evidence of CSF leakage[7] (Fig. 1A). β-2 transferrin test or biochemical analysis of the collected material was performed. For localization of the defect, both high-resolution computed tomography (CT) scan (Fig. 1B) and magnetic resonance imaging (MRI) were performed in all 24 cases, and additional magnetic resonance (MR) cisternography (Fig. 1C) was performed in 13 of the cases. After confirming CSF leakage with the above-mentioned process, surgical reconstruction was initiated.

The CSF leak fistulas were repaired with the endoscopic endonasal approach under general anesthesia. Preoperative and operative preparation of the cases was similar to routine functional endoscopic sinus surgery, and the same instruments were used during surgery. The inferior part of the middle turbinate of the defective sites were resected using cut forceps. A Hadad-Bassagasteguy nasoseptal flap[10] from the defective-site nasal mucosa was harvested and pushed into the nasopharynx. After complete uncinectomy, frontal sinus and maxillary sinus ostiums were identified using an intact bulla technique and exposed. Anterior and posterior ethmoidectomies were carried out. The superior turbinate and ostium of the sphenoid sinus were identified. For sphenoid sinus defects, the anterior wall of the sphenoid sinus was completely removed. After exposure of the skull base, topical application of 10% fluorescein intranasally over a cotton pledget on the skull base was used, especially for suspected regions, and a change in the color from yellow-brown to green fluorescence over the nasal mucosa was considered evidence of the presence of CSF (Fig. 1D). The CSF leak was traced by resection of the surrounding mucosa. The bone edges of the fistula were skeletonized. Collagen matrix (Duraform; Codman & Shurtleff, Inc., Raynham, MA) or fascia lata graft was carefully inserted into the defective place as an overlay technique to repair the dural defect. A cartilage graft, which was harvested from the nasal septum, was inserted over the bone defect using an overlay or underlay technique to reconstruct the bone defect. This graft was covered by additional collagen matrix or fascia lata graft. The defective place and skull base were covered by the nasoseptal flap to reconstruct mucosa and periosteum. The free edges of the nasoseptal flap were reinforced by oxidized cellulose (Surgicel; Ethicon, Neuchatel, Switzerland). The flap was covered by an absorbable gelatin sponge (Gelspon-P; Eucare, Chennai, India). The whole supportive structure was kept in the place by fibrin glue. A Foley balloon catheter was inflated by 5 to 8 mL of saline solution to support the duraplasty material and control the bleeding. A Doyle II (Medtronic, Minneapolis, MN) intranasal airway splint was inserted into the defective site nasal cavity. All cases received prophylactic ceftriaxone sodium for 7 days. The lumbar drain was kept in for 4 to 7 days. CSF was drained at 5 mL/h. The Foley balloon catheter and nasal splint were taken out on postoperative days 5 and 21, respectively. The topical fluorescein test was then repeated to screen for recurrence.

RESULTS

The 24 cases presented in the present study were consecutive patients during a 4-year period. No patient

with CSF leakage during this period was omitted. A history of meningitis was present in 11 cases, and four of them had recurrent meningitis. Seven of 11 (63.3%) cases had traumatic CSF leakage, and all recurrent cases (100%) had traumatic CSF leakage. There was an ethmoid roof defect in 10 cases. Twelve defects were located in the cribriform plate, and three defects were located in the sphenoid sinus (two were superior and two were posterior). One case had both ethmoid roof and sphenoid sinus defects; only this case underwent a second operation for closure of the sphenoid defect from the other side nasoseptal flap using the same technique. Other cases were successfully closed. We did not observe a fat graft during the preoperative screening and surgery of the two cases initially repaired with a fat graft because they were completely absorbed. We did not observe recurrence at 6 and 53 months follow-up (mean follow-up, 19.4 $\pm$ 12.4 months). The use of topical fluorescein application was accurate in diagnosing CSF rhinorrhea preoperatively and locating the CSF fistula intraoperatively. Although it was sensitive, we could not identify a second lesion in the case with both sphenoid and cribriform plate defects because we did not suspect the second defect for this case. Also, the postoperative control topical fluorescence test was positive for this case. All CSF leaks were successfully repaired by endoscopic endonasal surgery with a nasoseptal flap.

DISCUSSION

CSF leakage can lead to life-threatening intracranial complications. They have a high morbidity risk. It is reported that cases with post-traumatic CSF rhinorrhea may have a higher risk for meningitis.[1,11] In our cases, the frequency of meningitis was in 11/24 cases (45.8%), and four of them (36.4%) had recurrent meningitis before being admitted to our clinic. Seven out of 11 cases (63.6%) had traumatic CSF leakage, and all recurrent cases (100%) had traumatic CSF leakage. Our results supported the belief that there may be a high risk for meningitis for the patient with traumatic CSF leakage. To prevent these potentially lethal complications, early diagnosis of CSF leakage is mandatory. Patients with CSF leakage have silent symptoms. They may suffer from generally unilateral sweet or salty taste rhinorrhea, nasal obstruction, or meningitis.[1,9] Sometimes the patients are admitted to clinics several times and are prescribed allergic rhinitis drugs. This rhinorrhea may increase when leaning forward as in Muslim prayer. Chronic CSF leakage may cause a low-pressure headache. It is essential to demonstrate the presence of a CSF fistula and to localize the precise bone and dural defect for the cases with a suspected CSF leak. For this purpose, a combination of high-resolution CT scan, MRI, CT cisternography, MR cisternography, scintigraphy, intrathecal fluorescein, and clinical tests including β-2 transferrin or sugar and protein analysis are done.[1,11] We used a combination of the current techniques for our cases including β-2 transferrin or sugar and protein analysis, a high-resolution CT scan, MRI and/or MR cisternography, and topical fluorescein 10%. Preoperatively, we identified all dural defects with 100% accuracy by using this combination.

Numerous doses of intrathecal fluorescein have been widely used for detection and localization of CSF leakage, although fluorescein is licensed for eye angiography.[6] Several contemporary publications have supported low-dose ($\leq$50 mg) intrathecal fluorescein safety.[6] On the other hand, adverse reactions to intrathecal administration of fluorescein were reported including epileptic crisis, opisthotonos, peripheral nerve palsy, lower extremity weakness, allergic reactions, hemiparesis, dysphasia, and even death.[4–6,12] Injection of fluorescein into the intrathecal region is not comfortable for patients. Recently, Jones et al.[7] proposed that topical administration of fluorescein led to accurate identification of the site of the CSF leakage in their three cases. In addition to this report, there are only two published articles in the current English literature. Jones et al.[7] preferred to use fluorescein 10%, whereas Saafan et al.[8] and Liu et al.[9] preferred to use fluorescein 5%. In the present study, the use of topical application fluorescein 10% was very helpful in diagnosing CSF rhinorrhea preoperatively and locating the CSF fistula intraoperatively. Saline irrigation, mucus, or bleeding may cause false positive results. The surgical field should be kept dry before application of topical fluorescein. Although it was sensitive, we could not identify a second lesion in the case with both sphenoid and cribriform plate defects because we did not suspect the second defect. Postoperative control of the topical fluorescence test was positive for this case. This test assisted us both in qualitatively confirming the presence of a leak and carefully localizing the leak. Topical application of the fluorescence may be an easier and less expensive way than intrathecal fluorescein application. Fluorescein is available in 10% solution in a 5-mL box. We did not dilute it to 5% because the Jones et al.[7] study used it at 10%. It may be an advantage to use it under aseptic conditions. On the other hand, there is no study comparing topical application of fluorescein 10% and 5%. We did not see any adverse reaction with fluorescein 10%, but fluorescein 5% may also be selected. It may be a useful screening tool in the postoperative follow-up period.

Currently, endoscopic endonasal surgery is the most popular and successful technique for repair of CSF leakages.[1–11] In the present study, endoscopic endonasal surgery was successful in closing the CSF fistula defect in all cases. In the literature, various materials have been used for closure of CSF leakage such as fat, fascia lata, bone, cartilage, muscle, middle turbinate, bone wax, bovine or equine pericardium, silicone, titanium mesh, and polylactic acid.[2,13] It is obvious that there is a dural, bone, and mucosal defect when CSF leakage occurs. We are of the opinion that during reconstruction of the CSF leakage we should repair each layer of the skull base. Therefore, we used collagen matrix or fascia lata (to fix the dural defect), septal cartilage graft (to fix the bone defect), and a nasoseptal flap (to fix the mucosal defect). The Hadad-Bassagasteguy nasoseptal flap has been popular in the reconstruction of skull base defects since it was first described.[10] It is a versatile and reliable reconstructive technique for anterior, middle, clival, and parasellar skull

base dural defects.[5] In our series, the two cases with a defect of the sphenoid sinus were initially repaired by obliterating the sphenoid sinus with an abdominal fat graft, which showed recurrence after 1 and 2 years, respectively. During the surgery of these two cases, there was no fat graft in the sinus because the fat had been completely absorbed. We did not see any recurrence after the multilayer closure technique. A vascularized flap may be more reliable then grafting techniques.

CONCLUSION

Immediate surgical closure of traumatic CSF leakage cases is recommended because they may pose higher risk of meningitis than cases with spontaneous CSF leakage. Topical application of fluorescein is highly specific and sensitive in identifying preoperative, intraoperative, and postoperative CSF leakage. It is a simple, quick, and sensitive technique. The surgeon should be vigilant for multiple defects. Multilayer closure of CSF leakage is recommended to prevent recurrence of the CSF leak.

BIBLIOGRAPHY

1. Kerr JT, Chu FW, Bayles SW. Cerebrospinal fluid rhinorrhea: diagnosis and management. *Otolaryngol Clin N Am* 2005;38:597–611.
2. Schmerber S, Righini C, Lavielle JP, Passagia JG, Reyt E. Endonasal endoscopic closure of cerebrospinal fluid rhinorrhea. *Skull Base* 2001;11: 47–58.
3. Lopatin AS, Kapitanov DN, Potapov AA. Endonasal endoscopic repair of spontaneous cerebrospinal fluid leaks. *Arch Otolaryngol Head Neck Surg* 2003;129:859–863.
4. Bateman N, Mason J, Jones NS. Use of fluorescein for detecting cerebrospinal fluid rhinorrhoea: a safe technique for intrathecal injection. *ORL J Otorhinolaryngol Relat Spec* 1999;61:131–132.
5. Tosun F, Carrau RL, Snyderman CH, Kassam A, Celin S, Schaitkin B. Endonasal endoscopic repair of cerebrospinal fluid leaks of the sphenoid sinus. *Arch Otolaryngol Head Neck Surg* 2003;129:576–580.
6. Keerl R, Weber RK, Draf W, Wienke A, Schaefer SD. Use of sodium fluorescein solution for detection of cerebrospinal fluid fistulas: an analysis of 420 administrations and reported complications in Europe and the United States. *Laryngoscope* 2004;114:266–272.
7. Jones ME, Reino T, Gnoy A, Guillory S, Wackym P, Lawson W. Identification of intranasal cerebrospinal fluid leaks by topical application with fluorescein dye. *Am J Rhinol* 2000;14:93–96.
8. Saafan ME, Ragab SM, Albirmawy OA. Topical intranasal fluorescein: the missing partner in algorithms of cerebrospinal fluid fistula detection. *Laryngoscope* 2006;116:1158–1161.
9. Liu HS, Chen YT, Wang D, et al. The use of topical intranasal fluorescein in endoscopic endonasal repair of cerebrospinal fluid rhinorrhea. *Surg Neurol* 2009;72:341–346.
10. Hadad G, Bassagasteguy L, Carrau RL, et al. A novel reconstructive technique after endoscopic expanded endonasal approaches: vascular pedicle nasoseptal flap. *Laryngoscope* 2006;116:1882–1886.
11. Rice DH. Cerebrospinal fluid rhinorrhea: diagnosis and treatment. *Curr Opin Otolaryngol Head Neck Surg* 2003;11:19–22.
12. Anari S, Waldron M, Carrie S. Delayed absence seizure: a complication of intrathecalfluorescein injection. A case report and literature review. *Auris Nasus Larynx* 2007;34:515–518.
13. Ismail AS, Costantino PD, Sen C. Transnasal transsphenoidal endoscopic repair of CSF leakage using multilayer acellular dermis. *Skull Base* 2007; 17:125–132.