The Evolution of Retinal Surgery

A Personal Story

Harvey Lincoff, MD

I would like to thank The Retinal Research Foundation, The Schepens International Society, and Alice McPherson for establishing this lecture to honor Charles Schepens and for inviting me to be the first lecturer.

I met Charles Schepens (**Figure 1**) in 1955 when I was sent to the Howe Laboratory in Boston for a Heed fellowship with David Cogan. Dr Schepens had emigrated to the United States and to the Howe Laboratory from London 8 years before. Just before I left for Boston, Edward Norton, a friend at the New York Hospital, advised me to look in on Dr Schepens while in Boston. Charles Schepens' reputation for treating and curing retinal detachments had reached

See also page 921

New York, and there was disbelief. A leading retinal surgeon in New York—there were 2—referred to him as Boston Charlie, a takeoff on Boston Blackie, a fictional gangster in the movies. Retinal detachment was a neglected disorder at Bellevue Hospital where I trained, as well as elsewhere in the United States. At Bellevue it was assigned to a junior resident for repair. We knew there was supposed to be a retinal break, but as the breaks tended to be in the periphery and we only used direct ophthalmoscopy, we rarely found them. The routine was prolonged bed rest with binocular occlusion and then the application of perforating diathermy to the posterior edge of the detachment and drainage of subretinal fluid, followed by more binocular occlusion and bed rest. Twenty-five days in the hospital for a retinal detachment was not uncommon.

In Boston, when I wasn't working with Dr Cogan in the Howe Laboratory, I would slip downstairs to the retinal clinic to watch Drs Schepens, Okamura, and Brockhurst, using indirect ophthalmoscopy through a binocular scope (**Figure 2**) that Drs Schepens and Pomerantzev had developed, draw the fundus and retinal detachment to the ora serrata and find the retinal breaks.[1,2] The drawings were in a color code (**Figure 3**): red for attached retina and arteries, blue for detached retina and veins, green for opacities in the media, and yellow for exudate. The scallop at the border indicated that you had seen the ora seratta; if a segment was missing, you looked for it at the operating table with more scleral depression. Retinal detachment was operated upon under general anesthesia. The drawings were taken to the operating room and hung adjacent to the table for reference of the meridian and anterior posterior position of the retinal break.



Figure 1. Photograph of Charles Schepens, 1955.

Author Affiliations: The New York Presbyterian Hospital-Weill Cornell Medical Center, New York, New York.

Downloaded from www.archophthalmol.com at COLEGIO BRASILEIRO CIRURGIOES, on August 20, 2009
©2009 American Medical Association. All rights reserved.



Figure 2. Schepens binocular ophthalmoscope.

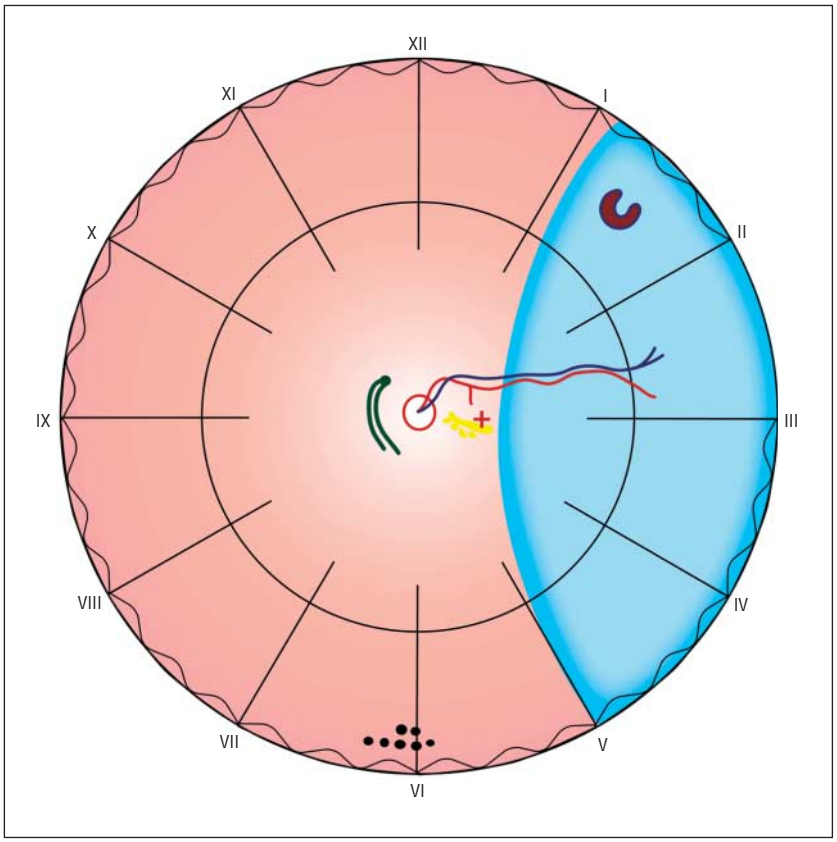

Figure 3. Retinal drawing in color code.

I can remember standing behind Dr Schepens at the operating table and peering over his shoulder as he localized and marked the posterior edge of a break. Then he made a lamellar dissection centered on the mark, applied multiple rows of diathermy posterior to the break, and inserted a section of polyethylene tube to create a buckle to augment the diathermy barrier that was intended to prevent a leak from the retinal break detaching the posterior retina (**Figure 4**).[3] It succeeded in most eyes with small breaks that were supported by the buckle (**Figure 5**A). In the presence of a larger break, however, the anterior end of the break would leak anteriorly and redetach the retina (Figure 5B). To counter this, Dr Schepens extended the buckle to 180° and made several radial lines of coagulation to the ora (**Figure 6**A). Still, in a number of eyes the anterior leak would circumvent the extent of the buckle (Figure 6B). The solution was a 360° buckle; the encircling buckle was a pragmatic solution to the anterior leak (**Figure 7**).[4] Eventually, it became apparent that we should buckle the anterior end of the break as well as the posterior end, and for this purpose numerous silicone forms (**Figure 8**) were developed to buckle completely breaks of all sizes and shapes. Encirclement was no longer needed, but it was so embedded in our technique that it was retained. Dr Schepens maintained that it served to counter future vitreous traction. It also preserved the barrier concept for any undiscovered breaks in the periphery. To this day, it remains a common addition to most procedures for retinal detachment.

I returned to Bellevue with a binocular indirect scope—it was 1 of 3 in New York—and I taught the residents to use it. Dr Devoe, an erudite chairman and cataract surgeon, viewed our drawings to the ora with skepticism. I went back to Boston periodically in the first years to confer with the expanding retina group, which added Regan and McMeel, and then Freeman, Pruett, Tolentino, Hirose, and Trempe. The Schepens Retina Associates and the Eye Research Institute acquired a national reputation for excellence in attaching the retina.

In 1957 I moved to The New York Hospital to fill Norton's place when he moved to Florida. Under Norton the Retina Service at the New York Hospital had been expanding; this was abruptly brought to my attention when a senior cataract surgeon complained to administration that the Retinal Service was preempting too many beds. Cataract surgery in the '50s was an inpatient procedure. In

Downloaded from www.archophthalmol.com at COLEGIO BRASILEIRO CIRURGIOES, on August 20, 2009
©2009 American Medical Association. All rights reserved.

response we reduced preoperative binocular occlusion and bed rest to 1 day and postoperative occlusion to 3 days. More recently, with recognition of the positive effect of ambulatory binocular occlusion, we reduce bed occupancy and meet Medicare and the insurance industry's requirement by admitting on the day of surgery after 1 or 2 days of ambulatory binocular occlusion at the patient's home.[5] The patient can peek momentarily from the unaffected eye for toilet and to get in and out of the car on his return to the office. Ambulatory occlusion induces regression of a detachment and will promote settling of acute vitreous hemorrhage. The critical factor appears to be the cessation of gaze movement. Body or head position do not seem to matter.

In 1958 I was sent to Bonn, Germany, to evaluate the photocoagulator that Meyer-Schwickerath had developed.[6] As I was leaving, Edward Norton asked me to look in on "this fellow Custodis," who had said at one of the first Retina Society meetings at Ipswich [Massachusetts] the previous year that he does not drain subretinal fluid.[7] In Bonn I made a positive assessment of the photocoagulator, and after a week I took a train 60 km north to Duesseldorf and arrived in time to see Ernst Custodis, using monocular indirect ophthalmoscopy, localize a retinal break in a bullous retinal detachment, sew a large red rubbery explant (polyviol) over the break with a single mattress suture, and not drain subretinal fluid. The operation took less than an hour; our operation with scleral dissection and encirclement took 2 to 3 hours. I examined Custodis' patient the next morning and found the retina attached. Not only was the retina attached but the vitreous crystal clear. After a scleral resection, silicone implant, encirclement, and drainage, we were accustomed to a cloudy vitreous for a number of days. I stayed in Duesseldorf for a week to watch Custodis, to make sure I had not witnessed a fluke, then flew back to New York with a pocket full of polyviol explants, began doing the procedure with equal results, and wrote about it in the *Archives*.[8] Before long I was invited to share a platform with Dr Schepens to describe the nondrainage procedure. Dr Schepens' comment was, "Not draining subretinal fluid is all right for New York doctors because New York doctors never sleep."

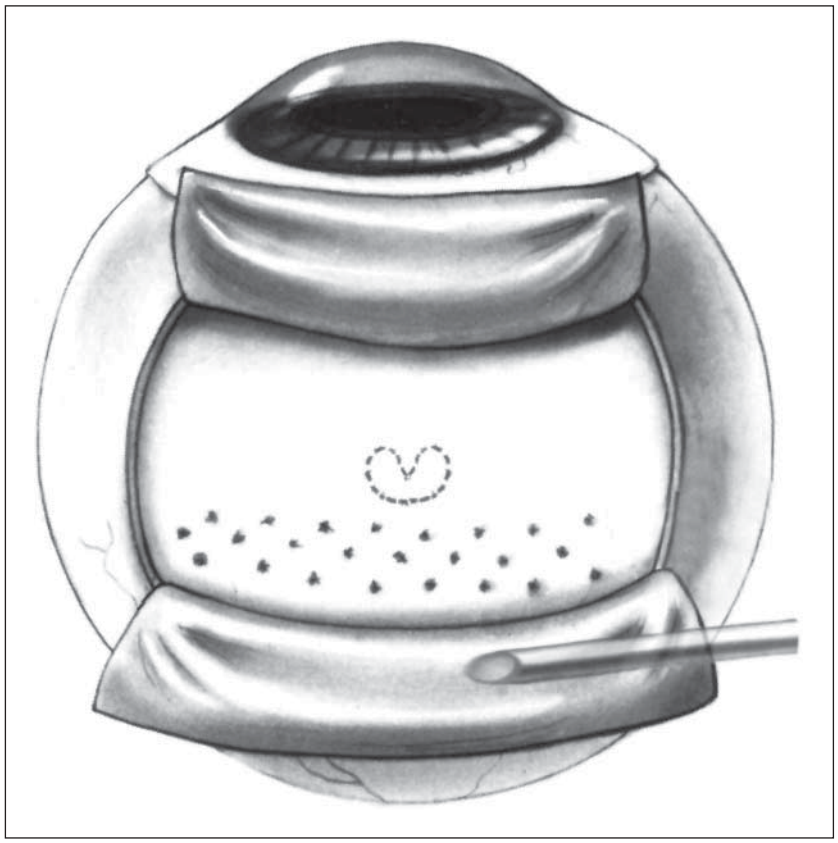

Figure 4. Scleral buckle with diathermy and polyethylene tube.

The polyviol explant operation was short-lived. In the next year Dr Schepens and the Retina Associates published a report of 25 operations using polyviol and described 7 infections, 4 of which were scleral abscesses and 1 of which perforated and required evisceration. The publication precluded further use of polyviol in the United States. Unwilling to give up the procedure, I consulted with Dow Corning about making an explant with the elastic properties of polyviol, and they came up with silicone sponge.[9] At a subsequent meeting, Dr Schepens acknowledged the silicone sponge and said, "It is like a New York apartment house where every room is filled with staphylococci that are multiplying like mad."

I asked Dow Corning about making a closed-cell sponge and they did, and the sponge operation survived. In the first 40 sponge operations, however, I encountered a scleral abscess that recovered without serious consequence after removal of the sponge. We made a rabbit model of scleral abscess, and by elimination we learned that diathermy necrosis of the sclera was the critical component.[10] If we eliminated diathermy, abscess did not occur. We searched for an alternative to perforating diathermy. Surface diathermy caused superficial scleral necrosis. Then on a visit to my dermatologist I saw him applying a carbon dioxide pencil to an indolent skin lesion. He said he did it to incite an inflammatory response. I took a pencil to the laboratory, applied it to a rabbit eye, and observed a white lesion in the retina in response. Over the next week the lesion evolved with pigmentation, much like a diathermy lesion. On subsequent dissection, the retina appeared adherent, and microscopy revealed the sclera undamaged. We began using cryo applications made with a liquid nitrogen probe that John McLean devel-

Downloaded from www.archophthalmol.com at COLEGIO BRASILEIRO CIRURGIOES, on August 20, 2009
©2009 American Medical Association. All rights reserved.

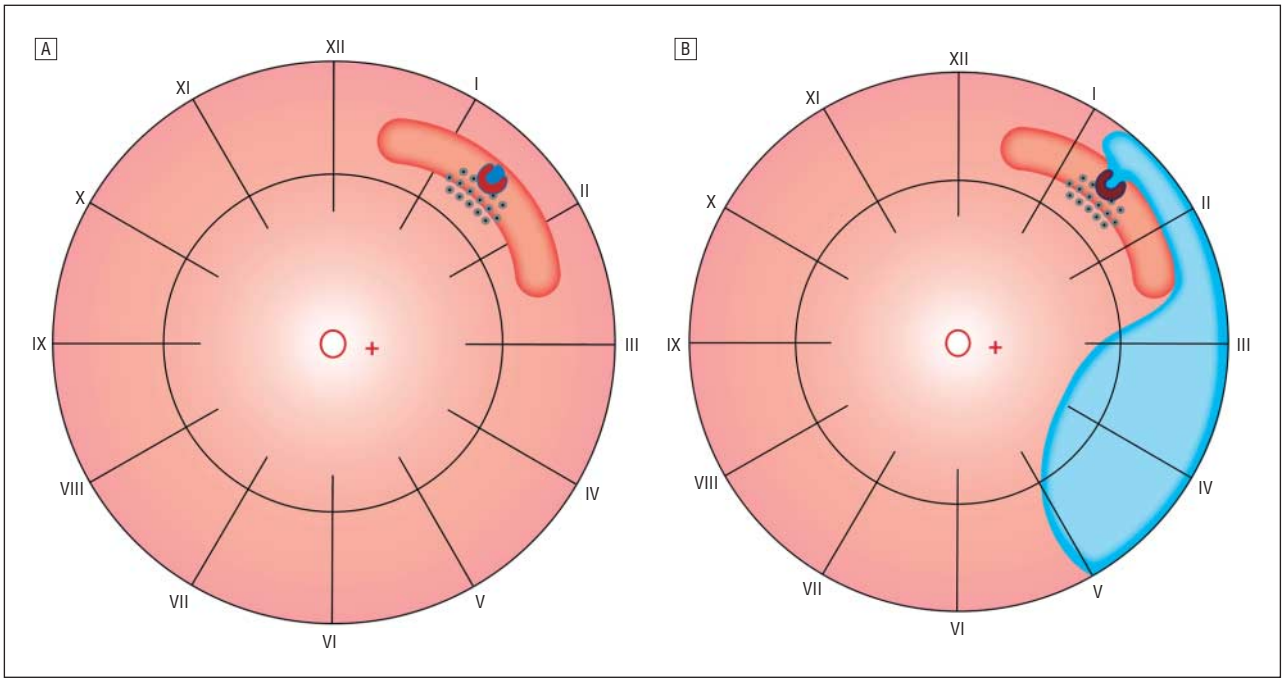

Figure 5. Quadrant buckle (A) leaking anteriorly (B).

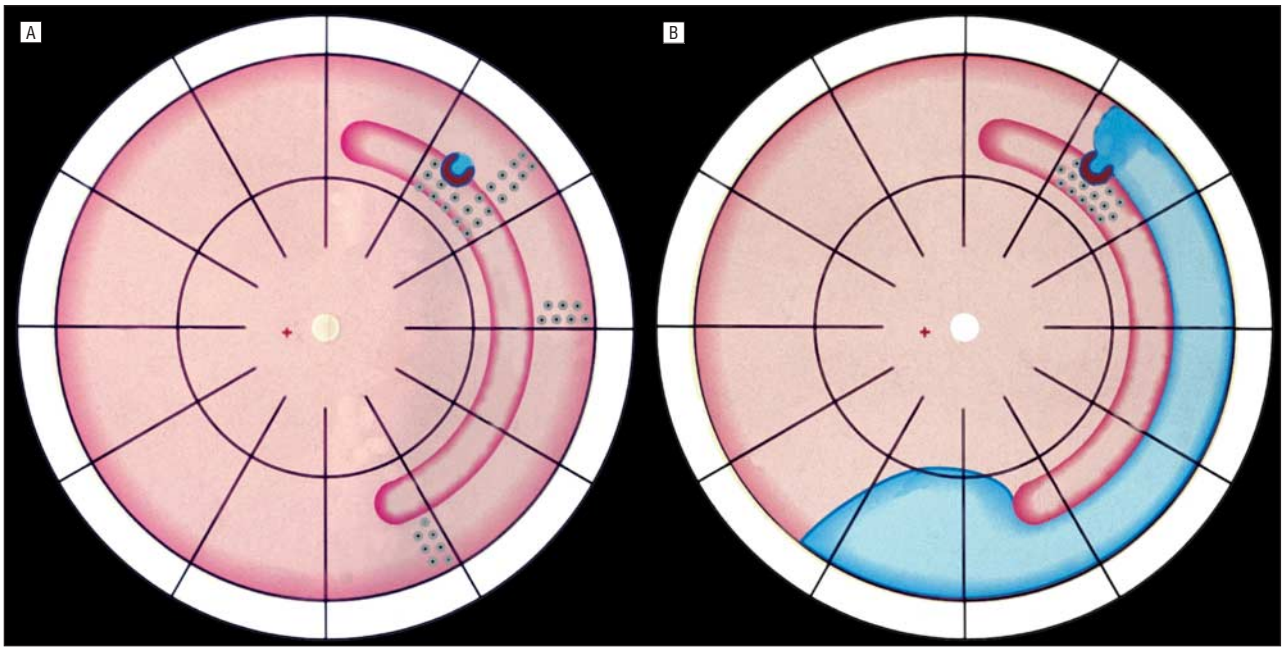

Figure 6. The 180° buckle (A) leaking anteriorly and inferiorly (B).

oped, on patients with retinal detachments, and in 1963 reported on the first 30 patients to the American Academy.[11]

At a subsequent meeting with Dr Schepens, we were introduced as Drs Hot and Cold. Dr Schepens acknowledged the value of cryo for transconjunctival use, but questioned whether the adhesion was as strong as that produced by diathermy and whether the dispersion of pigment that excessive freezing might produce would prove to be prohibitory. That was an astute observation and led to more temperate applications of cryo. Medical Instruments Research Associates of Boston subsequently developed a carbon dioxide instrument that yielded a more moderate freeze.

My last encounter with Dr Schepens occurred at a Retina Society meeting a few years ago. It was after the sessions that day that Ingrid Kreissig and I appeared on a porch where dinner was being served. Dr Schepens and his wife were already seated at a table and Dr Schepens beckoned for us to join them, and we did. We talked about the meeting and the papers. I had drunk a glass of wine when I said to Dr Schepens, "I always hoped that one day you would ask me to join you and the Retina Associates in Boston." Ingrid flushed with em-

Downloaded from www.archophthalmol.com at COLEGIO BRASILEIRO CIRURGIOES, on August 20, 2009
©2009 American Medical Association. All rights reserved.

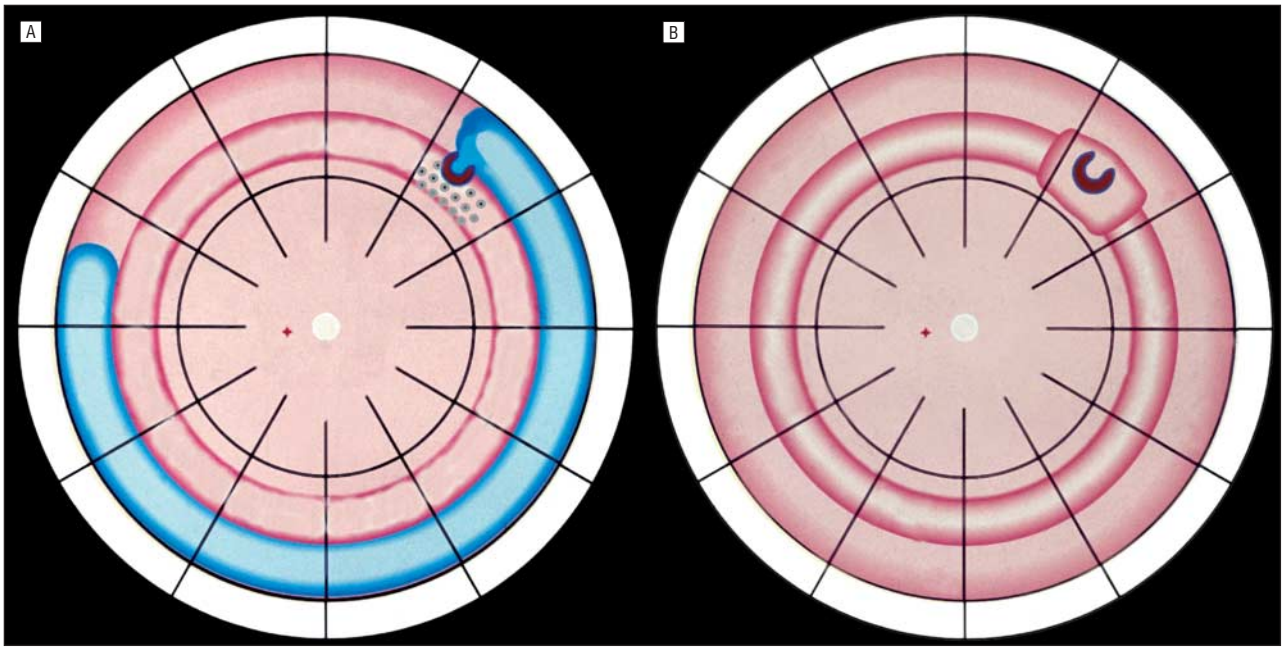

Figure 7. Encircling buckle confining an anterior leak (A) and augmented by a local buckle (B).

barrassment, there was a perceptible pause, then Dr Schepens replied, "You should have told me."

On a final note, one evening 40 years ago as I was about to sit down for dinner, Edward Norton called and said in a voice shaking with excitement, "We have just split the atom"; Robert Machemer had done the first pars plana vitrectomy.[12]

Vitrectomy has progressed to where it replaces scleral buckling for retinal detachment on some retinal services. Most vitrectomy procedures include an encircling band, presumably, as Dr Schepens said, to counteract future vitreous contraction and as a barrier for unperceived breaks in the periphery. More recently we have demonstrated that the encircling band diminishes the volume of the ocular pulse by 40%, and it is recommended that the band be cut after 6 months to restore volume.[13]

I want to thank Alice McPherson again for proposing this lecture to honor Charles Schepens, whose binocular ophthalmoscope and meticulous preoperative study and operative technique enabled us to find the breaks in the periphery of a retinal detachment to buckle them and attach the retina. As a result, blindness from retinal detachment that was frequent before the emergence of Jules Gonin in 1929 has become rare since the emergence of Charles Schepens in 1950.



Figure 8. Numerous silicone forms of various size and shapes.

Submitted for Publication: December 4, 2008; final revision received December 4, 2008; accepted December 5, 2008.

Correspondence: Harvey Lincoff, MD, The NY Presbyterian Hospital-Weill Cornell Medical Center, 1305 York Ave, Ste Y1114, New York, NY 10021 (mcaulfie@med.cornell.edu).

Financial Disclosure: None reported.

Downloaded from www.archophthalmol.com at COLEGIO BRASILEIRO CIRURGIOES, on August 20, 2009
©2009 American Medical Association. All rights reserved.

Additional Contributions: We gratefully acknowledge the assistance of Dominik Uram, MD, and MarieElena Caulfield.

REFERENCES

1. Schepens CL. A new ophthalmoscope demonstration. *Trans Am Acad Ophthalmol Otolaryngol*. 1947;51:298-301.
2. Schepens CL, Bahn GC. Examination of the ora serrata: its importance in retinal detachment. *AMA Arch Opthalmol*. 1950;44:677-690.
3. Schepens CL, Okamura ID, Brockhurst RJ, Regan CD. Scleral buckling procedures V: synthetic sutures and silicone implants. *Arch Ophthalmol*. 1960;64:868-881.
4. Schepens CL. Symposium: present status of retinal detachment surgery: scleral buckling with circling element. *Trans Am Acad Ophthalmol Otolaryngol*. 1964;68:959-979.
5. Lincoff H, Stopa M, Kreissig I. Ambulatory binocular occlusion. *Retina*. 2004;24(2):246-253.
6. Meyer-Schwickerath G. Lichtcoagulation: Buch. *Augenarzt Klin Monatsbl Augenheilkd*. 1959; 33:1-96.
7. Custodis E. Bedeutet die Plombenaufnahung auf die Sclera. *Ber Deutsch Ophth Ges*. 1953;58: 102.
8. Lincoff HA, Baras J, McLean J. Modifications to the Custodis procedure for retinal detachment. *Arch Ophthalmol*. 1965;73:160-163.
9. Lincoff H, McLean JM. Modifications to the Custodis procedure II: a new silicone implant for large tears. *Am J Ophthalmol*. 1967;64(5):877-879.
10. Langston R, Lincoff HA, McLean JM. Scleral abscess II: the experimental production in animals. *Arch Ophthalmol*. 1965;74(5):665-668.
11. Lincoff HA, McLean JM. Cryosurgical treatment of retinal detachment II. *Trans Am Acad Ophthalmol Otolaryngol*. 1966;70(2):202-211.
12. Machemer R, Norton EW. A new concept for vitreous surgery 3: indications and results. *Am J Ophthalmol*. 1972;74(6):1034-1056.
13. Lincoff H, Stopa M, Kreissig I, et al. Cutting the encircling band. *Retina*. 2006;26(6):650-654.

Archives *Web Quiz Winner*

Congratulations to the winner of our February quiz, Andrew J. Barkmeier, MD, Vitreoretinal Fellow, Cullen Eye Institute, Baylor College of Medicine, Houston, Texas. The correct answer to our February challenge was sarcoid retinal vasculitis. For a complete discussion of this case, see the Ophthalmic Images section in the March *Archives* (Hood CT, Lowder CY. Sarcoid retinal vasculitis. *Arch Ophthalmol*. 2009;127[3]: 269).

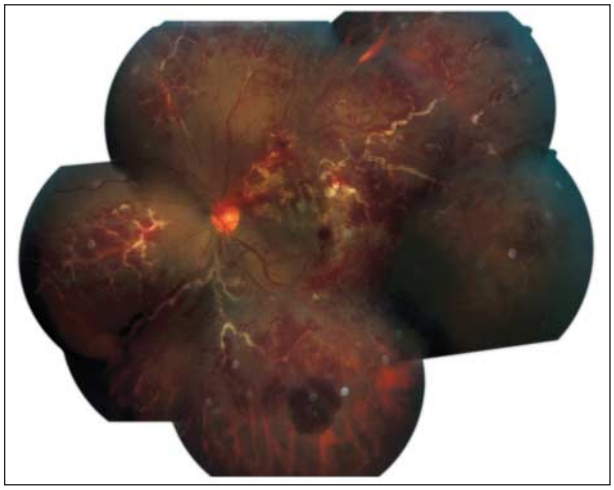

Be sure to visit the *Archives of Ophthalmology* Web site (http://www.archophthalmol.com) and try your hand at our Clinical Challenge Interactive Quiz. We invite visitors to make a diagnosis based on selected information from a case report or other feature scheduled to be published in the following month's print edition of the *Archives*. The first visitor to e-mail our Web editors with the correct answer will be recognized in the print journal and on our Web site and will also be able to choose one of the following books published by AMA Press: *Clinical Eye Atlas, Clinical Retina*, or *Users' Guides to the Medical Literature*.

Downloaded from www.archophthalmol.com at COLEGIO BRASILEIRO CIRURGIOES, on August 20, 2009
©2009 American Medical Association. All rights reserved.