Vascular and Endovascular Surgery
46(6) 480-483
© The Author(s) 2012
Reprints and permission:
sagepub.com/journalsPermissions.nav
DOI: 10.1177/1538574412449908
http://ves.sagepub.com



# Transcatheter Embolization of Extensive Left Gastric Artery Collaterals Presenting With Massive Upper Gastrointestinal Bleed

**Souheil Saddekni, MD, FSIR, FAHA[1], Ahmed Kamel Abdel-Aal, MD, MSc, PhD[1], Rachel F. Oser, MD[1], Edgar Underwood, MD[1], and Asim Bag, MD[1]**

**Abstract**

We report a case of extensive left gastric artery collaterals that were formed in the region of gastric fundus due to splenic artery occlusion and resulted in massive hematemesis. These collaterals were thought to be portosystemic collaterals related to portal hypertension during upper endoscopy study and single-phase venous computed tomography studies. The collaterals were treated by transcatheter endovascular coil embolization. Our case highlights the importance of recognizing and differentiating left gastric artery collaterals from gastric venous varices as a cause of hematemesis since the treatment approach for each condition is totally different. It also introduces the feasibility of percutaneous left gastric artery embolization as a treatment for this condition, without the need for surgical splenectomy and partial gastrectomy which have a higher mortality and morbidity.

**Keywords**

embolization, gastric, collaterals, venous, varices

## Introduction

We present a case of massive upper gastrointestinal (GI) bleeding due to enlarged left gastric artery collaterals caused by splenic artery occlusion and had a similar appearance to gastric venous varices on upper endoscopy and single-phase venous computed tomography (CT). The collaterals were treated with percutaneous transcatheter embolization. It is of utmost importance not to misinterpret these findings and miss the diagnosis since the treatment approach for gastric arterial collaterals and gastric venous varices is totally different. Furthermore, it is important to offer a far less invasive treatment for arterial gastric collaterals, such as percutaneous transcatheter embolization, rather than invasive surgery which have higher mortality and morbidity.

## Case Report

We present a case of a 23-year-old white female who presented to the emergency room with recurrent massive acute hematemesis and black tarry stool. The patient had a history of biliary atresia that was treated with liver transplantation in an outside hospital, when the patient was 2 years old. Her immediate post-transplant course was complicated with portal vein thrombosis necessitating a splenorenal shunt and biliary hepaticojejunostomy (Kasai procedure).

Ten years ago, the patient presented to us with clinical symptoms of cholangitis. A percutaneous transhepatic cholangiogram was performed which revealed moderate intrahepatic ductal dilatation without evidence of obstruction at the hepaticojejunostomy anastomosis. At that time, she also had an episode of black tarry stools and anemia. Upper GI endoscopy was performed and revealed isolated gastric varices without any specific source of bleeding. She was managed conservatively with blood transfusion. An ultrasound examination was also performed and revealed chronic portal vein thrombosis and patent splenorenal shunt. Follow-up upper GI endoscopy 2 years later revealed gastric fundal varices and portal gastropathy with no active bleeding.

The patient had a more recent attack of acute severe hematemesis and black tarry stools and upper endoscopy was performed showing a clump of large vessels at the greater curvature of stomach with no active bleeding from these vessels. These were assumed to be gastric varices resulting from her known history of portal vein thrombosis. She was transfused and treated with octreotide drip until bleeding was controlled and she was discharged home.

[1] Department of Radiology, University of Alabama at Birmingham, Birmingham, AL, USA

**Corresponding Author:**
Ahmed Kamel Abdel-Aal, Department of Radiology, University of Alabama at Birmingham, 619 19th Street South, Birmingham, AL 35249, USA
Email: akamel@uabmc.edu

Downloaded from ves.sagepub.com at Ebsco Electronic Journals Service (EJS) on September 12, 2012

One week later, she presented again with acute severe hematemesis. Upper GI endoscopy revealed extensive large vessels throughout the fundus of the stomach, with a large overlying blood clot. There was active oozing around the clot. The clot could not be manipulated by the endoscope. She was treated with proton pump inhibitors, octreotide, and blood transfusion. Based on her clinical presentation, endoscopic findings and prior history of splenorenal shunt, a provisional diagnosis of occluded or stenotic splenorenal shunt was entertained. Therefore, a 3-phase CT scan of the abdomen was obtained and coronal reconstruction of the arterial and portovenous phase images was performed to demonstrate the splenorenal shunt. The CT showed absent splenic artery, enlarged left gastric artery, and numerous collateral vessels in the region of fundus of the stomach. These collateral vessels appeared to fill unexpectedly in the arterial phase from the left gastric artery and therefore were consistent with arterial collaterals reconstituting the splenic artery rather than gastric varices (Figure 1A and B). There was no active contrast extravasation to suggest active bleeding. The splenorenal shunt was patent, although there was a focal area of moderate stenosis near its anastomotic junction with the renal vein (Figure 2).

Based on the CT findings, the patient underwent venous and arterial catheterizations to confirm the CT findings, with an intention to treat the mildly stenotic focal area in the splenorenal shunt. Venous access was obtained through a right transfemoral approach and selective renal vein and splenorenal shunt catheterization was performed. This showed patent shunt with moderate narrowing near the renal vein anastomosis resulting in a pressure gradient of 4 mm Hg (Figure 3). Balloon angioplasty of the stenotic area using a 10-mm angioplasty balloon (Atlas, Bard Peripheral Vascular, Tempe, Arizona) was performed for therapeutic and diagnostic purposes (Figure 4). However, no significant change was noted in the angiographic appearance or pressure gradient following angioplasty.

Arterial access was then obtained through right transfemoral approach and selective catheterization of the celiac was artery was performed. Selective celiac arteriogram revealed nonvisualization of the splenic artery (due to previous surgery) with numerous large arterial collaterals arising from the left gastric artery and supplying the spleen through capsular branches and reconstituting the splenic artery near the hilum of the spleen (Figure 5). During the venous phase of the selective left gastric arteriogram, a large splenic vein was seen draining into the left renal vein representing the surgically created splenorenal shunt. The procedure was terminated at this point without further intervention to allow for discussion of the angiographic findings with the patient and the clinical team and propose embolization of the left gastric artery collaterals as a possible treatment for the patient's clinical condition.

The patient continued to have hematemesis for the next 48 hours requiring further blood transfusions. After discussing the possible risks and benefits of transcatheter embolization versus the more invasive alternative surgical options with the patient, she agreed to proceed with transcatheter embolization of the left gastric artery collaterals. The patient was brought to our angio suite again, and the left gastric artery was catheterized using a 5-F catheter (RC2, Cook, Bloomington, Indiana) placed through a 6-F guiding sheath (Balkan, Cook, Bloomington, Indiana) using a right transfemoral arterial access. Selective catheterization of the left gastric artery branches and arterial collaterals was performed using a 2.8-F microcatheter (Renegade HI-FLO, Boston Scientific, Cork, Ireland) through which embolization was accomplished using 3- to 2-mm platinum coils (Tornado, Cook, Bloomington, Indiana). The main trunk of the left gastric artery was not embolized; however, very little flow remained in the left gastric artery branches beyond the main trunk (Figure 6).

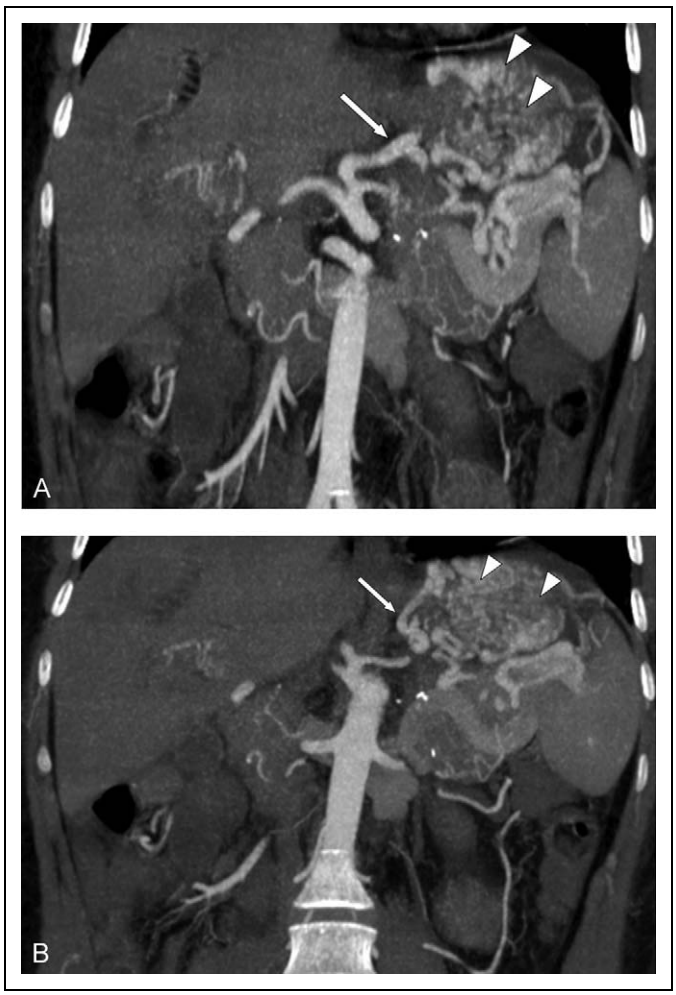


**Figure 1.** Coronal reformatted CT images in the arterial phase showing absent splenic artery with enlarged left gastric artery (arrow) and numerous left gastric artery collateral vessels in the region of fundus of the stomach (arrowheads) reconstituting the splenic artery. CT indicates computed tomography.

The patient's symptoms resolved on the day of the procedure. On the next day, she was stable and was transferred from the intensive care unit to the floor. She was discharged home 4 days after the procedure in a stable condition. On a follow-up upper GI endoscopy after 2 weeks, there was no evidence of active bleeding. She suffered no episodes of GI bleed up to 8 months after her embolization procedure.

Downloaded from ves.sagepub.com at Ebsco Electronic Journals Service (EJS) on September 12, 2012



**Figure 2.** Coronal reformatted CT images in the portovenous phase showing patent splenorenal shunt with a focal area of moderate stenosis near its anastomotic junction with the renal vein (arrow). CT indicates computed tomography.



**Figure 3.** Selective left renal vein and splenorenal shunt catheterization (arrow) showing patent shunt with moderate narrowing near the renal vein anastomosis (arrowheads).

## Discussion

Most commonly, the splenic artery arises from the celiac trunk. Rarely, it may arise from the superior mesenteric artery or even from the aorta in a common trunk with the left gastric artery. The splenic artery gives rise to short gastric arteries and pancreatic arteries with a variation of early branches to either pole of the spleen or to accessory splenule/splenules. If the splenic artery is occluded, extensive collaterals may develop from the

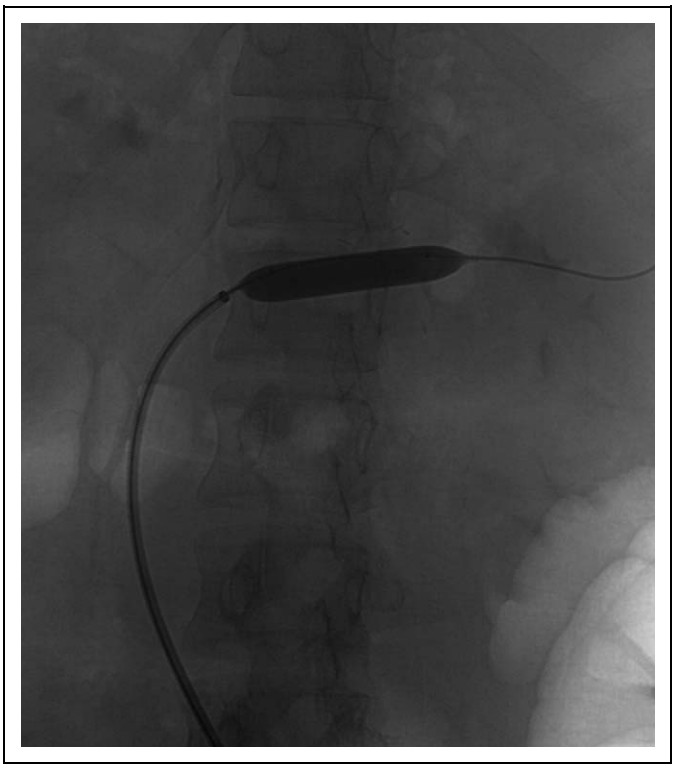

**Figure 4.** Balloon angioplasty of the stenosis at the splenorenal junction.

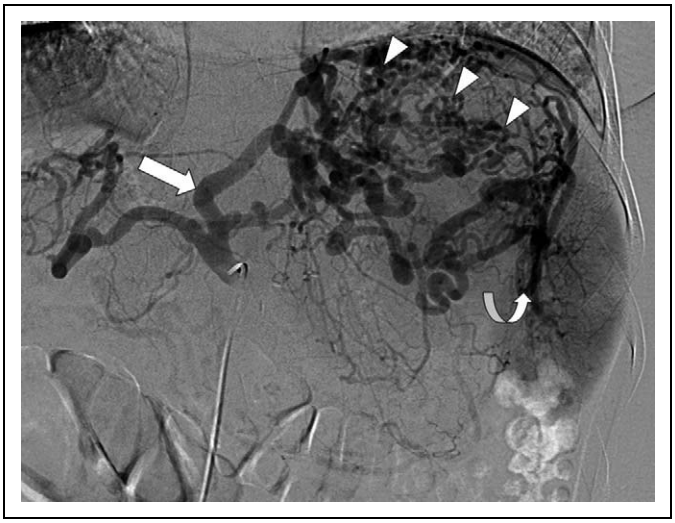

**Figure 5.** Celiac angiogram showing absent splenic artery (due to previous surgery) with enlarged left gastric artery (arrow) and numerous large arterial collaterals arising from the left gastric artery (arrowheads) and supplying the spleen through capsular branches and reconstituting the splenic artery near the hilum of the spleen (curved arrow).

Downloaded from ves.sagepub.com at Ebsco Electronic Journals Service (EJS) on September 12, 2012




**Figure 6.** Angiogram of the left gastric artery after embolization of the collaterals using 2- and 3-mm coils showing stasis of flow in the main artery.

pancreatic, left gastric, gastroepiploic, and short gastric arteries. Splenic artery occlusion may be congenital, idiopathic, or acquired due to a variety of conditions such as surgical ligation, trauma, extrinsic compression, and interventional embolization.[1-3]

There are only a few case reports of congenitally absent splenic artery with extensive splenic collaterals.[1,2] Usually, these collaterals arise from the left gastric and short gastric arteries and pass through the wall of the stomach. Surgical ligation of the splenic artery also causes development of collaterals usually from short gastric arteries.[4] Most of the reported cases of arterial collaterals that develop due to splenic artery occlusion or ligation were described in children or early adulthood.[1-5] There is one report of gastric hemorrhage as a late complication of splenic artery aneurysm repair in a 68-year-old patient that was due to gastric collateralls.[6] Therefore, we suggest that when splenic artery occlusion occurs early in life, more significant collaterals will develop from adjacent proximal patent arteries, such as the gastric arteries. Collateral supply may be clinically asymptomatic for a long time or may present with massive fatal hematemesis from erosion of submucosal arterial collaterals due to any cause.[1,2]

Surgical treatment options for this condition includes clamping of the splenic hilum with partial gasterctomy[1]; ligation of left gastric artery with splenectomy[2]; ligation of splenic artery, splenic vein, left, and short gastric arteries with splenectomy[5]; and partial gastric devascularization and splenectomy.[6]

Our patient had a history of liver transplant with splenorenal shunt, where the splenic artery has been clamped or ligated. This resulted in large arterial collaterals primarily from the left gastric artery reconstituting the splenic artery at the splenic hilum. Considering the patient's history of recurrent massive hematemesis, and after discussions with the patient and clinical team, we were successful in treating all the arterial collaterals with coil embolization. The nondilated left gastric artery proper was not embolized in an effort to preserve arterial supply to the stomach. Our approach was similar to the surgical ligation of the left gastric artery, but without the need to perform splenectomy or partial gastrectomy.

## Conclusion

This case offers 2 particularly instructive points. First, not all gastric varicosities seen on upper endoscopy are venous gastric varices. Enlarged arterial collaterals may have a similar appearance to gastric venous varices and can be misinterpreted on upper endoscopy and single venous phase CT. It is of utmost importance not to misinterpret the findings and miss the diagnosis, since the treatment approach for gastric arterial collaterals and gastric venous varices is totally different. Second, it is important to offer a far less invasive treatment to treat these arterial gastric varices, such as percutaneous transcatheter embolization, rather than invasive surgery that have higher mortality and morbidity.

### Declaration of Conflicting Interests

The author(s) declared no potential conflicts of interest with respect to the research, authorship, and/or publication of this article.

### Funding

The author(s) received no financial support for the research, authorship, and/or publication of this article.

### References

1. Spriggs DW. Congenital absence of the splenic artery. *Cardiovasc Intervent Radiol*. 1984;7:303-305.
2. Durrans D, Fawcitt RA, Taylor TV. Congenital absence of the splenic artery associated with major gastric bleeding in adolescence. *Br J Surg*. 1985;72(6):456-457.
3. Ozcan H, Yağmurlu B, Koral M. Asymptomatic splenic artery occlusion in a child: incidental detection with Doppler ultrasonography. *Diagn Interv Radiol*. 2006;12(2):68-69.
4. Keramidas DC, Kelekis D, Dolatzas T, Aivazoglou T, Voyatzis N. The collateral arterial network of the spleen following ligation of the splenic artery in traumatic rupture of the spleen; an arteriographic study. *Z Kinderchi*. 1984;39(1):50-51.
5. Baron PW, Sindram D, Suhocki P, Webb DD, Clavien PA. Upper gastrointestinal bleeding from gastric submucosal arterial collaterals secondary to splenic artery occlusion: treatment by splenectomy and partial gastric devascularization. *Am J Gastroenterol*. 2000;95(10):3003-3004.
6. Worthley DL, Rayner CK, Devitt PG, Fraser R. Gastric hemorrhage as a late complication of splenic artery aneurysm repair: a dramatic way to vent one's spleen. *J Gastroenterol Hepatol*. 2003;18(5):604-605.

Downloaded from ves.sagepub.com at Ebsco Electronic Journals Service (EJS) on September 12, 2012