Hepatic Trauma

Clay C. Cothren, Ernest E. Moore[1]

Abstract
Hepatic injuries are one of the most common abdominal injuries following either blunt or penetrating trauma. CT scanning has revolutionized the treatment algorithm for these patients. The majority of patients are successfully treated with nonoperative management, but surgeons should have a clear understanding of the indications for operative intervention. An array of techniques including operative, interventional, and endoscopic, are often required for management of advanced grade hepatic injuries.

Key Words
Abdominal · Abdominal Trauma

Eur J Trauma Emerg Surg 2008;34:339–54
DOI 10.1007/s00068-008-8029-5

Intoduction

The liver is the most commonly injured solid organ in blunt trauma, comprising 5% of all trauma admissions and due to its size is frequently involved in penetrating trauma. Historically, liver injuries have been associated with a substantial mortality. In the 1880s, a serious liver injury was uniformly fatal within 24 h [1]. By the early 1900s, improved management resulted in approximately 40% of blunt liver injuries proving fatal [2]. World War II brought advances in therapy including the implementation of early laparotomy; operative techniques advocated were parenchymal suturing of injuries and drainage to prevent complications [3]. As a result, mortality rates dropped to 30%. During the Vietnam War, aggressive hepatic resection was utilized for destructive injuries. These constructs were adapted by civilian trauma centers, and remained the primary management of liver injuries until the late 1980s.

Over the past 15 years, nonoperative management of liver injuries has evolved to become the dominant therapeutic strategy. Several concurrent changes resulted in this paradigm change. First was the realization that diagnostic peritoneal lavage (DPL) was sensitive but not specific for identifying intraperitoneal hemorrhage, necessitating operating management. Surgeons recognized that the majority of laparotomies undertaken for a positive DPL were associated with liver injuries that did not require intervention for bleeding [4]. The associated nontherapeutic laparotomy rate approached 60% in most series during this time. Trauma surgeons also noted that non-bleeding venous injuries, if manipulated, often resulted in major hemorrhage and sometimes death [5]. Therefore, surgeons queried whether venous injuries, which are low pressure-system injuries, would heal without intervention. At the same time, computed tomographic (CT) scanning was evolving as a reliable method for diagnosing and grading liver injuries.

Clinical Presentation

Hepatic injuries following blunt or penetrating trauma are suspected based upon the patient's physical examination including vital signs. Predominant mechanisms of blunt injury include motor vehicle collisions, auto–pedestrian accidents, crush injuries, and falls from any height. Following blunt trauma, the most commonly injured structures are the hepatic veins and the parenchyma. Blunt forces dissipate along segments of the liver and along the fibrous coverings of the portal triad structures; the hepatic veins, however, are not so insulated. Due to its size and location within the abdomen, the liver is also commonly involved in penetrating trauma. Stab wounds (SW) typically result in linear injuries while gunshot (GSW) or shotgun wounds result in significant cavitary injuries due to blast effect and the ''tumbling'' of the missile within the liver parenchyma.

[1]Department of Surgery, Denver Health Medical Center and the University of Colorado at Denver School of Medicine, Denver, CO, USA.

Received: February 21, 2008; revision accepted: April 9, 2008;
Published Online: July 25, 2008

The primary survey and assessment of the initial response to resuscitation of the trauma patient in the emergency department (ED), is the first step in management. During this phase, patients with hemodynamic instability and either a penetrating abdominal wound, or intraabdominal hemorrhage noted on focused abdominal sonography for trauma (FAST) exam should undergo laparotomy. Although a definitive diagnosis of a hepatic injury may not be evident, laparotomy should be undertaken (see ''Operative techniques''). If a patient has a penetrating weapon remaining in place, this should not be removed in the ED as it could be tamponading a lacerated blood vessel. The surgeon should extract the offending instrument in the controlled environment of the operating room, optimally after the incision has been made. For hemodynamically stable patients, further evaluation is warranted. Abdominal examination includes inspection for abdominal wall abrasions or ecchymosis, and assessing for rigidity, tenderness, or rebound. Drugs, alcohol, and head and spinal cord injuries may complicate clinical evaluation and, in such cases, diagnostic imaging assumes a greater role. Additionally, patients with a benign exam may have significant intraabdominal injury [6].

Although DPL was used routinely in the ED to evaluate abdominal trauma it has been virtually supplanted by FAST over the past decade. The advantage of FAST is that it is noninvasive, portable, rapid, and easily repeatable over the patient's ED course. Any of the three views of the abdomen – right and left upper quadrants, and pelvic views – can reveal intraabdominal fluid, which is presumed to be hemorrhage unless the patient has liver disease with ascites. Although this method is exquisitely sensitive for detecting intraperitoneal fluid greater than 400 ml, it does not reliably determine the source of hemorrhage or grade solid organ injuries [7, 8]. Patients with evidence of intraabdominal fluid should undergo CT scanning unless laparotomy is indicated. Occasionally, the first ultrasound views of the abdomen may be normal; repeating the ultrasound as a second snapshot in time is critical for patients at high risk for injury. FAST is not 100% sensitive [9]; therefore, diagnostic peritoneal aspiration (DPA) is warranted in hemodynamically unstable patients without a defined source of blood loss to rule out abdominal hemorrhage.

The diagnostic measures advocated above are those which can easily be performed in the trauma bay. Transport of a hypotensive patient out of the ED for computed tomographic (CT) scan evaluation is hazardous; monitoring is compromised and the environment is suboptimal to deal with acute problems; i.e. ''death begins in radiology''. The surgeon must accompany these patients and be prepared to abort the CT scan with direct transport to the OR. This dilemma is becoming less common in large urban trauma centers where CT scanning can be accomplished in the ED. On the other hand, CT scanning is very desirable in the hemodynamically stable patient at risk for liver injury since laparotomy may provoke hepatic bleeding. Additionally, isolated penetrating wounds to the right upper quadrant may be amenable to nonoperative management.

Imaging and Injury Grading

Since its initial use in the early 1980s, CT scanning has become a routine part of trauma evaluation. With multislice helical scanning, the entire torso can be scanned in under 5 min. Patients with fluid on FAST exam, considered a ''positive FAST'', who do not have immediate indications for laparotomy and are hemodynamically stable, undergo CT scan to quantify their injuries. Additionally, patients with persistent abdominal tenderness, significant abdominal wall trauma, distracting injuries, or altered mental status should undergo CT imaging (Figure 1). Although the majority of abdominal penetrating injuries that violate the peritoneum require laparotomy, the exception is penetrating trauma isolated to the right upper quadrant. In hemodynamically stable patients with the trajectory of penetrating trauma confined to the liver by CT scan, nonoperative observation may be considered [10, 11].

The American Association for the Surgery Trauma developed a grading scale to provide a uniform definition of liver injuries (Table 1) [7]. Solid organ injury grading permits effective transfer of information between treating physicians, and predicts failure rates and complication rates of nonoperative management. In addition to grading the liver injury, specific findings that should be noted on CT scan in patients include contrast extravasation (i.e., a ''blush''), the amount of intraabdominal hemorrhage, and the presence of pseudoaneurysms (Figure 2). Additionally, associated enteric injuries mandating laparotomy should be excluded.

Nonoperative Management

Indications for Nonoperative Management

Nonoperative management of blunt solid organ injuries is pursued in hemodynamically stable patients that do not have overt peritonitis or other indications for

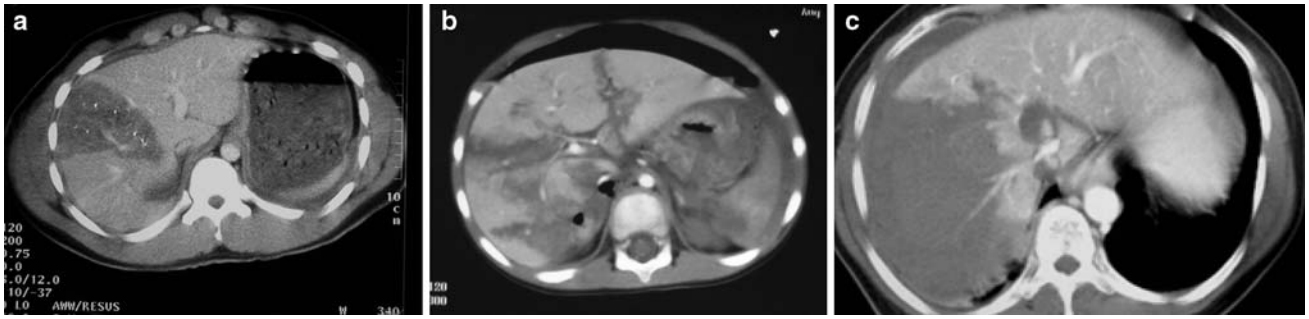

Figure 1. CT scan findings of high grade hepatic injuries. a) Grade III, b) Grade IV, c) Grade V.

Table 1. AAST grading scale for hepatic injuries.

Liver injury grade	Subcapsular hematoma	Laceration
Grade I	< 10% surface area	< 1 cm in depth
Grade II	10–50% surface area	1–3 cm
Grade III	> 50% or > 10 cm	> 3 cm
Grade IV	25–75% of a hepatic lobe	
Grade V	> 75% of a hepatic lobe	
Grade VI	Hepatic avulsion	

laparotomy. High-grade injuries, a large amount of hemoperitoneum, contrast extravasation, and pseudoaneurysms are not absolute contraindications for nonoperative management; however, these patients are at high risk for failure and are more likely to need angioembolization [12–16]. Likewise, there is not a patient age cutoff for the nonoperative management of solid organ injuries. In fact, in contrast to splenic trauma where age > 55 years is considered a relative indication for operative intervention, older patients are more likely to survive nonoperative management. A multidisciplinary approach including angiography with selective angioembolization (Figure 3) has resulted in decreased nonoperative failure rates and improved survival [5, 14, 15]. Patients with Grade ≥ III injuries should be admitted to the SICU with frequent monitoring of their hemodynamics, abdominal examination, and hemoglobin. The guideline for angioembolization to address ongoing hepatic bleeding is transfusion of 4 units of RBCs in 6 h or 6 units of RBCs in 24 h. Recurrent hemodynamic instability, however, often requires laparotomy with perihepatic packing for hemostasis. Patients who require laparotomy typically fail nonoperative management in the first 24–48 h [5, 12].

Although not universally embraced, selected patients with penetrating injuries to the right upper quadrant may be candidates for nonoperative management (Figure 4) [10, 11]. Patients must have a CT scan that documents confinement of the injury to the liver. Additionally, the patient must be hemodynamically stable, have a reliable physical examination without evidence of peritonitis (i.e. cannot have depressed mental status), and not require blood products. Patients should be admitted for serial examination and hemoglobin monitoring; any alteration should prompt laparotomy. An alternative approach is to perform laparoscopy to confirm trajectory of the missile or knife.

Results of Nonoperative Management

Over 80% of patients with liver injuries may be managed nonoperatively. A multidisciplinary approach including angiography and ERCP has resulted in decreased failure rates and improved survival. One of the early studies to test the application of nonoperative therapy in 1995 [12] supported its broad application with an overall success rate greater than 85% in hemodynamically stable patients, despite substantial hemoperitoneum documented by CT scanning. Of the 8% of patients that failed nonoperative management, half required operation due to associated injuries (i.e., enteric or pancreatic injuries) while half underwent laparotomy for hepatic-related hemorrhage. Perhaps not surprisingly, those patients who failed nonoperative therapy had increasing rates of failure associated with increasing grades of hepatic injury, with grade V injuries having a greater than 20% failure rate. Subsequent studies have reported failure rates of 14% in grade IV injuries and 23% in grade V injuries [13]. Similarly, the amount of hemoperitoneum appears to correlate with successful management; patients with a large amount of hemoperitoneum (i.e. blood extending into the pelvis) are more likely to fail nonoperative management. However, predicting which patients will ultimately require laparotomy has yet to be accomplished.

Patients with contrast extravasation identified on CT scanning, indicating arterial hemorrhage, should be

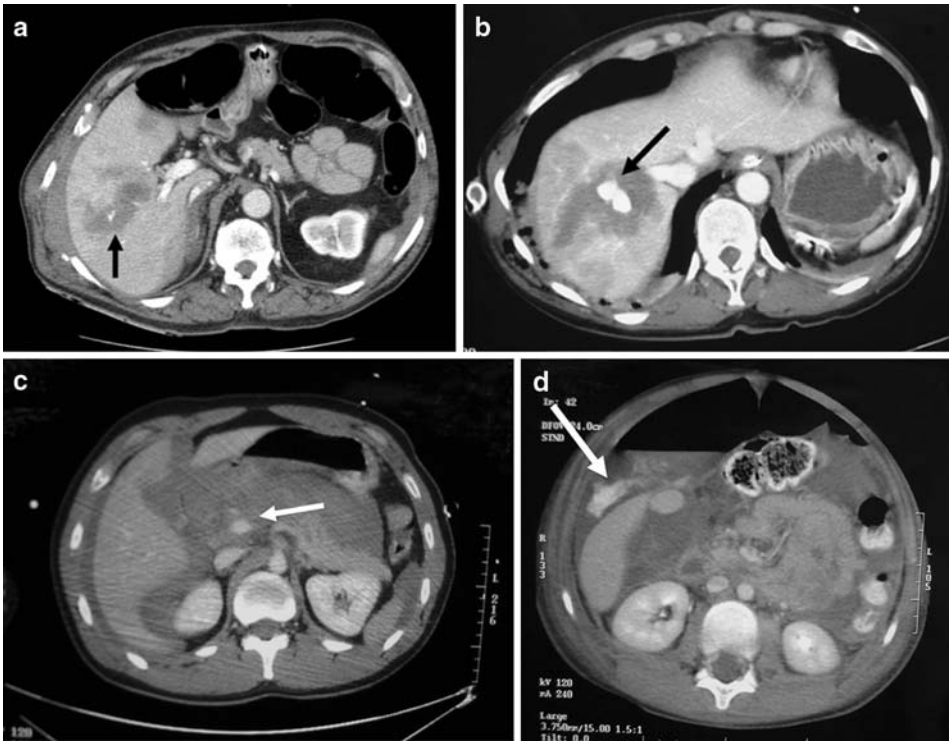

Figures 2a to 2d. Contrast extravasation, indicating arterial hemorrhage, can be a, b) intraparenchymal or c, d) intraperitoneal.

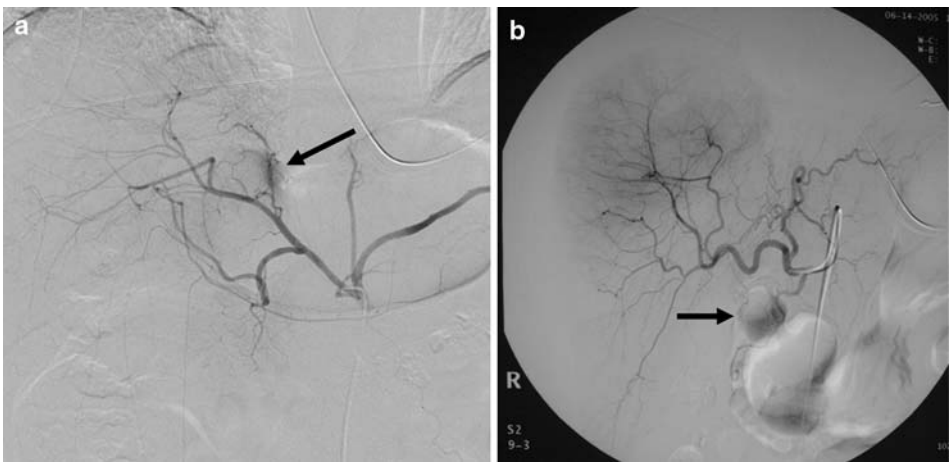

Figures 3a and 3b. Arterial injuries identified by angiography includes a) isolated extravasation into the hepatic parenchyma and b) fistulazation with the portal vein. Arterial embolization can be definitive treatment.

considered as a candidate for hepatic angiography. Originally, evidence of extravasation was an indication for laparotomy; however, the advent of endovascular techniques has resulted in effective hemostasis in selected cases. Angioembolization is particularly helpful in hemodynamically stable patients with contrast pooling within the hepatic parenchyma [14]. Patients with contrast extravasation into the peritoneal cavity are more likely to require laparotomy [15], but cases of successful embolization have been reported [16].

Several centers have reported successful nonoperative management of penetrating hepatic trauma [10, 11, 17, 18]. These studies carefully selected patients based upon the above criteria, and included patients with both SWs and GSWs. In addition to avoiding the morbidity of a laparotomy, the success of nonoperative therapy for penetrating trauma, has resulted in decreased hospital stays, lower transfusion requirements, and diminished abdominal infection rates.

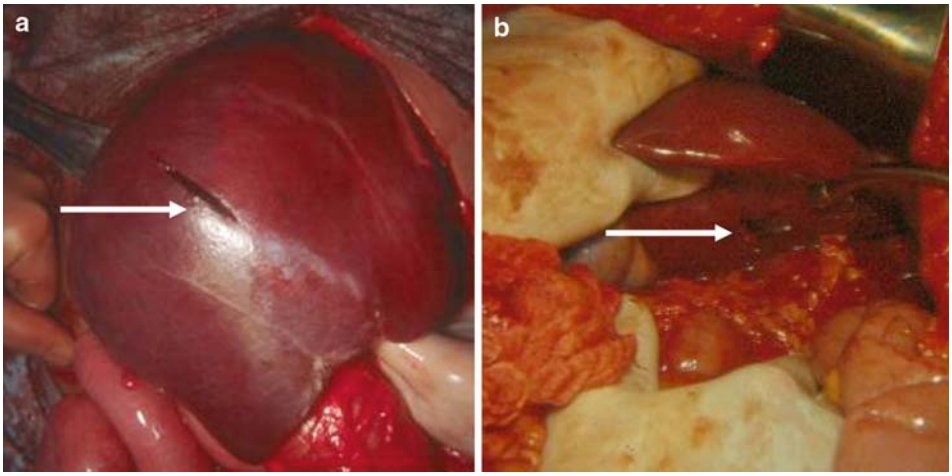

Figures 4a and 4b. Penetrating trauma isolated to the liver, such as these translobar a) stab wound and b) gunshot wounds, is often found to have stopped bleeding at the time of laparotomy; for this reason, in selected patients, nonoperative management is been suggested.

Follow-Up Imaging

Based upon the available literature, clear indications for repeat imaging in asymptomatic patients are lacking, although patients with grade ≥ IV injuries are at substantial risk of complications [19, 20]. Repeat imaging in patients with complex hepatic injuries should be performed with bedside ultrasound. Patients with evidence of right upper quadrant fluid collections or clinical deterioration (increasing abdominal pain, worsening liver function tests, unexplained fever) should undergo CT scanning to exclude a biloma, abscess, necrosis, or hemorrhage [19, 20]. In asymptomatic patients, the trend in several institutions has been to repeat CT scans in patients with all high-grade injuries, i.e., grade ≥ IV. The rationale is to exclude a delayed pseudoaneurysm, which may rupture, and to document healing which may be used to guide activity limitations. If post-discharge routine imaging is performed, it is typically done > 4 weeks after injury.

Operative Techniques

Exposure

The goal of laparotomy is to quantify the extent of hepatic injury and to promptly control hemorrhage. Access is gained through a generous midline laparotomy incision. The incision is faster with a scalpel compared to an electrosurgical unit; incisional abdominal wall bleeding should be ignored until intraabdominal sources of hemorrhage are controlled. Liquid and clotted blood is evacuated with multiple laparotomy pads and suction used to identify the area of active bleeding. Exposure of the right lobe of the liver can be improved by elevating the right costal margin with a large Richardson retractor.

The right lobe can be further mobilized by dividing the right triangular and coronary ligaments. Following division of the right triangular ligament, the dissection is continued medially, dividing the superior and inferior coronary ligaments. The right lobe can then be rotated medially into the surgical field (Figure 5). Mobilization of the left lobe is accomplished in a similar fashion. Care must be taken when dividing any of the coronary ligaments due to their proximity to the hepatic veins and retrohepatic vena cava. On occasion it may be necessary to extend the midline abdominal incision into the chest. This is best accomplished with a median sternotomy (Figure 6). The pericardium and diaphragm can be divided toward the center of the inferior vena cava. This combination of incisions provides exposure of the hepatic veins and retrohepatic vena cava while avoiding injury to the phrenic nerves.

Control of Hemorrhage

Initial control of hemorrhage is best accomplished using manual compression and perihepatic packing (Figure 7), which can be a life-saving maneuver. The addition of laparotomy pads on the surface of the liver distributes digital forces and lessens the chance of aggravating the injury. If the lacerated edges of the liver are carefully opposed and the proper forces applied, hemorrhage from almost any hepatic injury can be temporarily controlled. The drawback is that little else can be done while the liver is being compressed. Manual compression is best suited for immediate attempts to prevent exsanguination and for periodic control during a complex procedure.

Hemorrhage from major hepatic injuries can usually be controlled with effective peri-hepatic packing. The right costal margin is elevated, and the pads are

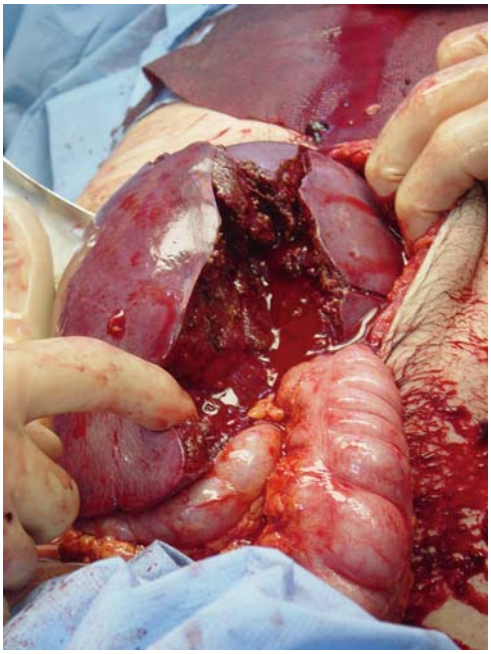

Figure 5. The right lobe of the liver can be rotated medially into the surgical field by dividing the right triangular and coronary ligaments.



Figure 6. Combining a median sternotomy with a midline laparotomy incision provides exposure to the hepatic veins and retrohepatic vena cava while avoiding injury to the phrenic nerves. The pericardium and diaphragm can be divided down the center toward the inferior vena cava.

strategically placed over and around the bleeding site. Additional pads should be placed between the liver, diaphragm, and anterior chest wall until the bleeding stops. Ten to fifteen pads may be required to control the hemorrhage from an extensive right lobar injury. Packing of injuries of the left lobe is not as effective since there is insufficient abdominal and thoracic wall anterior to the left lobe to provide adequate compression with the abdomen open. Fortunately, hemorrhage from the left lobe can usually be controlled by mobilizing the lobe and compressing it between the surgeon's hands. The surgeon should be aware that tight packing can compress the inferior vena cava and reduce cardiac filling; additionally, the right diaphragm will be forced cephalad with packing which increases airway pressures and decreases tidal volume and functional residual capacity. If the patient has persistent bleeding despite packing, injuries to the hepatic artery, portal vein and retrohepatic vena cava should be considered.

The Pringle maneuver [21], which is the occlusion of the portal triad using a vascular clamp, can help delineate the source of hemorrhage and provide temporary control (Figure 8). The authors prefer to manually tear the lesser omentum and place the clamp from the patient's left side while guiding the posterior blade of the clamp through the foramen of Winslow with the aid of the left index finger. The advantage of this approach is (1) it avoids injury to the hepatic pedicle structures, (2) it includes any aberrant or accessory hepatic arteries, and (3) the handle of the clamp sits over the stomach rather than the right lobe of the liver, hence providing better visualization and access. The length of time that a Pringle maneuver can remain in place without causing irreversible ischemic damage to the liver is unpredictable. Although cases in which a Pringle maneuver has been applied for > 60 min without appreciable hepatic damage have been reported, the goal of warm ischemia time should be < 30 min. An alternative is to intermittently unclamp the Pringle maneuver to allow temporary revascularization. Identification of the source of recurrent massive hemorrhage is clarified with application of the Pringle maneuver; hemorrhage from hepatic artery and portal vein injuries should halt with the application of a vascular clamp across the portal triad (including accessory hepatic arteries), while hepatic veins and retrohepatic vena caval bleeding will continue.

A number of effective methods for the definitive control of hepatic parenchymal hemorrhage have been developed (Figure 9). Minor lacerations may be controlled with manual compression applied directly to the injury site. Topical hemostatic techniques include electrocautery (set at 100), the argon beam coagulator (set at 100), microcrystalline collagen, thrombin-soaked gelatin foam sponge, fibrin glue, and BioGlue®. Suturing of the hepatic parenchyma with a large, blunt 0 chromic needle is generally discouraged due to the obligatory hepatic necrosis, but remains an effective hemostatic technique in selected cases. Deep lacerations that continue to bleed are approximated with interrupted horizontal mattress sutures placed parallel

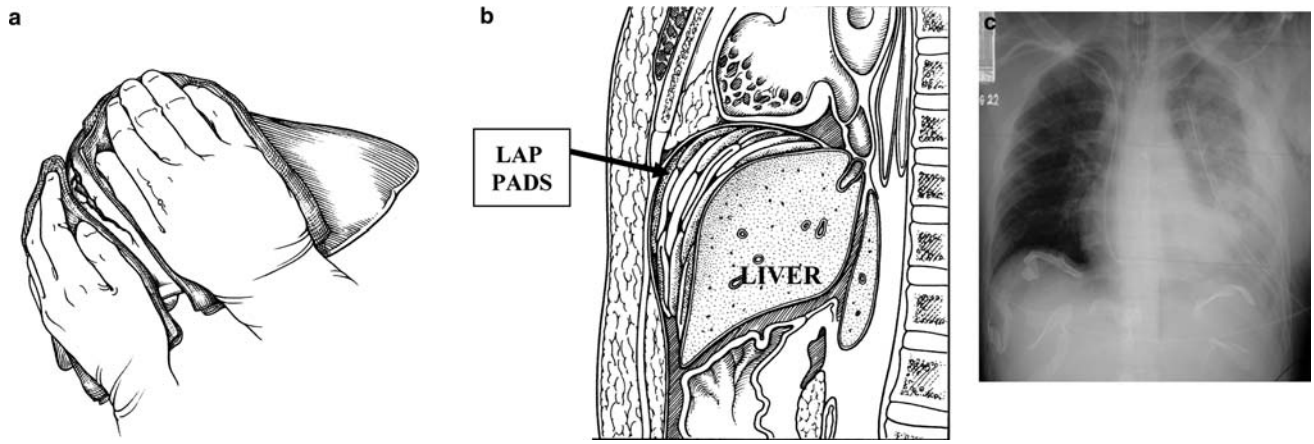

Figures 7a to 7c. Initial control of hemorrhage is best accomplished using a) manual compression and b) perihepatic packing. On this sagittal view, multiple laparotomy pads are placed between the liver and diaphragm, followed by packs underneath the liver. c) Following packing, the radiopaque laparotomy pad markers are visible on chest radiograph.

to the edge of the laceration. When tying the suture, tension should be limited to when visible hemorrhage ceases or the liver blanches around the suture. This technique of placing large liver sutures controls bleeding through re-approximation of the liver laceration rather than direct ligation of bleeding vessels. Aggressive finger fracture to identify bleeding vessels followed by individual clip or suture ligation was advocated previously, but currently has a limited role in hemostasis. Hepatic lobar arterial ligation may be appropriate for patients with recalcitrant arterial hemorrhage from deep within the liver, and is preferable to a deep hepatotomy, particularly in unstable patients. Omentum can be used to fill large defects in the liver. The tongue of omentum not only obliterates potential dead space with viable tissue, but also provides an excellent source of macrophages. Additionally, the omentum can provide buttressing support for parenchymal sutures. Several studies have demonstrated that the use of Penrose or sump drains is associated with a greater risk of intra-abdominal sepsis when compared to those treated with closed suction drains or no drains [22–25]. Drains are occasionally indicated if bile is seen oozing from the liver.

Portal Triad and Retrohepatic Vascular Injuries

Injuries of the portal triad vasculature must be addressed immediately to control potential massive hemorrhage and minimize hepatic reperfusion injury (Figure 10). In general, ligation from the celiac axis to the level of the common hepatic artery at the gastroduodenal arterial branch is tolerated due to extensive collaterals, but the proper hepatic artery should be repaired. The right or left hepatic artery, or in urgent situations the portal vein, may be selectively ligated; occasionally, lobar necrosis will necessitate delayed anatomic resection. If the right hepatic artery is ligated, cholecystectomy should also be performed. Initial control of vascular injuries is accomplished digitally by applying enough direct pressure to stop the hemorrhage. Sharp dissection is used to define the injury and mobilizes sufficient length for proximal and distal control. Heparinized saline (50 U/ml) is injected into

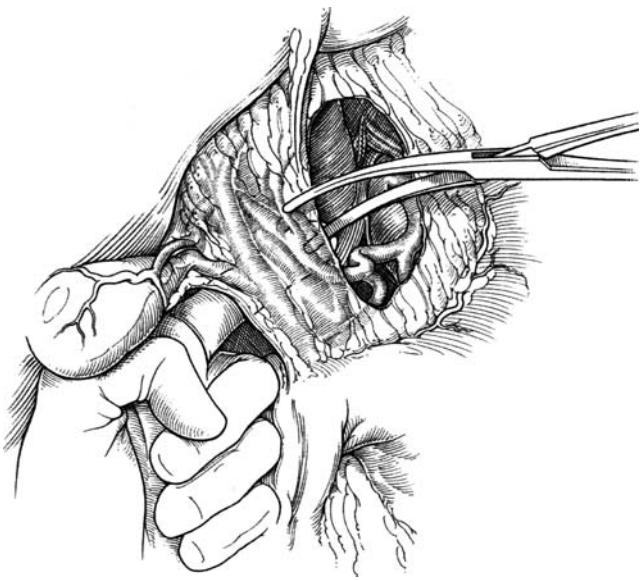

Figure 8. The Pringle maneuver. The portal triad is occluded by guiding the posterior blade of the clamp through the foramen of Winslow with the aid of the left index finger.

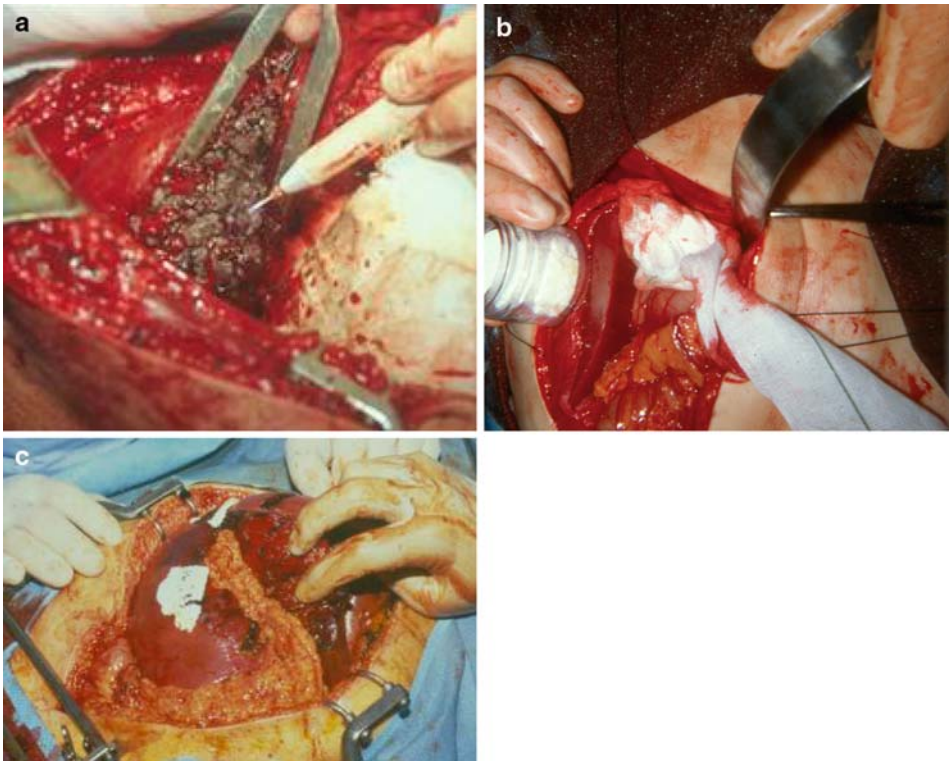

Figures 9a to 9c. Techniques for control of hepatic parenchymal hemorrhage include a) argon bean coagulation, b) microcrystalline collagen application, and c) omental packing.

the proximal and distal ends of the injured vessel to prevent clot formation on the exposed intima. Ragged edges of the injury site should be judiciously debrided using sharp dissection.

The type of operative repair is based upon the extent of injury. Lateral suture repair is preferred for arterial injuries with minimal loss of tissue. If the vascular injury is a stab wound with clean transection of the vessels, a primary end-to-end anastomosis is done. If the injury is destructive, temporary intravascular shunting should be used to reestablish inflow while preparing for definitive repair. Interposition grafts are used in such cases when end-to-end anastomosis cannot be accomplished without tension despite mobilization. For the hepatic artery, autogenous saphenous vein from the groin should be used since polytetrafluoroethylene (PTFE) grafts less than 6 mm have a prohibitive rate of thrombosis. The portal vein, however, can be bridged with a PTFE graft. Portal triad injuries may be complicated with enteric contamination from colon or small bowel injuries. There is natural reluctance to place artificial grafts in such circumstances, but graft infections are rare. Therefore, following the control of hemorrhage, bowel contamination is contained and the abdomen irrigated before placing PTFE grafts. Blunt avulsions of the portal structures are particularly problematic if located at the hepatic plate, flush with liver; hemorrhage control at liver can be attempted with directed packing or Fogarty catheters. If the avulsion is more proximal, flush with the border of the pancreatic body or even behind the pancreas, the body of the pancreas must be transected to gain access for hemorrhage control and vascular repair.

If massive venous hemorrhage is seen from behind the liver despite the Pringle maneuver, the patient likely has a major hepatic vein or retrohepatic vena caval injury. If bleeding is controlled, the packing should be left undisturbed and the patient observed in the SICU. If bleeding continues despite repeat perihepatic packing, attempts at direct repair, with or without hepatic vascular isolation, should be attempted. There are three techniques that have been employed to accomplish hepatic vascular isolation: (1) isolation with clamps on the diaphragmatic aorta, the suprarenal vena cava, and the suprahepatic vena cava, (2) the atriocaval shunt, and (3) the Moore–Pilcher balloon shunt. All techniques are performed with an associated Pringle maneuver. Even in experienced centers with readily available equipment, however,

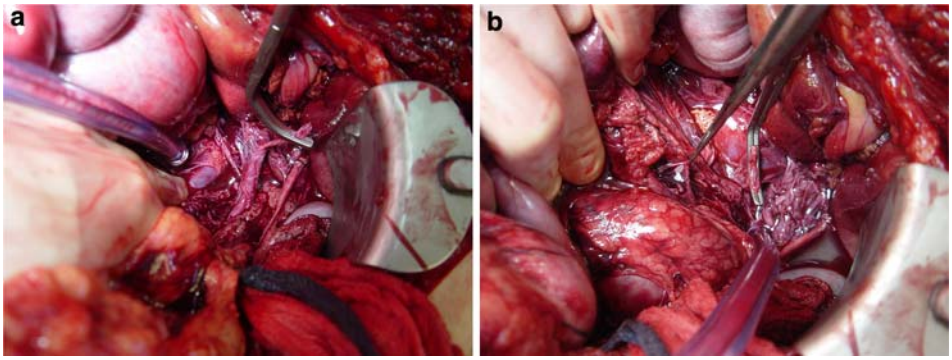

Figures 10a and 10b. a) A hepatic artery avulsion is controlled with a Satinsky vascular clamp. b) Complete portal vein transection with the proximal opening just above the pancreatic body (pickups reveal lumen) and the distal vein controlled with a vascular clamp.

such techniques carry a mortality rate greater than 80%.

Hepatic vascular isolation with clamps is accomplished by the application of a Pringle maneuver, clamping the aorta at the diaphragm, and clamping the suprarenal and suprahepatic vena cava. While this technique has enjoyed success in elective procedures, its use in trauma patients has had mixed results because patients in profound hemorrhagic shock do not tolerate the precipitous loss of venous return to the heart. The atriocaval shunt was designed to achieve hepatic vascular isolation while permitting venous blood to enter the heart from below the diaphragm [26]. To place the shunt, the suprarenal and suprahepatic vena cava are encircled, and a 36 Fr chest tube is passed into the cava from a purse-string controlled hole in the right atrial appendage. The shunt must be precisely constructed and properly positioned on the first attempt since patients with juxtahepatic venous injuries do not tolerate the continuing blood loss associated with repeated unsuccessful attempts to position the shunt. Enthusiasm for the shunt has declined as mortality rates with its use remain 50–80% [5]. A variation of the original atriocaval shunt has been the substitution of a 9-mm endotracheal tube for the large chest tube (Figure 11). While this change may seem trivial, surrounding the suprarenal vena cava with a snare tourniquet is extremely difficult since exsanguinating hemorrhage must be controlled by posterior compression of the liver, which severely restricts access to that segment of the vena cava. An alternative to the atriocaval shunt is the Moore–Pilcher balloon [27]. This device is inserted through the femoral vein and advanced into the retrohepatic vena cava. When the balloon is inflated, the hepatic veins and vena cava are occluded, thereby achieving vascular isolation. The catheter itself is hollow, and holes placed below the balloon permit blood to flow into the right atrium from the inferior vena cava. Despite a theoretically easier approach, there has been no documented improvement in survival with this balloon occlusion technique [28]. Instead, recent efforts to control this highly lethal injury have employed veno–veno bypass (Figure 12). Developing endovascular techniques may provide an alternative to direct vascular repair [29].

Surgeons who attempt hepatic vascular isolation should be aware that none of the techniques provide complete hemostasis. Because of the technical challenge and high mortality associated with hepatic vascular isolation, there has been a recent trend to avoid a direct operative approach to the injured vessels. If massive venous hemorrhage is seen from behind the liver, and if reasonable hemostasis can be achieved with perihepatic packing, the patient can be transferred to the interventional radiology suite, where hemorrhage from arterial sources are embolized and stents are placed to bridge venous injuries (Figure 13).

Penetrating Injuries

Translobar penetrating injuries are particularly challenging because the bullet frequently traverses a major blood vessel and the extent of the injury cannot be visualized. Management options include intraparenchymal tamponade with a Foley catheter or balloon occlusion [30]. A homemade balloon can be fashioned by placing a red Robinson catheter inside 1-in. Penrose drain, ligating each end of the drain (Figure 14). The deflated balloon is then inserted into the bleeding tract and, once positioned, a contrast agent is injected through the red Robinson catheter to fill the Penrose balloon. If control of the hemorrhage is successful, a stopcock or clamp is used to occlude the catheter and maintain the inflation. Another option for hemorrhage control, particularly for deep lacerations, is Foley catheter occlusion (Figure 15). Using a Foley catheter with a 30-cc balloon, the tip is placed deep within the tract; the balloon is inflated sequentially along the length of the tract until hemorrhage stops. If tampon-

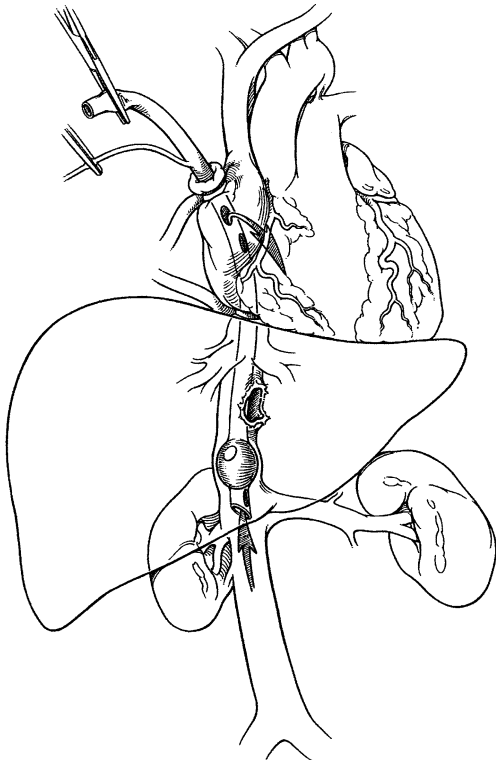

Figure 11. An endotracheal tube can be adapted to become an atriocaval shunt by cutting proximal holes to allow flow of blood into the atrium.

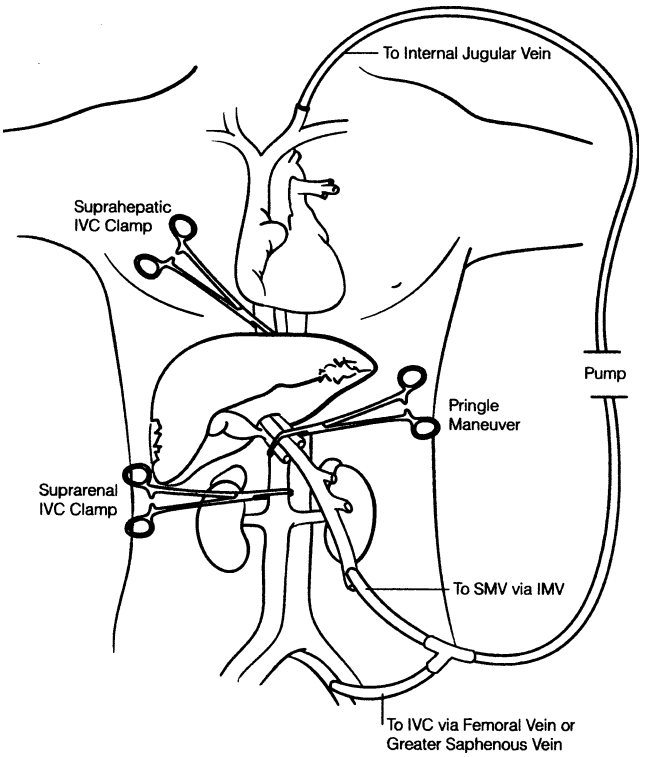

Figure 12. Veno–veno bypass permits hepatic vascular isolation with continued venous return to the heart.

ade is successful with either modality, the balloon is left inflated for 24–48 h followed by judicious deflation in the SICU and removal at a second laparotomy. Hepatotomy, using the finger fracture technique, with ligation of individual bleeders may occasionally be required. However, division of the overlying viable hepatic tissue may cause considerable blood loss in the coagulopathic patient. Finally, angioembolization is an effective adjunct in any of these scenarios and should be considered early in the course of treatment.

Gallbladder and Extrahepatic Duct Injuries

Injuries to the gallbladder or extrahepatic ducts may occur in isolation or in combination with more complex hepatic injuries [3–5]. Cholecystectomy is performed for injuries to the gallbladder and following operative ligation of the right hepatic artery. Injuries of the extrahepatic bile ducts are a challenge due to their small size and thin walls. Because of the proximity of other portal structures and the vena cava, associated vascular injuries are common. Small lacerations, with no loss or devitalization of adjacent tissue can be treated by the insertion of a T-tube through the wound, or by lateral suture using am absorbable 6–0 monofilament. Virtually all transections, and any injury associated with significant tissue loss, will require a Roux-en-Y choledochojejunostomy. The anastomosis is performed using a single-layer, interrupted technique using 6-0 monofilament absorbable suture. To reduce anastomotic tension, the jejunum should be tethered to the areolar tissue of the hepatic pedicle or porta hepatis. Injuries to the major hepatic ducts may not be possible to repair under emergent circumstances. One approach is to intubate the duct for external drainage and attempt a repair when the patient recovers. Alternatively, the lobar duct can be ligated if the opposite lobe is normal and uninjured [31, 32].

Intraoperative Considerations

Injured patients with life-threatening hemorrhage may develop marked coagulopathy requiring clotting factor replacement. Fresh whole blood, arguably the optimal replacement, is no longer available in the US. Rather, its component parts, packed red blood cells (PRBCs), fresh-frozen plasma (FFP), platelets, and cryoprecipitate are administered. Transfusion guidelines have been designed to limit infusion of immunologically active blood components which is associated with

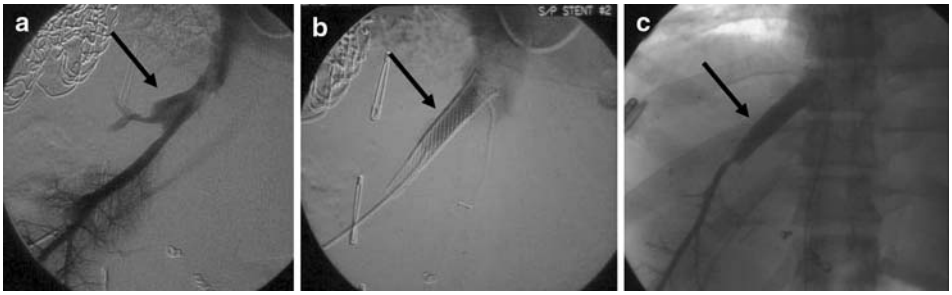

Figures 13a to 13c. a) A right hepatic vein injury can be effectively treated with b) endovascular stenting to restore c) normal blood flow.

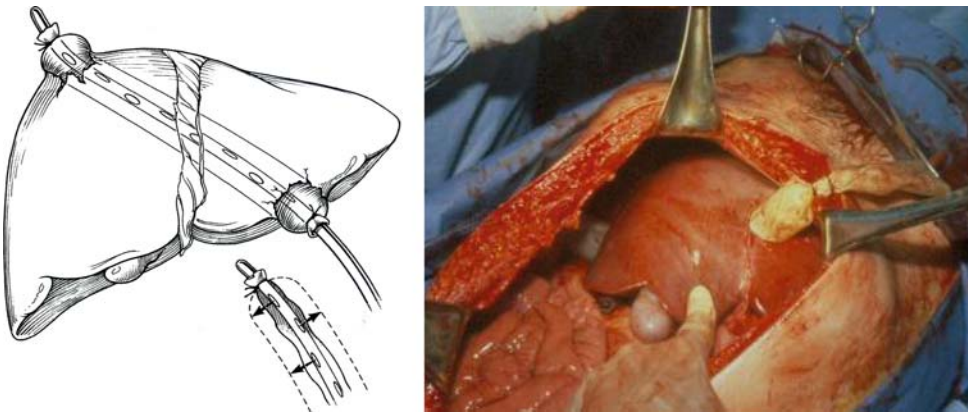

Figure 14. Balloon tamponade, as described by Pogetti et al., effectively controls translobar penetrating wounds.

transfusion associated lung injury (TRALI) and multiple organ failure (MOF) [33, 34]. During the acute phase of resuscitation, PRBC transfusion should continue until the patient's hemoglobin (Hb) is 10 g/dl [35]. Fresh frozen plasma is transfused to keep the patient's INR < 1.5, and partial thromboplastin time (PTT) < 45 s. A platelet count of 50,000 per μl is considered adequate if platelet function is normal. With massive transfusion, however, platelet dysfunction is common and, therefore, a target of 100,000 μl is advocated. If fibrinogen levels drop below 100 mg/dl, cryoprecipitate should be administered.

In the critically injured patient requiring large amounts of blood component therapy, a massive transfusion protocol should be employed (Figure 16). This approach uses ratio therapy during transfusion to achieve restoration of blood volume and correction of coagulopathy. Although the optimal ratio is yet to be determined, the majority of trauma centers use a presumptive 1:1 or 1:2 red cell to plasma ratio in patients at risk for massive transfusion (10 units PRBC/6 h). Trauma centers and their associated blood banks must have the capability of transfusing tremendous quantities of blood components, as it is not unusual to see 100 component units transfused during initial care of a critically injured patient.

Postinjury coagulopathy is associated with core hypothermia and metabolic acidosis, termed the ''bloody viscous cycle'' (Figure 17) [36]. The pathophysiology is multi-factorial and includes inhibition of temperature-dependent enzyme-activated coagulation cascades, platelet dysfunction, endothelial abnormalities, and a poorly understood fibrinolytic activity. Such

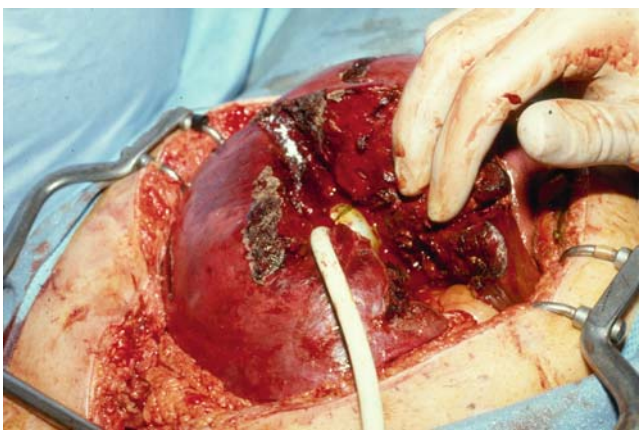

Figure 15. Using a Foley catheter with a 30 cc balloon can also effectively tamponade deep laceration following blunt or penetrating trauma.

Massive Transfusion Protocol

Trigger: Uncontrolled hemorrhage/anticipated coagulopathy with SBP < 90 mmHg despite 3½ L crystalloid (50mL/kg)

Surgery & Anesthesia Response

Continued Treatment of Shock
Hemorrhage Control
Correct Hypothermia
Correct Acidosis
Normalize Ca^{++}
Check labs q30 minutes as needed
Consider Recombinant Factor VIIα therapy

Ongoing Component Therapy**
INR > 1.5 or PTT > 45 → 4 units Fresh Frozen Plasma
Platelet count < 100,000/μL → 1 unit apheresis platelets
Fibrinogen < 100 mg/dL → 10 units pooled cryoprecipitate

Blood Bank Response

Shipment	PRBCs	FFP	Platelets	Cryo
1	4	2		
2	4	2	1	10
3	4	2		
4	4	2	1	10

Shipments are delivered every 30 minutes until Massive Transfusion Protocol is terminated.
Each shipment's quantity can be doubled at the request of Surgery or Anesthesia.
Shipments > 4 are determined by patient's clinical course and lab values.

**If Thromboelastography available: R > 4 minutes → 4 units FFP
MA < 54 mm → 1 unit apheresis platelets Angle < 47° → 10 units pooled cryoprecipitate CI > 3 → consider fibrinolysis treatment

Figure 16. Denver Health Medical Center's massive transfusion protocol.

coagulopathy may be insidious, so the surgeon must be cognizant of subtle signs such as excessive bleeding from the cut edges of skin. Although the coagulopathic ''ooze'' may seem minimal compared to the torrential hemorrhage from a retrohepatic caval injury, blood loss from the entire area of dissection can lead to life-threatening blood loss. Under such conditions, transfusion of FFP and platelets must be empiric, because lab results for the usual measurements of coagulation capability (i.e., INR, PTT, and platelet count) requires approximately 30 min. Recently, point-of-care testing with devices such as thromboelastography shows promise for more rationale transfusion of blood components.

Employing damage control techniques to limit operative time and provide physiologic restoration in the SICU can be lifesaving. Indications for damage control surgery, also termed a staged operation, include temperature < 35 °C, arterial pH < 7.2, base deficit < 15 mmol/l (or < 6 mmol/l in patients over 55 years of age), and INR or PTT > 50% of normal. Key damage control techniques for hepatic injuries include perihepatic packing and balloon occlusion tamponade. Temporary closure of the abdomen is obtained with ioban covering (Figure 18). In this technique, the bowel is covered with a fenestrated subfascial 1010 steri-drape (3 M Health Care, St. Paul, MN) and two Jackson–Pratt drains are placed along the fascial edges; this is then covered using an ioban,

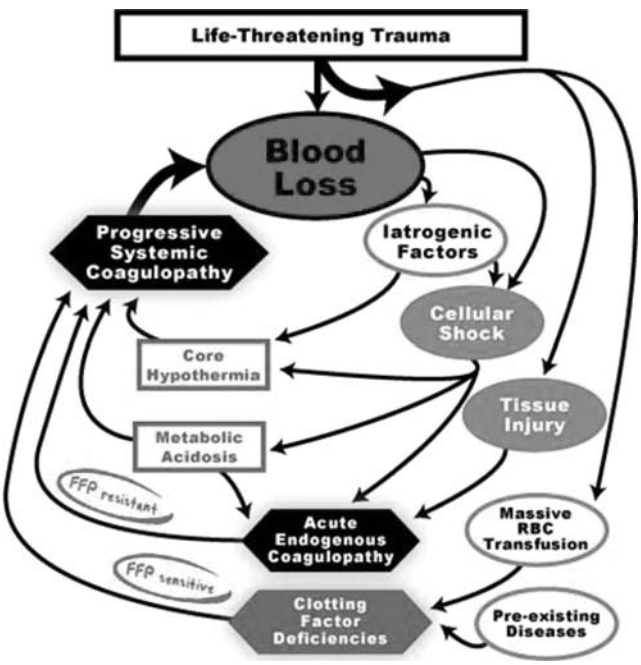

Figure 17. The bloody viscous cycle.

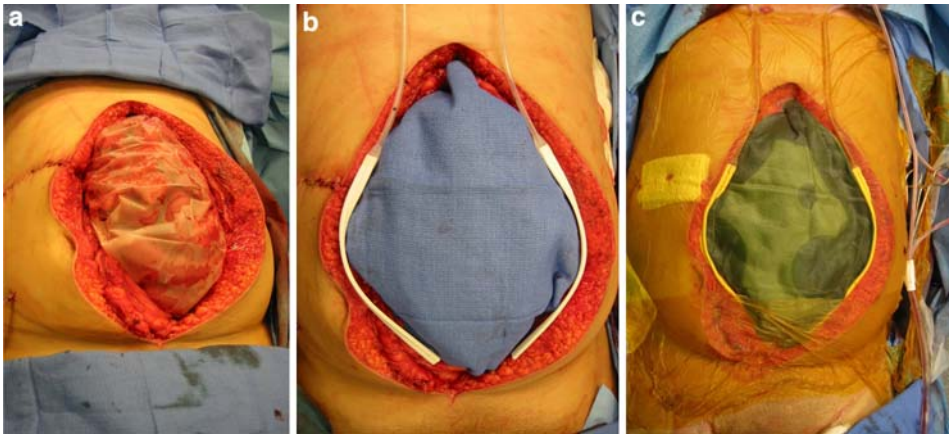

Figures 18a to 18c. a) Temporary closure of the abdomen entails covering the bowel with a fenestrated 1010 drape, b) placement of JP drains and a blue towel, c) followed by ioban occlusion.

allowing closed suction to control reperfusion-related ascitic fluid egress. During the initial DCS stage, the 1010 is not covered by a blue towel so that bowel viability and hemorrhage control can be assessed. With hepatic injuries, there is a balance in the effects of temporary closure. Although there must be enough intraabdominal pressure to achieve relative hemostasis from packing, too much pressure will result in the abdominal compartment syndrome [37]. Careful monitoring of bladder pressures in such patients every 2–4 h is warranted, with a low threshold for decompression if the patient exhibits end-organ sequelae. Return to the OR in 24–36 h is planned, once normothermia, normalization of coagulation studies, and correction of acidosis has been achieved.

Several centers have reported patients with devastating hepatic injuries or necrosis of the entire liver who have undergone successful hepatic transplantation. Clearly this is dramatic therapy and the patient must have all other injuries delineated, particularly those of the central nervous system, and have an excellent chance of survival excluding the hepatic injury. As donor availability will limit such procedures, hepatic transplantation for trauma will continue to be performed in extraordinary circumstances.

Postoperative Considerations

Postinjury Resuscitation

ICU management of the trauma patient, either with direct admission from the ED or following emergent operative intervention, is considered in distinct phases because there are differing goals and priorities. The period of acute resuscitation, typically lasting for the first 12–24 h following injury, combines several principles: optimizing tissue perfusion, ensuring normothermia, and restoring coagulation. There are a multitude of management algorithms aimed at accomplishing these goals; the majority involves goal-directed resuscitation with initial volume loading to attain adequate preload, followed by judicious use of vasoactive agents. Although the optimal hemoglobin level remains debated, during shock resuscitation a Hb > 10 g/dl optimizes oxygen delivery. A more judicious transfusion trigger of Hb < 7 g/dl in the euvolemic patient after the first 24 h of resuscitation limits the adverse immuno-inflammatory effects of stored RBCs. The resuscitation of the severely injured trauma patient may require what appears to be an inordinate amount of crystalloid resuscitation. Infusion volumes upwards of 10 l during the initial 6–12 h may be required to attain an adequate central venous pressure (CVP) above 8 mmHg. In fact, this is a challenging aspect of early care; i.e., balancing cardiac preload versus promoting an abdominal compartment syndrome or tissue edema [38].

Adequate resuscitation is mandatory, and often determines when the patient can safely return the patient to the OR after initial DCS. Specific goals of resuscitation prior to repeated ''semi-elective'' transport include a core temperature > 35 °C, base deficit < 6, and normal coagulation indices. Even those patients who do not require repeat operations should be monitored for resolution of physiologic perturbations; specific indices monitored over time include lactate and organ function. Although correction of base deficit and lactate values is desirable, how quickly this should be accomplished requires careful consideration. Exogenous bicarbonate, occasionally given to improve cardiovascular function and response to vasoactive agents if the serum pH is below 7.2, obfuscates the acid–base balance, and lactate may be a more reliable indicator of adequate perfusion. Adverse sequelae of overzealous crystalloid resuscitation include increased

intracranial pressure, worsening pulmonary edema, and intraabdominal visceral and retroperitoneal edema resulting in secondary abdominal compartment syndrome. Therefore, it should be the overall trend of the resuscitation rather than a rapid reduction of a specific index that is the goal.

Postoperative Care

Patients undergoing perihepatic packing for extensive liver injuries are typically returned to the operating room for pack removal 24–36 h after initial injury. Earlier exploration may be indicated in patients with evidence of ongoing hemorrhage. Signs of rebleeding are a falling hematocrit, blood clots accumulating under the temporary abdominal closure device, and bloody output from the JP drains placed under the abdominal ioban covering; the magnitude of hemorrhage is reflected in transfusion requirements and refractory acidosis. Patients with hepatic ischemia, due to a prolonged intraoperative Pringle maneuver, have an expected elevation but subsequent resolution of their transaminases; alternatively, patients requiring hepatic artery ligation may develop hepatic necrosis. Although patients should be evaluated for potential infectious complications, patients with complex hepatic injuries frequently have intermittent ''liver fever'' for first 5 postinjury days. If perihepatic drains were placed intraoperatively, the quantity and quality of output should be evaluated. Persistent bilious output should prompt investigation for a bile leak. Alternatively, abrupt cessation of drainage with an associated fever should prompt consideration for diagnostic imaging.

In general, outcome following vascular injuries of the portal triad is related to the early technical success of the operation. Following hepatic artery interposition grafting, the patient's systolic blood pressure should not exceed 140 mmHg for at least the first 72 h postoperatively. Conversely, following hepatic artery ligation, hypotension should be avoided. Midline laparotomy wounds are inspected 48-h postoperatively by removing the sterile surgical dressing. If a wound infection is identified – evidenced by erythema, pain along the wound, or purulent drainage – the wound should be opened by removing skin staples. After ensuring the midline fascia is intact with digital palpation, the wound is initially managed with wet-to-dry dressing changes.

Complications

The complications following major hepatic trauma include perihepatic abscesses, delayed hemorrhage, bilomas, hepatic necrosis, arterial pseudoaneurysms, and various fistulae [19, 20]. In patients requiring perihepatic packing, postoperative hemorrhage is not unusual. Ideally, patients should undergo re-exploration once their coagulopathy is corrected; however, unstable patients should be returned to the OR emergently for evaluation and repacking. Alternatively, angioembolization is appropriate for central lesions. Patients undergoing hepatic artery ligation, either operatively or with angioembolization, may develop hepatic necrosis (Figure 19). Resectional debridement is indicated for the removal of peripheral portions of nonviable hepatic parenchyma [39].

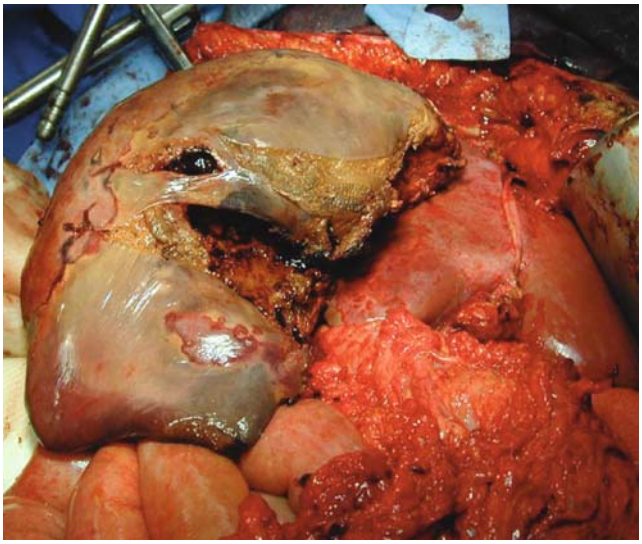

Figure 19. Formal hepatic lobectomy for necrosis may be required following either operative hepatic artery ligation or angioembolization.

The most common sequelae of hepatic trauma are biliary fistulas, complicating up to 20% of injuries [12, 20, 40]. Clinical presentation includes abdominal distension, pain and tenderness on exam, intolerance of enteral feeding, and abnormal liver function tests. Bedside ultrasound should be used liberally. Bilomas, loculated collections of bile, can have a variable clinical course. Small, sterile bilomas will eventually be reabsorbed, but larger fluid collections should be drained percutaneously (Figure 20). Bilomas may be come infected, particularly after penetrating trauma, and should be treated much like any other intraabdominal abscess. If operative drainage becomes necessary for loculated collections, a 12th rib resection-approach provides optimal drainage for posterior infections. Biliary ascites, due to the disruption of a major bile duct, often requires reoperation. If the patient was ini-

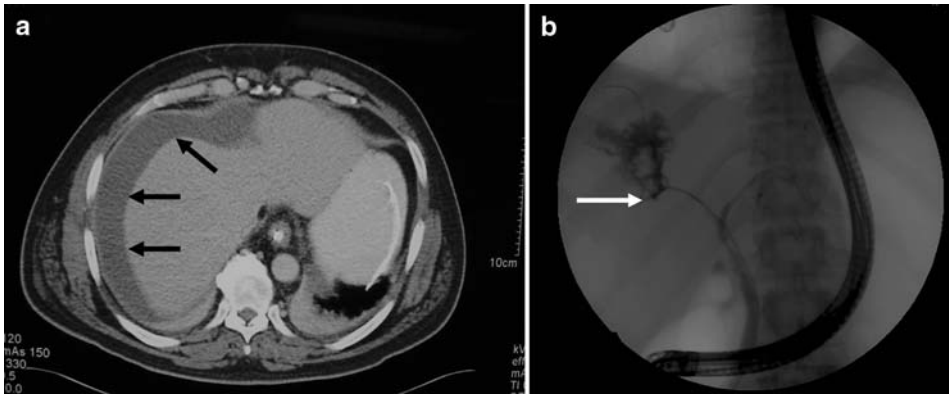

Figures 20a and 20b. a) A biloma, evident on CT scan, with an b) associated right hepatic duct injury evident on ERC.

tially treated nonoperatively, a laparoscopic approach may be considered for abdominal washout and drain placement [41]. Primary repair of the injured duct is unlikely to be successful and is rarely attempted. ERC should be relied on for both diagnosis and treatment [42] (Figure 20). Occasionally, the ductal injury can be stented, but sphincterotomy with placement of a common bile duct stent effectively reduces pressure within the biliary system and promotes healing [40, 43]. The vast majority of ductal injuries, particularly in patients managed nonoperatively, heal within 4–6 weeks.

Pseudoaneurysms are rare complications of patients with hepatic injuries. Since hemorrhage from hepatic injuries is often treated without isolating individual bleeding vessels, arterial pseudoaneurysms may develop with the potential for rupture. Rupture into a bile duct results in hemobilia, which is characterized by intermittent episodes of right upper quadrant pain, upper gastrointestinal hemorrhage, and jaundice. If the aneurysm ruptures into a portal vein, portal venous hypertension with bleeding esophageal varices may occur. Either scenario is best managed with hepatic arteriography and embolization [44, 45]. Biliovenous fistulae, causing jaundice due to rapid increases in serum bilirubin levels, should be treated with ERCP and sphincterotomy [46]. Rarely, a biliary fistulous communication will form with intrathoracic structures in patients with associated diaphragm injuries, resulting in a bronchobiliary or pleurobiliary fistula. Due to the pressure differential between the positive biliary tract and the negative pleural cavity, the majority require operative closure. Occasionally, endoscopic sphincterotomy with stent placement will effectively address the pressure differential, and the pleurobiliary fistula will close spontaneously.

Summary

Hepatic injuries are one of the most common abdominal injuries following either blunt or penetrating trauma. CT scanning has revolutionized the treatment algorithm for these patients. The majority of patients are successfully treated with nonoperative management, but surgeons should have a clear understanding of the indications for operative intervention. An array of techniques including operative, interventional, and endoscopic, are often required for management of advanced grade hepatic injuries.

References

1. Edler. Archiv f Klin Chir Bd XXXIV, 1887.
2. Tilton B. Considerations regarding wounds of the livers. Ann Surg 1905;27.
3. Madding GF, Lawrence KB, Kennedy PA. Forward surgery of the severely injured. Second Aux Surg Group 1942;1:307.
4. Lucas CE, Ledgerwood AM. Prospective evaluation of hemostatic techniques for liver injuries. J Trauma 1976;16:442–51.
5. Richardson JD, Franklin GA, Lukan JK, Carrillo EH, Spain DA, Frank BM, Wilson MA, Polk HC, Flint LM. Evolution in the management of hepatic trauma: a 25-year perspective. Ann Surg 2000;232:324.
6. Olsen WR, Redman HC, Hildreth DH. Quantitative peritoneal lavage in blunt abdominal trauma. Arch Surg 1972;104:536.
7. Rozycki GS, Ochsner MG, Feliciano DV, Thomas B, Boulanger BR, Davis FE, Falcone RE, Schmidt JA. Early detection of hemoperitoneum by ultrasound examination of the right upper quadrant: a multicenter study. J Trauma 1998;45:878.
8. Branney SW, Wolfe RE, Moore EE, Albert NP, Heinig M, Mestek M, Eule J. Quantitative sensitivity of ultrasound in detecting free intraperitoneal fluid. J Trauma 1995;39:375.
9. Rozycki GS, Ballard RB, Feliciano DV, Schmidt JA, Pennington SD. Surgeon-performed ultrasound for the assessment of truncal injuries: lessons learned from 1540 patients. Ann Surg 1998;228:557.
10. Renz BM, Feliciano DV. Gunshot wounds to the liver. A prospective study of selective nonoperative management. J Med Assoc Ga 1995;84:275.

11. Demetriades D, Gomez H, Chahwan S, et al. Gunshot injuries to the liver: the role of selective nonoperative management. J Am Coll Surg 1998;188:343.
12. Croce MA, Fabian TC, Menke PG, et al. Nonoperative management of blunt hepatic trauma is the treatment of choice for hemodynamically stable patients. Results of a prospective trial. Ann Surg 1995;221:744.
13. Malhotra AK, Fabian TC, Croce MA, Gavin TJ, Kudsk KA, Minard G, Pritchard FE. Blunt hepatic injury: a paradigm shift from operative to nonoperative management in the 1990s. Ann Surg 2000;231:804.
14. Pachter HL, Knudson MM, Esrig B, et al. Status of nonoperative management of blunt hepatic injuries in 1995: a multicenter experience with 404 patients. J Trauma 1996;40:31.
15. Fang JF, Chen RJ, Wong YC, et al. Classification and treatment of pooling of contrast material on computed tomographic scan of blunt hepatic trauma. J Trauma 2000;49:1083.
16. Ciraulo DL, Luk S, Palter M, et al. Selective hepatic arterial embolization of grade IV and V blunt hepatic injuries: an extension of resuscitation in the nonoperative management of traumatic hepatic injuries. J Trauma 1998;45:353.
17. Nance FC, Cohn I. Surgical judgment in the management of stab wounds of the abdomen: a retrospective and prospective analysis based on a study of 600 stabbed patients. Ann Surg 1969;170:569.
18. Velmahos GC, Constantinou C, Tillou A, et al. Abdominal computed tomographic scan for patients with gunshot wounds to the abdomen selected for nonoperative management. J Trauma 2005;59:1155.
19. Kozar RA, Moore JB, Niles SE, et al. Complications of nonoperative management of high grade blunt hepatic injuries. J Trauma 2005;59:1066–71.
20. Kozar RA, Moore FA, Cothren CC, et al. Risk factors for hepatic morbidity following nonoperative management: Multicenter study. Arch Surg 2006;141:451–9.
21. Pringle JH. Notes on the arrest of hepatic hemorrhage due to trauma. Ann Surg 1908;48:451.
22. Fischer RP, Beverlin BC, Engrav LH. Diagnostic peritoneal lavage: fourteen years and 2586 patients later. Am J Surg 1978;136:701.
23. Fabian TC, Croce MA, Stanford GG, et al. Factors affecting morbidity following hepatic trauma. A prospective analysis of 482 injuries. Ann Surg 1991;213:540.
24. Noyes LD, Doyle DJ, McSwain NE. Septic complications associated with the use of peritoneal drains in liver trauma. J Trauma 1988;28:337.
25. Mullins RJ, Stone HH, Dunlop WE, et al. Hepatic trauma: evaluation of routine drainage. South Med J 1985;78:259.
26. Schrock T, Blaisdell W, Mathewson C. Management of blunt trauma to the liver and hepatic veins. Arch Surg 1968;96:698.
27. Pilcher DB, Harman PK, Moore EE. Retrohepatic vena cava balloon shunt introduced via the sapheno-femoral junction. J Trauma 1977;17:837.
28. Cogbill TH, Moore EE, Jurkovich GJ, et al. Severe hepatic trauma: a multi-center experience with 1335 liver injuries. J Trauma 1988;28:1433.
29. Denton JR, Moore EE, Coldwell DM. Multimodality treatment for grade V hepatic injuries: perihepatic packing, arterial embolization, and venous stenting. J Trauma 1997;42:964–7.
30. Poggetti RS, Moore EE, Moore FA, et al. Balloon tamponade for bilobar transfixing hepatic gunshot wounds. J Trauma 1992;33:694.
31. Jurkovich GJ, Hoyt DB, Moore FA, et al. Portal triad injuries. J Trauma 1995;39:426–34.
32. Posner MC, Moore EE. Extrahepatic biliary tract injury: operative management plan. J Trauma 1985;25:833–7.
33. Toy P, Popovsky MA, Abraham E, et al. Transfusion-related acute lung injury: definition and review. Crit Care Med 2005;33:721.
34. Moore FA, Moore EE, Sauaia A.. Blood transfusion. An independent risk factor for postinjury multiple organ failure. Arch Surg 1997;132:620.
35. Moore FA, McKinley BA, Moore EE, et al. Inflammation and the host response to injury, a large-scale collaborative project: patient-oriented research core – standard operating procedures for clinical care. III. Guidelines for shock resuscitation. J Trauma 2006;61:82–9.
36. Kashuk JL, Moore EE, Sauaia A, Haenel J, Wilson M, Johnson J, Moore JB, Cothren CC. Postinjury life-threatening coagulopathy: is 1:1 the answer? J Trauma 2008 (in press).
37. Meldrum DR, Moore FA, Moore EE, Haenel JB, Cosgriff N, Burch JM. Jack A. Barney resident research award. Cardiopulmonary hazards of perihepatic packing for major liver injuries. Am J Surg 1995;170:537–40.
38. McKinley BA, Kozar RA, Cocanour CS, et al. Normal versus supranormal oxygen delivery goals in shock resuscitation: the response is the same. J Trauma 2002;53:825–32.
39. Strong RW, Lynch SV, Wall DR, et al. Anatomic resection for severe liver trauma. Surgery 1998;123:251.
40. Asensio JA, Demetriades D, Chahwan S, et al. Approach to the management of complex hepatic injuries. J Trauma 2000;48:66.
41. Griffen M, Ochoa J, Boulanger BR. A minimally invasive approach to bile peritonitis after blunt liver injury. Am Surg 2000;66:309.
42. D'Amour SK, Simons RK, Scudamore DH, et al. Major intrahepatic bile duct injuries detected after laparotomy: selective nonoperative management. J Trauma 2001;50:480.
43. Marks JM, Ponsky JL, Shillingstad RB, Singh J. Biliary stenting is more effective than sphincterotomy in the resolution of biliary leaks. Surg Endosc 1998;12:327.
44. Croce MA, Fabian TC, Spiers JP, et al. Traumatic hepatic artery pseudoaneurysm with hemobilia. Am J Surg 1994;168:235.
45. Cyret P, Baumer R, Roche A. Hepatic hemobilia of traumatic or iatrogenic origin. Recent advances of diagnosis and therapy. Review of the literature from 1976–1981. World J Surg 1984;8:2.
46. Glaser K, Wetscher G, Pointner R, et al. Traumatic bilhemia. Surgery 1994;116:24.

Address for Correspondence
Clay C. Cothren, MD, FACS
Department of Surgery
Denver Health Medical Center and the University of Colorado at Denver School of Medicine
777 Bannock Street, MC 0206
Denver, CO, 80204
USA
Phone (+13/03) 436-6558, Fax 436-6572
e-mail: clay.cothren@dhha.org