Magnetic Resonance Imaging Identifies Multifocal and Multicentric Disease in Breast Cancer Patients Who Are Eligible for Partial Breast Irradiation

Hania A. Al-Hallaq, PhD[1]
Loren K. Mell, MD[1]
Julie A. Bradley, MD[1]
Lucy F. Chen, MD[1]
Arif N. Ali, MD[1]
Ralph R. Weichselbaum, MD[1]
Gillian M. Newstead, MD[2]
Steven J. Chmura, MD, PhD[1]

[1] Department of Radiation and Cellular Oncology, University of Chicago, Chicago, Illinois.

[2] Department of Radiology, University of Chicago, Chicago, Illinois.

BACKGROUND. In this retrospective study, the authors hypothesized that magnetic resonance imaging (MRI) would alter partial breast irradiation (PBI) eligibility by identifying cancers outside the PBI volume compared with mammography alone.
METHODS. Since 2002, MRI was used nonselectively at the authors' institution for the staging of patients with nonmetastatic breast cancer. Of 450 consecutive patients with invasive breast cancer, 110 patients who were eligible for PBI were identified by using criteria outlined by National Surgical Adjuvant Breast and Bowel Project B-39/Radiation Oncology Group trial 0413 based on mammography, ultrasonography, and initial pathology. In that trial, patients were randomized (stage I/II invasive cancers that measured $\leq$3 cm and $\leq$3 positive lymph nodes) to receive either whole-breast radiotherapy or PBI. MRI reports were reviewed to determine whether MRI identified secondary lesions 1) within the same quadrant (multifocal), 2) in a different quadrant (multicentric), or 3) in the contralateral breast. These lesions were pathologically proven carcinoma and would have rendered the patient ineligible for PBI.
RESULTS. MRI identified secondary lesions in 10% of patients (95% confidence interval [CI], 4.4%-15.6%). Multifocal disease was identified in 3.6% (95% CI, 1.4%-9%), multicentric disease was identified in 4.5% (95% CI, 2%-10.2%), and contralateral disease was identified in 1.8% (95% CI, 0.5%-6.4%). The proportion of patients with false-positive MRI findings was 4.5% (95% CI, 2%-10.2%). The positive predictive value of MRI was 72.2% (95% CI, 46.4%-89.3%).
CONCLUSIONS. MRI identified frequent secondary cancers that would not be removed routinely by surgery or targeted in the radiation field if treated with PBI. The current data suggest that MRI should be considered to assess PBI eligibility to minimize potential local failures. ***Cancer* 2008;113:2408–14.** © *2008 American Cancer Society.*

KEYWORDS: breast cancer, magnetic resonance imaging, radiotherapy, whole-breast irradiation, partial breast irradiation.

Multiple randomized studies have demonstrated that breast-conserving therapy (BCT), consisting of local tumor excision followed by radiation to the entire breast, is equivalent to mastectomy in terms of disease-free survival, distant-disease-free survival, and overall survival for early-stage breast cancers.[1,2] In fact, studies attempting to limit treatment to the affected breast quadrant through quadrantectomy alone have demonstrated an increase in local recurrence from 6% to 24% compared with quadrantectomy followed by radiotherapy to the whole breast.[3] Furthermore, some studies have demonstrated a link between early-stage patients receiving radiation therapy and an increase in their overall

Gillian M. Newstead is on the advisory board of Konica Medical USA, has an institutional research agreement with Philips Medical, and her spouse owns stock in Hologic.

Address for reprints: Hania A. Al-Hallaq, PhD, Department of Radiation and Cellular Oncology, University of Chicago, 5758 South Maryland Avenue, MC9006, Chicago, IL 60637; Fax: (773) 834-7299; E-mail: hal-hallaq@radonc.uchicago.edu

Received April 14, 2008; revision received June 6, 2008; accepted June 20, 2008.

© 2008 American Cancer Society
DOI 10.1002/cncr.23872
Published online 29 September 2008 in Wiley InterScience (www.interscience.wiley.com).

survival,[4-6] particularly for lymph node-positive patients.[3,6,7] These results demonstrate that radiotherapy is an integral component to maintaining high levels of breast conservation in early-stage patients.[7]

Despite the equivalence of BCT to mastectomy, certain patients elect mastectomy.[8] Moreover, 15% of patients who receive BCT choose to forgo radiotherapy.[8] The 3- to 6-week daily radiotherapy treatments may be difficult for the elderly, noncompliant, or those with limited access to radiation therapy centers. Because the majority of first treatment failures for early-stage breast cancer occur within the original lumpectomy site,[9] techniques known as partial breast irradiation (PBI) have emerged to limit radiation to the lumpectomy cavity in certain low-risk patients. PBI may increase the practice of BCT across a larger patient population, decrease the total dose of radiation to the heart and lungs, and provide equivalent or superior cosmesis and quality of life.

Currently, the only national trial assessing PBI utility is the National Surgical Adjuvant Breast and Bowel Project (NSABP) B-39/Radiation Oncology Group (RTOG) 0413 phase 3 trial, which compares local tumor control rates between whole-breast irradiation (WBI) and PBI in patients with stage I/II invasive cancers ($\leq$3 cm, $\leq$3 positive lymph nodes). A variety of techniques for PBI are permitted in that study, including brachytherapy and 3-dimensional (3D) conformal external beam with accelerated radiation schedules. Although the NSABP B-39/RTOG 0413 trial currently is accruing patients, long-term follow-up will be needed to determine whether PBI provides comparable rates of local control, disease-free survival, and overall survival compared with traditional WBI. It is worth noting that the current NSABP B-39/RTOG 0413 trial neither requires nor scores magnetic resonance imaging (MRI) findings before patient selection.

It has been demonstrated that the use of MRI for preoperative staging is more accurate for measuring tumor size and disease extent than mammography alone.[10,11] Since 2002, MRI has been used routinely at our institution for breast cancer staging and for evaluating tumor recurrence.[12] MRI evaluation is performed with bilateral imaging using a dedicated, 4-channel breast coil. The imaging protocol consists of high-resolution, T_2-weighted, anatomic images in addition to analysis of dynamic contrast-enhanced (DCE), T_1-weighted images. Our data demonstrate sensitivity for breast cancer detection similar to that reported in the literature.[13]

We hypothesized that MRI may identify patients with disease outside both the lumpectomy cavity and the PBI target volume compared with modern mammography alone. This is because MRI has higher sensitivity than mammography and, thus, can detect disease that is clinically and/or mammographically occult.[13] Consequently, MRI may help to identify patients with concurrent disease in the ipsilateral and/or contralateral breast. The inclusion of patients with potentially occult disease in PBI trials may complicate interpretation of tumor recurrence between PBI and WBI. In addition, PBI in patients with untreated occult disease may result in higher ipsilateral tumor recurrence rates.

MATERIALS AND METHODS

MRI was performed on our clinical 1.5-T Signa scanner (General Electrical Medical System, Milwaukee, Wis). The scanner is equipped with dedicated, bilateral, 4-channel breast coils that provide high signal-to-noise ratios. Patients are positioned prone with their breasts lightly compressed by lateral paddles within the coils. The imaging protocol generally consist of 1) T_2-weighted fast spin-echo images, 2) T_1-weighted images obtained preinjection and postinjection of 0.01 mmol/kg gadodiamide (Omniscan; Amershan Biosciences Corp., Piscatawy, NJ), and 3) postcontrast, fat-saturated spin-echo images. Image resolution is 0.7 mm to 1.4 mm in each dimension with 3 mm to 4 mm slice thicknesses. Contrast uptake kinetic curves are analyzed for each suspicious lesion.[12] All patients who are referred for clinical breast MRI at our institution were entered into a database that was approved for research use by our Institutional Review Board.

Since 2002, breast radiologists at our institution routinely have advocated the use of MRI for staging all breast cancer patients. After a breast cancer diagnosis, breast MRI routinely is covered by private insurance and Medicare and subsequently continues to be covered after preauthorization. Not all breast cancer patients at our institution underwent MRI because of throughput issues. However, patient inclusion was nonselective (ie, blind to breast cancer stage or disease progression). Our institutional database contained 450 breast cancer patients with staging MRI between August 2002 and June 2006. Of the total 450 MRI staging reports that were reviewed for this study, approximately 300 had complete MRI, mammography, and final pathology reports from our institution. According to our Cancer Registry database, our institution provided definitive surgery for 470 patients with stage I/II breast cancer during this same period. Therefore, we estimate that approxi-

mately 60% of breast cancer patients received staging MRI.

Because final (ie, postsurgical) pathology reports from our institution were required for the inclusion of patients in our retrospective study, we carefully reviewed the institutional pathology reports after definitive surgery and identified 110 patients who met entry criteria for NSABP B-39. Because we are not currently treating patients with PBI, we chose to use these widely accepted criteria. Although NSABP B-39 allows for the inclusion of patients with ductal carcinoma in situ (DCIS), ie, stage 0 disease, our study focused on patients with a primary diagnosis of invasive carcinoma, because there is greater concern about the impact of disease elsewhere in the breast on locoregional recurrence rates and overall survival in this patient population. Furthermore, an initial retrospective review of pathology reports of DCIS proved problematic because of nonstandard reporting of DCIS lesion size. Without a clear size estimate from final pathology, it was not possible to determine retrospectively whether patients would have been eligible for PBI.

The initial screening and diagnostic mammography, diagnostic ultrasonography, and postsurgical pathology reports were reviewed retrospectively to determine whether the patient was eligible for PBI according to NSABP B-39 criteria. These criteria can be summarized as 1) a unifocal, invasive lesion no greater than 3 cm in size; 2) negative pathologic margins free of DCIS and invasive tumor; 3) no more than 3 positive lymph nodes; 4) no extracapsular lymph node extension; and 5) full axillary staging with a minimum of 6 axillary lymph nodes sampled if a sentinel lymph node was positive. Then, the MRI and final pathology reports for each patient were reviewed to determine whether MRI identified secondary invasive lesions or intraductal disease 1) within the same quadrant (multifocal), 2) in a different quadrant or 4 cm away (multicentric), or 3) in the contralateral breast. Figure 1 depicts a flow chart summarizing the use of MRI for breast cancer staging.

Our analysis focused on secondary lesions identified by MRI that were pathologically proven invasive carcinoma or DCIS and would have rendered the patient ineligible for PBI. Furthermore, the additional invasive or intraductal disease was not identified by the initial screening and diagnostic mammography, ultrasonography, or clinical examinations. In addition to tracking primary tumor size, location, grade, excision margin, and lymph node status, data regarding the following tumor characteristics were gathered: estrogen receptor status, progesterone receptor status, human epidermal growth factor receptor 2 (HER-2-*neu*) status, and the presence of lymphovascular invasion.

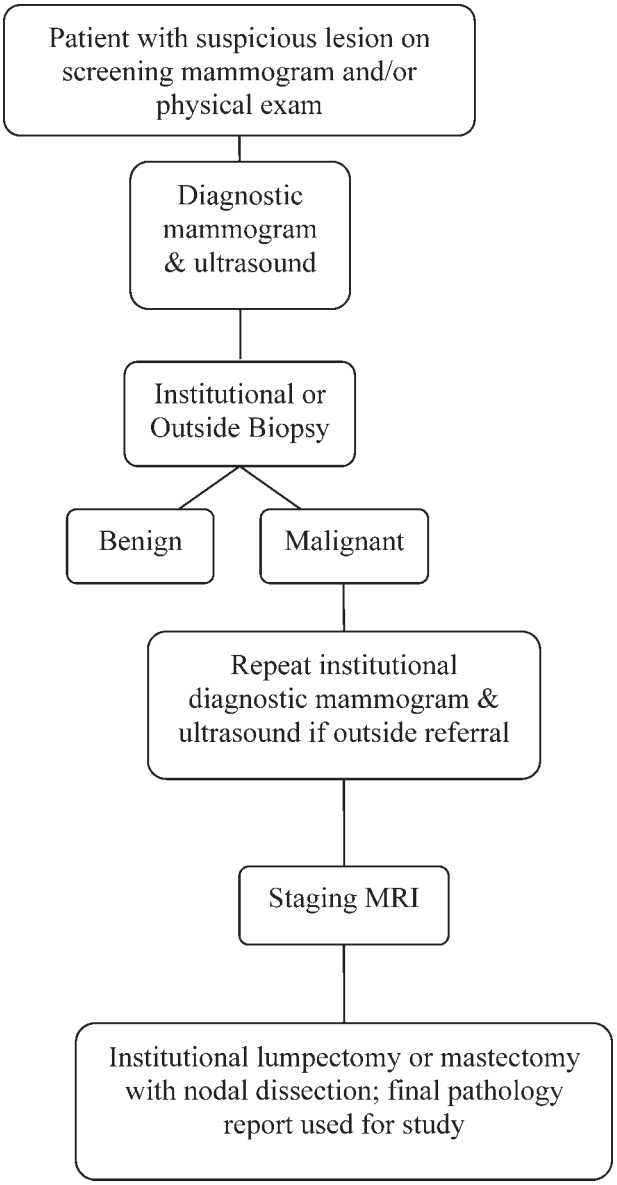

FIGURE 1. This flow chart depicts the use of staging magnetic resonance imaging (MRI) at the author's institution.

Because of the retrospective nature of this study, patients with incomplete final pathology reports or without full axillary dissection after a positive sentinel lymph node biopsy, as outlined by the NSABP B-39 trial, were excluded. Patients with persistent positive margins that led to multiple excisions and a final tumor size that was not assessed clearly by the pathologist also were excluded. In an attempt to eliminate incidental lesions that would have been found

TABLE 1
Patient and Tumor Characteristics

Characteristic	No. of Patients (%)
No. of patients	110
Mean age [range], y	57 [34-87]
Mean tumor size [range], cm	1.54 [0.1-3]
Stage	
I	94 (85)
IIA	9 (8)
IIB	7 (6)
Tumor classification	
T1a	5 (4.5)
T1b	26 (23.5)
T1c	52 (47)
T2	27 (25)
Positive lymph node status	16 (15)
DCIS component accompanying IDC	
0-20% DCIS	84 (76)
>20% DCIS	26 (24)
Hormone receptor status	
ER+/PR+	54 (50)
ER−/PR−	32 (30)
ER+/PR−	20 (18)
ER−/PR+	1 (1)
HER-2-*neu*+	17 (15)
Lymphovascular invasion	9 (8)
Grade	
1	27(25)
2	44 (40)
3	34 (37)
Unknown	2 (2)
Surgical management	
Lumpectomy	98 (89)
Mastectomy	12 (11)

IDC indicates invasive ductal carcinoma; DCIS, ductal carcinoma in situ; ER, estrogen receptor; +, positive; PR, progesterone receptor; −, negative; Her-2, human epidermal growth factor receptor 2.

by pathology alone, only secondary invasive lesions found by MRI that were at least 1 cm away from the initial, completely excised lesion site were considered to have changed PBI candidacy. A distance of 1 cm was chosen both to coincide with the standard surgical excision margin and to exclude tumors that may have been excised incidentally during surgery. Finally, biopsies prompted by MRI that ultimately were negative were scored to determine false-positive rates.

For statistical analysis, the normal approximation of the binomial distribution was used to calculate 95% confidence intervals (CIs) for proportions when the number of events was >5. Otherwise, the method described by Wilson[14] was used.

RESULTS

Since 2002, MRI has been used nonselectively at our institution for breast cancer staging. By using our staging MRI database, we identified 110 patients who would have been eligible for PBI. Table 1 summarizes patient characteristics, tumor characteristics, and surgical management.

TABLE 2
Magnetic Resonance Imaging Alters Eligibility for Partial Breast Irradiation by Identifying Multifocal, Multicentric, and Contralateral Disease

Characteristic	NSABP B-39/RTOG 0413 PBI Criteria: No./Total (%)
Mean patient age [range], y	57 [34-87]
All invasive secondary lesions	11/110 (10)
Secondary disease	
Multifocal	4/110 (3.6)
Multicentric	5/110 (4.5)
Contralateral	2/110 (1.8)

NSABP B-39 indicates National Surgical Adjuvant Breast and Bowel Project trial B-39; RTOG 0413, Radiation Oncology Group trial 0413; PBI, partial breast irradiation.

Table 2 summarizes the MRI results from the patients who were deemed ineligible for PBI according to the NSABP B-39 trial guidelines. MRI identified secondary disease in 11 patients (10%; 95% CI, 4.4%-15.6%) that would have made these patients ineligible for the NSABP B-39 trial. Thus, MRI identified a significant number of patients with secondary disease. Multifocal disease was identified in 3.6% of patients (95% CI, 1.4%-9%), multicentric disease was identified in 4.5% of patients (95% CI, 2%-10.2%), and contralateral disease was identified in 1.8% of patients (95% CI, 0.5%-6.4%).

Figure 2 shows mammographic and MR images from 1 of the study patients. Figure 2a,b shows mediolateral and craniocaudal views of the breast with a clip placed at the mammographically identified lesion at the 6 o'clock position. MRI identified 2 separate lesions 6 mm and 5 mm in size that were separated by 4 cm. Only the most inferior lesion was identified by an experienced radiologist on mammography screening. The second invasive lesion was occult upon examination by diagnostic ultrasound. The MRI sagittal slices show a maximum-intensity projection (MIP) (Fig. 2c) and a DCE subtraction MIP (Fig. 2d). Although the 2 lesions do not appear on the same sagittal slice in the MRI scans, MIPs were used to observe both lesions on a single sagittal image. Finally, Figure 2e shows the mediolateral mammogram that was obtained after MRI-guided wire placement in the mammographically occult, secondary lesion at the 9 o'clock position. These results demonstrate that the secondary invasive lesion would not have been identified without the

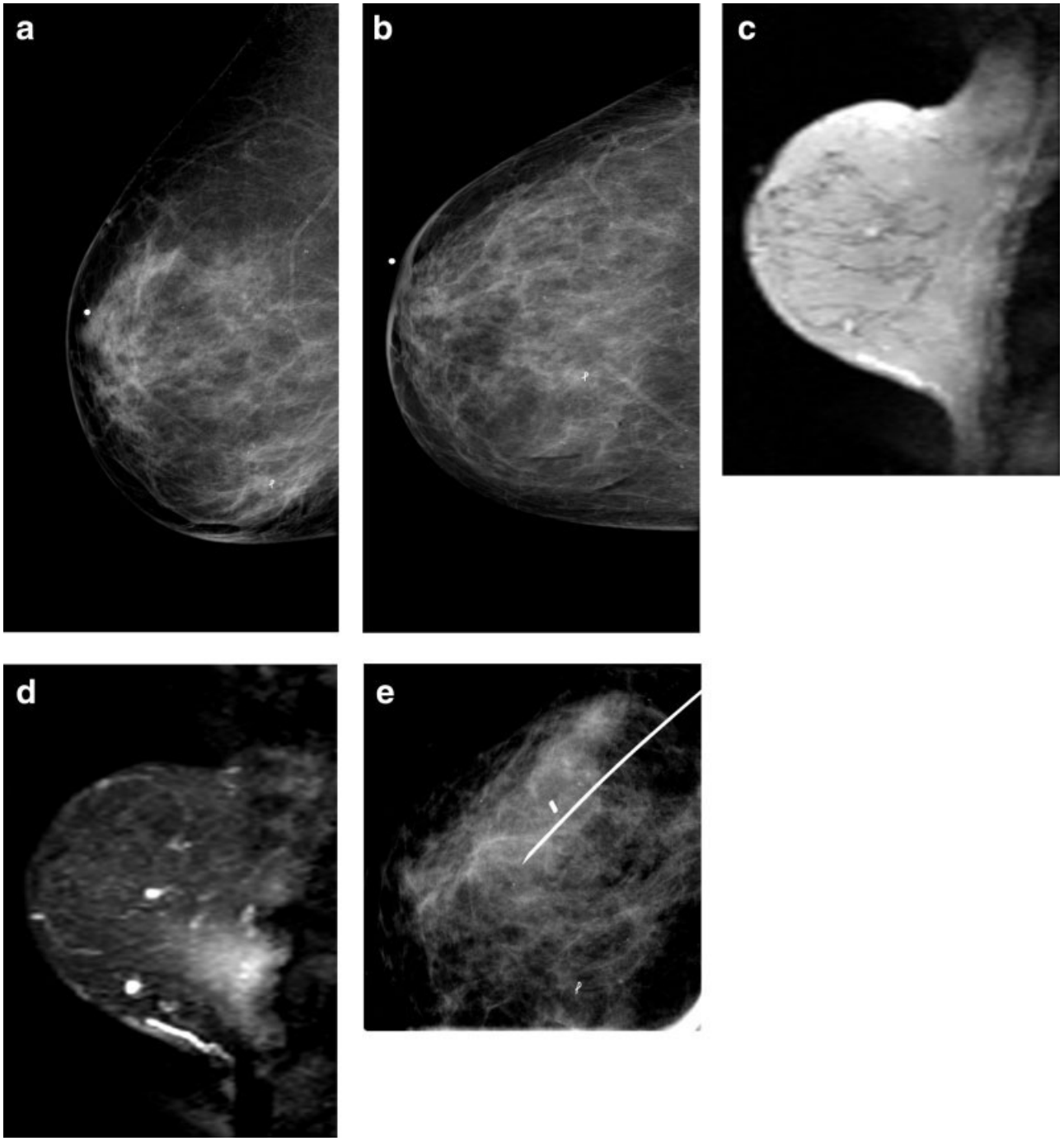

FIGURE 2. Mammographic and magnetic resonance images (MRIs) from a patient who had multicentric disease identified by staging MRI that was mammographically occult. These images show mediolateral (a) and craniocaudial (b) mammograms of the right breast with a clip placed at the site of the suspicious lesion identified before MRI; a maximum-intensity projection, sagittal MRI (c) and a maximum-intensity projection, subtraction MRI (d); and a compression mammographic view after MRI-guided wire placement in mammographically occult secondary invasive lesion (e).

use of MRI and, thus, would not have been included in the PBI volume.

Our study identified a total of 11 patients with additional disease that would have made them ineligible PBI had the lesions been detected with non-MRI methods. Characteristics of these patients and their tumors are included in Table 3. There are no clear criteria based on age, tumor size, lymph node status, tumor hormone status, or the presence of lymphovascular invasion that could be used to eliminate

TABLE 3
Characteristics of Patients Deemed Ineligible for National Surgical Adjuvant Breast and Bowel Project Trial B-39 by Magnetic Resonance Imaging

Patient Age, y	Initial Invasive Tumor Size, cm	Tumor Grade	No. of Positive Lymph Nodes	ER Status	PR Status	HER-2-*neu* Status	LVI	Additional Disease Location	Surgical Management
65	1.5	1	0	Positive	Positive	Negative	Absent	MC	Mastectomy
48	1	2	1	Positive	Positive	Negative	Absent	MC	Mastectomy
45	1.7	2	0	Negative	Negative	Negative	Absent	MF	Lumpectomy
54	1.2	1	0	Positive	Negative	Negative	Absent	C	Lumpectomy
45	2	2	2	Positive	Positive	Negative	Absent	MC	Mastectomy
57	1.8	2	0	Positive	Negative	Negative	Absent	MF	Mastectomy
53	1.5	2	0	Positive	Positive	Negative	Absent	MF	Mastectomy
53	1.8	3	0	Positive	Positive	Unknown	Absent	MF	Mastectomy
70	1.1	2	0	Positive	Negative	Positive	Absent	MC	Lumpectomy
83	2.1	2	1	Positive	Positive	Negative	Absent	C	Lumpectomy
74	0.6	1	0	Positive	Positive	Negative	Absent	MC	Lumpectomy

ER indicates estrogen receptor; PR, progesterone receptor; HER-2-neu, human epidermal growth factor receptor 2; LVI, lymphovascular invasion; MC, multicentric disease, MF, multifocal disease; C, contralateral disease.

these patients from incorrect inclusion in the NSABP B-39 trial. In addition, we used the stricter guidelines (ie, age $\geq$50 years, stage I/II invasive cancers $\leq$3 cm, lymph node negative) outlined by the American Brachytherapy Society for PBI to reanalyze our data. MRI would have rendered the same proportion of patients (7 of 71 patients; 10%) ineligible for PBI. 3D bilateral breast MRI is a straightforward method with which to search for disease elsewhere in the breast before treating patients with limited-field radiation.

MRI altered staging in several patients in this study. For example, the MRI scans from 2 patients correctly identified a single primary lesion that had been identified as 2 separate lesions by mammography. In several patients, MRI identified DCIS out of quadrant or extending from the primary tumor that had not been identified previously by mammography. In addition, MRI identified primary invasive lesions in 3 patients in whom mammography did not detect any mass but merely detected suspicious calcifications.

MRI did prompt biopsies in 5 patients that proved histopathologically negative. Thus, the proportion of patients with false-positive MRIs was 4.5% (95% CI, 2%-10.2%). The positive predictive value (PPV) of a suspicious MRI finding was 72.2% (95% CI, 46.4%-89.3%). This calculation includes 2 additional patients in whom MRI correctly identified additional disease that did not alter PBI eligibility (ie, PPV, 13 of 18 patients). In 5 patients, MRI correctly identified benign lesions, such as fibroadenomas, a papilloma, and an infected cyst, based on imaging characteristics. The proportion of patients who had negative biopsies was 9.1% (95% CI, 3.7%-87.9%) when all 10 patients with negative biopsies were included. Because biopsies were performed nevertheless for presurgical workup in a total of 10 patients, we provide a second PPV estimate factoring this into account: 56.5% (95% CI, 35.9%-77.1%). Had these been the only lesions identified by MRI, the radiologists at our institution would have recommended follow-up MRI at 6 months instead of biopsy. All 5 of these lesions occurred before March, 2005 and would not be biopsied today after our more extensive institutional experience with staging MRI.

DISCUSSION

BCT after surgical quadrantectomy or lumpectomy plus WBI to 50 Gray followed by a 10- to 16-Gray boost to the cavity demonstrated a 94% local tumor control rate at 10 years for patients with stage I and small (<2.5 cm) stage II cancer.[3,15] Our results demonstrate that MRI identified frequent secondary lesions that otherwise were not found by standard screening or clinical examinations (ie, incidental lesions) and that may have been eradicated by WBI. The incidental lesions discovered with MRI in this report would not have been included in either the surgical field or the PBI radiation field. These unresected, unirradiated lesions may increase the ipsilateral tumor recurrence rate and complicate the analysis of PBI trials like NSABP B-39. Although the clinical significance of such lesions is unclear, we suspect that few surgeons or radiation/medical oncologists would advocate not treating gross disease. In fact, our data provide evidence that ipsilateral 'recurrences' away from the tumor bed, even after WBI, simply may represent incidental lesions that were present at the time of initial diagnosis. In general, the ability of WBI to sterilize unidentified

disease elsewhere in the breast decreases as the incidental lesion size increases. Because MRI can detect tumors less than 1 cm with greater sensitivity than mammography or ultrasonography,[16] MRI could ensure PBI ipsilateral tumor control rates similar to those of patients receiving WBI. Our data suggest that MRI should be considered strongly for assessing PBI eligibility to minimize out-of-field failures.

This was a retrospective study and, thus, had certain limitations. Patients with a primary diagnosis of DCIS and patients with incomplete or indeterminate pathology reports were excluded from the study. No multivariate analysis was performed on these data because of the limited number of events and the relatively small study population. Our study demonstrated that approximately 33% of all cancer patients at our institution may be eligible for PBI according to the NSABP B-39 trial criteria. Increasing the total number of patients in this analysis to provide enough statistical power for multivariate analysis would require a multi-institution study. It should be acknowledged that the clinical significance of detecting additional lesions with MRI is not clear. For example, these lesions may have an indolent behavior, making the clinical value of their detection minimal. Second, it is not known whether the radiation dose given with WBI would be sufficient to control or delay the clinical detection of such lesions. Both factors would lead to an overestimation of the ability of MRI to reduce ipsilateral tumor recurrence in patients undergoing PBI compared with WBI.

Because of the retrospective nature of the current study, these data represent a minimum of multifocal and multicentric disease that exists in the population that is eligible for PBI or WBI. Concordant results have been produced in pathology studies,[17] which identified disease 3 to 4 cm away from the primary tumor in 7% to 8% of mastectomy specimens. Other investigators[18–20] have demonstrated that MRI detects incidental lesions at a 6% to 11% higher rate than standard screening, diagnostic, and clinical examinations. Our results suggest that 3D image guidance, such as MRI, should be considered to assess PBI eligibility to minimize long-term, out-of-quadrant failures and to give PBI clinical trials more power to succeed.

REFERENCES

1. Fisher B, Anderson S, Bryant J, et al. Twenty-year follow-up of a randomized trial comparing total mastectomy, lumpectomy, and lumpectomy plus irradiation for the treatment of invasive breast cancer. *N Engl J Med*. 2002;347:1233-1241.
2. Veronesi U, Cascinelli N, Mariani L, et al. Twenty-year follow-up of a randomized study comparing breast-conserving surgery with radical mastectomy for early breast cancer. *N Engl J Med*. 2002;347:1227-1232.
3. Veronesi U, Marubini E, Mariani L, et al. Radiotherapy after breast-conserving surgery in small breast carcinoma: long-term results of a randomized trial. *Ann Oncol*. 2001;12:997-1003.
4. Punglia RS, Morrow M, Winer EP, Harris JR. Local therapy and survival in breast cancer. *N Engl J Med*. 2007;356:2399-2405.
5. Ragaz J, Olivotto IA, Spinelli JJ, et al. Locoregional radiation therapy in patients with high-risk breast cancer receiving adjuvant chemotherapy: 20-year results of the British Columbia randomized trial. *J Natl Cancer Inst*. 2005;97:116-126.
6. Vicini FA, Kestin L, Huang R, Martinez A. Does local recurrence affect the rate of distant metastases and survival in patients with early-stage breast carcinoma treated with breast-conserving therapy? *Cancer*. 2003;97:910-919.
7. Clarke M, Collins R, Darby S, et al. Effects of radiotherapy and of differences in the extent of surgery for early breast cancer on local recurrence and 15-year survival: an overview of the randomised trials. *Lancet*. 2005;366:2087-2106.
8. Morrow M, White J, Moughan J, et al. Factors predicting the use of breast-conserving therapy in stage I and II breast carcinoma. *J Clin Oncol*. 2001;19:2254-2262.
9. Vaidya JS, Tobias JS, Baum M, et al. Intraoperative radiotherapy for breast cancer. *Lancet Oncol*. 2004;5:165-173.
10. Esserman L, Hylton N, Yassa L, Barclay J, Frankel S, Sickles E. Utility of magnetic resonance imaging in the management of breast cancer: evidence for improved preoperative staging. *J Clin Oncol*. 1999;17:110-119.
11. Van Goethem M, Tjalma W, Schelfout K, Verslegers I, Biltjes I, Parizel P. Magnetic resonance imaging in breast cancer. *Eur J Surg Oncol*. 2006;32:901-910.
12. Newstead GM. MR imaging in the management of patients with breast cancer. *Semin Ultrasound CT MR*. 2006;27:320-332.
13. Lalonde L, David J, Trop I. Magnetic resonance imaging of the breast: current indications. *Can Assoc Radiol J*. 2005; 56:301-308.
14. Wilson EB. Probable inference, the law of succession, and statistical inference. *J Am Stat Assoc*. 1927;22:209-212.
15. Bartelink H, Horiot JC, Poortmans PM, et al. Impact of a higher radiation dose on local control and survival in breast-conserving therapy of early breast cancer: 10-year results of the randomized boost versus no boost EORTC 22881–10882 trial. *J Clin Oncol*. 2007;25:3259-3265.
16. Gibbs P, Liney GP, Lowry M, Kneeshaw PJ, Turnbull LW. Differentiation of benign and malignant sub-1 cm breast lesions using dynamic contrast enhanced MRI. *Breast*. 2004;13:115-121.
17. Holland R, Veling SH, Mravunac M, Hendriks JH. Histologic multifocality of Tis, T1–2 breast carcinomas. Implications for clinical trials of breast-conserving surgery. *Cancer*. 1985;56:979-990.
18. Berg WA, Gutierrez L, NessAiver MS, et al. Diagnostic accuracy of mammography, clinical examination, US, and MR imaging in preoperative assessment of breast cancer. *Radiology*. 2004;233:830-849.
19. Schnall MD, Blume J, Bluemke DA, et al. MRI detection of distinct incidental cancer in women with primary breast cancer studied in IBMC 6883. *J Surg Oncol*. 2005;92:32-38.
20. Lehman CD, Gatsonis C, Kuhl CK, et al. MRI evaluation of the contralateral breast in women with recently diagnosed breast cancer. *N Engl J Med*. 2007;356:1295-1303.