Seminars in Pediatric Surgery (2010) 19, 96-106



ELSEVIER

SEMINARS IN PEDIATRIC SURGERY

# Transanal endorectal pull-through for Hirschsprung disease: technique, controversies, pearls, pitfalls, and an organized approach to the management of postoperative obstructive symptoms

**Luis De La Torre, MD,[a] Jacob C. Langer, MD[b]**

*From the [a]Universidad Nacional Autónoma de México, Department of Surgery, Hospital para el Niño Poblano and Hospital Angeles Puebla, Puebla, Mexico; and the*
*[b]Department of Surgery, Hospital for Sick Children, Toronto, Ontario, Canada.*

**KEYWORDS**
Soave;
Swenson;
Transanal pull-through;
Perineal pull-through;
Enterocolitis;
Botulinum toxin;
Internal sphincter achalasia

The transanal endorectal pull-through emerged in the late 1990s as the most recent step in the evolution of the surgical correction of Hirschsprung disease. This operation provides the advantages of a minimal access approach with shorter hospital stay, shorter time to full feeding, less pain, and improved cosmesis with excellent outcomes. This article will review the technical principles of the transanal endorectal pull-through, and will address ongoing controversies in the application of this technique. We will also discuss an organized approach to the problem of obstructive symptoms that may affect a subgroup of patients after the transanal pull-through.
© 2010 Elsevier Inc. All rights reserved.

Swenson first described definitive surgical management of neonates and infants with Hirschsprung disease in the late 1940s. Because these children often presented with severe malnutrition or enterocolitis, a preliminary colostomy was usually done, followed by a pull-through procedure many months later. Earlier recognition and diagnosis of the disease led a number of surgeons in the 1980s to report series of single-stage pull-through procedures even in small infants, using each of the 3 common operations (Swenson, Duhamel, and Soave). Since then, one-stage operations have become increasingly popular and many reports have suggested that this approach is safe, cost-effective, and avoids the morbidity of stomas in infants.[1]

In the early 1990s, Georgeson et al[2] described a minimal access approach, consisting of a laparoscopic biopsy to identify the transition zone, laparoscopic mobilization of the rectum below the peritoneal reflection, and a short endorectal mucosal dissection from below. The anastomosis was done from below after prolapsing and excising the rectum. Multiple reports documented a short time in the hospital, and early results were equivalent to those reported for the open procedures. Subsequently, laparoscopic approaches have been described for the Duhamel and Swenson operations,[3,4] with excellent short-term results reported.

The transanal Soave procedure represented a natural evolution from the laparoscopic operation. Transanal resection of the rectum was shown to be possible in an animal model, and initial series of children with Hirschsprung disease were

**Address reprint requests and correspondence:** Luis De La Torre, MD, Universidad Nacional Autónoma de Mexico, Hospital para el Nino Poblano and Hospital Angeles Puebla, Av Kepler No. 2143, Cons. 215, Col. Reserva Territorial Atlixcayotl, Puebla 72190, Mexico.
E-mail address: cirugia.pediatrica@mac.com.

1055-8586/$ -see front matter © 2010 Elsevier Inc. All rights reserved.
doi:10.1053/j.sempedsurg.2009.11.016

published by de la Torre and Ortega-Salgado[5] and Langer et al[6] in the late 1990s. The transanal approach has the principal benefit of avoiding the need for intra-abdominal mobilization of the rectum through either laparotomy or laparoscopy. Several studies have demonstrated that the transanal approach is associated with less pain, shorter hospital stay, and a better cosmetic result than open surgery.[7-9] There have not been any studies comparing the transanal to the laparoscopic approach. However, the transanal pull-through can be done by any pediatric surgeon, including those without laparoscopic skills, and by pediatric surgeons in parts of the world where access to appropriately miniaturized laparoscopic equipment is limited.[10]

This article will review preoperative considerations before performing the transanal pull-through, technical aspects of the operation, pitfalls and pearls the authors have learned, and ongoing controversies. We will also present an organized approach to the common problem of obstructive symptoms after the transanal pull-through.

## Preoperative considerations

Hirschsprung disease may present as neonatal intestinal obstruction, as constipation in an older child, or less commonly with primary enterocolitis. In the neonate, Hirschsprung disease must be differentiated from other causes of intestinal obstruction, including meconium ileus, intestinal atresia, anorectal malformation, malrotation, and congenital bands. Careful history and physical examination, abdominal radiogarph, and water-soluble contrast enema are the initial diagnostic maneuvers in most cases. The definitive diagnosis of Hirschsprung disease is either made or excluded on the basis of a suction rectal biopsy, looking for the presence or absence of ganglion cells and of hypertrophic nerves. Some pathologists also use cholinesterase staining to complement the standard histologic evaluation. The biopsy must not be taken too close to the pectinate line, because there is normally a paucity of ganglion cells in this location.[11] It is also important to initiate early resuscitation in infants with intestinal obstruction or enterocolitis, including the administration of intravenous fluids and antibiotics, and a nasogastric tube. Early decompression of the colon using digital rectal stimulation and/or irrigations through a rectal tube is important to prevent and treat enterocolitis and to decrease the diameter of the colon. Children with associated abnormalities, such as cardiac disease or congenital central hypoventilation syndrome, must have these problems dealt with before definitive surgical repair. After the child has been stabilized, the definitive surgical procedure can be done semielectively. During the waiting period, most children can be fed breast milk or an elemental formula, in combination with rectal stimulations or irrigations. Those who cannot tolerate oral or nasogastric feeding can be nourished with parenteral nutrition.

In the older child who presents with severe constipation, a suction biopsy is less likely to give the pathologist enough submucosa to make the diagnosis. In these children a deep or full-thickness biopsy must be done, usually under general anesthesia. In some centers, anorectal manometry is also used as a screening test, because the presence of a rectoanal inhibitory reflex effectively rules out the diagnosis of Hirschsprung disease. Absence of a recto-anal inhibitory reflex must be followed by a rectal biopsy to confirm the diagnosis, as there is a significant false-positive rate for this test. Older children who present with an extremely dilated colon may require weeks or months of irrigations to bring the colon to a more normal size before the definitive surgical procedure, and in some children with particularly dilated or thickened proximal colon, a preliminary colostomy may be necessary to achieve adequate decompression.

Most children with Hirschsprung disease have a contrast enema done as part of the diagnostic workup, looking for the presence and location of a radiological transition zone. However, many studies have documented that a maximum of 10% of neonates with Hirschsprung disease will not have a transition zone on contrast enema.[12] In addition, older children with a very short aganglionic segment may not demonstrate a transition zone on contrast enema, particularly if the catheter has been placed above the transition zone in the rectum. Finally, the contrast study is not always completely accurate in identifying the location of the pathologic transition zone, with 12% of cases having a pathologic transition zone which is different from the radiological transition zone.[13] It may be possible to increase the accuracy of the contrast enema in identifying the transition zone in older children by waiting until histopathological confirmation of the disease is available, and discontinuing the rectal irrigations for 1-3 days before performing the contrast enema. It is also important to recognize that the lateral projection is better than the anteroposterior view in identifying a rectal or rectosigmoid transition zone (Figure 1).

## Surgical technique

### Basic principles of the operation

After induction of anesthesia, before beginning the operation, a single shot caudal block should be placed to minimize the need for anesthetic agents. We routinely repeat the block again at the end of the procedure to provide early postoperative pain relief. All patients should receive prophylactic antibiotics, such as cefoxitin to cover Gram-negative bacilli and colonic anaerobes.

The operation starts with a mucosal incision above the dentate line. The distance above the dentate line depends on the surgeon and the size of the child, but it is crucial that the incision be high enough above the dentate line so that the transitional epithelium is not damaged. This is important to prevent loss of sensation, which may predispose the child to long-term problems with incontinence.

Fine silk sutures are placed in the mucosa, either before or after the mucosal incision, to provide traction on the

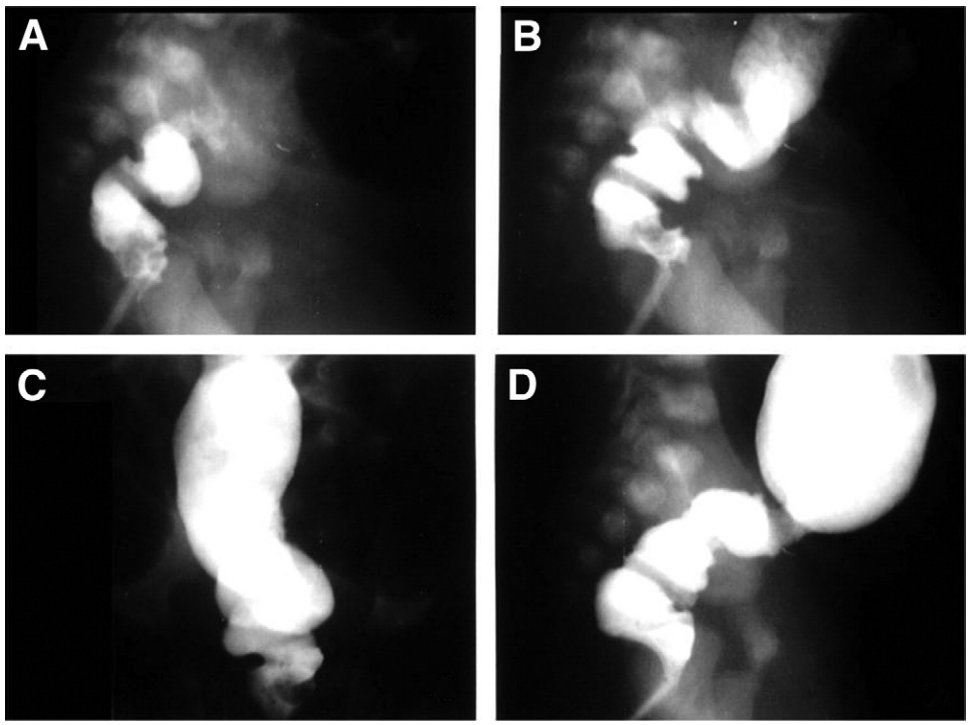


**Figure 1** (A) Rectogram of a histological-confirmed case of Hirschsprung disease showing a fluoroscopic lateral view starting instillation of the water-soluble contrast solution. (B) Lateral view showing how the dilated sigmoid is being initially filled. (C) Frontal view shows a dilated loop, but the transition zone cannot be defined in this view. (D) Radiological transitional zone is clearly demonstrated in the lateral view. This projection is more useful than the AP view in short segment Hirschsprung disease.

mucosal edge during the mucosal dissection. The mucosa is stripped from the underlying muscle for a variable distance, initially using electrocautery with a fine-tipped needle, and subsequently using blunt dissection. After the mucosal dissection has been completed, the rectal muscle is incised circumferentially, permitting the dissection to continue proximally along the rectal wall. It is important that the vessels be divided just as they enter the bowel wall, to avoid injury to pelvic nerves and vessels, as well as the prostate or vagina. It is also very important to avoid twisting of the bowel as the dissection progresses proximally. This can be accomplished by holding the rectum with a curved clamp, making sure that the orientation of the clamp does not change. When the normally innervated bowel is reached, the bowel is divided a variable distance above the transition zone, and the anastomosis is performed. Most surgeons use braided absorbable suture material for the anastomosis. The sutures should include a generous bite of the pull-through colon, as well as substantial bite of underlying muscle and a small bite of distal mucosa. Once again, care must be taken not to include the dentate line in the sutures, as this will produce more pain, and may compromise later continence.

The transanal technique is summarized in Figure 2.

For children with a transition zone that is more proximal than the midsigmoid colon, there is usually not enough length to bring it down without some mobilization of at least the descending colon, and in some cases the splenic flexure. This can be done either laparoscopically or through an umbilical incision. If the transition zone is at or proximal to the splenic flexure, it is usually also necessary to divide the middle colic vessels, leaving a generous arcade of marginal vessels along the colon, so as to achieve adequate length without undue tension (Figure 3).

## Ongoing controversies, pearls, and pitfalls

### Age at pull-through

Some surgeons prefer to wait until the child is a few months old before doing the procedure, and the child is discharged home on rectal stimulation and/or rectal irrigations while waiting. There are several expressed reasons for this, such as a feeling that the operation will be easier with better visualization, a hope that the dilated proximal colon will decrease in size, and in some cases a practical issue of operating room time availability. The primary danger of this approach is the possibility of the child developing enterocolitis during the waiting period. This risk can be minimized by ensuring adequate decompression of the rectum, the administration of prophylactic metronidazole or probiotics, and the use of breastfeeding or elemental infant formula. Many pediatric surgeons have now realized that the transanal pull-through can be successfully and safely performed as soon as the diagnosis is made, even in small newborns. The success of the procedure lies in magnification with loupes, meticulous dissection, and the fact that the neonatal pelvis is very shallow.

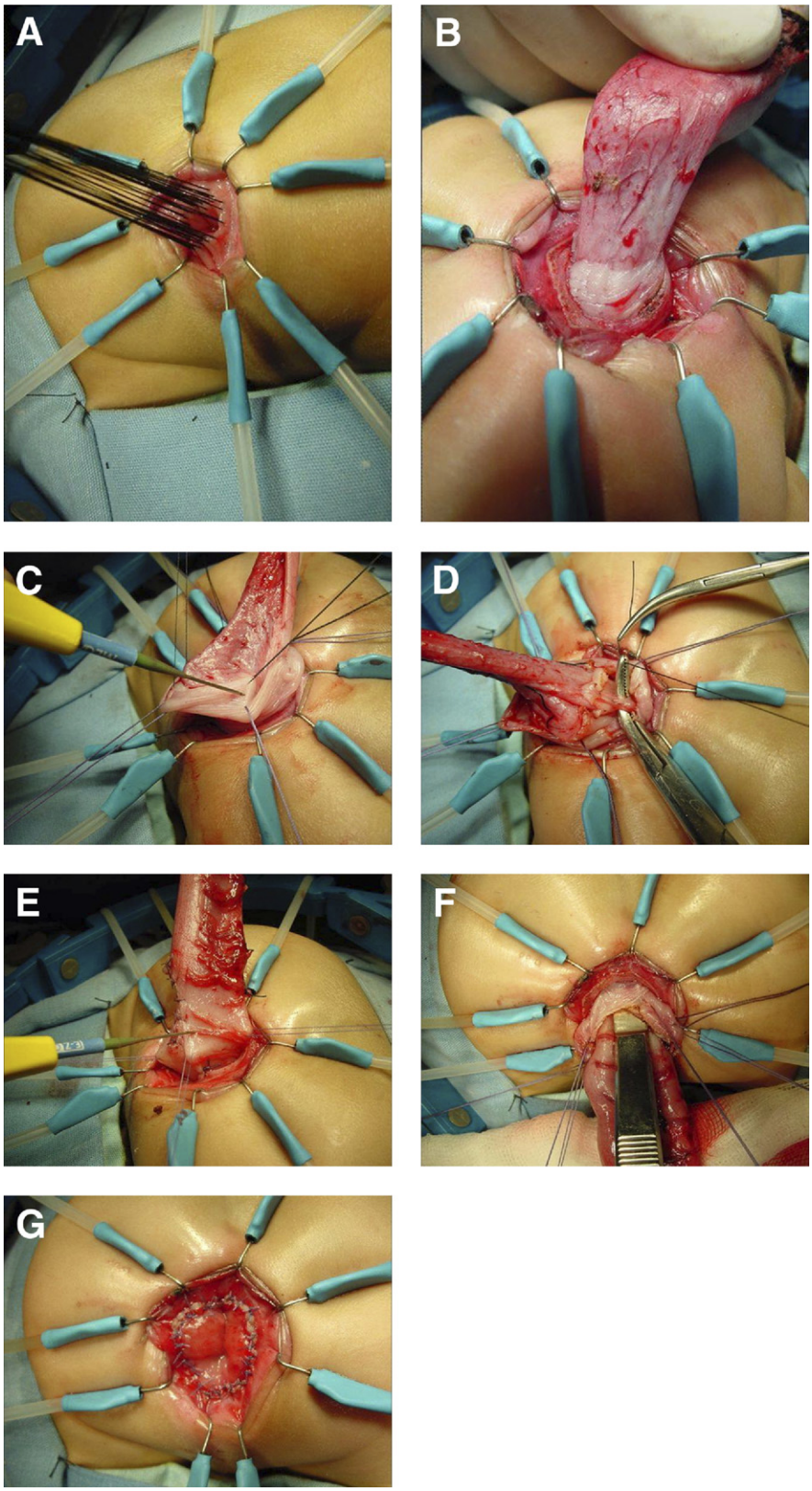


**Figure 2** Transanal technique. These examples are from a case done in the prone position. (A) The Lonestar retractor has been used to demonstrate the dentate line, and sutures have been placed in anticipation of a mucosal incision 0.5-1 cm above the dentate line. (B) Submucosal dissection has been done. (C) The rectal muscle cuff is being incised. (D) The dissection has been continued along the outside of the rectal wall, taking vessels as they enter the rectal wall using cautery or ties. (E) A biopsy has been done from the dilated rectum above the presumed transition zone. The biopsy should be full-thickness so the pathologist has the best chance possible to make an accurate diagnosis on frozen section. (F) The rectal muscle cuff has been split in the posterior midline. This step is not necessary if a very short cuff is used. (G) The rectum has been amputated and the anastomosis has been completed. (Color version of figure is available online.)

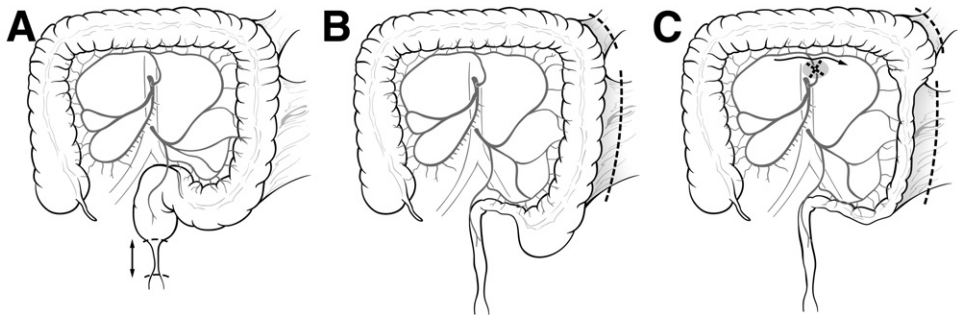


**Figure 3** Mobilization of the colon for children with a more proximal transition zone. (A) For children with a transition zone in the rectum or sigmoid colon, no proximal mobilization is usually required. (B) If the transition zone is in the proximal sigmoid or descending colon, dividing the lateral attachments of the descending colon, with or without taking down the splenic flexure, is necessary. (C) For a transition zone at or just proximal to the splenic flexure, the flexure must be taken down and the middle colic vessels divided, making sure that the marginal vessel are preserved.

### Use of a colostomy and performance of the operation in a patient with a preexisting colostomy

Although most pediatric surgeons have now abandoned the routine use of a colostomy, there are still some children in whom a colostomy should be considered. Probably the most common scenario in which this would be appropriate is the child who presents with enterocolitis. Enterocolitis must be treated aggressively with antibiotics, fluid resuscitation, and rectal irrigations. Those patients in whom sepsis continues despite nonoperative measures should have a stoma created. Those who respond successfully to nonoperative treatment can undergo a one-stage pull-through as soon as the child is completely stable. The threshold for creating a colostomy varies from surgeon to surgeon.

Other patient-related indications for a stoma include presentation with intestinal perforation, malnutrition, or massively dilated proximal bowel. In addition, some surgeons work in an environment where there is inadequate pediatric pathology support to reliably identify the transition zone on frozen section. In this situation, there are 2 choices. The surgeon can do multiple biopsies laparoscopically or through a small incision, and wait for the final results before going back for a second anesthetic to do the definitive pull-through, or a colostomy can be done.

For those children who require a stoma, or those who have a routine stoma done by another surgeon, a transanal approach to the pull-through procedure can still be accomplished. The colostomy and mucous fistula (if it is a divided stoma) are taken down first, and the mesenteric vessels to the distal bowel can be divided through the colostomy site. The transanal dissection is then carried out as described previously, and the distal bowel removed through the anus. The colostomy is then grasped with an instrument that is passed transanally, and pulled down for the anastomosis.

Some surgeons choose to perform a proximal colostomy in the right transverse colon in every case of Hirschsprung disease, without "leveling" biopsies. The rationale for this is that the colostomy will function even if the transition zone is proximal to the stoma, and this is therefore the safest approach in centers where there is inadequate pediatric pathology support. However, a transanal approach to the pull-through can still be used, leaving the colostomy intact, if there is enough length. If the colostomy results in too much tension, the surgeon has 3 options: (1) use the right-sided colostomy as the bowel to be pulled through; (2) close the colostomy and perform a loop ileostomy; or (3) close the colostomy without defunctioning. If the latter choice is made, the surgeon might consider using a Duhamel rather than a transanal approach, because the incidence of anastomotic narrowing and stricture, and therefore the risk of leak from the colostomy closure, is lower.

### The use of a preliminary biopsy prior to beginning the anal dissection

Most surgeons suspect the most likely location of the transition zone is based on the contrast enema, as well as on the acuity and severity of the patient's symptoms. However, as mentioned earlier, the contrast study is not always completely accurate, and some surgeons therefore prefer to obtain pathologic confirmation of the transition zone before beginning the anal dissection. This approach is particularly useful for those surgeons who would prefer to do a Duhamel rather than a Soave or Swenson procedure if the child has long-segment disease.

The preliminary biopsy can be done laparoscopically or through an umbilical incision (Figure 4). The advantage of the umbilical approach is that it can be done by any surgeon, anywhere in the world, regardless of ability or access to neonatal laparoscopy.[14] The use of a preliminary biopsy does not change the outcome of the transanal pull-through in terms of times to feed, amount of pain, or length of hospital stay.[15]

### Prone vs lithotomy position

Advocates of the prone position argue that the mesenteric vessels can be observed and controlled more effectively. Most pediatric surgeons are also comfortable with the prone position, as the same position is used for the posterior sagittal approach to anorectal malformations. The

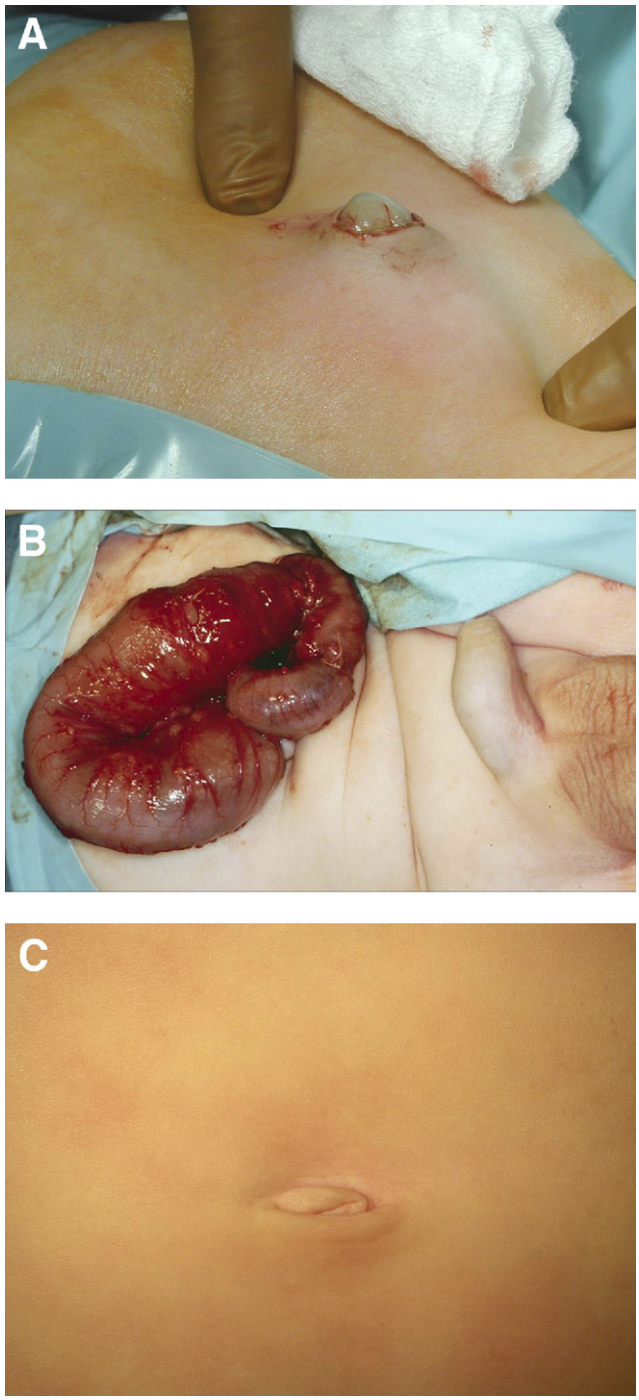


**Figure 4** An umbilical incision can be used to access the entire abdomen in a neonate. (A) A Hager dilator placed through the anus can be used to push the sigmoid colon out through the incision for preliminary biopsies. (B) The splenic flexure can be mobilized, as can the hepatic flexure in cases of long segment disease. (C) The late cosmetic appearance is excellent. (Color version of figure is available online.)

disadvantage of the prone position is that it does not permit access to the abdominal cavity, unless the patient is subsequently turned into the supine position. The lithotomy position allows for preliminary biopsy, as well as mobilization of the left colon or splenic flexure, and the creation of a stoma if necessary.

### Use of retractors

There are several options for everting the anus at the time of the mucosal dissection. Many surgeons use an automatic retractor, such as the Lonestar, which uses multiple small hooks attached to a plastic ring. This provides excellent visualization of the anal canal and dentate line, and placing the hooks just proximal to the dentate line effectively "hides" the dentate line so that it cannot be injured. In small babies, however, the Lonestar retractor can easily tear the fragile tissue around the anus, and many surgeons prefer to place sutures to Evert the anus.

Although some surgeons routinely use retractors in the anal sphincter during the mucosal dissection, this practice is to be condemned because it may cause damage to the sphincter mechanism which can result in long-term incontinence.[16] A nasal speculum can be gently used to initially visualize the mucosa, without the need for stretching of the sphincter. During the dissection, the surgeon should use fine sutures on the proximal edge of the mucosa to pull the bowel down, so that most of the dissection is done outside the anus without the need for retraction. Attention to these fine details is important so as to avoid long-term continence issues from sphincter injury during the operation.

### How high above dentate line should the dissection start

As a basic principle, the anastomosis should be low enough so that there is no significant residual aganglionic segment that may result in persistent obstructive symptoms after the operation. By contrast, the anastomosis must be high enough above the dentate line so that normal sensation is not interfered with. The age and size of the child is also a factor, with most surgeons starting the dissection somewhat higher in older children than in neonates. Most opinions range from 0.5 to 1.0 cm above the dentate line in a newborn, and 1.0-2.0 cm above the dentate line in an older child.[17]

### Length of the rectal cuff

In the original descriptions of the transanal pull-through procedure, the mucosal dissection was carried to a point above the peritoneal reflection, to ensure that there was no injury to pelvic structures. Using this technique, the rectal cuff is quite long, and most authors advocate dividing or excising a part of the cuff to prevent it from rolling down and forming a constricting ring around the pull-through bowel. Although many surgeons continue to leave a long rectal cuff, others have moved to a much shorter cuff.[18] In this modification of the technique, a short mucosal dissection is done for 1.0-3.0 cm, and the rectal wall is then incised circumferentially. With a very short cuff, the muscle does not need to be incised in most cases. Some surgeons have eliminated the mucosal dissection entirely, and performed a transanal Swenson procedure.[19] The advantage of leaving a short cuff or no cuff is the avoidance of a con-

stricting ring or residual aganglionic bowel, with a lower risk of obstruction and enterocolitis.[15] The disadvantage is that dissection on the outside of the rectum deep in the pelvis may increase the risk of injury to pelvic nerves and vessels, and to the prostate, urethra, or vagina.

### How much of the ganglionated bowel should be resected

The bowel is divided and the anastomosis performed using colon which has been proven to contain ganglion cells by frozen section, either before beginning the anal dissection or during the transanal resection of the colon. Often this ganglionated bowel is grossly dilated or thickened, and some surgeons choose to resect it back to more normal-appearing bowel. This decision is based on the theory that dilated bowel does not have normal motility, and will not function as well as the bowel that has a more normal caliber. In addition, it has been shown that the transition zone is not symmetric around the circumference of the colon. Resecting some of the bowel proximal to the positive biopsy therefore ensures that the transition zone will not be used in the anastomosis.[20] Recommendations in the published data range from 1-2 cm to 10-15 cm above the normal biopsy.[21]

## Postoperative care

Intestinal activity is usually normal after a transanal pull-through procedure, and most infants have bowel movements during the first 24 hours after surgery. Oral feeding can be started as soon as the child starts to pass stools, assuming that the abdomen is not distended. Most children do not require narcotics for pain, as long as regional anesthesia has been used (a caudal block and infiltration of the umbilical or laparoscopic wounds). Oral acetaminophen is sufficient in most cases.

At least 50% of children develop perianal dermatitis because of frequent bowel movements and liquid discharge during the initial months after a transanal pull-through operation. It is important to prevent this as much as possible by immediate application of barrier creams, and in some cases antidiarrhea medication. Both the frequency of stools and the perineal excoriation usually settle down within several weeks to months postoperatively.

There is a controversy about the need for daily rectal dilatations after a transanal pull-through procedure. Most surgeons wait 1-2 weeks, and then calibrate the anastomosis with a dilator or finger, depending on the size of the child. Some then teach the parents to do daily dilatations for a maximum of 6 months postoperatively. Others see the child weekly for 6 weeks, calibrating the anastomosis each week, and proceeding to daily dilatations only if there is evidence of anastomotic or cuff narrowing.

The most important and dangerous complication after a pull-through procedure is enterocolitis, because it is the most common cause of death in children with Hirschsprung disease.[22] It is extremely important that both the parents and the community pediatrician responsible for the follow-up of the patient be educated as to the signs and symptoms of enterocolitis, and that they bring the child to medical attention early if any of those clinical features occur. Many preventive measures have been described, including routine postoperative irrigations or rectal stimulation,[23] the use of antibiotics, such as metronidazole, and the use of probiotics.[24] The latter is currently the subject of a prospective randomized trial.

## Investigation and management of postoperative problems

All children with Hirschsprung disease are at risk for postoperative incontinence, enterocolitis, and obstructive symptoms, regardless of which operation is performed. Every child should therefore be followed up on a regular basis until at least the age of 5 years, or longer if they are still having problems at that point. The management of incontinence and enterocolitis are dealt with in other contributions in this issue; this section will outline the investigation and management of the child who has persistent obstructive symptoms after a transanal pull-through procedure.

### Definition and incidence of obstructive symptoms

Obstructive symptoms may take the form of abdominal distension, bloating, borborygmi, vomiting, or ongoing severe constipation. Some children will also have fever with these episodes, suggesting that an element of enterocolitis may be present. Many children with obstructive symptoms will not pass stools without assistance, using either rectal stimulation or irrigations, and when this is done the stools are often foul-smelling, “squirty,” or explosive in nature. Many of these children have postoperative symptoms that are identical to their initial presenting symptoms. The timing of obstructive symptoms also varies. In some cases, the child will have a good response to the surgical procedure and then develop obstructive symptoms later, and in other cases the child may not have any improvement in the postoperative period.

The incidence of obstructive symptoms varies in the published data, depending on how they are defined and how closely the authors are looking for them. Most of the older series probably underestimated the incidence. Recent series report an incidence of 8%-30%.[25] Obstructive symptoms are probably more common in children with Down syndrome. Children with long-segment disease seem to have a higher incidence of distension, vomiting, and enterocolitis, but a lower incidence of constipation. Obstructive symptoms may also be associated with incontinence in some children.

**Table 1** Causes of obstructive symptoms after a pull-through for Hirschsprung disease

| |
|---|
| Mechanical obstruction |
| Recurrent or acquired aganglionosis |
| Motility disorder in the proximal bowel |
| Internal sphincter achalasia |
| Functional megacolon |

## Causes of obstructive symptoms

The 5 major reasons for persistent obstructive symptoms after a pull-through procedure are listed in Table 1. These include mechanical obstruction, recurrent or acquired aganglionosis, disordered motility in the proximal colon or small bowel, internal sphincter achalasia, or functional megacolon caused by stool-holding behavior.[26]

### Mechanical obstruction

Mechanical obstruction may be the result of an anastomotic stricture (Figure 5). It may also be due to "rolling down" of the rectal muscular cuff after a transanal Soave procedure. This may occur even if the cuff has been divided, and is less likely if a short cuff is made.[15] These complications are identifiable by a combination of digital rectal examination and contrast enema.

Many strictures and cuff-related narrowing can be managed using repeated dilatations, particularly if the problem is identified early in the postoperative period. If dilatation from below is impossible because the problem is too high or too narrow, an antegrade approach using Tucker dilators may permit safer and more effective dilatation;[27] however, this approach requires the creation of a colostomy. If dilatation is unsuccessful, the child may require revision of the pull-through operation.[28]

Occasionally, the pulled-through bowel can become twisted during the operation, which will result in partial or complete obstruction (Figure 6). This is usually recognized early postoperatively, and usually requires surgical revision. Obstructive symptoms can also be caused by small bowel obstruction because of peritoneal adhesions, and can occur many years after the initial surgical procedure. This complication appears to be more common after open pull-through operations than after a transanal or laparoscopic procedure. The diagnosis can be made based on observing dilated bowel loops with air-fluid levels on plain abdominal radiographs, and in some cases where the obstruction is intermittent or partial, a contrast study with small bowel follow-through may be helpful.

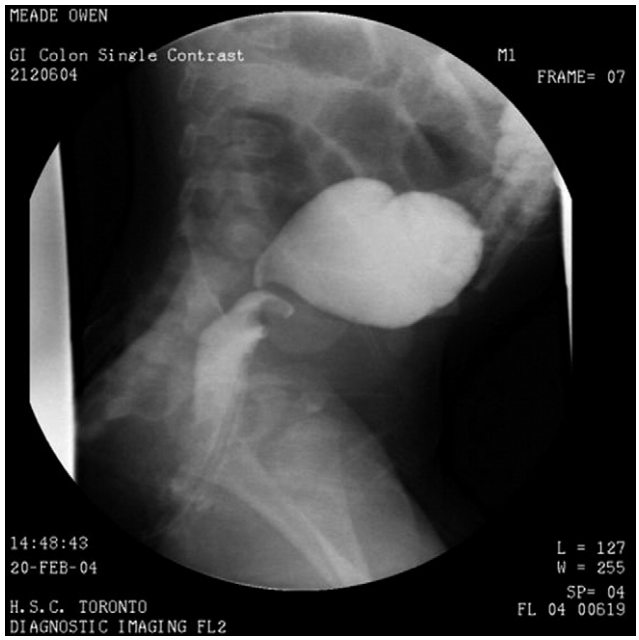


**Figure 6** Contrast enema showing twisting of the colon after a transanal pull through. This complication almost always requires revision of the pull through.

### Persistent or acquired aganglionosis

Some children may develop persistent obstructive symptoms as a result of aganglionosis after a pull-through pro-

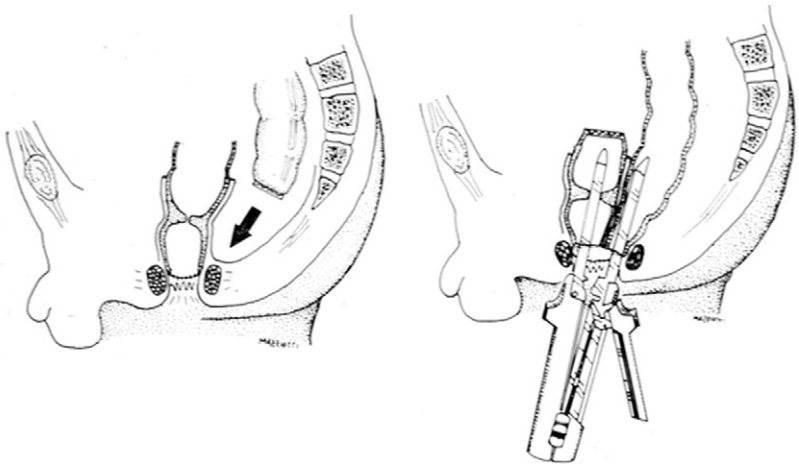

**Figure 5** Revisional surgery using the Duhamel technique for the treatment of a recalcitrant stricture after a transanal pull-through.

cedure. This may be due to pathologist error,[29] or a pull-through which has been done using the transition zone rather than normally innervated bowel. It has been shown that the transition zone is often asymmetrical,[20] and most surgeons advocate removing at least several centimeters of bowel proximal to their positive biopsy to avoid this problem. In other children, there are clearly normal ganglion cells at the proximal resection margin, but the child subsequently "loses" the ganglion cells.[30] Some children may have acquired aganglionosis associated with a stricture because of poor blood supply and/or tension at the initial anastomosis. Although this problem is relatively rare, it is imperative to perform a biopsy of the pulled-through bowel segment above the anastomosis to determine whether there are normal ganglion cells present in any child with persistent obstructive symptoms.

Most children with persistent or acquired aganglionosis should undergo a repeat pull-through procedure. It is important to document the level of aganglionosis first at laparotomy or using a laparoscopic approach. The pull-through operation can be done using a Swenson, Soave, or Duhamel approach, either open, laparoscopically, or transanally.[31] Some authors have advocated simple anal sphincter myectomy for this problem, especially if the aganglionic segment is short.

### Motility disorder

It is well recognized that children with Hirschsprung disease may have associated motility disorders in the proximal bowel that contains ganglion cells. This problem may be either focal (usually involving the left colon) or diffuse. In some cases the abnormal motility may be associated with histologic abnormalities, such as intestinal neuronal dysplasia, and in some children the histology may be completely normal. In children who have been shown not to have a mechanical obstruction and who have normal ganglion cells on rectal biopsy, investigations for motility disorders should be undertaken. Options include a radio-opaque marker transit study, nuclear colonic motility scan,[32] colonic manometry,[33] and laparoscopic full-thickness biopsies looking for intestinal neuronal dysplasia.[34] In children who have a chronically distended or thickened colon, investigations to identify a motility disorder may produce false positive results. In this situation, it is usually best to do a defunctioning stoma initially, and to do the motility investigation after at least 6 months of decompression.

If a focal motility disorder is found, resection and a repeat pull-through procedure using normal bowel should be considered. If the abnormality is diffuse, there is no role for resection, and the options include bowel management, prokinetic agents, or in severe cases, ileostomy.

### Internal sphincter achalasia

All children with Hirschsprung disease lack a recto-anal inhibitory reflex, and therefore cannot relax their internal anal sphincter. Most are able to overcome this nonrelaxation and achieve normal defecatory function, but in some children sphincter nonrelaxation may result in or contribute to persistent obstructive symptoms. The traditional treatment for this was internal sphincterotomy or myectomy, which is still recommended by many surgeons.[35] However, it is well recognized that the obstructive symptoms related to internal sphincter achalasia tend to improve over time. Because applying a permanent sphincter-injuring solution to this temporary problem may be a suboptimal approach, some authors have suggested the use of reversible techniques to relax the internal anal sphincter, including intrasphincteric botulinum toxin[36] (Figure 7) or the application of topical nitric oxide.[37] In many cases, repeated injection of botulinum toxin or application of nitroglycerin paste is necessary while waiting for resolution of the problem, which usually occurs around the age of 5 years. Injection of intrasphincteric botulinum toxin is also very useful as a diagnostic test, because absence of a clinical response to botulinum toxin



**Figure 7** Injection of botulinum toxin into the anal sphincter for the treatment of internal sphincter achalasia. The procedure is done under general anesthesia as an outpatient, and is effective in relieving the obstructive symptoms in more than half of the patients. Injection can be repeated if necessary when the effect wears off. Injection of botulinum toxin also serves as a diagnostic test to determine whether nonrelaxation of the sphincter is an important factor in causing the obstructive symptoms. (Color version of figure is available online.)

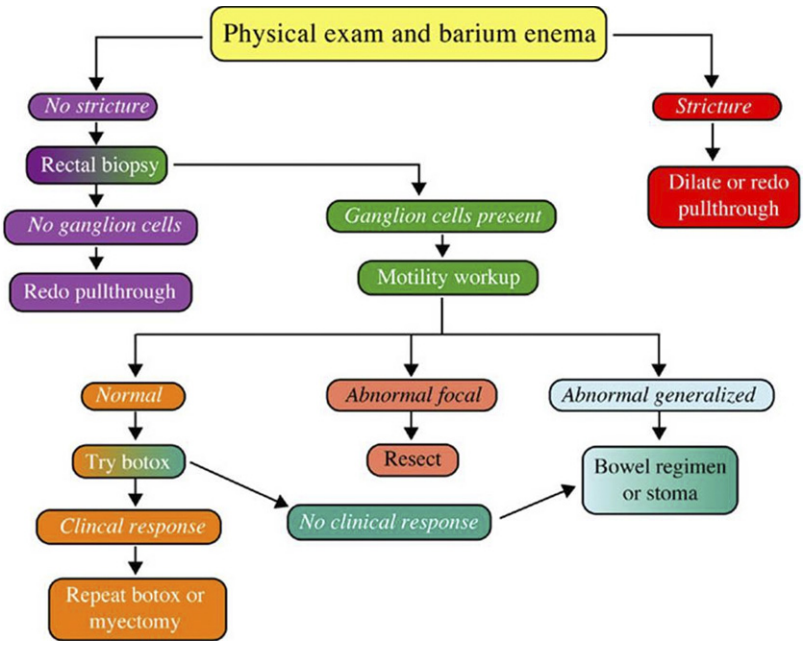


**Figure 8** Algorithm for the diagnosis and management of the child with obstructive symptoms after a pull through for Hirschsprung disease. (Color version of figure is available online.)

suggests that the sphincter is not the problem, and that myectomy is likely to fail.

### Functional megacolon

There remain a group of children who do not have an identifiable cause for their symptoms and who do not respond to surgical or chemical relaxation of the sphincter. Most of these children suffer from stool-holding behavior, and are best treated using a bowel management regimen consisting of a combination of diet, laxatives, and behavior modification, as well as support for the child and family. In some severe cases of obstructive symptoms, the child may be best served by use of a cecostomy[38] and administration of antegrade enemas, or by the creation of a proximal stoma.

An algorithm for the investigation and management of the child with obstructive symptoms is shown in Figure 8.

## Long-term prognosis

Despite the fact that postoperative problems, such as obstructive symptoms, enterocolitis and incontinence are relatively common, long-term follow-up studies would suggest that most children with Hirschsprung disease overcome these issues and do very well, regardless of the surgical technique used.[39] Sexual function, social satisfaction, and quality of life all appear to be relatively normal in the vast majority of patients. It is too early to determine what effect the single-stage pull-through procedure and the use of minimal access surgical techniques, such as laparoscopy and the transanal approach, will have on the postoperative complication rate and long-term outcome, but this is an important question that will require close follow-up and analysis. Although some authors initially raised concerns that the transanal pull-through procedure might be associated with an increased rate of incontinence and a higher stool frequency than the open Soave procedure,[16] these concerns do not appear to have been borne out in a larger multicenter study (Teitelbaum, personal communication). It is fair to say, however that strict attention to meticulous technique, and in particular a focus on avoiding stretching of the sphincter mechanism during the anal dissection, is crucial in optimizing long-term functional outcomes.

## References

1. Somme S, Langer JC. Primary vs staged pull-through for the treatment of Hirschsprung disease. Semin Pediatr Surg 2004;13:249-55.
2. Georgeson KE, Cohen RD, Hebra A, et al. Primary laparoscopic-assisted endorectal colon pull-through for Hirschsprung's disease: a new gold standard. Ann Surg 1999;229:678-83.
3. Travassos DV, Bax NM, Van der Zee DC. Duhamel procedure: a comparative retrospective study between an open and a laparoscopic technique. Surg Endosc 2007;21:2163-5.
4. Curran TJ, Raffensperger JG. Laparoscopic Swenson pull-through: a comparison with the open procedure. J Pediatr Surg 1996;31:1155-6.
5. de La Torre-Mondragon L, Ortega-Salgado JA. Transanal endorectal pull-through for Hirschsprung's disease. J Pediatr Surg 1998;33:1283-6.
6. Langer JC, Minkes RK, Mazziotti MV, et al. Transanal one-stage Soave procedure for infants with Hirschsprung disease. J Pediatr Surg 34:148-52.
7. Langer JC, Seifert M, Minkes RK. One-stage Soave pull-through for Hirschsprung disease: a comparison of the transanal vs open approaches. J Pediatr Surg 2000;35:820-2.
8. De la Torre L, Ortega A. Transanal versus open endorectal pull-through for Hirschsprung's disease. J Pediatr Surg 2000;35:1630-2.

9. Langer JC, Durrant AC, de la Torre L, et al. One-stage transanal Soave pullthrough for Hirschsprung disease: a multicenter experience with 141 children. Ann Surg 2003;238:569-83; discussion 583-5.
10. Pratap A, Shakya VC, Biswas BK, et al. Single-stage transanal endorectal pull-through for Hirschsprung's disease: perspective from a developing country. J Pediatr Surg 2007;42:532-5.
11. Venugopal S, Mancer K, Shandling B. The validity of rectal biopsy in relation to morphology and distribution of ganglion cells. J Pediatr Surg 1981;16:433-7.
12. Smith GHH, Cass D. Infantile Hirschsprung's disease—is barium enema useful? Pediatr Surg Int 1991;6:318-21.
13. Proctor ML, Traubici J, Langer JC, et al. Correlation between radiographic transition zone and level of aganglionosis in Hirschsprung's disease: implications for surgical approach. J Pediatr Surg 2003;38: 775-8.
14. Sauer CJE, Langer JC, Wales PW. The versatility of the umbilical incision in the management of Hirschsprung's disease. J Pediatr Surg 2005;40:385-9.
15. Nasr A, Langer JC. Evolution of the technique in the transanal pullthrough for Hirschsprung disease: effect on outcome. J Pediatr Surg 2007;42:36-9.
16. El-Sawaf MI, Drongowski RA, Chamberlain JN, et al. Are the long-term results of the transanal pull-through equal to those of the transabdominal pull-through? A comparison of the 2 approaches for Hirschsprung disease. J Pediatr Surg 2007;42:41-8.
17. Langer JC, Caty M, de la Torre-Mondragon L, et al. International Pediatric Endosurgery Group: Colorectal Panel. J Laparoendosc Adv Surg Tech 2007;17:77-100.
18. Wester T, Rintala RJ. Early outcome of transanal endorectal pull-through with a short muscle cuff during the neonatal period. J Pediatr Surg 2004;39:157-60; discussion 157-60.
19. Weidner BC, Waldhausen JH. Swenson revisited: a one-stage, transanal pull-through procedure for Hirschsprung's disease. J Pediatr Surg 2003;38:1208-11.
20. White FV, Langer JC. Circumferential distribution of ganglion cells in the transition zone of children with Hirschsprung disease. Pediatr Dev Pathol 2000;3:216-22.
21. Haricharan RN, Seo JM, Kelly DR, et al. Older age at diagnosis of Hirschsprung disease decreases risk of postoperative enterocolitis, but resection of additional ganglionated bowel does not. J Pediatr Surg 2008;43:1115-23.
22. Marty TL, Matlak ME, Hendrickson M, et al. Unexpected death from enterocolitis after surgery for Hirschsprung's disease. Pediatrics 1995; 96:118-21.
23. Marty TL, Seo T, Sullivan JJ, et al. Rectal irrigations for the prevention of postoperative enterocolitis in Hirschsprung's disease. J Pediatr Surg 1995;30:652-4.
24. Herek O. *Saccharomyces boulardii*: a possible addition to the standard treatment and prophylaxis of enterocolitis in Hirschsprung's disease? Pediatr Surg Int 2002;18:567.
25. Menezes M, Corbally M, Puri P. Long-term results of bowel function after treatment for Hirschsprung's disease: a 29-year review. Pediatr Surg Int 2006;22:987-90.
26. Langer JC. Persistent obstructive symptoms after surgery for Hirschsprung disease: development of a diagnostic and therapeutic algorithm. J Pediatr Surg 2004;39:1458-62.
27. Langer JC, Winthrop AL. Antegrade dilatation over a string for the management of anastomotic complications after a pull-through procedure. J Am Coll Surg 1996;183:411-12.
28. Langer JC. Repeat pullthrough surgery for complicated Hirschsprung disease: indications, techniques, and results. J Pediatr Surg 1999;34: 1136-41.
29. Shayan K, Smith D, Langer JC. Reliability of intraoperative frozen sections in the management of Hirschsprung disease. J Pediatr Surg 39:1345-8.
30. West KW, Grosfeld JL, Rescorla FJ, et al. Acquired aganglionosis: a rare occurrence following pull-through procedures for Hirschsprung's disease. J Pediatr Surg 1990;25:104-8; discussion 108-9.
31. Teitelbaum DH, Coran AG. Reoperative surgery for Hirschsprung's disease. Semin Pediatr Surg 2003;12:124-31.
32. Southwell BR, Clarke MC, Sutcliffe J, et al. Colonic transit studies: normal values for adults and children with comparison of radiological and scintigraphic methods. Pediatr Surg Int 2009;25:559-72.
33. Di Lorenzo C, Solzi GF, Flores AF, et al. Colonic motility after surgery for Hirschsprung's disease. Am J Gastroenterol 2000;95: 1759-64.
34. Mazziottti MV, Langer JC. Laparoscopic full-thickness intestinal biopsies in children. J Pediatr Gastroenterol Nutr 2001;33:54-7.
35. Blair GK, Murphy JJ, Fraser GC. Internal sphincterotomy in post-pullthrough Hirschsprung's disease. J Pediatr Surg 1996;31:843-5.
36. Minkes RK, Langer JC. A prospective study of botulinum toxin for internal anal sphincter hypertonicity in children with Hirschsprung's disease. J Pediatr Surg 2000;35:1733-6.
37. Tiryaki T, Demirbag S, Atayurt H, et al. Topical nitric oxide treatment after pull through operations for Hirschsprung disease. J Pediatr Gastroenterol Nutr 2005;40:390-2.
38. Yagmurlu A, Harmon CM, Georgeson KE. Laparoscopic cecostomy button placement for the management of fecal incontinence in children with Hirschsprung's disease and anorectal anomalies. Surg Endosc 2006;20:624-7.
39. Yanchar NL, Soucy P. Long term outcomes of Hirschsprung's disease: the patients' perspective. J Pediatr Surg 1999;34:1152-60.