
THE ANNALS OF THORACIC SURGERY

Management of pharyngoesophageal (Zenker's) diverticulum: which technique?

Christian A. Gutschow, Marc Hamoir, Philippe Rombaux, Jean-Bernard Otte, Louis Goncette and Jean-Marie Collard

Ann Thorac Surg 2002;74:1677-1683

The online version of this article, along with updated information and services, is located on the World Wide Web at:
http://ats.ctsnetjournals.org/cgi/content/full/74/5/1677

The Annals of Thoracic Surgery is the official journal of The Society of Thoracic Surgeons and the Southern Thoracic Surgical Association. Copyright © 2002 by The Society of Thoracic Surgeons.
Print ISSN: 0003-4975; eISSN: 1552-6259.

Downloaded from ats.ctsnetjournals.org by on November 5, 2010

Management of Pharyngoesophageal (Zenker's) Diverticulum: Which Technique?

Christian A. Gutschow, MD, Marc Hamoir, MD, Philippe Rombaux, MD, Jean-Bernard Otte, MD, Louis Goncette, MD, and Jean-Marie Collard, MD

Units of Upper G-I Surgery, ENT Surgery, and Radiology, Louvain Medical School, Brussels, Belgium

Background. **Incomplete symptomatic relief of pharyngoesophageal (Zenker's) diverticulum after endoscopic stapling or laser division has been reported by some authors. The clinical relevance of cricomyotomy, although supported by experimental data, remains controversial.**

Methods. **Operative procedures consisted of transcervical resection (n = 34, group I), transcervical resection plus cricomyotomy (n = 12, group II), transcervical cricomyotomy (n = 8, group III), transcervical cricomyotomy plus diverticulopexy (n = 47, group IV), endoscopic stapling division (n = 31, group V), and endoscopic laser division (n = 55; group VI).**

Results. **The percentage of totally asymptomatic patients was significantly ($p < 0.004$) higher after open procedures (combined groups I to IV) than after endoscopic treatment (combined groups V and VI) regardless of the size of the pouch (<3 cm, 85% versus 25%; ≥3 cm, 86% versus 50%). The percentage of patients with no or occasional (ie, fewer than twice a week) symptoms was significantly ($p < 0.001$) higher after open procedures (98%) than after endoscopic treatment (57%) for less than 3-cm diverticula whereas it was not higher ($p = 0.409$) for 3-cm or greater pouches (open, 97%; endoscopic, 88%). Furthermore, this percentage was similar ($p > 0.286$) after endoscopic stapling division and after endoscopic laser division (<3 cm, 50% versus 58%; ≥3 cm, 96% versus 80%). It was also similar ($p > 0.197$) after resection alone (group I) and after open operations including myotomy (combined groups II to IV) (<3 cm, 100% versus 98%; ≥3cm, 92% versus 100%). Unlike endoscopic stapling and division, laser division was complicated by mediastinitis (2 patients), and 1 patient was referred because of cervical esophageal disruption during laser division. Five of six postoperative fistulas after resection occurred in patients who did not have myotomy, and 4 patients were referred 12 to 49 years after resection without myotomy for true recurrence of the pouch.**

Conclusions. **Open techniques afford better symptomatic relief than endoscopic techniques, especially in patients with small diverticula. Endoscopic stapling and division is safer than laser division. Although very effective at midterm, resection without myotomy predisposes to the development of postoperative fistula and to recurrence of the pouch after many years.**

(Ann Thorac Surg 2002;74:1677–83)
© 2002 by The Society of Thoracic Surgeons

Since its description by Ludlow [1] in 1769 and by Zenker and von Ziemssen [2] in 1877, numerous surgical techniques have been developed to treat pharyngoesophageal diverticulum [3]. Transcervical resection of the diverticular pouch has been the procedure of choice as it was believed that the pouch itself constituted the disease [4, 5]. However, with the observations of Belsey [6], the concept was introduced that the diverticular sac was in fact the consequence of the disease, ie, a high pharyngeal pressure secondary to a lack of compliance of the cricopharyngeus muscle in relation to local fibrosis [7–9]. Consequently, proximal esophageal myotomy in combination with diverticulopexy was recommended for the management of the physiologic abnormality [10, 11]. However, no study has been published to demonstrate a superiority in terms of symptomatic relief of the myotomy-pexy technique over resection without myotomy.

As another form of therapy, the concept of endoscopic division of the wall separating the diverticular and esophageal lumina and containing the musculature that forms the upper esophageal sphincter was introduced by Mosher [12]. This technique was later improved by the application of diathermic [13] or laser [14, 15] coagulation. Recently, one of us (J.M.C.) described a stapling technique, which allowed an endoscopic suture of the cut margins [16, 17]. Although all published series [18–25] demonstrate that more than 90% of patients are substantially improved after endoscopic diverticuloesophagostomy, some authors [22–25] have reported that a substantial number of patients continue to have residual pharyngoesophageal symptoms at follow-up.

We reviewed our 16-year experience in the management of Zenker's diverticula to assess six different techniques in terms of both postoperative and long-term outcomes and to address the three following issues. Are the endoscopic approaches as safe and effective as the

Presented at the Thirty-eighth Annual Meeting of The Society of Thoracic Surgeons, Fort Lauderdale, FL, Jan 28–30, 2002.

Address reprint requests to Dr Collard, Upper G-I Surgery Unit, St. Luc Academic Hospital, Hippocrate Ave 10, B–1200, Brussels, Belgium; e-mail: collard@chir.ucl.ac.be.

© 2002 by The Society of Thoracic Surgeons
Published by Elsevier Science Inc

0003-4975/02/$22.00
PII S0003-4975(02)03931-0

Downloaded from ats.ctsnetjournals.org by on November 5, 2010

Table 1. Study Population (188 Operations on 184 Patients[a])

Characteristics	Group I Resection (n = 34)	Group II Resection + Myotomy (n = 12)	Group III Myotomy (n = 8)	Group IV Myotomy + Pexy (n = 47)	Group V Endo-stapling (n = 31)	Group VI Endo-laser (n = 55)
Sex ratio (M/F)	23/11	7/5	2/6	34/13	18/13	29/26
Age (y) median (range)	63.5 (27–86)	63 (43–84)	74 (50–83)	71 (39–92)	75 (37–84)	71 (41–87)
Size of the diverticulum (n)						
<3 cm	9	6	8	33	5	27
≥3 cm	25	6	0	14	25	24
?	0	0	0	0	1	4
Duration of symptoms (mo) median (range)	48 (7–240)	12 (7–360)	33 (7–84)	36 (3–290)	60 (2–408)	12 (2–240)
Primary/remedial operations	32/2	10/2	8/0	42/5	28/3	49/6
Duration of follow-up (mo) median (range)	157.5 (72–200)	93 (12–167)	72 (4–110)	57 (3–197)	35 (1–120)	61 (4–129)

[a] One patient belonging to none of the six groups.

open techniques? In the endoscopic approach, is it preferable to cut and suture the common wall between the esophageal and diverticular lumina by stapling or to burn and cut it by laser? And lastly, in patients operated on by cervicotomy, what is the clinical relevance of performing a cricomyotomy?

Material and Methods

Study Population

From 1984 to 2000, 184 patients (109 males and 75 females, aged 27 to 92 years with a median of 71 years) were referred to the Louvain Medical School Hospital (122 to the Upper G-I Surgery Unit and 62 to the ENT Surgery Unit) for management of a Zenker's diverticulum. Nineteen of these 184 patients had a remedial operation because of unsatisfactory outcome after resection without myotomy (n = 8) or endoscopic laser division (n = 11) of the pouch, for a total of 188 operations on 184 patients.

One hundred sixty-one patients were operated on for a diverticulum alone whereas 23 patients had a total of 27 other surgical conditions treated during the same operating session. Concomitant operations consisted of esophageal resection or bypass (n = 2), pleural drainage (n = 1), antireflux fundoplication (n = 13), cholecystectomy (n = 2), thyroidectomy (n = 4), vagotomy (n = 1), carpal tunnel division (n = 1), and abdominal wall hernia repair (n = 3). The preoperative symptoms consisted of dysphagia (n = 166), food regurgitation (n = 145), or respiratory complaints (n = 84).

Patients were classified into six groups (Table 1) according to surgical technique: transcervical resection of the pouch without cricomyotomy (group I), transcervical resection of the pouch with cricomyotomy (group II), cricomyotomy without diverticulopexy (group III), cricomyotomy with diverticulopexy (group IV), endoscopic stapling division (group V), and endoscopic laser division (group VI). An additional patient was referred to our institution after complete disruption of the cervical esophagus during endoscopic laser division that was managed by combined pharyngostomy, esophagostomy, and feeding jejunostomy. Diverticula were classified into two distinct categories depending on whether the common wall between the diverticular and esophageal lumina was shorter than 3 cm (small diverticulum) or longer than 3 cm (large diverticulum) on preoperative barium swallow radiographs.

Surgical Techniques

During the years, the technique of resection of the diverticulum as sole therapy was abandoned for an operation that included an esophageal myotomy or an endoscopic technique.

RESECTION (GROUP I). Thirty-four patients underwent resection of the diverticular pouch without cricomyotomy through a left cervical incision. In 24 patients, the collar of the pouch was transected with scissors and the pharyngeal defect closed primarily with 4-0 Vicryl (Johnson and Johnson, Somerville, NJ). Ten patients had their diverticular collar stapled using a TA-30 linear stapler (US Surgical Corporation, Norwalk, CT).

RESECTION PLUS MYOTOMY (GROUP II). Twelve patients underwent combined resection of the diverticular pouch and division of both the cricopharyngeus muscle and esophageal muscle fibers for a 5-cm distance through a left cervical incision. The pharyngeal defect was either handsewn (n = 6) or stapled (n = 6).

MYOTOMY (GROUP III). Eight patients with a 1-cm diverticulum were operated on through a left cervical incision by posterior division of both the cricopharyngeus muscle and esophageal muscle fibers for a 5-cm distance.

MYOTOMY PLUS DIVERTICULOPEXY (GROUP IV). Forty-seven patients with a more than 1-cm diverticulum were treated by anchorage of the diverticular pouch to the posterior

Downloaded from ats.ctsnetjournals.org by on November 5, 2010

pharyngeal wall or the prevertebral fascia in combination with a myotomy similar to that performed in patients of group III.

ENDOSCOPIC STAPLING DIVISION (GROUP V). Thirty-one patients were treated endoscopically with stapled division of the wall separating the diverticular and esophageal lumina according to a technique devised in 1991 and published in 1993 [16] by one of us (J.M.C.). The common wall was exposed between the two limbs of the Weerda-Collard diverticuloscope (Karl Storz, Tuttlingen, Germany) for application of one or more cartridges of an endo-GIA-30 stapler (US Surgical Corporation). The anvil of the stapler had its distal tip sawn off [17] to minimize the length (ie, 3 mm) of the residual spur at the bottom of the diverticulum after division.

ENDOSCOPIC LASER DIVISION (GROUP VI). Fifty-two patients referred to the ENT Surgery Unit underwent 55 operations consisting of endoscopic laser division of the wall separating both lumina. Technical principles have previously been reported [14, 15]. Briefly, a bivalved Holinger-Benjamin diverticuloscope (Karl Storz) was fixed to a chest support, and wet neurosurgical cottonoids (cotton sponges) were plugged in the esophageal lumen and at the bottom of the diverticulum to protect the mucosa from the laser. A 1040 Sharplan laser source (Sharplan, Tel Aviv, Israel) was coupled with an operative microscope equipped with a micromanipulator. The incision began in the mucosa of the common wall and extended down through the cricopharyngeus muscle and proximal esophageal muscle fibers. Occasional bleeding was controlled by electrocoagulation through an insulated suction device.

Data Recording and Interpretation

Information of the existence of residual symptoms (ie, cervical dysphagia, food regurgitation, and respiratory symptoms) was obtained from 148 patients (80%). All these 148 patients were interviewed on the telephone by one of us (C.A.G.) using a standardized questionnaire. Thirty-six patients (20%; ie, 16 from group I, 2 from group II, 1 from group III, 6 from group IV, 4 from group V, and 7 from group VI) were not suitable for symptomatic evaluation because they had died (n = 32) or were lost to follow-up (n = 4). Patients were classified into three groups on the basis of symptoms. The first group was very satisfied with the operation because they were totally asymptomatic (excellent result). The second group was satisfied with the operation but still had occasional (ie, twice a week or less) residual symptoms (good result). The final group was dissatisfied as they still had residual daily symptoms (fair result). Data analysis according to the size of the diverticulum was based on the radiographs from 144 patients (146 operations).

Fisher's exact and χ^2 tests were used for statistical analysis of categorical variables, and Kruskal-Wallis and Mann-Whitney rank sum tests were used for continuous variables with significance taken as $p \leq 0.05$.

Table 2. Postoperative Outcome of 161 Patients Operated on for Zenker's Diverticulum Alone (164 Operations)[a]

Group	Postoperative In-hospital Stay (d)	Postoperative Fasting Period (d)
Resection (group I, n = 29)	11 (8–61)	7 (5–55)
Resection + myotomy (group II, n = 12)	9 (7–43)	7 (6–8)
Myotomy (group III, n = 7)	3 (1–6)	1 (0–4)
Myotomy + pexy (group IV, n = 36)[b]	1.5 (0–26)	1 (0–20)
Endoscopic stapling division (group V, n = 25)	3 (0–10)	1 (0–4)
Endoscopic laser division (group VI, n = 54)	5 (3–43)	3 (1–40)

[a] Results are median (range). [b] One additional patient who died postoperatively was not suitable for analysis.

Results

Postoperative Course

Both postoperative in-hospital stay and fasting period were significantly longer in patients who underwent resection of the pouch with or without myotomy (groups I and II) than in those who underwent transcervical myotomy with or without diverticulopexy (groups III and IV; $p < 0.001$) and in those treated endoscopically (groups V and VI; $p < 0.001$). Furthermore, both the postoperative in-hospital stay and fasting period in group V (endoscopic stapling division) were significantly shorter ($p < 0.001$) than in group VI (endoscopic laser division; Table 2).

Postoperative complications were less frequent ($p = 0.037$) after the 169 primary operations (5.3%) than after the 19 remedial procedures (21.1%; Table 3). Five of the six cervical fistulas in group I developed after resection without myotomy. One elderly patient in group IV died of a cardiac arrest. A cervical abscess with upper mediastinitis developed in 2 patients of group VI. The patient referred to our institution with complete disruption of the cervical esophagus during endoscopic laser division was reoperated on for acute disruption of both the internal jugular vein and carotid artery.

Symptomatic Outcome

As shown in Figure 1, the percentage of totally asymptomatic patients (ie, excellent results) after open procedures (combined groups I to IV) was significantly higher than that after endoscopic procedures (combined groups V and VI) irrespective of the size of the diverticulum. With diverticula smaller than 3 cm, the percentage of patients with an excellent or good symptomatic outcome was significantly higher after open procedures than after endoscopic treatment whereas this was not the case with diverticula 3 cm or larger. After open procedures, there was no significant difference ($p = 0.698$) in terms of the percentage of patients having an excellent or good result

Downloaded from ats.ctsnetjournals.org by on November 5, 2010

Table 3. Postoperative Technical Complications After 188 Operations (169 Primary and 19 Remedial)

Group	Technical Complications	All Operations (n = 188)	Primary Operations (n = 169)	Remedial Operations (n = 19)
Group I (n = 34)	Salivary fistula	5/34	4/32	1/2
Group II (n = 12)	Salivary fistula	1/12	0/10	1/2
Group III (n = 8)	. . .	0/8	0/8	. . .
Group IV (n = 47)	Salivary fistula	2/47	1/42	1/5
Group V (n = 31)	Dental injury	1/31	1/28	0/3
Group VI (n = 55)	Upper mediastinitis	2/55	2/49	0/6
	Dental injury	1/55	1/49	0/6
Pharyngostomy and esophagostomy (n = 1)	Carotid artery and jugular vein disruption	1/1	. . .	1/1
Whole series (n = 188)	All complications	13/188 (6.9%)	9/169[a] (5.3%)	4/19[a] (21.1%)

[a] $p = 0.037$.

according to size of the diverticulum. In contrast, this percentage after endoscopic procedures was significantly ($p = 0.007$) higher in patients with diverticula 3 cm or larger than in those with diverticula smaller than 3 cm.

As shown in Figure 2, the symptomatic evaluation according to size of the diverticulum did not demonstrate any significant difference between patients operated on by endoscopic stapling division (group V) and those who underwent endoscopic laser division (group VI).

As shown in Figure 3, the percentage of patients with an excellent symptomatic outcome after resection without myotomy (group I) did not significantly differ from those patients with open approaches including a myotomy (combined groups II to IV) irrespective of the size of the diverticulum. Likewise, the percentage of patients with an excellent or good symptomatic outcome was similar after resection alone than after an open approach including a myotomy.

Causes of Failure

The cause of failure in the 19 patients who required a remedial operation because of an unsatisfactory outcome operation was determined on the basis of both the patient's clinical history and the analysis of preoperative barium swallow radiographs.

Ten of the 11 patients who underwent primary endoscopic laser division of the diverticulum still had a relatively long residual spur at the bottom of the pouch owing to incomplete division of the common wall between the esophageal and diverticular lumina. The 11th patient had had complete disruption of his cervical esophagus because of improper use of the laser source.

Four patients admitted to our institution 3 to 36 months after diverticulectomy without myotomy had no improvement of symptoms because of incomplete resection of the pouch. Four patients with a history of previous resection without myotomy sought consultation for recurrent pharyngoesophageal symptoms after a symptom-free period ranging from 12 to 49 years. In these 4 patients, there was evidence of progressive reappearance of a large diverticulum (Fig 4).

Comment

Although retrospective, our single center study demonstrates that open surgical treatment of Zenker's divertic-

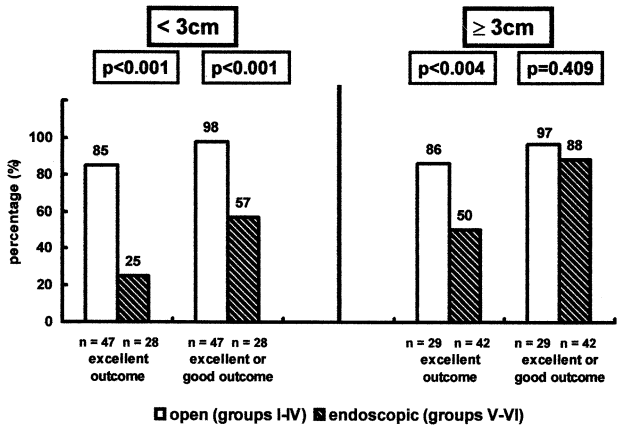

Fig 1. Symptomatic outcome after open (blank columns) and endoscopic (hatched columns) treatments according to whether diverticulum was smaller than 3 cm (left) or 3 cm or larger (right).

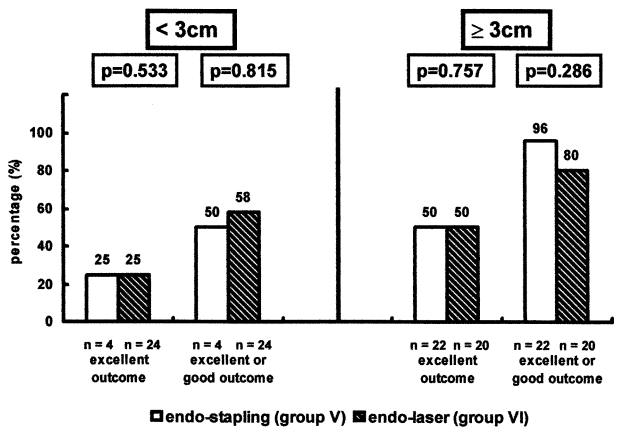

Fig 2. Symptomatic outcome after endoscopic stapling (blank columns) and laser (hatched columns) division according to whether diverticulum was smaller than 3 cm (left) or 3 cm or larger (right).

Downloaded from ats.ctsnetjournals.org by on November 5, 2010

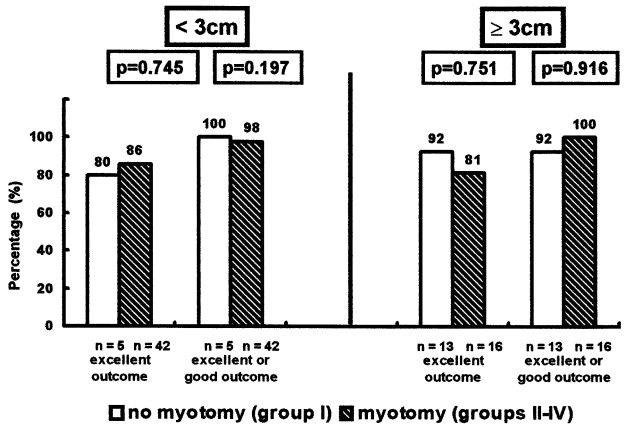

Fig 3. Symptomatic outcome after resection without cricomyotomy (blank columns) and open techniques including a cricomyotomy (hatched columns) according to whether diverticulum was smaller than 3 cm (left) or 3 cm or larger (right).

ulum yields a better symptomatic relief than do endoscopic techniques. In addition, unlike the open techniques, which are very effective in relieving symptoms regardless of the diverticular size, the endoscopic techniques are poorly effective and therefore contraindicated in the presence of a small diverticulum. Consequently, endoscopic division should be reserved for patients with a large diverticulum, ie, those with a history of previous neck operation because of risk of injury to the recurrent nerve, those with a giant diverticulum that would require an extended upper mediastinal dissection from the neck, and those high-risk elderly patients who could benefit from a short-lasting procedure.

Even though endoscopic division of the wall between the diverticular and esophageal lumina decreases resistance to a bolus through Killian's mouth [19], there are two main causes of incomplete symptomatic relief after endoscopic treatment. A first cause of failure is the existence of a short common wall to cut (ie, <3 cm). This condition precludes a long myotomy [10] and widening of the esophageal lumen sufficiently [17]. This is supported by the fact that after endoscopic treatment, patients with a small diverticulum had poor symptomatic relief compared with those with a large diverticulum. A second cause of failure is an insufficient division of the common wall between the esophageal and diverticular lumina. This leaves a relatively long residual spur at the bottom of the common cavity and persistence of stasis. We found that 10 of 11 patients reoperated on because of unsatisfactory outcome after endoscopic laser treatment had had incomplete division of the common wall.

This study fails to show any significant superiority for symptomatic relief with the endoscopic stapling technique over the laser technique irrespective of the diverticular size. However, endoscopic stapling division was shown to be safer than laser division of the common wall. Because the incision ends 3 mm proximal to the distal tip of the anvil and the cut margins are stapled, perforation is unlikely with the stapling technique [17]. In contrast, difficulty in determining the point where laser division of the common wall must end predisposes to the persistence of dysphagia (too long a residual spur) and to perforation with mediastinitis (too long a cut). In addition, the use of the laser may cause dramatic damage such as complete disruption of the cervical esophagus (as occurred in one referred patient).

This study demonstrates that simple resection of the pouch without cricomyotomy [4, 5] provides patients with the same chance at a midterm excellent outcome as do open techniques that include an esophageal myotomy [6–11]. Cricomyotomy has been recommended because dysfunction of the upper esophageal sphincter has been shown to play a role in the genesis of the diverticulum [9]. However, to date no comparative study has been published that confirmed the benefit of symptomatic relief of the myotomy-pexy technique over resection of the sac without myotomy. The high success rate achieved by resection of the sac alone [4, 26] indicates that once the diverticulum has developed, pharyngoesophageal symptoms are mainly caused by the existence of the sac itself, which retains ingested material and pushes the cervical esophagus forward so as to collapse it against the trachea. However, this study shows that resection of the diverticulum without myotomy predisposes to the development of a cervical fistula postoperatively and to the long-term recurrence of the pouch. This may be explained by the persistence of a high intrapharyngeal pressure that acts on the posterior pharyngeal wall just proximal to the upper esophageal sphincter [7, 9]. Although a very low recurrence rate after resection alone was reported by the Mayo Clinic team [26], our experience indicates that many years can pass until the patient seeks consultation again for recurrent pharyngoesophageal symptoms. Most of the elderly patients may die before experiencing clinical recurrence. Although radiologic recurrence may remain asymptomatic for a long period [5], the clinical history of 4 patients referred to our institution because of persistent symptoms after resec-

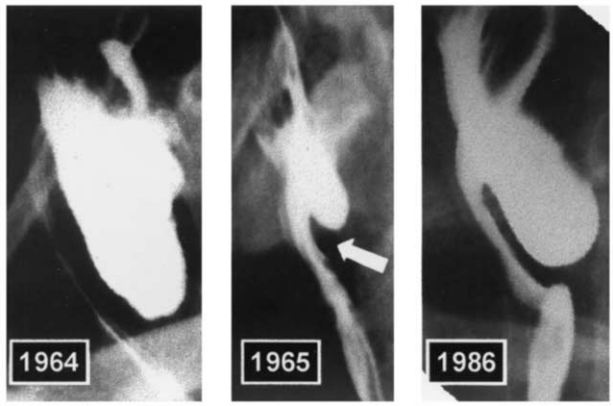

Fig 4. Radiographs showing a large diverticulum before resection without myotomy (left), a small pseudopouch caused by the imprint of the cricopharyngeal muscle (arrow) *1 year later (center), and the reappearance of a large diverticulum 22 years after the operation (right).*

Downloaded from ats.ctsnetjournals.org by on November 5, 2010

tion without myotomy demonstrates that incomplete symptomatic relief may be related to partial removal of the pouch.

Another advantage of the myotomy-pexy technique over resection of the sac [4, 5, 26] is that in the former technique, the pharyngeal lumen is not opened unless inadvertently injured. This allows earlier oral feeding after the operation [8, 10, 11] and shortens the hospital stay.

In conclusion, any patient referred with a Zenker's diverticulum must be informed of the increased risk of residual symptoms with endoscopic treatment rather than after open procedures. This is especially true if the diverticulum is small. The endoscopic stapling technique is as effective but safer than the laser technique and may be indicated in selected patients with a large diverticulum. Omitting a cricomyotomy predisposes to the development of a fistula postoperatively and to pouch recurrence in the long term.

We thank Nadine Thiebaut for typing the manuscript.
Doctor Christian Gutschow, resident in the Upper G-I Surgery Unit, received financial support from UCB Pharma, Braines, Belgium.

References

1. Ludlow A. A case of obstructed deglutition from a preternatural bag formed in the pharynx. Johnson W, Caldwell T, eds. In: Medical observations and inquiries by a society of physicians in London. London, Vol. 3, 2nd ed., 1769:85–101.
2. Zenker FA, von Ziemssen H. Krankheiten des Oesophagus. In: von Ziemssen H, ed. Handbuch der speciellen Pathologie und Therapie, vol. 7 (suppl). Leipzig: FC Vogel, 1877:1–87.
3. Ferguson MK. Evolution of therapy for pharyngoesophageal (Zenker's) diverticulum. Ann Thorac Surg 1991;51:848–52.
4. Michot F, Lienhard P, Maillard JN. La myotomie du cricopharyngien est inutile dans la cure chirurgicale du diverticule pharyngo-oesophagien. Chirurgie 1978;104:679–82.
5. Bertelsen S, Aasted A. Results of operative treatment of hypopharyngeal diverticulum. Thorax 1976;31:544–7.
6. Belsey R. Functional disease of the esophagus. J Thorac Cardiovasc Surg 1966;52:164–88.
7. Cook IJ, Blumbergs P, Cash K, et al. Structural abnormalities of the cricopharyngeus muscle in patients with pharyngeal (Zenker's) diverticulum. J Gastroenterol Hepatol 1992;7:556–62.
8. Lerut T, Guelinckx P, Dom R, et al. Does the musculus cricopharyngeus play a role in the genesis of Zenker's diverticulum? Enzyme histochemical and contractility properties. In: Siewert JR, Hölscher AH, eds. Diseases of the esophagus. Berlin: Springer Verlag, 1988:1118–23.
9. Cook IJ, Gabb M, Panagopoulos V, et al. Pharyngeal (Zenker's) diverticulum is a disorder of upper esophageal sphincter opening. Gastroenterology 1992;103:1229–35.
10. Sideris L, Chen LQ, Ferraro P, et al. The treatment of Zenker's diverticula: a review. Semin Thorac Cardiovasc Surg 1999;11:337–51.
11. Hauters PH, Segol PH, Leroux Y, et al. Place de la myotomie du cricopharyngien associée à une diverticulopexie dans le traitement du diverticule de Zenker (quinze années d'expérience). Ann Chir 1988;42:726–30.
12. Mosher HP. Webs and pouches of the esophagus, their diagnosis and treatment. Surg Gynecol Obstet 1917;25:175–87.
13. Dohlman G, Mattson O. The endoscopic operation for hypopharyngeal diverticula. Arch Otolaryngol 1960;71:744–52.
14. van Overbeek JJ, Hoeksema PE, Edens ET. Microendoscopic surgery of the hypopharyngeal diverticulum using electrocoagulation of carbon dioxide laser. Ann Otol Rhinol Laryngol 1984;93:34–6.
15. Hamoir M, Gruyer X, Rombaux P. [Use of CO_2 laser in endoscopic treatment of Zenker's pharyngo-esophageal diverticula. Experience apropos of 33 cases]. Ann Otolaryngol Chir Cervicofac 1997;114:7–12.
16. Collard JM, Otte JB, Kestens PJ. Endoscopic stapling technique of esophagodiverticulostomy for Zenker's diverticulum. Ann Thorac Surg 1993;56:573–6.
17. Collard JM. Endoscopic approach to hypopharyngeal diverticulum. In: Peters JH, Demeester TR, eds. Minimally invasive surgery of the foregut. St Louis: Quality Medical Publishing, 1994:73–82.
18. Baldwin DL, Toma AG. Endoscopic stapled diverticulotomy: a real advance in the treatment of hypopharyngeal diverticulum. Clin Otolaryngol 1998;23:244–7.
19. Peracchia A, Bonavina L, Narne S, et al. Minimally invasive surgery for Zenker diverticulum. Arch Surg 1998;133:695–700.
20. Omote K, Feussner H, Stein HJ, et al. Endoscopic stapling diverticulostomy for Zenker's diverticulum. Surg Endosc 1999;13:535–8.
21. van Overbeek JJM. Meditation on the pathogenesis of hypopharyngeal (Zenker's) diverticulum and a report of endoscopic treatment in 545 patients. Ann Otol Rhinol Laryngol 1994;103:178–85.
22. Cook RD, Huang PC, Richstmeier WJ, et al. Endoscopic staple-assisted esophago-diverticulostomy: an excellent treatment of choice for Zenker's diverticulum. Laryngoscope 2000;110:2020–25.
23. Philippsen LP, Weisberger EC, Whiteman TS, et al. Endoscopic stapled diverticulotomy: treatment of choice for Zenker's diverticulum. Laryngoscope 2000;110:1283–6.
24. Luscher MS, Johansen LV. Zenker's diverticulum treated by the endoscopic stapling technique. Acta Otolaryngol Suppl 2000;543:235–8.
25. van Eeden S, Lloyd RV, Tranter RM. Comparison of the endoscopic stapling technique with more established procedures for pharyngeal pouches: results and patients satisfactory survey. J Laryngol Otol 1999;113:237–40.
26. Payne WS. The treatment of pharyngoesophageal diverticulum: the simple and complex. Hepatogastroenterology 1992;39:109–14.

DISCUSSION

DR STEVEN R. DEMEESTER (Los Angeles, CA): Thank you for that fascinating review of your experience. I had a question though. It was intriguing that you found that the small diverticulum with the stapled technique did not seem to do as well as the larger diverticula with the stapled technique, and your assumption was that is was because you were not getting an effective myotomy with the division in those small pouches. Maybe you could enhance our understanding a little bit by describing the symptoms that they were complaining about. Was it dysphagia or regurgitation? The regurgitation should go away if you get rid of the pouch. And the corollary, then, is it is intriguing if that is the case why you did not see a difference in

Downloaded from ats.ctsnetjournals.org by on November 5, 2010

symptoms in the open group between myotomy and no myotomy. How can you explain no difference in symptoms in the open group, and yet postulate that the incomplete myotomy led to more symptoms in the transorally stapled patients with small pouches?

Thanks.

DR GUTSCHOW: The symptoms in these patients with a cricopharyngeal problem and a small diverticulum were mainly dysphagia and not regurgitation.

Can I have your second question again, please?

DR DEMEESTER: How does that fit, then, with the open group that had a myotomy versus no myotomy, why there was no difference in symptoms?

DR COLLARD: With the open technique we used the myotomy or myotomy plus pexy mainly for small diverticula. In fact, when you perform an open myotomy for a small diverticulum, this myotomy is very long. It includes not only the cricopharyngeus muscle but also the 5 cm of the cervical esophagus. When you try to perform the same operation endoscopically for a small diverticulum, it is impossible to perform a very long myotomy. The myotomy is limited by the length of the common wall between the small diverticulum and the esophagus.

On the other hand, most patients operated on by resection without myotomy had a large diverticulum. After removal of the large sac, the esophageal lumen is no longer collapsed, and retention of food material is impossible, of course. This is why we did not find any significant difference in terms of symptomatic relief between patients who had a myotomy and those who had not. In contrast, we found that omitting a myotomy in patients who had their diverticulum resected predisposed to the development of a cervical fistula postoperatively and to pouch recurrence in the very long term, probably because of the persistence of a high intrapharyngeal pressure at swallowing.

Downloaded from ats.ctsnetjournals.org by on November 5, 2010

Management of pharyngoesophageal (Zenker's) diverticulum: which technique?

Christian A. Gutschow, Marc Hamoir, Philippe Rombaux, Jean-Bernard Otte, Louis Goncette and Jean-Marie Collard

Ann Thorac Surg 2002;74:1677-1683

Updated Information & Services	including high-resolution figures, can be found at: http://ats.ctsnetjournals.org/cgi/content/full/74/5/1677
References	This article cites 21 articles, 3 of which you can access for free at: http://ats.ctsnetjournals.org/cgi/content/full/74/5/1677#BIBL
Citations	This article has been cited by 3 HighWire-hosted articles: http://ats.ctsnetjournals.org/cgi/content/full/74/5/1677#otherarticles
Subspecialty Collections	This article, along with others on similar topics, appears in the following collection(s): **Esophagus - other** http://ats.ctsnetjournals.org/cgi/collection/esophagus_other
Permissions & Licensing	Requests about reproducing this article in parts (figures, tables) or in its entirety should be submitted to: http://www.us.elsevierhealth.com/Licensing/permissions.jsp or email: healthpermissions@elsevier.com.
Reprints	For information about ordering reprints, please email: reprints@elsevier.com

THE ANNALS OF THORACIC SURGERY

Downloaded from ats.ctsnetjournals.org by on November 5, 2010