Brief clinical report

Management of complicated umbilical hernias in patients with end-stage liver disease and refractory ascites

Shawn P. Fagan, MD, Samir S. Awad, MD, *and* **David H. Berger, MD,** *Houston, Tex*

From the Michael E. DeBakey Department of Surgery, Houston Veterans Affairs Medical Center, Baylor College of Medicine, Houston, Tex

UMBILICAL HERNIA IS SEEN IN UP TO 20% of patients with long-standing cirrhosis and ascites.[1] Occasionally, a patient will present with spontaneous rupture of an umbilical hernia and leaking ascites. Patients with ascites who present acutely with ruptured umbilical hernias have 2 distinct problems that need to be treated, namely, the ruptured umbilical hernia and the underlying ascites. The strategy for treating umbilical hernia in patients with ascites has evolved considerably. Initial management consisted of nonoperative therapy as a result of fear of precipitating bleeding from esophageal varices. As a result of the high morbidity and mortality observed with a nonoperative approach, the treatment of choice became primary repair of the hernia with either concomitant or staged peritoneovenous shunting (PVS).[1]

Recently, transjugular intrahepatic portosystemic shunting (TIPS) has supplanted PVS as the treatment of choice of patients with intractable ascites.[2] However, there is only a single report of the use of TIPS in the management of patients presenting with a ruptured umbilical hernia and ascites.[3] Here, we describe the combined use of TIPS and urgent umbilical hernia repair in 3 patients with refractory ascites. Two patients who presented with frank rupture of an umbilical hernia and leaking ascites were managed initially by TIPS followed by hernia repair. A third patient presenting with ascites and gangrenous intact skin overlying an umbilical hernia (indicating impending rupture) required emergent umbilical hernia repair followed by a TIPS procedure postoperatively.

Accepted for publication December 26, 2003.

Reprint requests: David H. Berger, MD, Veterans Affairs Medical Center, Michael E. DeBakey Department of Surgery, Surgical Services (112), 2002 Holcombe Blvd. Houston, TX 77054.

Surgery 2004;135:679-82.

0039-6060/$ - see front matter

© 2004 Elsevier Inc. All rights reserved.

doi:10.1016/j.surg.2003.12.010

CASE 1

A 62-year-old white male reformed alcoholic with cirrhosis and ascites presented for evaluation of an umbilical hernia. He first noticed the onset of ascites 9 months before surgical evaluation, and more recently noticed the presence of an umbilical hernia. On physical examination he was found to be thin with a normal mental status. He had a protuberant abdomen and a nonleaking 4.0-cm umbilical hernia. Laboratory analysis revealed total bilirubin 0.8 mg/dL, albumin 3.9 g/dL, alanine aminotransferase 15 U/L, aspartate aminotransferase 34 U/L, creatinine 1.2 mg/dL, partial thromboplastin time 32.4 seconds, and an international normalizee ratio (INR) of 1.2 consistent with Child-Pugh classification B. Because of his tense ascites, the patient was scheduled for elective herniorrhaphy after medical treatment of his ascites. He was started on an aggressive regimen of furosemide and spironolactone. Before elective hernia repair, the patient presented to the emergency room with a ruptured umbilical hernia leaking ascitic fluid. The periumbilical region was prepared sterilely, and a sterile occlusive dressing was applied. Broad-spectrum antibiotics were instituted, and the patient underwent a TIPS procedure. Over the next 4 days his ascites diminished. Umbilical herniorrhaphy was accomplished with primary repair on hospital day 8. His postoperative course was unremarkable, and he was discharged home on postoperative day 3. The patient has been doing well postoperatively, and has had no evidence of recurrent hernia or ascites during 13 months of follow-up.

CASE 2

A 65-year-old white male with ruptured umbilical hernia, tense ascites, a history of upper gastrointestinal bleed, and a long-standing history of ethanol abuse was transferred to our hospital for further treatment. At an outside hospital an ostomy bag had been placed around the ruptured hernia, and the patient had been given intravenous antibiotics. Upon arrival to our hospital, the patient had a normal mental status, a distended abdomen, and a 3-cm umbilical hernia leaking ascites through the center. There was no evidence of peritonitis. The patient claimed to be compliant with his diuretic regimen of high-dose lasix and spironolactone. Laboratory analysis revealed total bilirubin 0.3 mg/dL, albumin 2.0 g/dL, alanine aminotransferase 34 U/L, aspartate aminotransferase 52 U/L, creatinine 1.1 mg/dL, partial thromboplastin time 31.4 seconds, and an INR of 1.1 consistent with a Child-Pugh classification B.

The patient's periumbilical ostomy bag was removed, and the area was prepared sterilely. A sterile occlusive dressing was applied, and intravenous antibiotics were continued. The patient underwent TIPS procedure on hospital day 2, and primary repair of the umbilical hernia later that same day. The patient's ascites diminished over the ensuing days. He recovered well from the procedures and remained afebrile, and at his 5-month follow-up visit has had no evidence of recurrence of his hernia.

CASE 3

A 51-year-old male presented with a 12-hour history of an incarcerated umbilical hernia. His past medical history was significant for idiopathic pulmonary fibrosis, cirrhosis resulting from hepatitis C, and alcohol consumption that was complicated by uncontrolled ascites, despite medical management. The patient was found to have a strangulated umbilical hernia with overlying thin, gangrenous skin, ascites, and peritonitis. Laboratory analysis revealed total bilirubin 1.1 mg/dL, albumin 2.7 g/dL, alanine aminotransferase 55 U/L, aspartate aminotransferase 77 U/L, creatinine 0.9 mg/dL, prothrombin time 16.6 seconds, partial thromboplastin time 32.3 seconds, and an INR of 1 consistent with a Child-Pugh classification B. The patient underwent an exploratory laparotomy, which revealed a strangulated segment of jejunum and a 5-cm fascial defect. The operative procedure consisted of a segmental small bowel resection and primary closure of fascial defect. Postoperatively, the patient rapidly reaccumulated his ascites, which was treated on the second postoperative day with a TIPS procedure. The patient did well post-portal decompression, with control of his ascites, and was discharged without complication. He was free of hernia recurrence and ascites at his 3-month follow-up visit.

DISCUSSION

Kirkpatrick and Schubert[4] first documented the benefit of surgical repair in cases of spontaneous rupture of umbilical hernia. These authors calculated the overall mortality rate for spontaneous umbilical hernia rupture to be 60% for patients managed conservatively compared with 14% for those undergoing hernia repair. The exact timing of hernia repair remains controversial, as does the need and method for control of ascites. Emergent surgery appears to offer no advantage to delayed surgery. As long as the patient has been stabilized with intravenous fluids, placed on broad-spectrum antibiotics, and had their site of rupture covered with an occlusive dressing, there appears to be no increase in morbidity or mortality.[1]

Until the 1980s, the standard practice had been to forego elective repair of umbilical hernias in patients with ascites because of fear of high morbidity and mortality rates, and a high incidence of postoperative hernia recurrence. However, review of the literature documents that the mortality rate for elective repair of umbilical hernias in patients with ascites is only 2% compared with a 14% mortality rate for emergent repair. Therefore, if a patient can be adequately prepared for surgery, elective repair is indicated.[1,3]

Repair of an umbilical hernia without adequate control of ascites results in a hernia recurrence rate as high as 73%.[1,3] Aggressive medical management of ascites with diuretics is advocated before elective hernia repair. Peritoneovenous (PV) shunting at the time of, or after, hernia repair has been used successfully in patients with refractory ascites. Leonetti and colleagues[5] demonstrated no hernia recurrences in 15 patients with functioning PV shunts compared with 4 of 24 recurrences in patients without shunts or with nonfunctioning shunts. Belghiti et al[1] observed no hernia recurrences in 14 patients who underwent simultaneous umbilical herniorrhaphy and PV shunting. This was in contrast to a recurrence rate of 25% in patients undergoing hernia repair alone.[3]

Despite being an effective means of relieving ascites, the use of PVS has largely been abandoned because of its high morbidity. PV shunts have a 40% to 60% complication rate that can result from infection, obstruction, venous thrombosis, pulmonary embolus, small bowel obstruction, disseminated intravascular coagulation, bleeding, and pulmonary edema. Several studies have documented that patients with advanced cirrhosis and severely compromised hepatic function do poorly with PVS. Death has been reported to occur within 1 month of PVS in nearly 50% of cirrhotics. Additionally, the mortality rate for Child-Pugh classification C cirrhotics undergoing PVS is high, approaching 100% in some studies.[3]

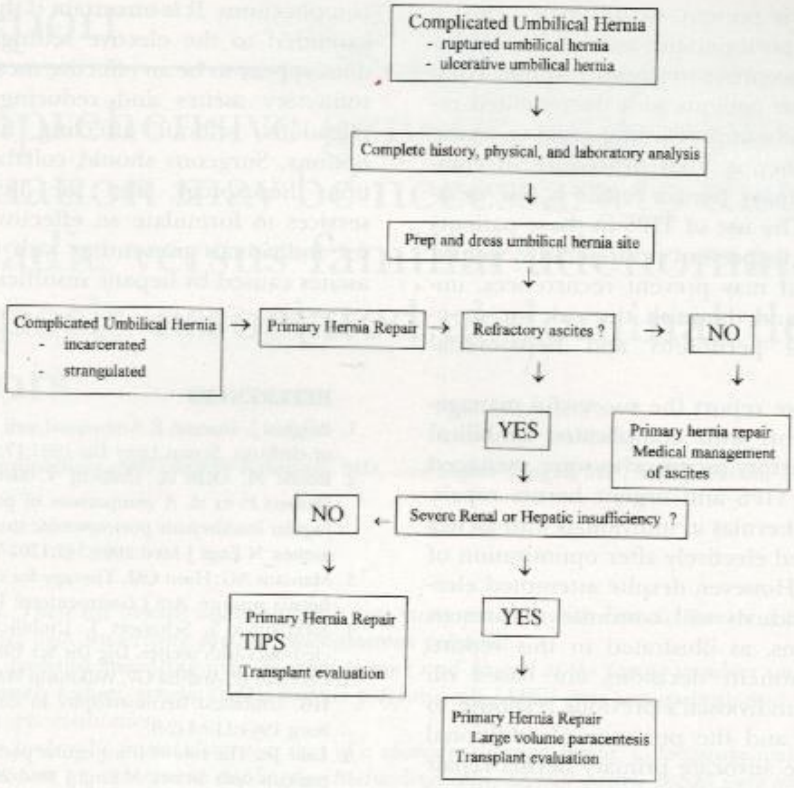

Fig 1. Management of umbilical hernias complicated by cirrhosis and ascites.

The ability of portosystemic shunting to control refractory ascites in patients with portal hypertension has long been recognized. Side-to-side portocaval or mesocaval shunts have been most effective in treating ascites. Despite the demonstrated efficacy in reducing ascites, these operations have fallen out of favor because of high associated mortality rates (10%), the high incidence of postoperative encephalopathy (50%), and the negative impact on subsequent hepatic transplantation.[1,3] The development of TIPS in the early 1990s changed the way that refractory ascites is managed in patients with portal hypertension. TIPS provides effective control of ascites in 80% to 90% of patients with advanced cirrhosis and ascites refractory to medical management.[2] Although infection, hepatic encephalopathy, and bleeding have been reported, TIPS appears to be safe, with reported mortality less than 5%. The 1-year stent occlusion rate with TIPS is 20%; however, in most cases the shunt can be reestablished.[3] In comparison with large-volume paracentesis, the use of TIPS can improve survival in patients with refractory or recurrent ascites.[2]

Based on these results and others, we developed an algorithm for treatment of complicated umbilical hernias in the presence of refractory ascites (Fig 1). All patients presenting to our facility with a complicated umbilical hernia and ascites undergo a detailed review of his/her medical records, history, physical examination, and laboratory analysis. To prevent or limit further complications, all non-incarcerated and non-strangulated hernias are prepped sterilely and an appropriate dressing applied. The most important step in determining if a patient is a candidate for TIPS in combination with their hernia repair is to determine if the patient has refractory ascites. Refractory ascites is defined as the resistance to high-dose diuretic therapy (400 mg spironolactone and 160 mg furosemide per day), or the development of rapid recurrences of ascites after large-volume paracentesis. If the patient is not refractory to medical therapy, we advocate optimization of combination diuretic therapy and urgent primary hernia repair. For those patients diagnosed with refractory ascites, they should be evaluated for preexisting renal disease and severe hepatic insufficiency. Previous reports have demonstrated TIPS to be ineffective and problematic in patients with severe preexisting renal or hepatic insufficiency.[6,7] If either of these

disease processes is present, we advocate primary hernia repair and postoperative ascites control with large-volume paracentesis to prevent wound complications. In those patients with documented refractory ascites, without preexisting renal or severe hepatic insufficiency, a TIPS procedure in combination with primary hernia repair is our treatment of choice. The use of TIPS in these patients not only appears to prevent postoperative wound complications, but may prevent recurrences, improve nutrition, and diminish the risk for spontaneous bacterial peritonitis and hepatorenal syndrome.[6,8]

In this paper we report the successful management of 3 patients with complicated umbilical hernias and refractory ascites who were managed successfully with TIPS and urgent hernia repair. Ideally, umbilical hernias in individuals with ascites should be repaired electively after optimization of diuretic therapy. However, despite attempted elective repair, individuals will continue to present with complications, as illustrated in this report. The critical treatment decisions are based on determining the individual's previous response to diuretic therapy, and the presence of additional comorbidities. We advocate primary hernia repair in combination with TIPS as the treatment of choice for individuals presenting with complicated umbilical hernias in association with ascites refractory to maximum combination diuretic therapy, without preexisting severe renal or hepatic insufficiency. The authors realize this is a small series, with limited follow-up, but initial results are encouraging, with no wound healing or short-term complications. It is uncertain if this therapy can be extended to the elective setting. However, TIPS does appear to be an effective means of controlling refractory ascites and reducing potential complications without affecting future transplant options. Surgeons should collaborate with nutrition, hepatology, and the hepatic transplant services to formulate an effective treatment plan for individuals presenting with complications of ascites caused by hepatic insufficiency.

REFERENCES

1. Belghiti J, Durand F. Abdominal wall hernias in the setting of cirrhosis. Semin Liver Dis 1997;17:219-26.
2. Rossle M, Ochs A, Gulberg V, Siergerstetter V, Holl J, Deibert P, et al. A comparison of paracentesis and transjugular intrahepatic portosystemic shunting in patients with ascites. N Engl J Med 2000;342:1701-7.
3. Maniatis AG, Hunt CM. Therapy for spontaneous umbilical hernia rupture. Am J Gastroenterol 1995;90:310-2.
4. Kirkpatrick S, Schubert T. Umbilical hernia rupture in cirrhotics with ascites. Dig Dis Sci 1988;33:762-5.
5. Leonetti JP, Aranha GV, Wilkinson WA, Stanley M, Greenlee HB. Umbilical herniorrhaphy in cirrhotic patients. Arch Surg 1984;119:442-5.
6. Lake JR. The role of transjugular portosystemic shunting in patients with ascites. N Engl J Med 2000;342:1745-7.
7. Deschenes M, Dufresne MP, Bui B, Fenyves D, Spahr L, Roy L, et al. Predictors of clinical response to transjugular intrahepatic portosystemic shunt (TIPS) in cirrhotic patients with refractory ascites. Am J Gastroenterol 1999; 94:1361-5.
8. Trotter JF, Suhocki PV, Rockey DC. Transjugular intrahepatic portosystemic shunt (TIPS) in patients with refractory ascites: effect on body weight and Child-Pugh score. Am J Gastroenterol 1998;93:1891-4.