Innovations in Minimally Invasive Facial Treatments

José Roberto Parisi Jurado, MD[1] Leila Freire Rego Lima, MD[1] Isabela Peixoto Olivetti, MD[1] Helena Hotz Arroyo, MD[1] Ingrid Helena Lopes de Oliveira, MD[1]

[1] Department of Otorhinolaryngology, University of São Paulo School of Medicine, São Paulo, Brazil

Facial Plast Surg 2013;29:154–160.

Address for correspondence José Roberto Parisi Jurado, MD, Clinical Hospital of the University of São Paulo–Otolaringology, Avenida Doutor Enéas de Carvalho Aguiar, 155 São Paulo São Paulo 05403-000, Brazil (e-mail: jjurado@superig.com.br).

Abstract

Patients are seeking healthier lives, and at the same time their concern about having a beautiful face and maintaining a youthful appearance over time has increased. Traditionally, surgeries based on tissue resection and resurfacing were the focus in facial rejuvenation. Over the last decade, minimally invasive procedures have expanded exponentially because of the variety of cosmetic products available on the market and because patients are looking for a better appearance with nonincision methods. The understanding of the aging process, facial anatomy, and ideal proportions is extremely important for successful rejuvenation procedures. Also, neuromodulators, chemical peels, filler properties, correct indications, and effectiveness must be well known by the injector for favorable results. Therefore, knowledge of all facial cosmetic options and an adequate facial analysis are essential for a better performance. In this article, the authors review some different product options and show cases of minimally invasive cosmetic procedures for the face currently used.

Keywords
- facial rejuvenation
- minimally invasive
- injectables
- fillers
- botulinum toxin

Facial harmony has been an object of study for centuries. The quest for understanding this harmony dates back to the ancient Greek philosophers who sought to unveil the elements that constitute beauty, going from the Egyptian sculptures that showed complex facial harmony to studies by Renaissance artists such as Michelangelo and Leonardo da Vinci, who sought concrete measurements for facial proportions. From this accumulated knowledge we have inherited notions on the facial aesthetics currently applied.[1]

Thus, professionals working with facial aesthetics should be aware of the ideal facial proportions to correctly indicate procedures to their patients, because an incorrect analysis leads to inappropriate conclusions.[2] In this sense, one should bear in mind concepts such as proportion, symmetry, and harmony. Nonetheless, facial volume, contour, and surface are important elements to be considered.

People have been increasingly concerned about having a beautiful physical appearance and retaining a youthful appearance as they age. In this context, patients seek minimally invasive procedures regarding cosmetic facial treatment, due to both the growing number of patients in different stages of life who desire to improve their facial appearance, and also due to the fact that fillers and neuromodulators are more widely available in the market.[1,3]

The aging process may be intrinsic and extrinsic and is influenced by environmental factors and genetics. The intrinsic process corresponds to skin atrophy and laxity and development of bags and folds due to the effects of gravity throughout time (►**Fig. 1**). These conditions may be more effectively treated by means of surgeries for muscle repositioning and removal of excess skin and periorbital bags. On the other hand, extrinsic aging is related to photoaging and smoking, in which the damage to the epidermis and dermis causes static wrinkles, dryness, and spots (►**Fig. 2**). In these cases, treatment with peels, lasers, whitening agents, fillers, and botulinum toxin provides favorable results.

Next, we describe some minimally invasive procedures routinely performed by our team that aim at improving the facial aesthetics.

Issue Theme Facial Plastic Surgery in Latin America; Guest Editor, Roxana Cobo, MD

Copyright © 2013 by Thieme Medical Publishers, Inc., 333 Seventh Avenue, New York, NY 10001, USA. Tel: +1(212) 584-4662.

DOI http://dx.doi.org/10.1055/s-0033-1347004.
ISSN 0736-6825.

Downloaded by: World Health Organization (WHO). Copyrighted material.

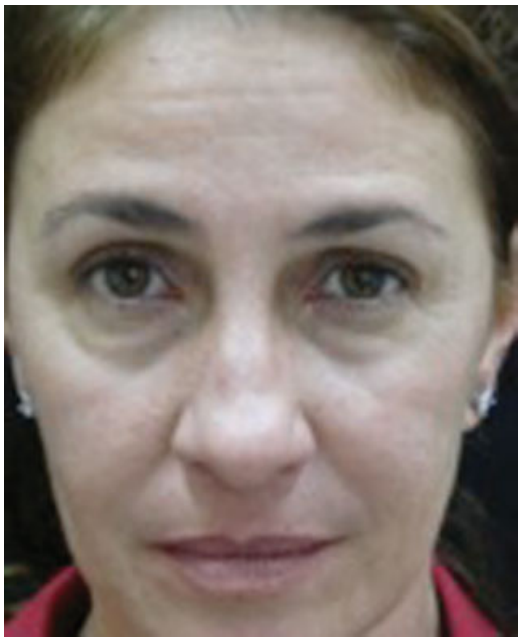

Fig. 1 Intrinsic aging.

Aesthetic Analysis of the Face

The development of skills in facial analysis is key to achieving good results in aesthetic procedures. Even a well-performed procedure may produce unsatisfactory results if an inappropriate facial analysis has led to wrong decisions.[2]

In the frontal view, the face is divided into vertical fifths by lines traced adjacent to the lateralmost projection of the face, to the outer corner of the eyes, and to the inner corner of the eyes. It is also divided into thirds by horizontal lines traced adjacent to the chin, the subnasal point, the glabella, and the hairline.

Harmony of the upper third of the face may be assessed using Leonardo da Vinci's golden proportion. In women, the ideal relationship between the palpebral fissure and the distance between the edges and the eyebrow is 1:1.618. In men, the relationship is reversed: the proportion of the palpebral fissure is 1.618 and the distance between the edge and eyebrow is 1 (►**Fig. 3**).

The lower third is subdivided into an upper part, between the subnasal point and the stomion, and a lower part, between the stomion and the chin. The ratio between these parts is 1:2.[4]

Botulinum Toxin

Botulinum toxin (BT), produced by the anaerobic bacterium *Clostridium botulinum*, was first used therapeutically in the 1980s by Dr. Allen Scott for the treatment of strabismus.[5] This amazing substance acts by binding to specific proteins on the presynaptic membrane, thus inhibiting acetylcholine release at the neuromuscular junction. Thus, the electrical impulse is not transmitted, resulting in muscle paralysis. Seven different serotypes of BT have been described (A, B, C, D, E, F, and G). However, only toxins A and B are available as medications.

In 1987, Dr. Jean Carruthers observed that many patients treated for benign idiopathic blepharospasm with BT type A (BTX-A) showed significant improvement of their glabellar frown lines. After this finding, Dr. Alastair and Dr. Jean Carruthers conducted systematic studies on the use of BT for cosmetic purposes. In 1992, they published their findings in a document that had a great impact, showing the safety and efficacy of the treatment of glabellar frown lines with BTX-A.[6]

The main objective of the treatment with BT is to cause selective paralysis. To this end, the correct application in the desired site is essential.

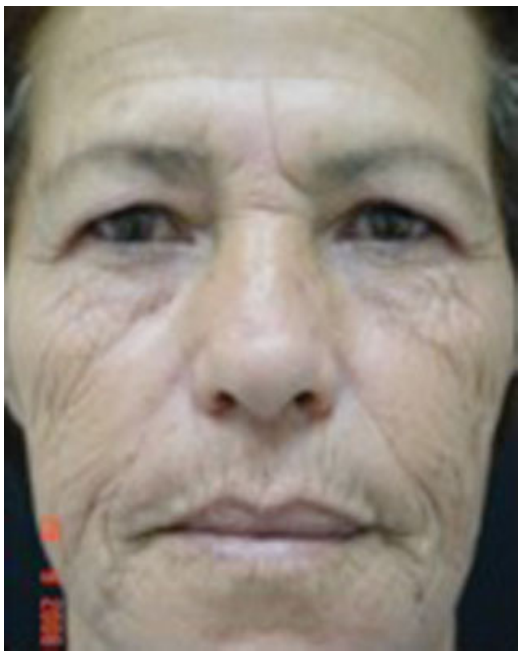

Fig. 2 Extrinsic aging.



Fig. 3 (A) Divine proportion in a woman and (B) in a man.

Downloaded by: World Health Organization (WHO). Copyrighted material.

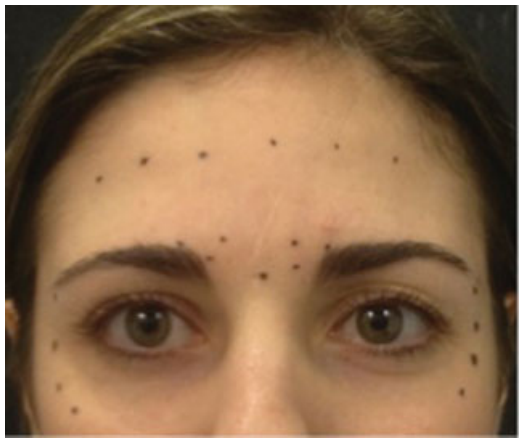

Fig. 4 Markings used to inject the frontal region.

Frontal Region

In this region, BT is indicated in two situations: for expression wrinkles caused mainly by contraction of the frontalis muscle, or to improve the position of the eyebrow itself. The vial of BT is diluted in saline solution (Botox [Allergan, Irvine, CA] in 2 mL and Dysport [Ipsen Biopharm Ltd., Paris, France] in 3 mL).

The position of the eyebrow is determined by the balance between the muscles that pull it upward and downward. The first ones are the frontal bellies of the occipitofrontalis muscles. The muscles that pull the eyebrows downward are the orbicularis oculi, in their orbital portion; the depressor supercilii muscle; the central portion of the procerus; and the corrugator supercilii muscles with their respective bellies—the transverse belly, which is more horizontal, and the oblique belly, which is more vertical.

The author's preference for marking the points where BT will be applied follows the guidelines described below.

In the frontal region, the points are marked every 2 cm, using 2 U of BT per point. In the medialmost line of the forehead two to three points are marked. It is important to observe a space situated between 2 cm and 2.5 cm above the eyebrow to avoid eyelid ptosis. If the patient presents with more expression wrinkles, two lines should be marked (instead of one), with the second line closer to the hairline. The forehead is divided into two halves in which three points are marked on each side, and 2 U of BT is applied per point (►**Fig. 4**). Thus, the expression wrinkles can be reduced or even eliminated from the frontal region (►**Fig. 5**).

On the glabellar area, 2 U of BT is applied per point in the region of the procerus muscle to correct horizontal wrinkles. One or two points are marked.

In the area of the corrugator supercilii muscles, where wrinkles are vertical, one point is marked on each portion (head, transversal, and oblique portions), for a total of two to three points on each side.

In the lateral portion of the orbicularis oculi muscle, four points are marked. A point is marked on the eyebrow tail to elevate it by means of the paralysis of the lateral portion of the orbicularis oculi muscle. Below it, three more points are marked 1 cm apart from each other and 1 cm from the orbital rim. Thus, the periorbital wrinkles, also known as crow's-feet, can be attenuated.

Nasal Region

The nasal muscle is characterized by producing a strong contraction, which results in "bunny lines." Care should be taken not to apply a large amount of BT in this region, because its effect may spread and reach the levator alaeque nasi and anguli oris muscles. BT (4 to 5 U) is applied on each side, and care should be taken not to apply too laterally.

Depressor Anguli Oris Muscle

BT (1 to 2 U) is applied in each point marked 1 cm laterally and below the oral commissure. Thus, the corners of the mouth are lifted. This procedure is usually indicated for patients whose mouth gives them an unhappy look, in which the lateral area is lower than the central area.

Mentalis Muscle

Patients presenting with chin retraction contract the mentalis muscle strongly. In this area, four to six points are marked, depending on the patient's degree of contraction.

Phenol Peel

Application of caustic chemicals to improve the facial appearance and reverse the actinic damage to the skin has been used for centuries. However, in the past few decades the use of caustic chemicals has become more systematized.

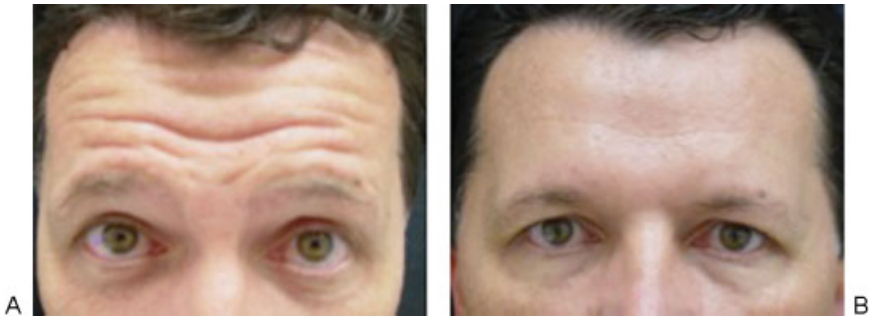

Fig. 5 (A) Before and (B) after Dysport application in the frontal region.

Downloaded by: World Health Organization (WHO). Copyrighted material.



Fig. 6 (A) Before and (B) after deep peel (phenol).

The indications, patient selection, armamentarium, histology, comprehension of the mechanisms of action, and safety parameters of peels have only recently been defined.

Phenol peels provide the most life-changing and effective results. However, they have the highest potential for systemic and local complications, especially hypopigmentation. They are indicated for patients with fair skin and provide significant improvement of wrinkles and actinic spots (►**Fig. 6**). Possible complications include arrhythmia, long-lasting erythema, hypopigmentation, hypertrophic scar, and keloid.

Medium peels may provide good results, although not as noticeable as those of deep peels. Ideal for mild changes, medium peels improve spots and wrinkles with a lower potential for systemic toxicity. On the other hand, local complications such as scars and pigmentary anomalies should not be underestimated.

Superficial peels do not correct imperfections caused by aging and sun exposure completely. Nonetheless, if performed repeatedly, they may improve spots and minor changes of the skin surface, providing a more youthful appearance. This procedure is relatively safe, although the risk of pigmentary changes exists.[6]

The choice of an adequate technique and type of peel is based on the analysis of the skin defects and the patient's desire, considering the risks of the procedure. Chemical peels combined with other cosmetic procedures provide significant improvement of the facial aesthetics.[7]

Fillers

Types of Fillers

The most widely used fillers for facial rejuvenation are autologous fat, collagen, hyaluronic acid, and biosynthetic polymers. They are manufactured in a laboratory or obtained from the patients themselves (autologous implants), from other humans (allogeneic implants), or from animals or bacteria (heterologous implants).[8]

Fillers may be classified as temporary, semipermanent, or permanent according to the degree of absorption after injection. Temporary or absorbable fillers provide temporary results, and repeated applications are necessary to maintain the desired result. Semipermanent fillers last longer than temporary fillers; however, they are also reabsorbed. Only permanent fillers provide long-term results after a single application, because they remain in the tissue indefinitely. For this reason, restrictions apply to the use of permanent fillers regarding their safety and long-term adverse effects.

In this sense, important characteristics should be considered when choosing a filler for a safe, effective, and easy application. Fillers are considered safe when they are biocompatible, are hypoallergenic, do not migrate, and cause minimal pain.

Fillers show different biocompatibility, and this determines their texture and applicability. Thus, there is no universal filler, but different indications for each type of filler.[9]

The author's product preference is hyaluronic acid (injected with needles), polymethyl methacrylate (injected with cannulas 50 × 0.8), and autologous fat (injected with Tulip [Tulip Medical Products, San Diego, CA] cannulas), depending on the indication and the region to be filled.

Orbital Region

In the early stages of life, the transition between the lower eyelid and the malar region is not noticed. With aging, not only are eyebrow and eyelid ptosis observed, but the formation of an infraorbital fold is also observed, due to the gravitational action and decreased tension of the elastic and collagen fibers of the skin and ligaments.[9] Because these fibers are responsible for fixation of the periosteum to the region of the orbital septum, a reduction in their tension results in the demarcation of the orbital rim (►**Fig. 7**). This can be surgically treated by means of blepharoplasty combined with repositioning of the orbital fat or using minimally invasive therapies.

Hyaluronic acid should be applied in the infraorbital area using low pressure to prevent accidental injection in intraorbital vessels.[10] The author's preference is for the serial puncture technique instead of the retrograde (linear threading) technique. This way, the amount of product injected is thought to be more easily controlled thus preventing uneven surfaces (►**Fig. 8**).

Downloaded by: World Health Organization (WHO). Copyrighted material.

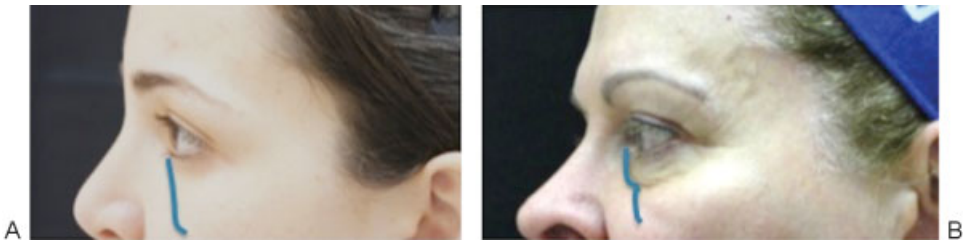

Fig. 7 Infraorbital fold in (**A**) a young person and (**B**) an elderly person.



Fig. 8 (**A**) Before and (**B**) after of Restylane (Q-Med AB, Uppsala, Sweden) application in the infraorbital fold.

Some patients may present with sunken eyes due to a deep upper eyelid fold. This feature may be more pronounced with age due to the loss of orbital volume. In this sense, with the application of hyaluronic acid in the roof of the orbit, a more youthful and rested appearance is achieved. To observe this feature, one should bear in mind da Vinci's golden proportion (►**Fig. 9**).

Malar Region

In this area, the product is applied in a deep plane and care should be taken not to apply it too laterally to prevent artificial results. On average, 0.2 to 0.5 mL are used on each side. The author's preference for this area is Juvéderm Voluma (Allergan) and polymethyl methacrylate (Linnea-Safe 30%—Lebon Produtos Quimicos e Farmaceuticos, Porto Alegre, Brazil).

Also, the submalar region can be filled in its subcutaneous plane to provide a slight local convexity.

Nasolabial Fold

Application is performed in two planes. Initially, 0.5 mL of the product is applied by means of a cannula in the fold area close to the nasal wing perpendicular to the skin. Next, the cannula is directed toward the fold and the product is applied in the plane as recommended by the manufacturer. The total amount to be applied is customized according to the depth of the fold (►**Fig. 10**).



Fig. 9 (**A**) Before and (**B**) after Juvéderm (Allergan) application in the roof of the orbit.



Fig. 10 (**A**) Before and (**B**) after Juvéderm Ultra (Allergan) application in nasolabial folds.

Downloaded by: World Health Organization (WHO). Copyrighted material.



Fig. 11 (A) Before and (B) after polymethyl methacrylate 30% application in prejaw region.



Fig. 12 (A) Injection sites for filler agents in prejaw region, chin, and (B) mandible.

Mandibular Contour

The mandibular contour is made more evident by the mandibular angle, prejaw region, and chin. In these areas, long-lasting hyaluronic acid such as Juvéderm Voluma or Restylane SuQ (Q-Med AB) and permanent fillers such as polymethyl methacrylate 30% are preferred. Calcium hydroxyapatite, such as Radiesse (Merz Aesthetics Inc., San Mateo, CA), can also be used.

The round shape of the chin area should be attenuated. Fillers are used to increase its projection and change its u shape into a v shape. Application is made in two points 1 cm apart from the mandibular symphysis on average. The cannula is placed perpendicular to the skin, touching the chin bone (juxta-osseous), and 0.5 to 1 mL of filler is applied in each point. The chin is thus projected, forming an angle between the mandibular body and the chin.

In the prejaw region, subcutaneous application is preferred to smooth the transition from the chin to the jaw. Between 0.2 and 0.3 mL of filler is used on each side (►**Fig. 11**).

The mandibular angle can be filled to increase projection and change the inclination of the mandibular plane. A point is marked in the most projected site of the mandibular angle. A cannula is used to apply 0.5 mL of the product perpendicular to the skin and close to the bone to project the mandibular angle (►**Fig. 12**). Subsequently, the cannula is directed toward the ascending mandibular branch and the application is made using the retrograde technique. The cannula is then pointed toward the chin and a similar application is made. In all, 1.5 mL is applied on each side, on average.

Patients eligible for chin projection usually present with a larger opening between the mandibular plane and the Frankfurt plane, which shows a vertical facial overgrowth. When volume is injected in the chin and mandibular angle, a better facial proportion is achieved (►**Fig. 13**).

Conclusion

Recently, patients have been seeking skin rejuvenation to achieve a youthful appearance through minimally invasive procedures. There are numerous products available on the market, so an understanding of each of them, the injection techniques, the indications, and the potential complications are crucial to their successful use. Nevertheless, patients and physicians should keep in mind that aging is an inevitable biological process, and a good look comes from reasonable treatments for a balanced, holistic, and natural result.

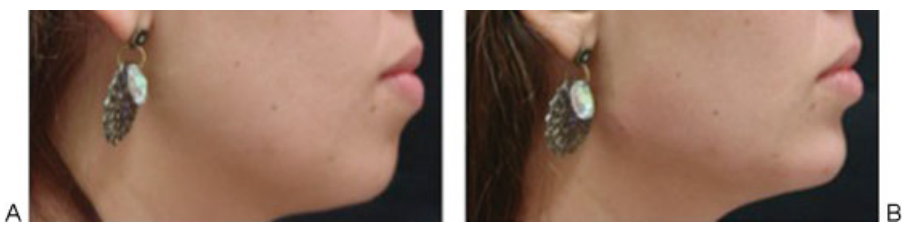

Fig. 13 (A) Before and (B) after polymethyl methacrylate 30% in the chin.

Downloaded by: World Health Organization (WHO). Copyrighted material.

References

1 Patel U, Fitzgerald R. Facial shaping: beyond lines and folds with fillers. J Drugs Dermatol 2010;9(8, Suppl ODAC Conf Pt 2):s129–s137
2 Tollefson TT, Sykes JM. Computer imaging software for profile photograph analysis. Arch Facial Plast Surg 2007;9:113–119
3 Maas CS, Bapna S. Pins and needles: minimally invasive office techniques for facial rejuvenation. Facial Plast Surg 2009;25:260–269
4 Gunter JP, Hackney FL. Clinical assessment and facial analysis. In: Gunter JP, Rohrich RJ, Adams WP, eds. Dallas Rhinoplasty: Nasal Surgery by the Masters. Vol. 1. St. Louis, MO:Quality Medical Publishing Inc; 2007:105–123
5 Scott AB, Magoon EH, McNeer KW, et al. Botulinum treatment of childhood strabismus. Opthalmology 1990;97(11):1434–1438
6 Carruthers JDA, Carruthers JA. Treatment of glabellar frown lines with C. botulinum-A exotoxin. J Dermatol Surg Oncol 1992;18:17–21
7 Matarasso SL, Glogau RG. Chemical face peels. Dermatol Clin 1991;9:131–150
8 Buck DW II, Alam M, Kim JYS. Injectable fillers for facial rejuvenation: a review. J Plast Reconstr Aesthet Surg 2009;62:11–18
9 Carruthers J, Cohen SR, Joseph JH, Narins RS, Rubin M. The science and art of dermal fillers for soft-tissue augmentation. J Drugs Dermatol 2009;8:335–350
10 Wollina U, Payne CR. Aging well—the role of minimally invasive aesthetic dermatological procedures in women over 65. J Cosmet Dermatol 2010;9:50–58

Downloaded by: World Health Organization (WHO). Copyrighted material.