Facelift without Periauricular Incisions

Alfonso Riascos, MD[1]

[1] Department of Plastic Surgery, Centro Medico Imbanaco, Cali, Colombia

Address for correspondence Alfonso Riascos, MD, Centro Medico Imbanaco–Plastic Surgery, Cra. 39 5A-91 Cali Valle 2, Colombia (e-mail: alfonsoriascos@gmail.com; alfonso.riascos@imbanaco.com.co).

Facial Plast Surg 2013;29:225–232.

Abstract

The best technique for facial rejuvenation has been argued about for years. Some result in more or longer scars, others in fewer or shorter scars; some techniques are more invasive, and some less invasive, giving, in turn, improvements to different aspects of aging. Some techniques may be less aggressive in parts of the face and may have better scar results compared with more invasive techniques; less scaring can provide long-lasting and enjoyable results. With the facelift without periauricular incision technique, no evidence of facial surgery is left because the traditional periauricular scars resulting from standard facelifts are avoided. A retrospective study of 210 patients who underwent a facelift without preauricular incisions between 2008 and 2011 showed a high patient satisfaction, effective action on effects of aging, and improvement on specific aspects for each patient. The complication rate was very low with simple revisions, among which were two related to temporal edema, two related to the marionette lines, three related to cervical suspension points, and four regarding scars. This technique is useful in patients between 40 and 70 years of age who do not have excessive facial wrinkles. It improves facial contour affected by aging, genetics, or secondary to previous surgeries and provides reproducible lasting natural results.

Keywords
- periauricular
- facial rejuvenation
- plication
- autologous grafts
- facelift

Genetics is the most important cause of loss of facial contour and youthful appearance. It makes each person age at his or her own rate. Aging is also affected by environment-related factors such as smoking, sun exposure, and changes in body weight.[1,2]

There is loss of elastic and collagen fibers, ligamentous laxity, localized fat deposits, tissue atrophy, and absorption (including muscle, skin, and bone). All of these contribute to tissue ptosis.

Patients who ask for a facelift usually complain about issues such as nasolabial folds, marionette lines, and excessive skin on the jowl and the neck without realizing that these issues appear on the face but are noticeable because they are the result of descended (ptosis) tissue that leaves the upper face somehow empty, with depressions that characterize facial aging, especially in the malar and inferior periorbicular region (►**Fig. 1**).

Some techniques are more invasive and may also bring greater risk of complications.[3–5] Other techniques improve some but not other parts of aging. There are less invasive techniques resulting in fewer scars that can bring excellent results,[6] and other procedures with less encouraging results that can leave bigger scars.

We started using the facelift without periauricular incision (FWOPI) technique in 2008 to harmonize the effects of age on our patients, making a sequence of new procedures and applying some maneuvers that have been previously used and described for other traditional techniques such as the following.

In the lower third of the face, we use fat suction, wide subcutaneous dissection, cervical platysma muscle placations,[7] and suspensions using nonabsorbable sutures placed subcutaneously in the neck.[8]

We do not make periauricular incisions in the middle third of the face, instead a horizontal temporal incision is done and a wide dissection of the midface at the subcutaneous level, superficial musculoaponeurotic system (SMAS) plication or suspension, tissue restructuring with autologous grafting, and skin tightening.

Issue Theme Facial Plastic Surgery in Latin America; Guest Editor, Roxana Cobo, MD

Copyright © 2013 by Thieme Medical Publishers, Inc., 333 Seventh Avenue, New York, NY 10001, USA. Tel: +1(212) 584-4662.

DOI http://dx.doi.org/10.1055/s-0033-1347005.
ISSN 0736-6825.

Downloaded by: World Health Organization (WHO). Copyrighted material.



Fig. 1 Facial aging may lead to imbalanced lower- and midfacial contours and volumes.

In the upper third of the face, we use blepharoplasty, eyebrow suspension or lift, Botox (Allergan, Irvine, CA), or muscular ablations.

Technique

We used the FWOPI technique on a total of 210 patients (20% men), avoiding patients with excessive skin redundancy, patients with too many wrinkles, patients with expectations of significant skin stretching, and patients who previously had undergone a facelift (who already had periauricular scars). The age range was 44 to 78 years with an average of 53, and 20% of the patients were men.



Fig. 2 Neck suspension is produced with subcutaneous polypropylene sutures.



Fig. 3 The polypropylene suture loops are crossed submentally.

Markings were done on the patient's face while sitting or standing, planning what we would do in surgery with special emphasis on the tissues to be repositioned and depressions to be treated (►**Fig. 1**).

The procedure was performed under local anesthesia and sedation, using some drugs such as cephalosporins (antibiotic prophylaxis) and Catapresan ([Boehringer Ing. Pharma, Ingelheim am Rhein, Germany] to keep a stable blood pressure).

Initial infiltration of the abdominal region was performed in the places from which the graft (if needed) would be taken. The face was infiltrated with a number 1.2 needle per 10-cm-long cannula using ~ 100 mL of solution (saline solution, 0.5% lidocaine, 1:200,000 epinephrine) for each side starting with the area of the neck, the mastoid area at the auriculomastoid junction, and the jowl. We then continued widely infiltrating the middle third of the face.



Fig. 4 Polypropylene sutures are fixed to the mastoid periosteum through small retroauricular incisions.

Downloaded by: World Health Organization (WHO). Copyrighted material.



Fig. 5 The temporal incision is made behind the hairline in an irregular pattern. Scissors are beveled to preserve hair follicles maximally.

A 3-cm submental incision was done for neck liposuction and to make an extensive cervical dissection at the subcutaneous level using scissors. The platysma bands were approximated medially using four to five absorbable sutures.[9–11] A 3 × 30-cm curved cannula and two Prolene (Ethicon, Somerville, NJ) 2–0 sutures were used to create suspension of the platysma and neck tissues.[12,13] The suspension was achieved by the two superficially placed Prolene sutures (Gore-Tex [W.L. Gore & Associates, Newark, DE] sutures can also be used; ►**Fig. 2**) cross-linked in the midline (►**Fig. 3**) and fixed deep in the mastoid periosteum on each side (►**Fig. 4**) to bring a nice contour to the neck angle.[14] The retroauricular incision was closed with one 4–0 Monocryl (Ethicon) stitch.

A horizontal temporal incision was done starting from the auricular apex in a zigzag manner,[15] with the scalpel and the scissors inclined to preserve the hair follicles in the cut (►**Fig. 5**). This incision went, according to each case, along but 2 mm in the hairline to a level above the tail of the eyebrow. From here we made a wide subcutaneous dissection that could be joined inferiorly with the submandibular (neck) incision (►**Fig. 6**). Three to five separate 4–0 Monocryl stitches were given to the SMAS (sometimes a continuous running suture) to bring it and the internal tissues up vertically as far as possible for each patient to mobilize these tissues.



Fig. 6 A subcutaneous flap is dissected and may connect to the cervical dissection.



Fig. 7 Temporal skin is redraped and resected.



Fig. 8 A preauricular roll is sometimes created.



Fig. 9 A running suture closes the temporal incision.

Downloaded by: World Health Organization (WHO). Copyrighted material.



Fig. 10 Preoperative view.



Fig. 12 Preoperative view of a 52-year-old patient.

Autologous tissue grafts were introduced as deeply as possible in the malar and submalar area as previously marked, always in 0.33-mL amounts per site, with a self-curved cannula, which was carefully maneuvered to distribute the graft. For this tissue restructuring, ~ 10 mL of autograft was used on each side and then distributed evenly with finger pressure.

Cephalic skin traction was done at the incision site to resect skin redundancy (2 to 4 cm was excised; ►**Fig. 7**), placing the first subdermal stitch (4–0 Monocryl suture) at the anterior sideburn line and four or five more subdermal stitches to compensate for the skin excision, sometimes creating a preauricular deformity (►**Fig. 8**). After draining some of the infiltrated solution through the temporal and



Fig. 11 Same patient as ►**Fig 10**, 6 months after superficial musculoaponeurotic system plication and 11 mL of midfacial fat grafting.



Fig. 13 Six months after facelift without preauricular incision.

Downloaded by: World Health Organization (WHO). Copyrighted material.



Fig. 14 Preoperative view of a 47-year-old patient.

submental incisions, the temporal skin was closed with a 4–0 Prolene running suture compensating back toward the auricular vertex (►**Fig. 9**), and the submental incision was closed with three subdermally placed 4–0 Monocryl stitches.

A soft dressing was placed for 24 hours and no drains were left. The patients went home after staying 3 to 4 hours in the recovery room.

Results

The ideal FWOPI patients do not have too much skin laxity or too many wrinkles, and are between 40 and 65 years of age.

The majority of patients need additional procedures (blepharoplasty, peelings, Botox, laser, etc.), and these can be easily done at the same time without complications or skin suffering.

A 57-year-old patient after neck tightening and suspension, SMAS plication, skin cephalic tightening, and 11 mL of malar autografting on each side is seen on the preoperative (►**Fig. 10**) and 6-month postoperative images (►**Fig. 11**).

Postoperative and 6-month postoperative images can be seen in ►**Figs. 12** and **13** for a 52-year-old patient. A reddish scar with hair growing into it can be seen in ►**Fig. 13**.

A patient (47 years old) with signs of aging starting to appear preoperatively is seen in ►**Fig. 14**. The same patient after neck suspension, SMAS plication, 9 mL of autograft placed to each malar site, and 4 cm of skin cephalically excised is shown 6 months postoperatively (►**Fig. 15A**) and 8 months postoperatively (►**Fig. 15B**).

After a full FWOPI, a 59-year-old patient is shown preoperatively (►**Fig. 16**) and 1 year postoperatively, preserving what was done in the surgery when she returned to the office because a little red dimple appeared over the left temporal scar (►**Fig. 17**). A fragment of one of the monofilament absorbable sutures was producing this reaction and had to be simply pulled out of the scar to resolve the problem.

A preoperative image of a 61-year-old patient is seen in ►**Fig. 18**. A close-up of the periauricular area where the initial deformity can be seen 1 week postoperatively (►**Fig. 19**). One-year postoperative image preserving the surgical achievements is seen in ►**Fig. 20** and another image showing no deformity and no scars on a close-up of the periauricular area is seen in ►**Fig. 21**.

Some temporal scar healing problems were seen in these four patients: one of them had a small keloid at the upper auricular vertex, one had a 6-mm scar dehiscence, and two had a small portion of wide scarring in the temporal region. All of these problems were solved under local anesthesia at the office.



Fig. 15 (**A**) Six months after facelift without preauricular incision. (**B**) Same patient, 8 months after surgery.

Downloaded by: World Health Organization (WHO). Copyrighted material.



Fig. 16 Preoperative view of a 59-year-old patient.



Fig. 18 Preoperative view of a 61-year-old patient.

Three cases reported loss of the cervical angle months after the FWOPI was done. Two required exchange of the Prolene sutures because of suture rupture and one because of failure of the Prolene anchoring stitch on one side. After these were replaced, all cases recovered their neck suspensions.

Two patients had asymmetric edema for the first 20 days that resolved without treatment.

Two patients had previous fibrosis in the area of the neck with some irregularities secondary to previous surgery. This improved ~ 70%, and the patients were satisfied and felt nothing needed to be done to further correct this.

In addition to this, two patients showed little improvement on the marionette lines (by the mouth). These were



Fig. 17 A suture granuloma at the inferior extent of the wound required removal of a dermal suture.

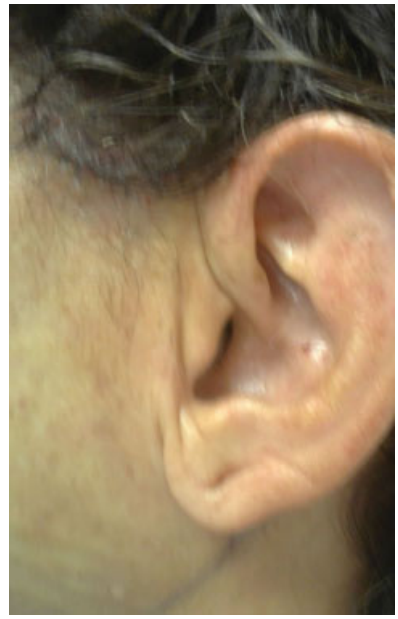

Fig. 19 A preauricular "roll" of redundant skin is seen 1 week after surgery.

Downloaded by: World Health Organization (WHO). Copyrighted material.



Fig. 20 Excellent results seen 1 year after surgery.

treated, one with fat grafting and the other with a dermal filler.

We find that there is great satisfaction among patients and that this contributes to the request of this surgical technique by some other referred patients.



Fig. 21 Close up view shows resolution of the preauricular skin redundancy.

Discussion

Our experience with 210 consecutive patients who underwent FWOPI has been positive, always with excellent results and very few complications.

The FWOPI is very effective for patients with signs of aging and relatively good skin elasticity or patients who have genetically inherited inadequate neck and middle third facial contours. It is also perfect to be done in patients between 50 and 70 years of age who do not have too many wrinkles or too much skin excess. It is also a very good procedure for patients who have previously undergone facial surgery and who wish to improve their results.

The FWOPI can be done as an independent procedure or associated with some ancillary procedures generating more tissue trauma with great confidence and without complications.

Many techniques have been used in the past 50 years to reverse the signs of aging and restore youth to the face. Some focus more on specific aspects such as the neck, others more toward the upper and midface. Some techniques try to encompass all aspects of aging and use different tools such as suture suspensions, implants, and endoscope.

The FWOPI focuses the treatment of the neck and the middle third of the face as it has been used traditionally for years combined with some newer techniques and maneuvers. These involve wide subcutaneous dissections, medial plications of the platysma bands, suspension with nonabsorbable sutures for better and longer-lasting results, treatment to the subdermal tissues as SMAS plication (or suspension), and tissue restructuring associated with autologous grafts, which allows us to improve many aspects of aging.

Having a preauricular deformity in the early postoperative days is not a problem, as this area returns to normal in the first 20 days.

Those patients operated on with this technique have seen effective, durable, and natural-looking results with less swelling, less edema, and a short recovery time.

Patients with platysma bands or with fat deposits had neck tissue suspension to ensure that over the years, as tissues turn ptotic, the skin remains in place.

We can use FWOPI instead of the traditional facelift procedures as we can remove some skin excess from the neck. The neck dissection is joined with the midface dissection, and this allows the transfer of some sagging neck skin to be raised upward.

Although the FWOPI can be used at the same time with other well-known techniques, it allows wonderful results without preauricular scars.

The results of our series of 210 consecutive patients with 4-year follow-up have shown that, with proper patient selection, FWOPI provides excellent results on patients between 40 and 70 years of age. Although for some patients older than 70 years, the technique is fascinating because it leaves them no stigma of surgery and the changes are very natural.

The FWOPI is an effective technique, well received by the patients, and can be reproduced by other surgeons.

Downloaded by: World Health Organization (WHO). Copyrighted material.

References

1 Gonzalez-Ulloa M, Flores ES. Senility of the face—basic study to understand its causes and effects. Plast Reconstr Surg 1965;36: 239–246

2 Lin AN, Carter DM, Balin AK. Nonmelanoma skin cancers in the elderly. Clin Geriatr Med 1989;5(1):161–170

3 Skoog T. Plastic Surgery: New Methods and Refinements. Philadelphia, PA: WB Saunders; 1974:393–410

4 Mitz V, Peyronie M. The superficial musculo-aponeurotic system (SMAS) in the parotid and cheek area. Plast Reconstr Surg 1976;58:80–88

5 Ramirez OM, Maillard GF, Musolas A. The extended subperiosteal face lift: a definitive soft-tissue remodeling for facial rejuvenation. Plast Reconstr Surg 1991;88:227–236, discussion 237–238

6 Baker DC. Minimal incision rhytidectomy (short scar face lift) with lateral SMASectomy: evolution and application. Aesthet Surg J 2001;21:14–26

7 Fuentedel Campo A. Midline platysma muscular overlap for neck restoration. Plast Reconst Surg 1998;102:1710–1715

8 Feldman JJ. Corset platysmaplasty. Plast Reconstr Surg 1990;85: 333–343

9 Guerrerosantos J. Managing platysma bands in the aging neck. Aesthet Surg J 2008;28:211–216

10 Giampapa VC, Di Bernardo BE. Neck recontouring with suture suspension and liposuction: an alternative for the early rhytidectomy candidate. Aesthetic Plast Surg 1995;19:217–223

11 Giampapa V, Bitzos I, Ramirez O, Granick M. Suture suspension platysmaplasty for neck rejuvenation revisited: technical fine points for improving outcomes. Aesthetic Plast Surg 2005;29:341–350, discussion 351–352

12 Ramirez OM, Robertson KM. Comprehensive approach to rejuvenation of the neck. Facial Plast Surg 2001;17:129–140

13 Camirand A, Doucet J. A comparison between parallel hairline incisions and perpendicular incisions when performing a face lift. Plast Reconstr Surg 1997;99:10–15

14 Stuzin JM, Baker TJ, Gordon HL, Baker TM. Extended SMAS dissection as an approach to midface rejuvenation. Clin Plast Surg 1995;22:295–311

15 Matarasso A, Elkwood A, Rankin M, Elkowitz M. National plastic surgery survey: face lift techniques and complications. Plast Reconstr Surg 2000;106:1185–1195, discussion 1196

Downloaded by: World Health Organization (WHO). Copyrighted material.