ntraoperative flow cytometry analysis of glioma tissue for rapid determination of tumor presence and its histopathological grade
Clinical article

Takahiro Shioyama, Ph.D.[1,6], Yoshihiro Muragaki, M.D., Ph.D.[2,3], Takashi Maruyama, M.D., Ph.D.[2,3], Takashi Komori, M.D., Ph.D.[1,4,5], and Hiroshi Iseki, M.D., Ph.D.[2,3]

[1]Institute of Advanced Biomedical Engineering and Science; [2]Faculty of Advanced Techno-Surgery, Graduate School of Medicine; [3]Departments of Neurosurgery and [4]Pathology, Tokyo Women's Medical University; [5]Laboratory of Brain Tumor Pathology, Department of Brain Development and Regeneration, Tokyo Metropolitan Institute of Medical Science; and [6]Nihon Kohden Corporation, Tokyo, Japan

Abbreviations used in this paper: AUC = area under the curve; HSD = honestly significant difference;iFC = intraoperative flow cytometry; MI = malignancy index; PBS = phosphate-buffered saline; ROC = receiver operating characteristic; 5-ALA = 5-aminolevulinic acid.

Address correspondence to: Yoshihiro Muragaki, M.D., Ph.D., Faculty of Advanced Techno-Surgery, Institute of Advanced Biomedical Engineering and Science, Tokyo Women's Medical University, 8-1 Kawada-cho, Shinjuku-ku, Tokyo 162-8666, Japan. email: ymuragaki@abmes.twmu.ac.jp.

Please include this information when citing this paper: published online February 22, 2013; DOI: 10.3171/2013.1.JNS12681.

Abstract

OBJECT

Intraoperative histopathological investigation plays an important role during surgery for gliomas. To facilitate the rapid characterization of resected tissue, an original technique of intraoperative flow cytometry (iFC) was established. The objective in this study was evaluation of this technique's efficacy for rapidly determining tumor presence in the surgical biopsy sample and WHO histopathological grade of the neoplasm.

METHODS

In total, 328 separate biopsy specimens obtained during the resection of 81 intracranial gliomas were analyzed with iFC. The evaluated malignancy index (MI) was defined as the ratio of the number of cells with greater than normal DNA content to the total number of cells. The duration of iFC in all cases was approximately 10 minutes. Each sample was additionally investigated histopathologically on frozen and permanent formalin-fixed paraffin-embedded tissue sections. The latter process was used as a “gold standard” control for evaluation of the diagnostic efficacy of iFC analysis.

RESULTS

The MI differed significantly between neoplastic and perilesional brain tissue (25.3% ± 22.0% vs 4.6% ± 2.6%, $p < 0.01$). Receiver operating characteristic curve analysis revealed a corresponding area under the curve value of 0.941. The optimal cutoff level of the MI for identification of tumor in the biopsy specimen was 6.8%, which provided 0.88 sensitivity, 0.88 specificity, 0.97 positive predictive value, 0.60 negative predictive value, and 0.88 diagnostic accuracy. Additionally, the MI showed a significant association with WHO histopathological grades of glioma ($p < 0.01$), but its values in Grade II, III, and IV tumors overlapped prominently and were on average 13.3% ± 11.0%, 35.0% ± 21.8%, and 46.6% ± 23.1%, respectively.

CONCLUSIONS

Results of this study demonstrate that iFC with the determination of the MI may be feasible for rapidly determining glioma presence in a surgical biopsy sample.

Related Articles

By Keywords: DNA aneuploidy, DNA content, flow cytometry, glioma,intraoperative histopathological analysis,surgery, oncology

There is growing evidence that the completeness of resection of cerebral glioma has a significant impact on long-term prognosis after surgery.[10,20,23] Because of typical infiltrative growth, total removal of these tumors was rarely possible in the past. Currently, however, available advanced intraoperative techniques significantly facilitate the achievement of such a goal. Real-time integration of the various intraoperative information, including anatomical, functional, and histopathological data, permits the surgeon to achieve the maximal possible removal of the neoplasm with minimal risk of neurological morbidity.[7,15]Nowadays, in fact, total radiological resection of intracranial gliomas, including high-grade and critically located lesions, can be done in 43%–57% of cases.[15,20,22,23] Thus, detailed characterization of resected tissue for precise identification of the tumor border plays an extremely important role.

Histopathological monitoring during surgery for parenchymal brain tumors can be based on either neurochemical navigation, particularly with 5-ALA,[2,12,23] or direct microscopic investigation of the tissue specimen on stained frozen or smear sections and touch preparations.[17–19,21,24] Both techniques have known limitations, however. Identifying residual lesion based on the incorporation of 5-ALA may be less effective in low-grade neoplasms or at the border between glioma and edematous peritumoral brain.[2] At the same time intraoperative histopathological diagnosis strongly depends on the experience of the individual pathologist and may be significantly influenced by the technique of tissue preparation. In particular, the presence of tissue artifacts on frozen sections frequently complicates precise determination of the histopathological tumor grade. Therefore, additional methods for rapid and reliable analysis of biopsy samples are highly desirable.

To facilitate the characterization of resected tissue during brain tumor surgery, our group developed an original technique of iFC. Our objective in the present study was to evaluate the feasibility of this method during resection of intracranial gliomas and to assess its diagnostic efficacy for rapidly determining tumor presence in a biopsy specimen and its WHO histopathological grade.

Methods

Our original technique of iFC of surgical biopsy samples was applied during the resection of 100 intracranial neoplasms. All procedures were performed in the Department of Neurosurgery at the Tokyo Women's Medical University between January 2009 and August 2010. Data were prospectively collected in a constantly maintained computer database. According to the objectives of the present study, 83 tumors with a final histopathological diagnosis of WHO Grade II, III, or IV glioma of astrocytic, oligodendroglial, oligoastrocytic, or ependymal origin were selected for analysis. Two cases were later eliminated from the investigated cohort: the lesion in one case was a recurrent anaplastic astrocytoma, which had been previously subjected to high-dose radiotherapy, whereas the lesion in a second case was a disseminated glioblastoma whose neoplastic cells were microscopically identified exclusively in the subpial regions, and only reactive astrocytes were revealed in brain parenchyma. It was believed that in both of these cases the determination of histopathological tumor grade and/or evaluation of DNA content using iFC could lead to erroneous results. The remaining 81 cases constituted the clinical and histopathological basis of our study and included 67 newly diagnosed and 14 recurrent neoplasms.

Pathological tissue samples were obtained during surgery in 47 men (mean age 44.7 ± 17.2 years) and 34 women (mean age 42.3 ± 15.0 years). The requirement for enrollment was negative preoperative testing for hepatitis B, hepatitis C, HIV, syphilis, parvovirus, and human T-lymphotropic virus. The research protocol was approved by the local ethics committee. Each patient agreed to participate in the study and provided signed informed consent.

Tissue Sampling

Analyzed pathological tissue was sampled from the specific area of interest using forceps under the control of updated neuronavigation based on intraoperative MRI.[15] In total, 328 separate biopsy specimens were taken during the resection of 81 gliomas. Each specimen had a volume of around 3–6 mm^3 and was separated into 3 more or less equal parts with a volume of 1–2 mm^3 each: 1) 1 piece for iFC analysis; 2) 1 piece for intraoperative histopathological examination

on frozen sections; and 3) 1 piece for permanent histopathological investigation on formalin-fixed paraffin-embedded tissue sections. Usually the central part of the specimen was analyzed with iFC, whereas its peripheral parts were sent for histopathological investigation.

Intraoperative Flow Cytometry Analysis

For iFC analysis investigated tissue was placed in a test tube containing 2 ml of mixed reagent consisting of 0.25 μl/ml Triton X-100 in PBS (Kishida Chemical Co., Ltd.), 0.25 mg/ml RNase in PBS (Sigma-Aldrich Co., LLC), 0.05 mg/ml propidium iodide in PBS (Sigma-Aldrich Co., LLC), and PBS (Kishida Chemical Co., Ltd.). The analyzed tissue was disrupted by pipetting for 200 seconds. After confirming that the tissue sample was sufficiently homogenized, it was isolated by pipetting, and cell nuclei were stained with interfacial action agents at room temperature under protection from light for 5 minutes. After that the suspension was filtered by 50-μm mesh nylon, and the measurement of DNA content was started 1 minute later. Human peripheral blood mononuclear cells were stained in the same way to be used as a reference during DNA histogram analysis.

Evaluation of DNA content was done with an EPICS flow cytometer (Beckman Coulter, Inc.). After excitation with a 488-nm laser, the fluorescence of 610 ± 10 nm was checked and measured for 4 minutes at a low sample flow rate (15 μl/minute). The intensity of the fluorescent peak of the stained human peripheral blood mononuclear cells was fixed on the DNA histogram under the scale value of 200. Several areas on the histogram were defined according to the predominance of a specific cell type. Sub-G_0G_1 phase cells, apoptotic cells, and debris corresponded to Area A, G_0G_1 phase (diploid) cells to Area B, S phase cells to Area C, aneuploid cells with an abnormal number of chromosomes to Area D, G_2/M phase cells to Area E, and cells containing more DNA than G_2/M phase cells to Area F (Fig. 1). Thereafter, the malignancy index (MI) was determined as the ratio of the number of cells with greater than normal DNA content to the total number of cells (N), that is: MI = (Area C + Area D + Area E + Area F)/N. If DNA aneuploidy was detected, the DNA index was also calculated as the ratio of DNA content in the aneuploid cells with an abnormal number of chromosomes (Area D) to those in G_0G_1 cells (Area B). If the cells could not be distinguished from the G_2/M phase of diploid cells (DNA index > 1.95), they were not considered aneuploid.

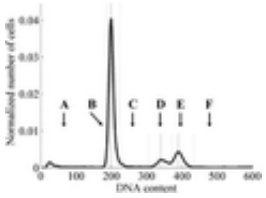

View larger version(31K)

Fig. 1.
Different areas of the typical DNA histogram of glioma. Sub-G_0G_1 phase cells, apoptotic cells, and debris are contained in Area A; G_0G_1 phase (diploid) cells in Area B; S phase cells in Area C; aneuploid cells with an abnormal number of chromosomes in Area D; G_2/M phase cells in Area E; and cells containing more DNA than G_2/M phase cells in Area F.

Histopathological Investigation

Histopathological investigation of the tissue samples on both frozen and permanent tissue sections was performed by the sole board-certified pathologist with sub-specialization in neuropathology (T.K.).

Intraoperative histopathological examination of the frozen tissue sections using H & E staining was mainly directed at identifying tumor presence and its approximate degree of malignancy (low grade vs high grade). Final histopathological diagnosis based on the latest criteria of the WHO[13] was established on the formalin-fixed paraffin-embedded tissue sections stained with H & E and appropriate antibodies for immunohistochemistry. It was used as a “gold standard” for evaluation of the diagnostic efficacy of iFC analysis of the tissue sample. Obtained specimens of peritumoral brain without identifiable neoplastic cells were considered as normal controls.

Statistical Analysis

The Student t-test was applied for comparison of the MI between normal and tumor tissues for each WHO histopathological grade. To evaluate the diagnostic efficacy of the MI in discriminating normal brain tissue and various WHO histopathological grades of glioma, ROC curve analysis was done by calculating the AUC. Of note, an AUC value of 1 denotes a perfect test, whereas a value of 0.5 shows complete lack of discrimination. The Youden index was used to calculate the optimal cutoff value for the MI.[1,11] The occurrence of DNA aneuploidy in tumors with different WHO

histopathological grades was compared using the chi-square test. One-way ANOVA was used to determine the differences for the MI and DNA index in tumors with different WHO histopathological grades. Additionally, the Tukey HSD test was performed to identify significant differences between each group of neoplasms. The level of statistical significance was defined at $p < 0.05$.

Results

Histopathological investigation of the formalin-fixed paraffin-embedded tissue sections revealed 29 WHO Grade II tumors (11 diffuse astrocytomas, 8 oligodendrogliomas, 9 oligoastrocytomas, and 1 ependymoma), 23 WHO Grade III tumors (7 anaplastic astrocytomas, 8 anaplastic oligodendrogliomas, 6 anaplastic oligoastrocytomas, and 2 anaplastic ependymomas), and 29 WHO Grade IV glioblastomas. In none of the cases did we identify a discrepancy in the results as relates to the identification of tumor presence on frozen tissue sections as compared with permanent sections.

The MI of resected gliomas differed significantly from specimens of perilesional brain without histopathologically identifiable tumor (25.3% ± 22.0% vs 4.6% ± 2.6%, $p < 0.01$, Student t-test). The diagnostic efficacy of iFC using various cutoff values of the MI to discriminate between neoplastic tissue and perilesional brain is outlined in Table 1. The ROC analysis revealed a corresponding AUC value of 0.941 (Fig. 2). The optimal cutoff value for the MI, identified with the Youden index, was 6.8%. It provided 0.88 sensitivity, 0.88 specificity, 0.97 positive predictive value, 0.60 negative predictive value, and 0.88 diagnostic accuracy.



TABLE 1:
Diagnostic efficacy of iFC for identification of tumor in biopsy samples, as compared with permanent tissue sections*

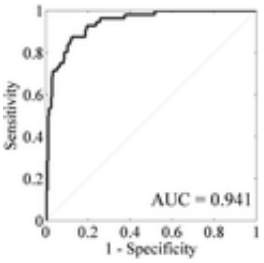

View larger version(30K)

FIG. 2.
Receiver operating characteristic curve of the MI detected with iFC analysis in discriminating between neoplastic tissue and perilesional brain. Note the large AUC, which reflects high diagnostic efficacy.

The MI showed a direct association with the histopathological grade of the tumor. Its corresponding values in WHO Grade II, III, and IV gliomas were 13.3% ± 11.0%, 35.0% ± 21.8%, and 46.6% ± 23.1%. The differences in MI between all investigated groups of neoplasms were statistically significant ($p < 0.01$, ANOVA), but the values overlapped prominently (Fig. 3). The typical DNA histogram pattern also showed an association with the WHO histopathological grade of the tumor (Fig. 4).

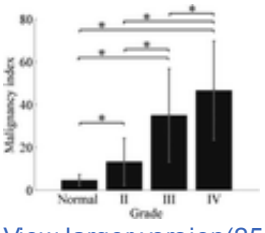

View larger version(25K)

FIG. 3.
Dependence of MI detected with iFC analysis on the presence of glioma and its WHO histopathological grade. Data are presented as the means ± standard deviation. Statistically significant differences between all groups were identified (*$p < 0.01$). Perilesional brain tissue without histopathologically identifiable tumor is defined as “Normal.”

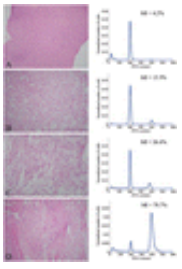

FIG. 4.
Examples of the histopathological characteristics of tissue samples *(left)* evaluated on frozen sections and corresponding DNA histograms obtained with iFC analysis *(right)*: perilesional edematous brain tissue without histopathologically identifiable tumor **(A)**, WHO Grade II oligoastrocytoma **(B)**, WHO Grade III anaplastic astrocytoma **(C)**, and WHO Grade IV glioblastoma**(D)**. H

View larger version(92K) & E, original magnification × 200.

Meanwhile, neither the frequency of DNA aneuploidy nor the DNA index differed significantly between the different groups of tumors. Specifically, DNA aneuploidy was observed in 10 (34.5%) of 29 WHO Grade II tumors, 11 (47.8%) of 23 WHO Grade III tumors, and 17 (58.6%) of 29 WHO Grade IV tumors ($p = 0.70$, chi-square test). The mean DNA index of WHO Grade II, III, and IV gliomas was 1.67 ± 0.21, 1.58 ± 0.33, and 1.60 ± 0.39, respectively ($p = 0.46$, ANOVA).

The duration of iFC analysis varied from 9 to 10 minutes (mean 9.5 minutes). The duration of the intraoperative histopathological examination of frozen sections was approximately 20 minutes.

Illustrative Case

A 32-year-old man presented with mesial temporal lobe epilepsy poorly controlled with medication. There were no other neurological symptoms or signs. His general condition was good and his Karnofsky Performance Scale score was 90. An intraaxial hyperintense lesion was demonstrated in the medial part of the left temporal lobe on T2-weighted MRI. There was neither contrast enhancement on MRI nor methionine uptake on PET scanning (Fig. 5). The differential diagnosis considered either low-grade glioma or cortical dysplasia. During surgery, open biopsy from the center of the lesion was performed under the guidance of updated neuronavigation based on intraoperative MRI. However, histopathological investigation of the frozen sections did not reveal neoplastic pathology. At the same time iFC analysis disclosed an MI of 39.9% with clear detection of aneuploid cells on the DNA histogram. Aggressive resection of the lesion was performed given the strong suspicion of tumor, and the final histopathological diagnosis established on permanent tissue sections revealed diffuse astrocytoma (WHO Grade II).

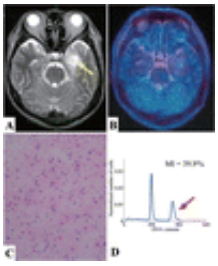

View larger version(115K)

Fig. 5.
Effectiveness of iFC analysis during surgery for intraaxial brain lesion. Preoperative T2-weighted MR image **(A)** showing an area of hyperintense signal *(arrow)* in the medial part of the left temporal lobe, which was not accompanied by radioisotope uptake on methionine PET scan **(B)**. While histopathological investigation of the frozen tissue sections did not reveal neoplastic pathology (**C,** H & E, original magnification × 400), intraoperative DNA histogram **(D)** clearly demonstrated the presence of aneuploid cells *(arrow)* and a high MI, which led to a strong suspicion of tumor presence and resulted in aggressive resection of the lesion. The final histopathological diagnosis was diffuse astrocytoma.

Discussion

Microscopic investigation of pathological material on frozen tissue sections represents the gold standard for intraoperative histopathological diagnosis. However, this technique has several important limitations. First, it is time-consuming, typically requiring around 20–30 minutes for tissue processing and staining, unless the pathology laboratory is located within the operating block itself. Second, interpretation of the microscopic data varies between individual pathologists, and the reliability of the established diagnosis is strongly related to their experience and skill. Third, appropriateness of the technique of tissue preparation is very important.[18,21,24] While in the present series we did not identify any case with a significant discrepancy between histopathological investigation on the frozen versus permanent tissue sections, the reported risk of such discordance varies from 2.7% to 12.4%.[17,19,21,24] To facilitate intraoperative histopathological diagnosis on frozen sections, several specific techniques, such as direct immunofluorescence,[8] ultrarapid immunostaining,[5] and confocal microscopy,[4] have been proposed. It was recently demonstrated that iFC can also be used for such purposes.[14] The method introduced by Mesiwala et al.[14] is based on the use of ultrasound aspiration for the removal and homogenization of pathological tissue with subsequent staining and in situ automatic measurement of DNA content. However, its practical application may lead to erroneous results because of limited precision in tissue sampling and possible mixing of neoplastic and normal brain elements.

To improve the usefulness of iFC in cases of brain tumor resection, our group developed an original analytical method for evaluating DNA content, which is presented herein. It significantly simplifies preprocessing preparation of the tissue sample and tremendously shortens the duration of analysis, which can be completed within 10 minutes. In our experience, it is approximately 2 times faster than intraoperative histopathological examination of the tissue specimen on frozen sections. The shorter period of time required for iFC was attributable to the special setup of the site, which was, in fact, rather simple. The technique is directed on the evaluation of the variety of cells isolated by pipetting under the same conditions. Certainly, it does not permit the separation of neoplastic cells from normal ones, which may result in impaired sensitivity of the analysis. Nevertheless, in the present study the results of iFC correlated well with the histopathological evaluation of permanent formalin-fixed paraffin-embedded tissue sections. The minimal volume of tissue required for iFC is approximately 1–2 mm^3, which allows the surgeon to very precisely determine the biopsy area both within the bulk of the tumor and at its border.

In general, benign intracranial neoplasms have higher diploid cell numbers, whereas aneuploidy is detected in 30%–80% of high-grade gliomas.[3,6,9] Nevertheless, even in glioblastoma various patterns of DNA content can be observed; therefore, it might be inaccurate to determine the histopathological grade of the tumor based only on the presence of aneuploid cells.[6,16] In our analysis the differences in the frequency of aneuploidy and the DNA index in gliomas of various degrees of malignancy did not reach the level of statistical significance. Therefore, these parameters have limited effectiveness for the intraoperative determination of brain tumor grade.

The main parameter investigated on the DNA histogram was designated as the MI, which should not be confused with the well-known mitotic index. The term “malignancy index” was chosen, since it reflects the known correlation of the proportion of cells in the S and G_2/M phases with the degree of brain tumor malignancy.[9] Meanwhile, calculation of the MI considers not only cells in the S and G_2/M phases, but also aneuploid cells with an abnormal number of chromosomes as well as cells containing more DNA than G_2/M phase cells (DNA index > 1.95). While the latter cells could not be unambiguously considered aneuploid, it is rather difficult to make a precise differentiation. Since simplicity and speed were considered to be required parameters for iFC, the proposed method of MI calculation seems sufficiently suitable for clinical needs.

Distinguishing between reactive astrocytosis and low-grade glial neoplasm is considered to be one of the most difficult challenges in surgical neuropathology.[17] Our results demonstrate that the MI, as determined using iFC, may be rather effective for identifying glioma presence in a surgical biopsy sample. We determined the optimal cutoff level of 6.8% to discriminate between neoplasm and perilesional brain, whereas greater cutoff levels would further increase the specificity of the analysis. The usefulness of the technique was clearly shown in the illustrative case. Therefore, it seems that the addition of iFC to routine intraoperative histopathological investigation of frozen sections may significantly facilitate the decision-making process during resection of intracranial glioma and may be helpful for monitoring the completeness of tumor removal. It should be emphasized that the proposed method is based on rather strict criteria and allows one to avoid the “subjectivity” of tissue characterization. At the same time, at least at present, iFC definitely cannot replace standard methods of intraoperative histopathological diagnosis, such as the analysis of frozen tissue sections, and should be used only as an adjunctive tool.

In the present series the MI and DNA histogram pattern showed a statistically significant association with the WHO histopathological grade of glioma. However, the overlap of values between tumors of different degrees of malignancy was too prominent. This may have been caused by several factors. First, some spatial differences, while rather small, had existed between samples taken for histopathological investigation and those taken for iFC analysis. Second, nearly all groups of tumors with the same WHO histopathological grade were rather heterogeneous in their origin (astrocytic, oligodendroglial, oligoastrocytic, or ependymal), whereas tumor type might influence DNA content. Third, the variability of the MI might reflect the different biological behaviors of the lesion and/or its propensity for malignant transformation. In any case, this issue may have significant impact on the effective use of iFC and requires clarification in further studies.

There are several limitations to the present study. First, it was performed at a single institution, and all histopathological investigations were done by only one pathologist. It does not permit evaluation of the interobserver variability of obtained results. Second, a blind comparison between iFC analysis and intraoperative histopathological investigation of frozen

tissue sections was not performed, and, in fact, both methods were used simultaneously. Therefore, the diagnostic advantages of one method over another and the impact of iFC on surgical decision making during resection of glioma remain generally obscured. Third, smear tissue sections and touch preparations are not routinely used in our clinic. Those techniques may be more effective than investigations of frozen sections and, in fact, may be completed within the same period as iFC. Finally, peritumoral brain tissue without identifiable neoplastic elements was used as a “normal” control. It might be more reliable to establish the standard MI values with iFC analysis of the brain tissue samples in the absence of neoplastic pathology (for example, during epilepsy surgery) and this should be done in the future.

Conclusions

Our original method of iFC with the determination of the MI seems technically feasible and reliable for the rapid determination of glioma presence in a surgical biopsy sample. On the other hand, it may be less useful for detailed characterization of the tumor because of prominent overlap of the MI between neoplasms with different histopathological grades. The cell processing algorithm we developed allows one to complete the analysis within approximately 10 minutes and requires a minimal amount of pathological tissue. Further studies are required for comparison of the iFC analysis during resection of intracranial gliomas with standard intraoperative techniques for the histopathological evaluation of tissue samples.

Disclosure

This study was partly supported by the Japan Society for the Promotion of Science through the Funding Program for World-Leading Innovative Research and Development on Science and Technology (FIRST Program), initiated by the Council for Science and Technology Policy and Third Term Comprehensive Control Research for Cancer, Health and Labor Sciences Research Grants funded by the Ministry of Health, Labor and Welfare of Japan.

Author contributions to the study and manuscript preparation include the following. Conception and design: Muragaki, Maruyama. Acquisition of data: Shioyama. Analysis and interpretation of data: Muragaki, Shioyama, Komori. Drafting the article: Shioyama. Critically revising the article: all authors. Reviewed submitted version of manuscript: all authors. Approved the final version of the manuscript on behalf of all authors: Muragaki. Statistical analysis: Shioyama. Administrative/technical/material support: Muragaki, Iseki. Study supervision: Muragaki, Maruyama, Iseki.

Acknowledgements

The authors are grateful to Professor Sunao Takeda and Dr. Nae Hinata (Department of Clinical Engineering, Tokyo University of Technology), Professor Yoshikazu Okada and Drs. Masahiko Tanaka, Taiichi Saito, Mikhail Chernov, Manabu Tamura, Takashi Suzuki, Kitaro Yoshimitsu, and Soko Ikuta and Mr. Takashi Sakayori (Department of Neurosurgery and Faculty of Advanced Techno-Surgery, Tokyo Women's Medical University), and all staff members of the Ogino Memorial Laboratory (Nihon Kohden Corp.) for help provided during this study.

References

1. Akobeng AK: Understanding diagnostic tests 3: Receiver operating characteristic curves. *Acta Paediatr* 96:644–647, 2007 CrossRef, Medline
2. Ando T, Kobayashi E, Liao H, Maruyama T, Muragaki Y, Iseki H, et al.: Precise comparison of protoporphyrin IX fluorescence spectra with pathological results for brain tumor tissue identification. *Brain Tumor Pathol* 28:43–51, 2011 CrossRef, Medline
3. Appley AJ, Fitzgibbons PL, Chandrasoma PT, Hinton DR, Apuzzo ML: Multiparameter flow cytometric analysis of neoplasms of the central nervous system: correlation of nuclear antigen p105 and DNA content with clinical behavior. *Neurosurgery* 27:83–96, 1990 CrossRef, Medline
4. Eschbacher J, Martirosyan NL, Nakaji P, Sanai N, Preul MC, Smith KA, et al.: In vivo intraoperative confocal

microscopy for real-time histopathological imaging of brain tumors. Clinical article. *J Neurosurg* 116:854–860, 2012 Abstract, Medline

5. Haapasalo J, Mennander A, Helen P, Haapasalo H, Isola J: Ultrarapid Ki-67 immunostaining in frozen section interpretation of gliomas. *J Clin Pathol* 58:263–268, 2005 CrossRef, Medline
6. Hoshino T, Nomura K, Wilson CB, Knebel KD, Gray JW: The distribution of nuclear DNA from human brain-tumor cells. *J Neurosurg* 49:13–21, 1978 Abstract, Medline
7. Iseki H, Nakamura R, Muragaki Y, Suzuki T, Chernov M, Hori T, et al.: Advanced computer-aided intraoperative technologies for information-guided surgical management of gliomas: Tokyo Women's Medical University experience. *Minim Invasive Neurosurg* 51:285–291, 2008CrossRef, Medline
8. Iwamoto S, Burrows RC, Born DE, Piepkorn M, Bothwell M: The application of direct immunofluorescence to intraoperative neurosurgical diagnosis. *Biomol Eng* 17:17–22, 2000CrossRef, Medline
9. Kawamoto K, Herz F, Wolley RC, Hirano A, Kajikawa H, Koss LG: Flow cytometric analysis of the DNA distribution in human brain tumors. *Acta Neuropathol* 46:39–44, 1979 CrossRef,Medline
10. Lacroix M, Abi-Said D, Fourney DR, Gokaslan ZL, Shi W, DeMonte F, et al.: A multivariate analysis of 416 patients with glioblastoma multiforme: prognosis, extent of resection, and survival. *J Neurosurg* 95:190–198, 2001 Abstract, Medline
11. Langlotz CP: Fundamental measures of diagnostic examination performance: usefulness for clinical decision making and research. *Radiology* 228:3–9, 2003 CrossRef, Medline
12. Liao H, Noguchi M, Maruyama T, Muragaki Y, Kobayashi E, Iseki H, et al.: An integrated diagnosis and therapeutic system using intra-operative 5-aminolevulinic-acid-induced fluorescence guided robotic laser ablation for precision neurosurgery. *Med Image Anal*16:754–766, 2012 CrossRef, Medline
13. Louis DN, Ohgaki H, Wiestler OD, Cavenee WK: *WHO Classification of Tumours of the Central Nervous System* ed 4Lyon, IARC Press, 2007
14. Mesiwala AH, Scampavia LD, Rabinovitch PS, Ruzicka J, Rostomily RC: On-line flow cytometry for real-time surgical guidance. *Neurosurgery* 55:551–561, 2004 CrossRef, Medline
15. Muragaki Y, Iseki H, Maruyama T, Tanaka M, Shinohara C, Suzuki T, et al.: Information-guided surgical management of gliomas using low-field-strength intraoperative MRI. *Acta Neurochir Suppl* 109:67–72, 2011 CrossRef, Medline
16. Nishizaki T, Ohshita N, Nagatsugu Y, Orita T, Ito H, Sasaki K: Clinical evaluation of DNA index in human brain tumors. *J Neurooncol* 17:9–13, 1993 CrossRef, Medline
17. Plesec TP, Prayson RA: Frozen section discrepancy in the evaluation of central nervous system tumors. *Arch Pathol Lab Med* 131:1532–1540, 2007 Medline
18. Powell SZ: Intraoperative consultation, cytologic preparations, and frozen section in the central nervous system. *Arch Pathol Lab Med* 129:1635–1652, 2005 Medline
19. Regragui A, Amarti Riffi A, Maher M, El Khamlichi A, Saidi A: [Accuracy of intraoperative diagnosis in central nervous system tumors: report of 1315 cases.]. *Neurochirurgie* 49:67–72,2003. (Fr) Medline
20. Salvati M, Pichierri A, Piccirilli M, Floriana Brunetto GM, D'Elia A, Artizzu S, et al.: Extent of tumor removal and molecular markers in cerebral glioblastoma: a combined prognostic factors study in a surgical series of 105 patients. Clinical article. *J Neurosurg* 117:204–211, 2012 Abstract,Medline
21. Savargaonkar P, Farmer PM: Utility of intra-operative consultations for the diagnosis of central nervous system lesions. *Ann Clin Lab Sci* 31:133–139, 2001 Medline
22. Senft C, Forster MT, Bink A, Mittelbronn M, Franz K, Seifert V, et al.: Optimizing the extent of resection in eloquently located gliomas by combining intraoperative MRI guidance with intraoperative neurophysiological monitoring. *J Neurooncol* 109:81–90, 2012 CrossRef, Medline

23. Stummer W, Reulen HJ, Meinel T, Pichlmeier U, Schumacher W, Tonn JC, et al.: Extent of resection and survival in glioblastoma multiforme: identification of and adjustment for bias.*Neurosurgery* 62:564–576, 2008 CrossRef, Medline

24. Uematsu Y, Owai Y, Okita R, Tanaka Y, Itakura T: The usefulness and problem of intraoperative rapid diagnosis in surgical neuropathology. *Brain Tumor Pathol* 24:47–52, 2007 CrossRef,Medline

Cited by

1. George Vartholomatos, Ph.D., George A. Alexiou, M.D., Ph.D., Anna Batistatou, M.D., Ph.D.,Athanassios P. Kyritsis, M.D., Ph.D., and Spyridon Voulgaris, M.D., Ph.D.. (2013) Letters to the Editor: Intraoperative diagnosis. *Journal of Neurosurgery* **119**:2, 528-530. Online publication date: 1-Aug-2013. Citation | Full Text | PDF (1928 KB)