World J Surg (2013) 37:1258–1262
DOI 10.1007/s00268-013-1992-y

World Journal of Surgery

Laparoscopic Treatment for Unsuspected Common Bile Duct Stones by Transcystic Sphincter of Oddi Pneumatic Balloon Dilation and Pressure-Washing Technique

Luigi Masoni · Francesco Saverio Mari · Vincenzo Pietropaolo · Maurizio Onorato · Massimo Meucci · Antonio Brescia

Published online: 9 March 2013
© Société Internationale de Chirurgie 2013

Abstract

Background Unsuspected common bile duct stones (CBDS) are found in 4–5 % of patients with cholelithiasis. The optimal strategy for the treatment of asymptomatic CBDS, diagnosed during laparoscopic cholecystectomy (LC), is not yet well established. A one-stage solution is preferable to solve the CBDS during the LC and to avoid the exposure of patients to the risks of a second procedure, such as complications or failure.

Methods We attempted to remove CBDS by transcystic sphincter of Oddi pneumatic balloon dilation and common bile duct pressure-washing in all cases of intraoperative identification of CBDS since September 2008.

Results In 29 cases, unsuspected CBDS was identified by intraoperative cholangiography; in 28 cases a single stone with a mean diameter of 4.3 mm (range = 3–6) was detected and in one case three 5–8-mm-diameter stones were identified. Clearance of the common bile duct was obtained in 27 cases (96 %), with a mean operative time of 54 min (range = 36–90) and mean length of hospital stay of 2.5 days.

Conclusion Treatment of unsuspected CBDS detected by intraoperative cholangiography during LC with this original technique was safe and effective and a viable alternative of the transcystic endoscopic approach.

L. Masoni · F. S. Mari (✉) · M. Meucci · A. Brescia
Department of Medical and Surgical Sciences and Translational Medicine, School of Medicine and Psychology, University Sapienza of Rome, Rome, Italy
e-mail: frasavmari@yahoo.it

V. Pietropaolo · M. Onorato
Department of Gastroenterology and Endoscopy, School of Medicine and Dentistry, University Sapienza of Rome, Rome, Italy

Introduction

The incidence of unsuspected common bile duct stones (CBDS) in patients with cholelithiasis is 4–5 %, whereas the incidence of CBDS is 5–10 % [1, 2]. Today, the optimal strategy for the treatment of asymptomatic CBDS, diagnosed during laparoscopic cholecystectomy (LC), is not yet well established. In recent years, several methods have been proposed for the treatment of asymptomatic CBDS. The most popular is endoscopic retrograde cholangiopancreatography (ERCP) with endoscopic sphincterotomy or with sphincter of Oddi pneumatic dilation performed during the same procedure (rendezvous) or afterward (two-stage) [3]. It is obvious that a delay in CBDS clearance may expose the patient to the risks of a second procedure (such as complications or failure), and, therefore, a one-stage solution is typically advisable. Another very common technique is laparoscopic common bile duct (CBD) exploration with a choledochoscope inserted via the cystic duct or directly through a choledochotomy. Conversion to open surgery after positive intraoperative cholangiography (IOC) is also possible. Some authors have also proposed clinical observation with or without medical therapy. Obvious difficulties in organizing an unplanned ERCP when CBDS are identified during elective LC led us to develop an original method to obtain clearance of the CBD during the same laparoscopic intervention.

We attempted to remove CBDS by transcystic sphincter of Oddi pneumatic balloon dilation and CBD saline flushing in all cases of intraoperative identification of CBDS since September 2008.

Materials and methods

Between January 2008 and December 2011, we performed 488 LC; IOC was executed in 84 patients who had a clinical history of an increase in cholestatic liver enzymes or previous jaundice episodes and preoperative negative abdominal US or MR cholangiography. All patients were asymptomatic for CBDS at the time of surgery. Patients in whom IOC identified the presence of CBDS were treated by transcystic sphincter of Oddi pneumatic balloon dilation and CBD saline flushing. Written informed consent was obtained from all patients preoperatively.

Surgical technique

We routinely perform LC using three trocars: one 10-mm trocar placed in the umbilicus and 5-mm trocars placed under the xiphoid and in the right flank, respectively. Patients with suspected asymptomatic CBDS were prospectively treated according to the following strategy. When the cystic duct was identified and isolated, a titanium clip was placed under the gallbladder infundibulum. The cholangiography was then performed via the cystic duct using a dedicated kit (Percutaneous Laparoscopic Cholangiography Set with Karlan Balloon Catheter, Arrow International, Reading, PA, USA). An 8-Fr sheath with stylet was used to penetrate the abdomen and to insert, through a small incision, a 6-Fr vinyl catheter in the cystic duct. Then the catheter balloon was inflated and cholangiography was performed using a C-arm fluoroscope with conventional technique (Fig. 1a). If a stone was found in the distal CBD, the cholangiocatheter was removed and a 0.35-in. floppy-tip guide wire was inserted through the sheath and passed through the papilla into the duodenum (Fig. 1b). A 6-Fr 6.0-mm × 40-mm angioplasty balloon (Wanda, SciMed, Boston Scientific, Natick, MA, USA) was advanced over the guide wire into the papilla (Fig. 1c) and was used to dilate the papilla (the balloon was kept inflated at 4 atm for 30–60 s to open the papilla) (Fig. 1d). Then, the balloon was deflated, the catheter was slowly withdrawn so that it did not pull the stone up, and the balloon was reinflated. The stones were then flushed into the duodenum with pressure-washing using saline solution (Fig. 1e). We repeated the whole process two to three times, alternating with contrast infusion, to show that the calculi were cleared (Fig. 1f). The balloon catheter was then removed and the cystic duct was closed with a titanium clip. Failures require an intraoperative ERCP, if possible; otherwise, the guide wire is taken from the cystic duct into the duodenum to facilitate postoperative ERCP. During the procedure, introduction of air into the bile duct was avoided to prevent mimicking of CBDS.

In this study, patients' demographic data (age, sex, BMI, ASA score, and comorbidities), surgical procedure data (intraoperative complications, operating time, conversion, and associated procedure), and outcomes (blood test, including liver and pancreas function, and postoperative complications) were collected.

Results

Unsuspected CBDS were identified by IOC in 29 cases; stone diameter ranged between 3 and 6 mm (mean = 4.3). The study included 15 men and 14 women with a mean age of 55 years (range = 38–72) and mean BMI of 29.3 (range = 25–35). Preoperatively, no patient had any imaging evidence of stones, except a history of an increase in cholestatic liver enzyme levels or subclinical jaundice episodes. The IOC detected the presence of a single stone (mean diameter = 4.3 mm, range = 3–6) in 28 cases (see Table 1), and in the other case, three 5–6-mm stones were identified. A transcystic cannulation was successfully performed in all 29 patients. In 27 cases, it was possible to clean up the CBD, while in one patient we did not find any evidence of stones so the IOC false positivity was likely due to an air bubble. In the remaining case, the presence of more than one stone prevented successful application of this method. In this case, it was possible to perform postoperative ERCP, which showed evidence of three stones 5–8 mm in diameter. All of the procedures were performed by five different surgeons (two senior surgeons with an overall LC experience of more than 500 cases, and three mildly skilled surgeons who had performed fewer than 100 LCs and who conducted the procedure under the supervision of a senior surgeon) with the same results.

The mean operative time of the whole procedure (LC plus CBD clearance) was 54 min (range = 36–90). On the first postoperative day, the blood tests in 10 (37 %) patients showed evidence of an increase in amylase and lipase, which normalized in seven patients during the next 48 h and in the remaining three patients not more than 5 days later. None of these patients showed any clinical signs of pancreatitis as epigastric pain. There were no major postoperative complications; all the patients were successfully discharged by the fifth postoperative day (mean hospital length of stay = 2.5 days). None of the treated patients developed symptomatic choledocholithiasis from retained stones during the follow-up period (mean = 26 months, range = 12–48).

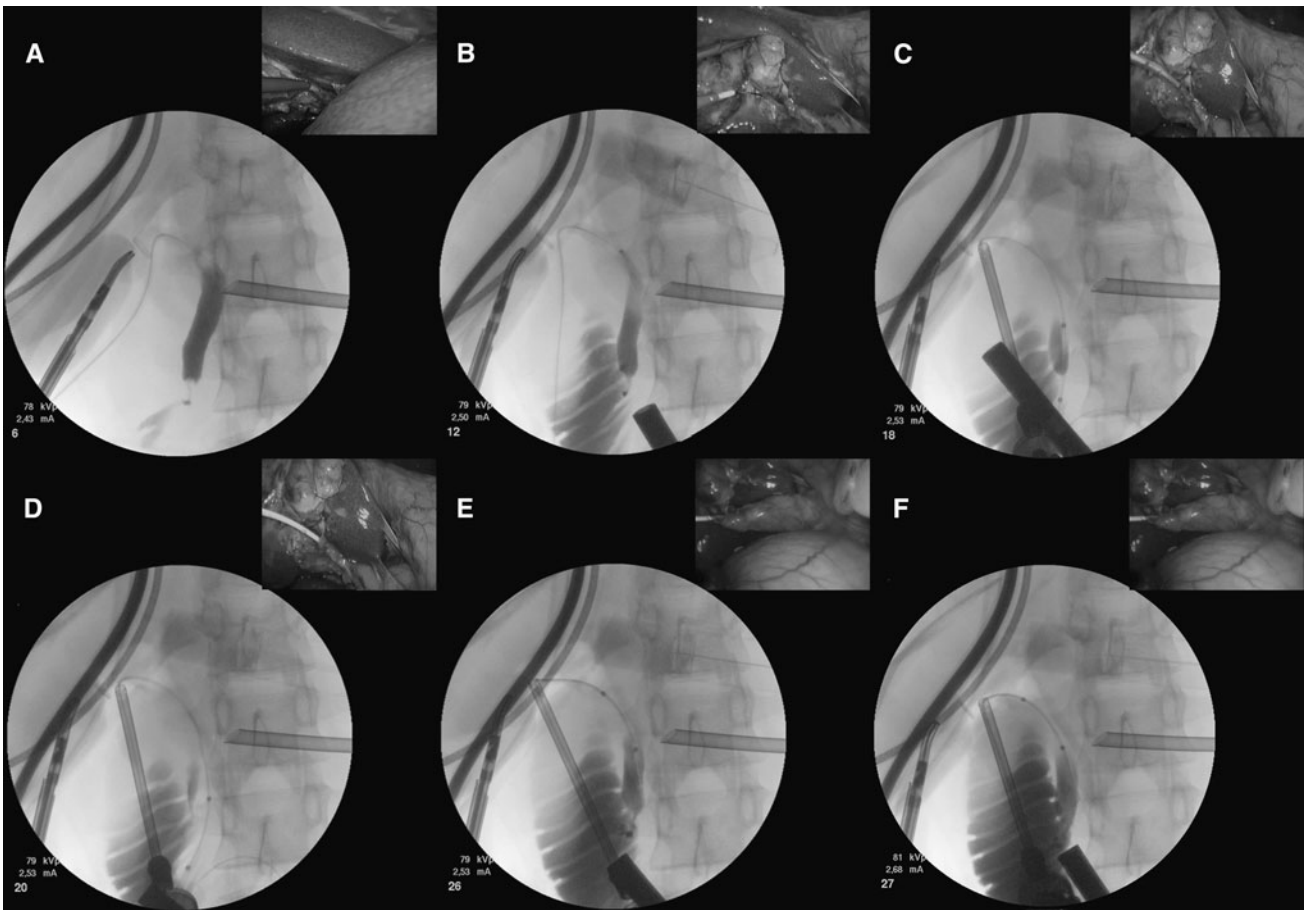

Fig. 1 Papilla pneumatic balloon dilation and pressure-washing of the common bile duct. **a** Cholangiography was performed using a C-arm fluoroscope with percutaneous catheter. **b** A 0.35-in. floppy-tip guide wire was inserted through the sheath and passed through the papilla into the duodenum. **c** A 6-Fr 6.0-mm × 40-mm angioplasty balloon was advanced over the guide wire into the papilla. **d** Balloon was inflated to dilate the papilla. **e** Balloon was deflated and slowly withdrawn and then reinflated and the common bile duct was cleared by saline solution pressure-washing. **f** Contrast was infused to demonstrate clearance of the common bile duct

Table 1 Patients' biographic data and results

N	29
Sex, M/F	15/14
Age [mean (range)]	55 years (38–72)
BMI [mean (range)]	29.3 kg/m^2 (25–35)
Number of stones	
Single	28 cases
Multiple	1 case
Dimension of stones [mean (range)]	4.3 mm (3–8)
Duration of surgery [mean (range)]	54 min (36–90)
Hospitalization [mean (range)]	2.5 days (1–5)

Discussion

More than a third of CBDS cases are unexpected because of the absence or the ambiguity of clinical history, clinical signs, laboratory data, or radiological tests [4, 5]. In our experience, when the calculi are small and do not cause a marked obstruction, the bile duct dimensions are normal or slightly dilated but have scarce symptomatology and radiological images that are not always clear.

In the diagnosis of CBDS, abdominal ultrasound scanning has a sensitivity of 25–63 % and a specificity of about 95 % [6]. The technique is strictly operator-dependent, as the MR cholangiography presents a sensitivity of 95 % and a specificity of approximately 97 % [7]. Despite these excellent results, the technique cannot always be used to identify the single and small calculi that can be identified during an IOC. The IOC has a sensitivity of 75–100 % and a specificity of 76–100 % [8–13].

In our surgical division, we do not routinely perform IOC, reserving it for cases suspected of asymptomatic CBDS. When a CBDS is detected before the interventions, we prefer to subject the patient to preoperative ERCP. In case of intraoperative identification of CBDS, there is no clear consensus on the strategy for clearing the stone(s). Among the several methods proposed, the most commonly

used is the postoperative ERCP, which has a stone clearance rate of about 90 % in expert hands but high morbidity (5–11 %) and mortality rates (0.7–1.2 %) [14–16]. In 3–10 % of patients, it is not possible to execute the procedure [17]. The main complications following ERCP with sphincterotomy are bleeding, duodenal perforation, cholangitis, pancreatitis, bile duct injury, and disruption of sphincter of Oddi function [18]. A reduced number of complications such as bleeding, perforation, and Oddi disruption are reported for the papilla pneumatic dilation technique, in spite of a lower stone clearance rate, especially when there are larger-dimension calculi involved [19–23]. Among the disadvantages of this procedure is the necessity of a second procedure and a possibly third procedure if the ERCP fails.

Another popular method is laparoscopic exploration of the CBD using a transcystic or transductal (via choledochotomy) approach. The excellent results described in the literature (stone clearance rate of 85–95 %, morbidity rate of 4–16 %, and mortality rate of 0–2 %) [24, 25] are related to the use of specific and expensive devices by expert operators and in favorable conditions with respect to the CBD anatomy and the number and size of the calculi [26]. The main complications of this method are CBD laceration and bile leak [27]. This procedure allows the CBDS to be addressed through a single operation, which is converted to open exploration in case of failure. The intraoperative ERCP with rendezvous is less diffuse due to its organizational challenges (stone clearance rate = 90–100 %) [28, 29]. With this approach, the complications related to sphincterotomy and the incidence of postoperative pancreatitis remain unchanged, but the laparoscopic introduction of a guide wire through the cystic duct into the duodenum facilitates papilla cannulation, which decreases the risk of failure. Another advantage of this method compared to postoperative ERCP is the possibility of clearing the CBD in a single operation, eventually converting the procedure to open surgery if the cannulation was impossible.

The open exploration of the CBD, proposed by some authors, seems to be more successful and to have a lower mortality rate than ERCP but at the price of a more invasive intervention and a longer period of hospitalization [30, 31].

Another proposed method includes medical observation of small calculi (<4 mm) because the possibility of their spontaneous transition into the duodenum (even if this is difficult to predict) and the presence of retained calculi can sometimes still cause pancreatitis or papillary stenosis [32, 33].

We had a stone clearance rate of 96 %, with a low risk of complications. The success of our procedure is related to the size of the stone, which must not be greater than the balloon diameter.

The clearing of the CBD using the transcystic approach, as described here, allows us to address CBDS smaller than 6 mm in diameter with a single procedure, that is a simple and safe technique performed by the same surgical team that performed the LC. This procedure also keeps down procedural costs which are burdened only by the cost of the balloon. Furthermore, in the case of failure of the transcystic approach, it is possible to plan a postoperative ERCP involving the use of a transcystic guide wire to facilitate papilla cannulation. This technique also reduces the risk of bleeding and sphincter injuries by employing pneumatic dilation, and it involves a reduced incidence of postoperative pancreatitis. Moreover, the hospital length of stay in these cases is not significantly longer than with LC alone.

Moreover, as demonstrated by our study, this is a relatively simple technique that can be performed by all laparoscopic surgeons experienced in IOC. The surgeon who will perform the transcystic sphincter of Oddi pneumatic balloon dilation and CBD saline flushing only needs to become familiar with the balloon catheter and with the introduction of the guide wire through the papilla of Vater under fluoroscopy.

The excellent results of this technique in terms of CBD clearance must be carefully evaluated considering our relatively short follow-up (mean = 26 months), which may have led to the loss of patients who later developed symptomatic choledocholithiasis from retained stones. In fact, the assessment of the effective cleaning of CBD at the end of the procedure by an IOC and not by a cholangioscopy does not ensure that the stones were really removed; this represents a weakness of this study.

The absence in our series of clinically evident postoperative pancreatitis, as opposed to what happens after ERCP, should be attributed to the small number of cases rather than to a real advantage of the technique. In fact, this technique is not much different than ERCP in terms of the risk of pancreatic duct contrast injections or Vater's papilla trauma. Also, as for ERCP, the risk of postoperative pancreatitis seems to depend more on patient-related risk factors than on technique-related ones [20, 21, 29].

In our hospital, the absence of a choledochoscope and the organizational challenges that must be surmounted to have an endoscopist in the operating room led us to develop this method, which a simple, safe, and effective procedure for treating asymptomatic CBDS detected intraoperatively with a lower complications rate than postoperative ERCP. This method should not be used when the diagnosis of CBDS is determined preoperatively, especially in the presence of evident symptomatology and/or laboratory and radiological findings. In these cases, the presence of relatively larger calculi is very common and preoperative ERCP is recommended.

Conclusion

This study shows that laparoscopic transcystic papilla pneumatic balloon dilation with the pressure-washing technique is a safe and effective procedure with which to treat the unsuspected CBDS if it is detected during LC and there is only one stone that is smaller than 6 mm. A larger number of cases are needed to definitively validate this technique but the preliminary results are very promising.

Conflict of interest The authors have no conflicts of interest or financial ties to disclose.

References

1. Metcalfe MS, Ong T, Bruening MH et al (2004) Is laparoscopic intraoperative cholangiogram a matter of routine? Am J Surg 187(4):475–481
2. Snow LL, Weinstein LS, Hannon JK et al (2001) Evaluation of operative cholangiography in 2043 patients undergoing laparoscopic cholecystectomy: a case for the selective operative cholangiogram. Surg Endosc 15:14–20
3. Memon MA, Hassaballa H, Memon MI (2000) Laparoscopic common bile duct exploration: the past, the present, and the future. Am J Surg 179(4):309–315
4. Roush TS, Trasverso LW (1995) Management and long-term follow-up of patients with positive cholangiograms during laparoscopic cholecystectomy. Am J Surg 169:484–487
5. Lezoche E, Paganini AM (1995) Single stage laparoscopic treatment of gallstones and common bile duct stones in 120 unselected, consecutive patients. Surg Endosc 9(10):1070–1075
6. Caddy GR, Tham TC (2006) Symptoms, diagnosis and endoscopic management of common bile duct stones. Best Pract Res Clin Gastroenterol 20(6):1085–1101
7. Romagnuolo J, Bardou M, Rahme E et al (2003) Magnetic resonance cholangiopancreatography: a meta-analysis of test performance in suspected biliary disease. Ann Intern Med 139(7):547–557
8. Perry KA, Myers JA, Deziel DJ (2008) Laparoscopic ultrasound as the primary method for bile duct imaging during cholecystectomy. Surg Endosc 22(1):208–213
9. Catheline JM, Turner R, Paries J (2002) Laparoscopic ultrasonography is a complement to cholangiography for the detection of choledocholithiasis at laparoscopic cholecystectomy. Br J Surg 89(10):1235–1239
10. Barteau JA, Castro D, Arregui ME et al (1995) A comparison of intraoperative ultrasound versus cholangiography in the evaluation of the common bile duct during laparoscopic cholecystectomy. Surg Endosc 9(5):490–496
11. Birth M, Ehlers KU, Delinikolas K et al (1998) Prospective randomized comparison of laparoscopic ultrasonography using a flexible-tip ultrasound probe and intraoperative dynamic cholangiography during laparoscopic cholecystectomy. Surg Endosc 12(1):30–36
12. Siperstein A, Pearl J, Macho J et al (1999) Comparison of laparoscopic ultrasonography and fluorocholangiography in 300 patients undergoing laparoscopic cholecystectomy. Surg Endosc 13(2):113–117
13. Hublet A, Dili A, Lemaire J et al (2009) Laparoscopic ultrasonography as a good alternative to intraoperative cholangiography (IOC) during laparoscopic cholecystectomy: results of prospective study. Acta Chir Belg 109(3):312–316
14. Cotton PB, Lehman G, Vennes J (1991) Endoscopic sphincterotomy complications and their management: an attempt at consensus. Gastrointest Endosc 37(3):383–393
15. Freeman LM, Nelson DB, Sherman S (1996) Complications of endoscopic biliary sphincterotomy. N Engl J Med 335(13): 909–918
16. Loperfido S, Angelini G, Benedetti G (1998) Major early complications from diagnostic and therapeutic ERCP: a prospective multicenter study. Gastrointest Endosc 48(1):1–10
17. Martin IJ, Bailey S, Rhodes M et al (1998) Towards T-tube free laparoscopic bile duct exploration: a methodologic evolution during 300 consecutive procedures. Ann Surg 228(1):29–34
18. Tai CK, Tang CN, Ha JPY et al (2004) Laparoscopic exploration of common bile duct in difficult choledocholithiasis. Surg Endosc 18(6):910–914
19. Bergman JJ, van Berkel AM, Bruno MJ (2001) A randomized trial of endoscopic balloon dilatation and endoscopic sphincterotomy for removal of bile duct stones in patients with a prior Billroth II gastrectomy. Gastrointest Endosc 53(1):19–26
20. Baron TH, Harewood GC (2004) Endoscopic balloon dilatation of the biliary sphincter compared to endoscopic biliary sphincterotomy for removal of common bile duct stones during ERCP: a meta-analysis of randomized, controlled trials. Am J Gastroenterol 99(8):1455–1460
21. Park DH, Kim MH, Lee SK (2004) Endoscopic sphincterotomy vs. endoscopic papillary balloon dilatation for choledocholithiasis in patients with liver cirrhosis and coagulopathy. Gastrointest Endosc 60(2):80–85
22. Yasuda I, Tomita E, Enya M et al (2001) Can endoscopic papillary balloon dilatation for choledocholithiasis really preserve sphincter of Oddi function? Gut 49(5):686–691
23. Weinberg BM, Shindy W, Lo S (2006) Endoscopic balloon sphincter dilatation (sphincteroplasty) versus sphincterotomy for common bile duct stones. Cochrane Database Syst Rev 18(4):CD004890
24. Rojas-Ortega S, Arizpe-Bravo D, Martin Lopez ER et al (2003) Transcystic common bile duct exploration in the management of patients with choledocholithiasis. J Gastrointest Surg 7(4):492–496
25. Thompson MH, Tranter SE (2002) All-comers policy for laparoscopic exploration of the common bile duct. Br J Surg 89(12):1608–1612
26. Topal E, Aerts R, Pennickx F (2007) Laparoscopic common bile duct clearance with flexible choledochoscopy. Surg Endosc 21(12):2317–2321
27. Dion YM, Ratelle R, Morin J et al (1994) Common bile duct exploration: the place of laparoscopic choledochotomy. Surg Laparosc Endosc 4(6):419–424
28. Christoforidis E, Konstantinos V, Konstantinos B et al (2008) Feasibility of therapeutic endoscopic retrograde cholangiopancreatography for bile duct stones in nonagenarians: a single unit audit. J Gastrointest Liver Dis 17(4):427–432
29. Cavina E, Franceschi M, Sidoti F et al (1998) Laparo-endoscopic "rendezvous": a new technique in the choledocholithiasis treatment. Hepatogastroenterology 45(23):1430–1435
30. Aroori S, Bell JC (2002) Laparoscopic management of common bile duct stones: our initial experience. Ulster Med J 71(1):22–25
31. Shuchleib S, Chousleb A, Mondragon A et al (1999) Laparoscopic common bile duct exploration. World J Surg 23(7):698–701. doi: 10.1007/PL00012371
32. Kondylis PD, Simmons DR, Agarwal SK et al (1997) Abnormal intraoperative cholangiography. Treatment options and long term follow-up. Arch Surg 132:347–350
33. Chung RS, Klabbatz L, Chari V et al (1998) Unsuspected choledocholithiasis first diagnosed at laparoscopic cholecystectomy: treatment by trans-cystic duct stenting and elective stent-guided sphincterotomy. Gastrointest Endosc 48:71–74