World J Surg (2015) 39:1373–1380
DOI 10.1007/s00268-014-2793-7

SURGICAL SYMPOSIUM CONTRIBUTION

Management Guidelines for Penetrating Abdominal Trauma

Walter L. Biffl · Ari Leppaniemi

Published online: 15 October 2014
© Société Internationale de Chirurgie 2014

Abstract
Introduction The optimal management of patients with penetrating abdominal injuries has been debated for decades, since mandatory laparotomy (LAP) gave way to the concept of "selective conservatism."
Materials and Methods A comprehensive literature review was performed and summarized.
Results A proposed management guideline for patients with penetrating abdominal trauma was created.
Conclusion Indications for immediate laparotomy (LAP) include hemodynamic instability, evisceration, peritonitis, or impalement. Selective nonoperative management of stable, asymptomatic patients has been demonstrated to be safe. Adjunctive diagnostic testing—ultrasonography, computed tomography, local wound exploration, diagnostic peritoneal lavage, laparoscopy—is often used in an attempt to identify significant injuries requiring operative management. However, prospective studies indicate that these tests frequently lead to nontherapeutic LAP, and are not cost-effective.

Introduction

The optimal management of patients with penetrating abdominal injuries has been debated for decades, since mandatory laparotomy (LAP) gave way to the concept of "selective conservatism." [1] There is little disagreement that hemodynamic compromise, peritonitis, evisceration, or impalement mandate prompt LAP. But there is considerable divergence of opinion and variation in practice with regard to the approach to a hemodynamically stable, asymptomatic patient. The current review will focus on decision-making related to the selective nonoperative management (SNOM) of penetrating abdominal trauma. Most of the literature and therefore most of the discussion will pertain to stab wounds (SWs), but the concept has recently been applied to gunshot wounds (GSWs). Our goal is to create a safe, cost-effective, evidence-based algorithmic approach to stable patients.

W. L. Biffl (✉)
Department of Surgery, Denver Health Medical Center/University of Colorado, 777 Bannock Street, MC 0206, Denver 80204-4507, CO, USA
e-mail: walt@biffl.com

A. Leppaniemi
Department of Abdominal Surgery, Helsinki University Hospital, Helsinki, Finland

Mandatory LAP and its consequences

Mandatory LAP was considered the standard of care for abdominal SWs until the 1960s, and for GSWs until much more recently. While LAP may be considered the most conservative, safest approach to identify and treat all injuries in a timely manner, it is unnecessary in as many as 70 % of abdominal SW patients [1]. Moreover, there are significant consequences of unnecessary LAP in terms of complication rates, length of stay (LOS), and costs. Leppaniemi et al. [2] analyzed the records of 459 patients managed under a mandatory LAP protocol, of whom 147 had no associated extra-abdominal injuries or procedures.

Among these patients, 17 % had complications and the mean LOS was 7.6 days. Renz and Feliciano [3] performed the first prospective study of patients undergoing unnecessary LAP after trauma. They found that (1) complications occurred in 26 % of patients who had a nontherapeutic (NONTHER) LAP, even in the absence of associated injuries; (2) complications significantly increased LOS; and (3) the mean and median LOS following an unnecessary LAP for trauma was 5 days, even in the absence of complications or associated injuries. In two recent Western Trauma Association (WTA) prospective multicenter trials, although there were very few LAP-related complications, the mean LOS of patients undergoing NONTHER LAP was 3.6 days [4, 5].

Selective nonoperative management

In developing management strategies for penetrating abdominal trauma, it is helpful to divide the abdomen into regions: the anterior abdomen (from xiphoid to pubis, between the anterior axillary lines); the flank and back (posterior to the anterior axillary lines); and the thoracoabdomen (from the nipple line to the costal margin). Hemodynamic compromise, peritonitis, evisceration, and impalement remain indications for LAP, regardless of region. However, the SNOM approach varies in each of these regions.

Thoracoabdomen

Penetrating trauma in the thoracoabdominal region may create injuries in both the chest and the abdomen, including the diaphragm. Unstable patients present a challenging management dilemma, regarding which body to cavity to enter first [6]. Patients in extremis should undergo resuscitative thoracotomy [7]. In the more stable GSW victim, chest and abdominal X-rays with a skin marker on entry wound(s) will help to ascertain the trajectory (e.g., transmediastinal or transdiaphragmatic). The chest X-ray and focused abdominal sonographic examination for trauma (FAST) will elucidate the presence of blood in the thoracic cavity, pericardial sac, or abdominal cavity. Tube thoracostomy may provide definitive treatment for hemothorax; however, large initial volume (>1,500 mL) or continued hemorrhage (>200 mL/hr) is indications for thoracotomy, and inability to evacuate blood (i.e., "caked hemothorax") is an indication for thoracoscopic evacuation and hemorrhage control as necessary. Significant hemopericardium generally mandates sternotomy or thoracotomy for cardiac repair, although if FAST is equivocal or demonstrates very small henopericardium it is reasonable to perform subxiphoid pericardial window and irrigate the pericardium. If there is no evidence of active hemorrhage, it appears to be safe to simply leave a drain and monitor for bleeding or pericardial tamponade [8]. Obviously, major bleeding in any area or a change in the patient's condition may alter the order of interventions and the decision to use damage control techniques.

Stable, asymptomatic patients with potential thoracoabdominal penetrating trauma may still harbor occult injuries. While blunt diaphragmatic injuries may be relatively easy to diagnose, penetrating injuries are far more difficult. The presence of a small knife wound in the diaphragm can elude detection by the most sensitive imaging modalities. A prospective series from the University of Maryland Shock-Trauma Center included 50 patients with CT findings suggesting a potential diaphragm injury [9]. The authors noted "specific" CT findings of diaphragmatic injury (defined as contiguous organ injury on either side of the diaphragm or herniation of abdominal fat through a defect in the diaphragm) in 20 (40 %) of patients. "Nonspecific" findings included a wound tract extending up to the diaphragm; thickening of the diaphragm from blood or edema; or an apparent defect in the diaphragm without herniation or adjacent hematoma. Seventeen (34 %) of the 50 patients had surgical evaluation of the diaphragm—LAP in 12 and thoracoscopy in 5—and diaphragmatic injury was confirmed in only 12 (71 %) of that subgroup. Of note, two patients with "specific" findings had no diaphragmatic injury. The authors provided no data on the number of patients who subsequently presented with diaphragmatic hernia, so the number of false (−) CT scans is unknown.

Diagnostic peritoneal lavage (DPL) has been employed to help detect bleeding from diaphragmatic lacerations. Moore and Marx [10] proposed a red blood cell (RBC) threshold of 5,000/mm^3, as this level was not likely to be attributed to the DPL procedure. More recently, direct assessment of the diaphragm with thoracoscopy or laparoscopy has been suggested. Uribe et al. [11] performed routine thoracoscopy and found diaphragmatic injuries in 32 % of patients with penetrating thoracoabdominal injuries. On subsequent LAP, the authors found that 89 % of the patients with diaphragmatic injuries had intra-abdominal injuries that required surgical repair. In the 1990s, a number of investigators attempted to clarify the role of laparoscopy. Murray et al. [12] prospectively studied 110 patients with penetrating injuries to the left lower chest, and found occult diaphragmatic injuries in 26 (24 %) of them. Friese et al. [13] confirmed these results, also finding diaphragmatic injuries in 24 % (8 of 34) of patients with penetrating thoracoabdominal injuries. They further evaluated the accuracy of laparoscopy by following it with LAP, and found 1 (11 %) missed injury. Thoracoscopy and laparoscopy are clearly accurate, but require the resources of a major operation—including the surgical team. On the other hand, experience with DPL is marginal in this era, so its success and accuracy may not be optimal.

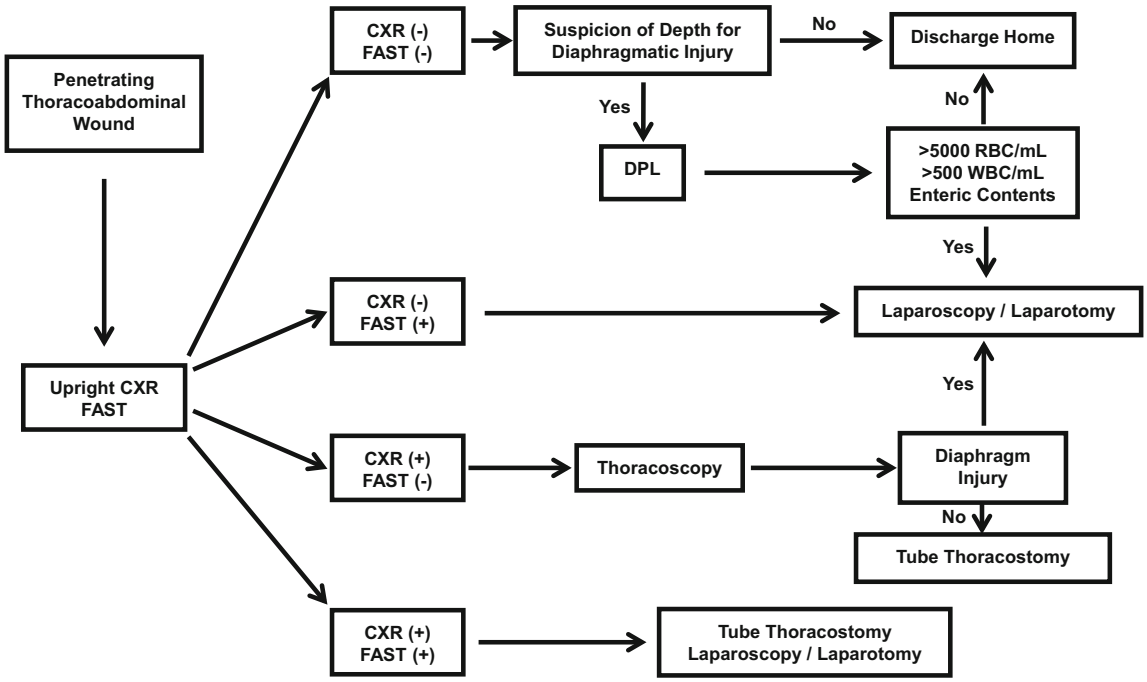

Fig. 1 Algorithmic approach to thoracoabdominal stab wounds. *CXR* chest X-ray, *FAST* focused abdominal sonographic examination for trauma, *DPL* diagnostic peritoneal lavage, *WBC* white blood cell count

In the interest of allocating resources to the highest risk patients, a reasonable management strategy for stable patients with penetrating thoracoabdominal trauma is outlined in Fig. 1. An upright chest X-ray and FAST are performed. If both are normal but there is clinical suspicion of deep enough penetration to cause diaphragmatic injury, DPL is performed with a RBC threshold of 5,000/mm^3. This will avoid laparoscopy in the large majority of patients, as only a (+) DPL mandates LAP or laparoscopy. If there is a hemo- or pneumothorax with (−) FAST, thoracoscopy is performed first. Since the patient already requires tube thoracostomy, this adds little additional morbidity, and the pericardium can be evaluated. If there is a diaphragm injury—as expected in 24 % of patients—[12, 13] LAP or laparoscopy is performed to exclude injury below the diaphragm [11]. If there is a (+) FAST, LAP or laparoscopy is mandatory. The accuracy and therapeutic value of laparoscopy for abdominal hollow viscus injuries are discussed below.

Table 1 Classification and management recommendations for CT scan findings following penetrating flank/back injuries

Risk	CT findings	Intervention
Low	No penetration	Discharge from ED
	Penetration into subcutaneous tissue	
Moderate	Penetration into Muscle	Serial clinical assessments
	Retroperitoneal hematoma, not near critical structure	
High	Contrast extravasation from colon	Laparotomy
	Major extravasation from kidney	
	Hematoma adjacent to major retroperitoneal vessel	
	Free air in retroperitoneum, not attributed to wounding object	
	Evidence of injury above and below diaphragm	
	Free fluid in peritoneal cavity	

Adapted from Himmelman et al. [28]

Back/flank

Penetrating trauma to the back or flank is associated with a lower likelihood of significant injury compared with anterior abdominal or thoracoabdominal wounds. However, these injuries can pose a special problem because of the difficulty in clinically evaluating the retroperitoneal organs with physical exam and FAST. In a stable asymptomatic patient, CT scanning is reliable for excluding significant injury [14, 15]. Findings may be classified as low, moderate, or high risk, and patients are managed accordingly (Table 1). More recently, the necessity of rectal contrast has been questioned, as the image quality of current-generation CT scanners appears to allow adequate evaluation of the colon and rectum to determine the need for surgical exploration, without instillation of intraluminal contrast [16].

Anterior abdomen

It is recognized that of all anterior abdominal SWs (AASWs), only 50–75 % enter the peritoneal cavity—and of those, only 50–75 % cause an injury requiring operative repair. The large majority of patients requiring operative repair of injuries will present with hemodynamic compromise, peritonitis, evisceration, or impalement. Consequently, only a minority of initially stable, asymptomatic patients would be expected to require operative intervention [17]. In 1960, Shaftan [1] first challenged the dictum of mandatory LAP for AASWs, introducing a policy of "selective conservatism"—i.e., management based primarily on clinical evaluation. This approach was promulgated by the groups at Kings County Medical Center [1] and Charity Hospital [18]. Then as now, however, the desire to avoid NONTHER LAP has been tempered by the fear of morbidity related to a delay in intervention, and a number of adjuncts have been employed in an attempt to identify significant injuries prior to clinical deterioration. Initially there were tests aimed at determining whether the peritoneum had been entered, including sinography [19] and local wound exploration (LWE) [17, 20]. Although sinography proved less useful [21], LWE allowed many patients to be safely discharged (D/C'ed) from the emergency department (ED) if the peritoneal cavity was not violated [17]. As it was realized that the decision for LAP should be based not just on peritoneal penetration, but on the presence of a significant intraperitoneal injury, DPL was adopted to look for evidence of significant intra-abdominal injury in the setting of a "positive" (+) LWE (i.e., penetration into the peritoneal cavity) [17, 20, 22]. Subsequently, technology-based approaches were introduced, including laparosocopy [23, 24], CT scanning [25], and ultrasonography (US) [26]. The debate has continued to focus on the balance between invasiveness, resource utilization, and timely repair of significant injuries [27–29].

Although the recent literature on AASWs has been predominated by reports of adjunctive measures, the safety of serial clinical assessments (SCAs) has continued to be demonstrated [30]. The WTA conducted a prospective observational multicenter trial, to evaluate the outcomes of various management strategies [4]. In that study, there were three notable findings: (1) If a stable asymptomatic patient was taken to the OR primarily on the basis of a test result (i.e., FAST, LWE, DPL, or CT), the NONTHER LAP rate was high, ranging from 24 to 57 %; (2) Performing LWE in stable patients would allow the D/C of over 40 % of the stable patients from the ED; and (3) Nonoperative observation with SCAs was safe—i.e., there was no apparent morbidity related to a potential delay to operative treatment of injuries. Based on all of these findings, a unifying algorithm for the management of patients with AASWs was proposed (Fig. 2) [4]. A subsequent WTA multicenter study was designed to evaluate the algorithm [5]. Between the two WTA trials [4, 5], a total of 581 patients were prospectively followed through their hospital course and afterward, allowing an analysis of the various management strategies.

Immediate LAP

There is uniform agreement that immediate LAP is warranted for hemodynamic compromise, peritonitis, evisceration, or impalement. Between the two WTA trials, a total of 143 (25 %) of the 581 patients were taken for immediate LAP; 122 (85 %) were therapeutic (THER). Of 41 patients taken for immediate LAP who had signs of hemodynamic compromise, 37 (90 %) were THER. "Peritonitis" is a relatively subjective finding. In the combined WTA trials, if a patient had "diffuse peritonitis" without either shock or evisceration, the NONTHER LAP rate was 20 %—but if it isolated "local peritonitis," 50 % of LAPs were NONTHER. The authors still contend that it is difficult to justify delaying intervention in a patient with peritonitis, but an experienced clinician should attempt to differentiate true peritoneal signs from tenderness related to the wound. Of 76 patients taken to the OR with evisceration, the overall THER LAP rate was 89 %. If there was intestinal evisceration, 100 % had THER LAP; on the other hand, of 40 patients with omental evisceration who did not have shock or peritonitis, 33 (83 %) had THER LAP. Although the significance of omental evisceration has been debated, the fact is that the patient has a symptomatic hernia, and greater than 65 % chance of requiring a THER LAP [17, 31, 32], so evisceration should remain an indication for immediate LAP.

Management of stable, asymptomatic patients

A number of adjuncts have been employed in order to identify significant abdominal injuries in the absence of shock, evisceration, or peritonitis. The WTA management algorithm (Fig. 2) [4] was designed to streamline care to be cost-effective and minimize the number of NONTHER LAPs. According to the algorithm, if a patient does not have an indication for immediate LAP, LWE is performed. It is important to recognize that LWE must be technically adequate; a simple probing of the stab wound is not reliable to rule out peritoneal violation [33]. The procedure requires adequate exposure of the wound to follow the tract of the stabbing object [17]. Further, some surgeons consider violation of anterior fascia to constitute a (+) LWE. This definition ignores the muscle and/or posterior fascia, and does not correlate with violation of the peritoneal cavity. A stricter definition of (+) LWE—that is, violation of the

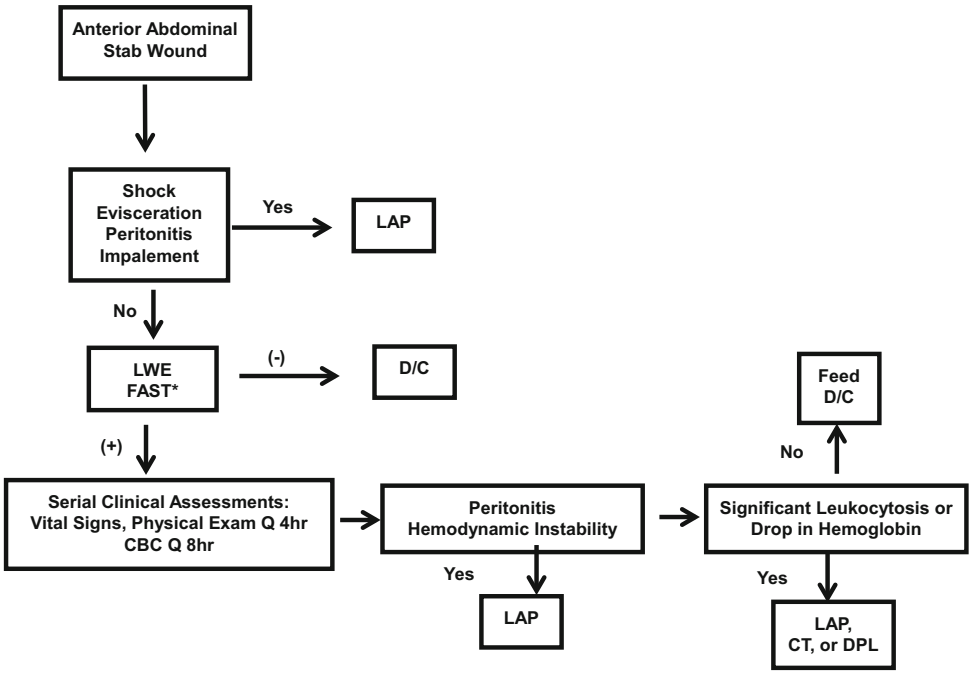

Fig. 2 Algorithmic approach to anterior abdominal stab wounds. A (+) focused abdominal sonographic examination for trauma (FAST) can obviate the need for local wound exploration (LWE), but is not in and of itself an indication for laparotomy (LAP). *D/C* discharge home, *CBC* complete blood count, *CT* computed tomography

posterior fascia and peritoneum—increases the number of patients eligible for ED D/C. The surgeon must keep in mind that LWE may be compromised in very obese patients or those with a tangential wound tracking through muscle layers. If the peritoneal cavity is not violated, the patient may be D/C'ed from the ED. In the WTA trials [4, 5], 31 % of patients had a (−) LWE and could have been D/C'ed from the ED; this is consistent with historical data on the incidence of peritoneal violation in penetrating abdominal trauma [1, 18]. If the peritoneal cavity is violated, the patient should be admitted for SCAs. Peritoneal violation is not an indication for LAP; if stable asymptomatic patients were taken to the OR for (+) LWE in the WTA trials, 22 (55 %) of 40 had a NONTHER LAP [4, 5].

If the peritoneum is breached, the patient should be admitted for SCAs. SCAs require serial physical exam, ideally by the same examiner. If there is to be a patient handoff it should take place at the bedside to ensure clear understanding of physical exam findings. Laboratory evaluation need not be extensive—a complete blood count will allow the detection of hemorrhage and demonstrate the trend in the white blood cell (WBC) count. Absolute WBC count is less helpful than the trend; however, a value $<12.5 \times 10^3$/mL is reassuring, whereas a value $>20 \times 10^3$/mL is associated with a significant risk of hollow viscus injury [34].

Many have advocated for CT scanning in the evaluation of patients with AASWs. There is no question that CT scanning is invaluable in the management of blunt trauma patients. However, in the setting of AASW, published data do not prove the value of CT, and in fact suggest it is cost-ineffective [4, 5, 35]. Whereas LWE will determine peritoneal breach, the accuracy of CT scanning for this purpose has not been strictly determined. The major benefit of CT is in demonstrating a tangential wound tract and allowing ED D/C, but LWE should serve this purpose except in the morbidly obese patient. If stable asymptomatic patients are taken to the OR based on CT scan findings, the WTA trials indicate that 15 (25 %) of 59 will have NONTHER LAP [4, 5]. Indeed, Inaba and colleagues [35] recently reaffirmed that management of patients without CT scanning is safe and avoids the additional insult of radiation dosing.

Ultrasonography (FAST) is ubiquitous in trauma care, but its role in AASW management is dubious. Once the patients with indications for immediate LAP are determined, FAST is not helpful and can be quite misleading. Detectable hemoperitoneum does not necessarily correlate with a significant injury requiring operative intervention, particularly in stable, asymptomatic patients. In the WTA trials, 10 (50 %) of 20 such patients had a NONTHER LAP or did not require LAP [4, 5]. The major value of the test is probably in identifying patients who have hemoperitoneum, as it can obviate the need for LWE. On the other hand, the absence of hemoperitoneum does not equate with the absence of injury. In the WTA trials, 30 (17 %) of 175 patients with a "normal" FAST ultimately had a THER LAP [4, 5]. Thus, we agree with Udobi and colleagues—[36] who reported 18 % sensitivity of FAST in penetrating trauma—that patients should not be D/C'ed from the ED based solely on a (−) FAST. And although US has been advocated for identifying fascial defects after penetrating

trauma [37], it is probably not reliable enough to determine a patient's suitability for ED D/C.

While the authors believe there may still be a role for DPL in the setting of potential diaphragmatic laceration, it is less helpful in the setting of AASW. Because significant injuries are commonly manifest by shock, evisceration, or peritonitis, a small amount of bleeding may have come from the abdominal wall, omentum, or a solid organ. Thus, RBC counts are not helpful. The detection of hollow viscus injuries is also unreliable with DPL. Difficulties in interpreting the DPL WBC count have also been widely discussed and to date there is no threshold that offers 100 % accuracy [38–40]. In the first WTA series [4], a high lavage WBC count (>500 WBCs/mm^3) led to two NONTHER LAPs, and two patients with hollow viscus injuries had a subthreshold lavage WBC count. Recognizing the problem of equivocal DPL results, measurement of amylase and alkaline phosphatase have been suggested to improve the sensitivity of DPL [41, 42]. These results, like the WBC count, are somewhat dependent on the timing of DPL; furthermore, the enzymes may not reliably diagnose colon injury [39–42]. Based on the reports out of Dallas [22] and Denver [28], false (−) results (i.e., WBC <500/mm3) are found in 3–10 % of patients with hollow viscus injuries when DPL is performed relatively soon after injury. On the other hand, waiting 6–7 h may result in a 35 % incidence of false (+) studies based on high WBC counts [38]. Standard threshold values for WBCs and enzymes are not reliable enough to overcome physical exam findings. In the experience of the WTA trials, 8 (40 %) of 20 patients had NONTHER LAP based on DPL results [4, 5].

Many authors have advocated for laparoscopy in the setting of penetrating abdominal trauma. As discussed above, laparoscopy is an excellent test for evaluating the diaphragm for laceration, and allows minimally invasive repair. However, the surgeon must beware the missed hollow viscus injury. A small wound can be difficult to detect, particularly on the posterior wall of the stomach or on the colon underneath pericolonic fat or on the mesenteric border. Leppaniemi and Haapiainen [43] performed a prospective randomized study of diagnostic laparoscopy in AASWs. In stable patients with (+) LWE, 60 % had NONTHER operation, which was the same as the rate with mandatory LAP. Among patients with equivocal peritoneal violation, laparoscopy offered no advantage over SCAs—but increased LOS, costs, and time off of work. A recent systematic review of the literature identified selection and publication bias in the existing literature. Still, the NONTHER LAP rate overall was 16 %, and 12 % negative LAP; further, there were 83 (7 %) missed injuries among 1,129 patients with injuries [44]. In the setting of AASWs, the authors feel it is an inappropriate use of resources. Although the group from Memphis [45] recently suggested it was a safe and efficient use of resources, 86 % of their patients underwent formal operative intervention (either LAP or laparoscopy); 62 % had LAP, and 24 % of LAPs were NONTHER. If the goal is cost-effective care, LWE can rule out peritoneal penetration, and observation with SCAs is much less costly than a surgical procedure.

In the WTA trials, most patients (77 %) who did not have LAP and were admitted for observation stayed one day or less [4, 5]. Prolonged stays were generally attributed to psychiatric or social issues, or to the need for chest tube management. The mean LOS of patients undergoing LAP was 4.7 days; the LOS following a THER LAP was 5.1 days, and 3.6 days following NONTHER LAP. There was a morbidity rate of 20 % following THER LAP, and 4 % following NONTHER LAP. The LOS associated with complications after LAP was 7.8 days, compared with 4.1 days without complications.

Regarding the safety issue, as noted in previous studies, admission for SCAs appears to be a safe strategy [27, 29, 30]. In the most recent WTA multicenter study [5], there were 11 patients managed with this strategy who went to the OR in a delayed fashion. Although delayed intervention is potentially deadly in the setting of blunt small bowel injury [46], this does not seem to translate to penetrating trauma victims [47, 48]. Indeed, with vigilant observation, clinical change is generally evident early: in the WTA study [5], 10 (91 %) of the 11 delayed LAPs occurred within 4 h of presentation. Moreover, the mean LOS was two days shorter for patients having THER LAP after a period of SCAs, compared with those undergoing THER LAP immediately, or after CT or DPL. We harken back to Nance and Cohn [49], who wrote (emphasis theirs):

> …the incidence of complications was the *same* in the patients operated on immediately and in those whose surgery was delayed. Further, the incidence of complications reflected more the *nature* of the injury (i.e., whether or not a hollow viscus was entered) than it did a delay in surgery. This observation is confirmed in the data of Wilson and Sherman and in the report of McNabney and McCanse. The oft-expressed fear that a delay in exploration will increase morbidity and/or mortality is not supported by these nor by any other data we can find.

Gunshot wounds

Mandatory LAP has long been considered the standard of care for management of abdominal GSWs, given that over 90 % of patients with peritoneal penetration have an injury requiring operative management [50]. In recent years, however, a number of reports have identified a subset of patients who may be candidates for nonoperative

management [51–54]. Stable, asymptomatic patients are candidates for CT scanning. Those who have clear evidence of extracavitary trajectory can be D/C'ed from the ED. Patients with isolated solid organ injuries may be candidates for nonoperative management. However, the setting must be appropriate, as the patient's condition could change abruptly [55].

References

1. Shaftan GW (1960) Indications for operation in abdominal trauma. Am J Surg 99:657–664
2. Leppaniemi A, Salo J, Haapiainen R (1995) Complications of negative laparotomy for truncal stab wounds. J Trauma 38:54–60
3. Renz BM, Feliciano DV (1996) The length of hospital stay after an unnecessary laparotomy for trauma: a prospective study. J Trauma 40:187–190
4. Biffl WL, Kaups KL, Cothren CC et al (2009) Management of patients with anterior abdominal stab wounds: a Western Trauma Association multicenter trial. J Trauma 66:1294–1301
5. Biffl WL, Kaups KL, Pham TN et al (2011) Validating the Western Trauma Association algorithm for managing patients with anterior abdominal stab wounds: a Western Trauma Association multicenter trial. J Trauma 71:1494–1502
6. Berg RJ, Karamanos E, Inaba K et al (2014) The persistent diagnostic challenge of thoracoabdominal stab wounds. J Trauma Acute Care Surg 76:418–423
7. Burlew CC, Moore EE, Moore FA et al (2012) Western Trauma Association critical decisions in trauma: resuscitative thoracotomy. J Trauma Acute Care Surg 73:1359–1363
8. Nicol AJ, Navsaria PH, Hommes M et al (2014) Sternotomy or drainage for a hemopericardium after penetrating trauma: a randomized controlled trial. Ann Surg 259:438–442
9. Shanmuganathan K, Mirvis SE, Chiu WC et al (2004) Penetrating torso trauma: triple-contrast helical CT in peritoneal violation and organ injury- A prospective study in 200 patients. Radiology 231:775–784
10. Moore EE, Marx JA (1985) Penetrating abdominal wounds: rationale for exploratory laparotomy. JAMA 253:2705–2708
11. Uribe RA, Pachon CE, Frame SB et al (1994) A prospective evaluation of thoracoscopy for the diagnosis of penetrating thoracoabdominal trauma. J Trauma 37:650–654
12. Murray JA, Demetriades D, Asensio JA et al (1998) Occult injuries to the diaphragm: prospective evaluation of laparoscopy in penetrating injuries to the left lower chest. J Am Coll Surg 187:626–630
13. Friese RS, Coln CE, Gentilello LM (2005) Laparoscopy is sufficient to exclude occult diaphragm injury after penetrating abdominal trauma. J Trauma 58:789–792
14. Himmelman RG, Martin M, Gilkey S et al (1991) Triple-contrast CT scans in penetrating back and flank trauma. J Trauma 31:852–856
15. Boyle EM Jr, Maier RV, Salazar JD et al (1997) Diagnosis of injuries after stab wounds to the back and flank. J Trauma 42:260–265
16. Ramirez RM, Cureton EL, Ereso AQ et al (2009) Single-contrast computed tomography for the triage of patients with penetrating torso trauma. J Trauma 67:583–588
17. Thompson JS, Moore EE, Van Duzer-Moore S et al (1980) The evolution of abdominal stab wound management. J Trauma 20:478–484
18. Nance FC, Wennar MH, Johnson LW et al (1974) Surgical judgment in the management of penetrating wounds of the abdomen: experience with 2,212 patients. Ann Surg 179:639–646
19. Cornell WP, Ebert PA, Greenfield LJ et al (1965) A new nonoperative technique for the diagnosis of penetrating injuries to the abdomen. J Trauma 7:307–314
20. Thal ER (1977) Evaluation of peritoneal lavage and local exploration in lower chest and abdominal stab wounds. J Trauma 17:642–648
21. Aragon GE, Eiseman B (1976) Abdominal stab wounds: evaluation of sinography. J Trauma 16:792–797
22. Oreskovich MR, Carrico CJ (1983) Stab wounds of the anterior abdomen: analysis of a management plan using local wound exploration and quantitative peritoneal lavage. Ann Surg 198:411–419
23. Ivatury RR, Simon RJ, Weksler B et al (1992) Laparoscopy in the evaluation of the intrathoracic abdomen after penetrating injury. J Trauma 33:101–106
24. Livingston DH, Tortella BJ, Blackwood J et al (1992) The role of laparoscopy in abdominal trauma. J Trauma 33:471–478
25. Rehm CG, Sherman R, Hinz TW (1989) The role of CT scan in evaluation for laparotomy in patients with stab wounds of the abdomen. J Trauma 29:446–450
26. Rozycki GS, Ochsner MG, Schmidt JA et al (1995) A prospective study of surgeon-performed ultrasound as the primary adjuvant modality for injured patient assessment. J Trauma 39:492–500
27. Demetriades D, Rabinowitz B (1987) Indications for operation in abdominal stab wounds: a prospective study of 651 patients. Ann Surg 205:129–132
28. Henneman PL, Marx JA, Moore EE et al (1990) Diagnostic peritoneal lavage: accuracy in predicting necessary laparotomy following blunt and penetrating trauma. J Trauma 30:1345–1355
29. Leppaniemi AK, Haapiainen RK (1996) Selective nonoperative management of abdominal stab wounds: prospective, randomized study. World J Surg 20:1101–1106
30. Tsikitis V, Biffl WL, Majercik S et al (2004) Selective clinical management of anterior abdominal stab wounds. Am J Surg 188:807–812
31. Leppaniemi AK, Voutilainen PE, Haapiainen RK (1999) Indications for early mandatory laparotomy in abdominal stab wounds. Br J Surg 86:76–80
32. Nagy K, Roberts R, Joseph K et al (1999) Evisceration after abdominal stab wounds: is laparotomy required? J Trauma 47:622–624
33. Rosenthal RE, Smith J, Walls RN et al (1987) Stab wounds to the abdomen: failure of blunt probing to predict peritoneal penetration. Ann Emerg Med 16:172–175
34. Schnuriger B, Inaba K, Barmparas G et al (2010) Serial white blood cell counts in trauma: do they predict a hollow viscus injury? J Trauma 69:302–307
35. Inaba K, Okoye OT, Rosenheck R et al (2013) Prospective evaluation of the role of computed tomography in the assessment of abdominal stab wounds. JAMA Surg 148:810–816
36. Udobi KF, Rodriguez A, Chiu WC et al (2001) Role of ultrasonography in penetrating abdominal trauma: a prospective clinical study. J Trauma 50:475–479
37. Murphy JT, Hall J, Provost D (2005) Fascial ultrasound for evaluation of anterior abdominal stab wound injury. J Trauma 59:843–846
38. Feliciano DV, Bitondo-Dyer CG (1994) Vagaries of the lavage white blood cell count in evaluating abdominal stab wounds. Am J Surg 168:680–683
39. Fang JF, Chen RJ, Lin BC (1998) Cell count ratio: new criterion of diagnostic peritoneal lavage for detection of hollow organ perforation. J Trauma 45:540–544

40. Otomo Y, Henmi H, Mashiko K et al (1998) New diagnostic peritoneal lavage criteria for diagnosis of intestinal injury. J Trauma 44:991–997
41. McAnena OJ, Marx JA, Moore EE (1991) Contributions of peritoneal lavage enzyme determinations to the management of isolated hollow visceral abdominal injuries. Ann Emerg Med 20:834–837
42. Jaffin JH, Ochsner MG, Cole FJ et al (1993) Alkaline phosphatase levels in diagnostic peritoneal lavage fluid as a predictor of hollow visceral injury. J Trauma 34:829–833
43. Leppaniemi A, Haapiainen R (2003) Diagnostic laparoscopy in abdominal stab wounds: a prospective, randomized study. J Trauma 55:636–645
44. O'Malley E, Boyle E, O'Callaghan A et al (2013) Role of laparoscopy in penetrating abdominal trauma: a systematic review. World J Surg 37:113–122
45. Sumislawski JJ, Zarzaur BL, Paulus EM et al (2013) Diagnostic laparoscopy after anterior abdominal stab wounds: worth another look? J Trauma Acute Care Surg 75:1013–1018
46. Fakhry SM, Broenstein M, Watts DD et al (2000) Relatively short diagnostic delays (<8 hours) produce morbidity and mortality in blunt small bowel injury: an analysis of time to operative intervention in 198 patients from a multicenter experience. J Trauma 48:408–415
47. Martin RR, Burch JM, Richardson R et al (1991) Outcome for delayed operation of penetrating colon injuries. J Trauma 31:1591–1595
48. Clarke DL, Allorto NL, Thomson SR (2010) An audit of failed non-operative management of abdominal stab wounds. Injury 41:488–491
49. Nance FC, Cohn I Jr (1969) Surgical judgment in the management of stab wounds of the abdomen: a retrospective and prospective analysis based on a study of 600 stabbed patients. Ann Surg 170:569–580
50. Moore EE, Moore JB, Van Duzer-Moore S et al (1980) Mandatory laparotomy for gunshot wounds penetrating the abdomen. Am J Surg 140:847–851
51. Renz BM, Feliciano DV (1994) Gunshot wounds to the right thoracoabdomen: a prospective study of nonoperative management. J Trauma 37:737–741
52. Demetriades D, Hadjizacharia P, Constantinou C et al (2006) Selective nonoperative management of penetrating abdominal solid organ injuries. Ann Surg 244:620–628
53. Navsaria PH, Nicol AJ (2009) Selective nonoperative management of kidney gunshot wounds. World J Surg 33:553–557
54. Navsaria PH, Nicol AJ, Krige JE et al (2009) Selective nonoperative management of liver gunshot injuries. Ann Surg 249:653–656
55. Jansen JO, Inaba K, Resnick S et al (2012) Selective non-operative management of abdominal gunshot wounds: survey of practice. Injury Int J Care Injured 44:639–644