# Initial antibiotic treatment for acute simple appendicitis in children is safe: Short-term results from a multicenter, prospective cohort study

**Ramon R. Gorter, MD,[a,b] Johanna H. van der Lee, MD, PhD,[c] Huibert A. Cense, MD, PhD,[b] C. M. Frank Kneepkens, MD, PhD,[d] Marc H. W. A. Wijnen, MD, PhD,[e] Klaas H. in 't Hof, MD, PhD,[f] Martin Offringa, MD, PhD,[g] *and* Hugo A. Heij, MD, PhD,[a] on behalf of the APAC Study Group,**
*Amsterdam, Beverwijk, Nijmegen, and Almere, The Netherlands, and Toronto, Canada*

***Background.*** *Initial antibiotic treatment for acute appendicitis has been shown to be safe in adults; so far, not much is known about the safety and efficacy of this treatment in children. The aims of this study were to investigate the feasibility of a randomized controlled trial (RCT) evaluating initial antibiotic treatment for acute appendectomy in children with acute simple appendicitis and to evaluate the safety of this approach.*
***Methods.*** *In a multicenter, prospective cohort study patients aged 7–17 years with a radiologically confirmed simple appendicitis were eligible. Intravenous antibiotics (amoxicillin/clavulanic acid 250/25 mg/kg 4 times daily; maximum 6,000/600 mg/d and gentamicin 7 mg/kg once daily) were administered for 48–72 hours. Clinical reevaluation every 6 hours, daily blood samples, and ultrasound follow-up after 48 hours was performed. In case of improvement after 48 hours, oral antibiotics were given for a total of 7 days. At any time, in case of clinical deterioration or non-improvement after 72 hours, an appendectomy could be performed. Follow-up continued until 8 weeks after discharge. Adverse events were defined as major complications of antibiotic treatment, such as allergic reactions, perforated appendicitis, and recurrent appendicitis.*
***Results.*** *Of 44 eligible patients, 25 participated (inclusion rate, 57%; 95% CI, 42%–70%). Delayed appendectomy was performed in 2, and the other 23 were without symptoms at the 8 weeks follow-up. Minor complications occurred in three patients. None of the patients suffered from an adverse event or a recurrent appendicitis.*
***Conclusion.*** *Our study shows that an RCT comparing initial antibiotic treatment strategy with urgent appendectomy is feasible in children; the intervention seems to be safe. (Surgery 2015;157:916-23.)*

*From the Paediatric Surgical Centre of Amsterdam,[a] Emma Children's Hospital AMC & VU University Medical Centre, Amsterdam; the Department of Surgery,[b] Red Cross Hospital, Beverwijk; the Paediatric Clinical Research Office Division Woman and Child,[c] Academic Medical Centre, Amsterdam; the Department of Paediatric Gastroenterology,[d] VU University Medical Centre, Amsterdam; the Department of Paediatric Surgery,[e] Radboud University Nijmegen Medical Centre, Nijmegen; the Department of Surgery,[f] Flevoziekenhuis, Almere, The Netherlands; and the Child Health Evaluative Sciences (CHES),[g] The Hospital for Sick Children, University of Toronto, Toronto, Canada*

No disclosures to report.

Part of this paper has been presented at the EUPSA 2014 meeting in Dublin, June 18–21, 2014.

Accepted for publication January 11, 2015.

Reprint requests: Ramon R. Gorter, MD, Paediatric Surgical Centre of Amsterdam, Emma Children's Hospital AMC and VU University Medical Centre, P. O. Box 22660, 1100 DD, Amsterdam, The Netherlands. E-mail: rr.gorter@vumc.nl.

0039-6060/$ - see front matter

© 2015 Elsevier Inc. All rights reserved.

http://dx.doi.org/10.1016/j.surg.2015.01.008

Acute appendicitis is a common gastrointestinal disease in children, generally considered to require operative intervention. In The Netherlands, >15,000 appendectomies are performed annually, >5,500 (37%) in patients below the age of 20.[1,2] This ancient strategy is based on the entrenched idea that appendicitis is an irreversibly progressive disease, starting with an uncomplicated stage and leading to a complicated stage with gangrene, perforation, and peritonitis. Surgeons, therefore, have advocated an aggressive surgical treatment ever since Fitz's report in 1886.[3] Removal of a healthy appendix

was never seen as an undesirable, let alone adverse, event.

Recently, this paradigm has shifted. Based on epidemiologic, radiologic, and pathologic studies, several authors no longer consider appendicitis as an invariably irreversible progressive disease.[4-8] Rather, they envisage 2 types of appendicitis: simple (uncomplicated or nonperforated) appendicitis with no tendency to progress, and complex (complicated or perforated) appendicitis.[4,5,7] In this view, the latter group represents a spectrum of disease severity and includes not only perforated appendicitis, but also gangrenous appendicitis, periappendicular abscess, periappendicular contained mass, and generalized purulent peritonitis.[4,5,7,9,10]

Subsequently, the effectiveness of initial antibiotic treatment for acute appendicitis in adults was investigated. Five randomized, controlled trials (RCTs) showed that antibiotic treatment alone was effective in 41–85% of the patients with a follow-up period of 1 year.[11-15] Several metaanalyses on this topic summarized the results of these studies inconsistently, with some favoring antibiotic treatment over primary appendectomy; others either favored appendectomy or were inconclusive.[16-21] Most authors conclude that antibiotic treatment alone is less effective than an appendectomy and therefore promote appendectomy.[16-20] However, the methodologic quality of the included studies was low to moderate, there was considerable statistical heterogeneity ($I^2$: 43-70%), and these inferences continue to be questioned.[16-18] In addition, potential long-term disadvantages of surgery in children have not been evaluated adequately.

In children, no prospective studies have been conducted to date. A recent review aiming to determine the role of conservative treatment for acute appendicitis in children stated that there are no reliable data, although there are some studies suggesting it to be safe.[21] One retrospective study of 16 children between the ages of 5 and 13 reported initial antibiotic treatment as safe and effective, with a recurrence rate of 13% (2/16) within 1 year after discharge.[22] Another recent retrospective study ($n$ = 12) concluded that antibiotic treatment for early acute appendicitis in selected children "can be successful." They found that 75% of the patients (<18 years old) did not require an appendectomy, avoiding surgery-related complications.[23] Another case series, reporting on 5 children who were not operated owing to hematologic malignancy and coexisting chemotherapy-induced neutropenia, reported antibiotic treatment to be curative in four of them (follow-up range, 0.5–3 years).[24] Initial antibiotic treatment for acute appendicitis in children may, therefore, be considered safe. Still, this controversial idea encounters resistance both in the general public as well as in the medical sector.

We conducted a pilot study with 2 goals: (1) to investigate the feasibility of a RCT comparing initial antibiotic treatment with acute appendectomy for children with acute simple appendicitis, (2) to investigate the safety of initial antibiotic treatment alone in terms of failures and complications of antibiotic treatment.

## PATIENTS AND METHODS

**Design and setting.** This multicenter, prospective cohort study was performed in 4 hospitals in The Netherlands, including 2 academic (tertiary referral) centers and 2 large peripheral hospitals. The study started in September (VU University Medical Centre, Amsterdam), November (Academic Medical Centre, Amsterdam), December 2012 (Red Cross Hospital, Beverwijk), and February 2014 (Flevoziekenhuis, Almere). Inclusion lasted until June 7, 2014. The medical ethics committee of the VU University medical center approved the study protocol.

**Study population.** All children 7 –17 years with a simple appendicitis, confirmed by imaging studies, were eligible for inclusion. Imaging studies had to confirm the diagnosis within 8 hours after presentation at the emergency department; otherwise, patients were excluded. Both radiologists and trainees performed the imaging studies; trainees were supervised. If ultrasonography was inconclusive, additional imaging studies such as MRI or CT could be performed according to the preference of the surgeon or radiologist, and in accordance with the local protocol for the diagnostic workup of appendicitis in children. Simple appendicitis was defined based on both clinical and radiologic variables. Clinical criteria included: unwell, but not generally ill; localized tenderness in the right iliac fossa region; normal/hyperactive bowel sounds; no mass palpable; and no diffuse guarding. Ultrasonography criteria included incompressible appendix with an outer diameter of >6 mm, hyperemia within the appendiceal wall, infiltration of the surrounding fat, and no signs of perforation, abscess, mass, phlegmon, disseminated peritoneal fluid, or extraluminal gas.

Patients <7 years old, those who presented with severe general illness (generalized peritonitis, severe sepsis or septic shock, and signs of complex appendicitis) and those with a fecolith present on ultrasonography were excluded. In addition,

patients with severe associated conditions or malformations and those with documented type 1 allergy to the antibiotics used were excluded.

The responsible physician informed eligible patients and their parents about this study and, if they agreed to participate, written informed consent was obtained before the start of the antibiotic administration.

**Intervention.** Study participants were admitted to the pediatric (surgical) ward and received intravenous (IV) antibiotics (amoxicillin/clavulanic acid 250/25 mg/kg 4 times daily; maximum 6,000/600 mg/d and gentamicin 7 mg/kg once daily) for ≥48 hours. During the first 24 hours, no oral intake was permitted and IV fluids were given. Every 6 hours, clinical reevaluation was performed systematically to identify signs of clinical deterioration at an early stage. If the clinical condition was improved (no fever, normal heart rate, normal daily activity, less pain) after 24 hours, a normal diet was started. After 48 hours, ultrasonography was repeated. If the patient met the criteria for improvement described herein, treatment was switched to oral antibiotics (amoxicillin/clavulanic acid 500/125 mg 3 times daily). The patient was kept in the hospital for another 24 hours to ensure adequate oral intake of the antibiotics and to observe the clinical status. If the clinical course was favorable, the patient was discharged after 72 hours from admission with oral antibiotics for another 4 days. The following criteria of improvement were used: body temperature < 38°C, visual analog scale/comfort scale < 4, adequate oral intake, able to mobilize, lower level of C-reactive protein, amount of leukocytes less than at admission, and no signs of complex appendicitis on repeat ultrasonography.

If after 48 hours the patient did not meet these criteria for improvement, IV administration was continued for another 24 hours with reevaluation. In case of either not meeting the criteria of improvement after 72 hours or signs of clinical deterioration during the antibiotic course, appendectomy was performed with its approach (open or laparoscopic) according to the surgeon's preference.

**Data collection, follow-up, and outcome measures.** A standardized case record form was used to record all pretreatment, peritreatment, and posttreatment data. Follow-up was conducted after 2 and 8 weeks in the outpatient clinic. The proportion of eligible patients willing to participate was used as a primary endpoint for feasibility. This endpoint was defined as the number of patients who consented to participate divided by the total number of eligible patients who had been informed and asked to participate in this study. An RCT was considered feasible if the lower boundary of the 95% CI of the proportion was >33%.

The safety of initial antibiotic treatment alone was investigated in terms of the proportion of patients in whom antibiotic treatment failed, that is, who required appendectomy owing to lack of response, and the occurrence of major complications of antibiotic treatment, for example, allergic reactions, perforated appendicitis, need for readmission, and recurrent appendicitis. If patients had to undergo appendectomy, the following outcomes were considered as safety issues as well: negative appendectomy, abscess formation, wound infection, wound rupture, wound herniation, readmission, reoperation, anesthesia-related complications, prolonged ileus requiring total parenteral nutrition, secondary bowel obstruction, and pneumonia.

**Statistical analysis.** Descriptive statistics were performed using SPSS version 20 (SPSS, Inc, Chicago, IL). Percentages and 95% CIs were calculated using the software CIA.[25]

## RESULTS

**Feasibility of the initial antibiotic strategy.** During the study period, 117 children with acute appendicitis were examined at the emergency departments of the participating hospitals. Seventy-three did not fulfil the inclusion criteria. The main exclusion criterion was the complexity of appendicitis. In 23 patients, the appendix could not be visualized on ultrasonography and it was decided not to obtain additional imaging studies, but to admit these patients for observation or to perform a diagnostic laparoscopy.

Of the 44 patients who were eligible, 25 were willing to participate, yielding an inclusion rate of 57% (95% CI, 42–70%; Fig 1). Reasons for nonparticipation were mostly lack of parental confidence in this unorthodox treatment. General characteristics of our study group are displayed in Table I. In 24 patients, the appendix could be visualized on ultrasonography. In the remaining patient, this was not the case but an additional CT was performed, which confirmed the diagnosis of simple appendicitis. Therefore, all included patients had a radiologic confirmed appendicitis.

**Safety of the initial antibiotic strategy.** All 25 patients were discharged with oral antibiotics. Twenty-three patients (92%) were still without symptoms after this treatment at the 8 weeks follow-up. Two patients eventually underwent appendectomy, one of them within 1 week after the start of antibiotic treatment because of persistent complaints with a

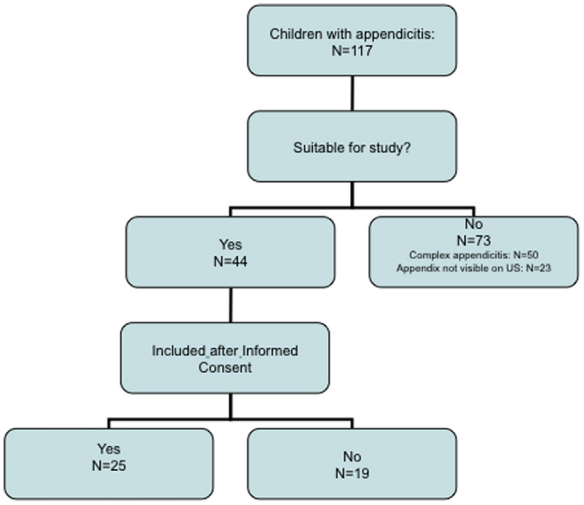


**Fig 1.** Flow diagram of patients with acute appendicitis.

fecolith visible on the second ultrasound. Owing to the significant improvement of his clinical condition, it was decided to change to oral antibiotic treatment after 48 hours and an extra follow-up check was made. However, at this follow-up, he had persistent complaints and it was decided to perform an appendectomy. The other patient underwent an appendectomy after 6 weeks because of suspected recurrent appendicitis. Both patients underwent laparoscopic appendectomy without complications. Histopathologic examination of the first appendix revealed chronic fibrosis with little inflammation response, and the other appendix showed fibrosis and no inflammation. The short-term complications associated with initial antibiotic treatment strategy are summarized in Table II. All patients recovered uneventfully after their complication. None of the included patients suffered eventually from complex appendicitis.

Figure 2 shows the flow diagram of the 25 patients treated with initial antibiotic treatment. During the clinical phase of the study, all patients responded well to IV antibiotics. As demonstrated in Fig 2, 22 of 25 the patients received IV antibiotics for 48 hours. The reasons for prolonged IV administration of antibiotics (72 hours) were a visual analog scale score of >3 in 1 patient and an increasing C-reactive protein level in the remaining 2 patients. All patients fulfilled the criteria for improvement after 72 hours.

## DISCUSSION

This multicenter, prospective cohort study shows that a subsequent RCT comparing initial antibiotic treatment with acute appendectomy for acute simple appendicitis in children is feasible and safe. The initial antibiotic strategy (with an appendectomy in case of failure) was effective in all cases. In our study, almost all patients on initial antibiotic treatment did not need appendectomy within 8 weeks after initial antibiotic treatment. The 2 patients in whom eventually an appendectomy was performed did not have any complications. We conclude that this management strategy is safe for children with simple appendicitis.

To our knowledge, this is the first prospective study investigating the short-term results of initial antibiotic treatment of appendicitis in children. As initial antibiotic treatment has conquered the field of other previously strictly surgical diseases such as

**Table I.** Clinical characteristics

| *Characteristics* | *Value* |
|---|---|
| Clinical variable ($n$ = 25) | |
| Age (y)* | 13 (10–16) |
| Gender (M/F) | 15/10 |
| Duration of pain (d)* | 2 (1–4) |
| Nausea | 19 (76%) |
| Vomiting | 11 (44%) |
| Diarrhea | 3 (12%) |
| Fever | 4 (16%) |
| Anorexia | 17 (68%) |
| Physical examination | |
| Temperature (°C)* | 37.3 (36.0–38.3) |
| Heart rate (beats/min)* | 85 (61–122) |
| Weight (kg)* | 50 (26.5–95.0) |
| Localized RLQ pain | 25 (100%) |
| Laboratory results | |
| CRP (mg/L)* | 29.0 (1.0–112.0) |
| Leukocytes ($\times 10^9$/L)* | 12.7 (5.7–19.2) |
| Ultrasound findings | |
| Appendix visible | 24 (96%) |
| Noncompressible | 24 (96%) |
| Tenderness | 24 (96%) |
| Diameter (mm)* | 9.0 (6.0–15.0) |
| Fecolith | 0 (0%) |
| Free fluid | 12 (48%) |
| Infiltrate | 0 (0%) |
| Abscess | 0 (0%) |
| Lymphadenopathy | 9 (36%) |
| Mesenteric fat infiltration | 22 (88%) |
| Complex signs | 0 |
| Additional imaging study | 1 (4%): CT-scan (case in which the appendix could not be visualized by ultrasonography) |

*Results are displayed as median and (range).
Results are displayed as number of patients (percentage), unless noted otherwise.
*CRP*, C-reactive protein; *RLQ*, right lower quadrant.

**Table II.** Overview of the short term complications of initial antibiotic treatment: Appendectomy and complications

| *Characteristic* | *No. of patients* | *Comment* |
|---|---|---|
| Delayed appendectomy | 2/25 | |
| Postappendectomy complications | 0/2 | |
| Complication | 3/25 | Clinical phase: Overdose antibiotics, no consequence ($n$ = 1)<br>Eight-week follow-up: Cystitis (additional antibiotic treatment; $n$ = 1); assumed allergic reaction to oral antibiotics ($n$ = 1) |
| Unscheduled extra emergency department visits | 3/25 | Reason: Abdominal pain in all 3 |
| Recurrent appendicitis | 0/25 | |
| Complex appendicitis | 0/25 | |

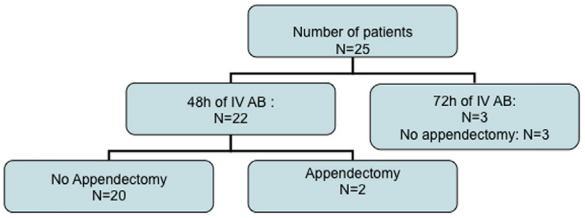


**Fig 2.** Flow diagram of the included patients.

diverticulitis, the investigation of this strategy in simple appendicitis in adults was a logical next step, with promising results.[11-15] Urgent appendectomy for simple appendicitis, although effective, has been associated with complications such as surgical site infection, small bowel obstruction, intra-abdominal abscess, and appendectomy of an appendix sana.[11-15] Its associated mortality rate is low at 0.07–0.7%.[26,27] The major advantage of initial antibiotic treatment is the avoidance of surgery and its above mentioned related (early, but especially late) complications. In children with simple appendicitis the frequency of postappendectomy complications depends on the surgical approach, but ranges from 3 to 11% at the 1-year follow-up.[11-15,23,28,29]

Not much is known yet about initial antibiotic treatment strategy in children. Outcomes reported in the scarce available literature and our study have been summarized in Table III.[22-24] In total, 58 patients have been treated with the initial antibiotic treatment strategy. In the majority of patients ($n$ = 49), surgery could be avoided (84%; 95% CI, 73–95%). The remaining 9 patients underwent an appendectomy for the following reasons: failure of the initial antibiotic ($n$ = 5), recurrent appendicitis ($n$ = 3), and suspicion of recurrent appendicitis, although the diagnosis could not be confirmed ($n$ = 1). Other complications associated with initial antibiotic strategy were noted in 3 of the 58 patients. The question is whether these complications would imply an important argument against the strategy of antibiotics only; in our study, most of the complications were not severe and did not require invasive procedures. In comparison with the known literature of postappendectomy complications (up to 11%), this strategy reduces potentially the incidence of complications. This conclusion is in line with results from metaanalyses demonstrating that in adults initial antibiotic treatment reduced the risk of complications with 43–46%.[16,18,21,23,28]

To reduce the frequent adverse effects of appendectomy in patients who may benefit from antibiotics alone, this study should be considered the first step in a treatment algorithm for acute simple appendicitis, reserving an appendectomy only for those not responding to initial antibiotic treatment.[16,21] This strategy may be ≤ 100% effective in treating acute simple appendicitis. Metaanalyses on this subject should, therefore, focus on effectiveness and complications associated with the complete strategy—≤1 year after the acute episode—rather than comparing the efficacy of antibiotics alone with appendectomy.

A major criticism of previous studies in adults was the lack of radiologic confirmation. All children in our study had ultrasound-proven appendicitis and would traditionally have been scheduled for surgery. The strength of our protocol is the strict selection of children and adolescents who might benefit from initial antibiotic treatment. Although there are several scoring systems for the differentiation of simple from complex appendicitis, we were unable to use them, because they are not compatible with our national guideline for the workup of acute

**Table III.** Overview of outcomes of the treatment strategy of antibiotics only in the literature[22-24]

| | *Initial antibiotic treatment* | | | | *Delayed appendectomy after initial antibiotic strategy (reason)* | |
|---|---|---|---|---|---|---|
| *First author* (n) | *No complications* | *Failure of initial AB strategy* | *Complications* | *Recurrence at follow-up* | *No complications* | *Complications* |
| Abes[22] (16) | 13 | 1 | 0 | 2 | 3 (2 recurrence, 1 failure) | 0 |
| Wiegering[24] (5) | 4 | 1 | 0 | 0 | 1 (failure) | 0 |
| Armstrong[23] (12) | 9 | 2 | 0 | 1 | 2 (1 failure, 1 recurrent) | 1 (failure) (IAA) |
| Gorter (current study; 25) | 21 | 1 | 3 | 0 | 2 (1 failure, 1 suspicion recurrent appendicitis) | 0 |
| Overall (58) | 47 (81%) | 5 (9%) | 3 (5%) | 3 (5%) | 8 (14%) | 1 (2%) |
| 95% CI | 69–89%* | 4–18%* | 2–14%* | 2–14%* | 7–25%* | 0–9%* |

*Results are displayed as 95% CI of the above mentioned percentage.
Results are displayed as number of patients (percentage), unless noted otherwise.
*IAA*, Intra-abdominal abscess.

appendicitis.[30-34] In our study, CT was only performed in a 16-year-old boy, weighing 95 kg. Although CT is valuable in detecting both simple and complex appendicitis in adults, it should be avoided preferably in children because of the radiation associated.[30-34] Ultrasonography has a good sensitivity (99%), specificity (95%), and positive predictive value (97%) for diagnosing appendicitis in children, although its value might be reduced especially in obese children.[35-37] With ultrasonography, simple appendicitis can be differentiated from complex appendicitis.[35-40] However, because ultrasonography is operator dependent, the reported sensitivity and specificity may have a limited generalizability. The stringency of our inclusion criteria may explain the relatively large proportion of patients treated successfully with antibiotics alone. Selection of those patients who might benefit from initial antibiotic treatment is crucial. Therefore, a tailor-made approach for acute appendicitis is necessary.

Opponents of initial antibiotic treatment raise several concerns, such as the relatively high therapeutic failure rate of antibiotic treatment alone (≤59%).[16-21] In our opinion, however, the initial antibiotic strategy should be part of an algorithm, starting with antibiotic treatment and including appendectomy for those not responding. The effectiveness of this strategy is, therefore, comparable with acute appendectomy as a first step (100%). The gain can be shown in reduction of medical and financial costs of the primary appendectomy. In our study, the costs of our strategy were assumed to be relatively high owing to increased duration of hospital stay, and additional ultrasonography and blood draws, procedures that were included in our study protocol for safety issues. Because the results of our study now seem to be favorable regarding safety, we plan to reduce the number of blood samples per patient to 2 and to reduce the minimum duration of hospital stay from 72 to 48 hours. This change will reduce further the costs associated with our strategy.

Another potential disadvantage is the fact that, owing to not removing an inflamed appendix, parents will be concerned about (recurrent) appendicitis every time a child develops abdominal pain in the future. In our study, 3 of the 25 children visited the emergency department after the intervention owing to recurrent abdominal pain. This rate might even increase over time. However, we think that, when sufficient information is given to parents regarding so-called alarm symptoms and when the conservative treatment becomes less unusual, the rate will be comparable with that after an initial appendectomy.

Some authors are concerned about the higher incidence of perforated appendicitis, complications associated with delayed appendectomy, and recurrent appendicitis. None of the patients in our study had a perforated appendicitis. In the literature, only 1 patient was reported to suffer from a perforated appendicitis while being treated with antibiotics (Table III).[24] Regarding postoperative complications, none were noted in our study group. In only 1 of the 9 patients undergoing a delayed appendectomy described in the literature (Table III), a complication was noted; an intraabdominal abscess requiring readmission, but no invasive procedure.[23] Metaanalyses of adult RCTs did not show a higher incidence of surgical site infections after delayed appendectomy.[16-21] In addition, the assumed incidence of recurrent appendicitis in adults varies from 14 to 35%. The latter rate is questionable, because important information such as how the diagnosis was made and whether pathologic examination confirmed

recurrent appendicitis is lacking.[11-21] However, when looking at the available literature in children, recurrent appendicitis ranges from 0 to 13%, with an average of 5% (Table III). In our study group, no recurrences have been reported to date. Nevertheless, the occurrence of perforated appendicitis was not greater among adult patients with recurrent appendicitis and some specialists suggest that antibiotics could be given for a second time, as is sometimes done in patients with diverticulitis.[16] Another concern is the possibility of missing an underlying cause for the acute appendicitis, in particular malignancy, the prevalence of which ranges from 0.5% in children to 1.6% in adults with a first episode of appendicitis.[41-44] It is questionable as to whether this possibility justifies primary appendectomy in all cases, especially given that such patients will probably not respond to antibiotics and, therefore, require subsequent further action within this protocol.

Our study has some limitations. One of the main concerns to our study might be the antibiotics used. Based on our standard postoperative protocol for patients with perforated appendicitis, we have chosen to administer amoxicillin/clavulanic acid combined with gentamicin, because *Escherichia coli* is increasingly resistant in Europe.[45] Second, only 25 patients were included. The relatively low number is explained by the stringency of our inclusion and exclusion criteria, the initial skepticism of both medical personnel, as well as parents against this new treatment strategy, but also by the fact that 2 tertiary referral centers participated in this study. The proportion of patients with complex appendicitis in these centers is much higher than in large, peripheral centers. Furthermore, we decided to exclude patients <7 years old as the incidence of complex appendicitis in this specific age group is greater. Surprisingly, in most patients with inconclusive results on ultrasonography, it was decided not to obtain additional imaging studies but to admit and observe the patients or to perform a diagnostic laparoscopy, which also contributed to the relatively small number of patients included. Third, the follow-up period of 8 weeks can be considered insufficient. For now, we can conclude that the short-term results of the pharmaceutical treatment are favorable, avoiding surgery in the majority of the patients. However, long-term results are needed to confirm these conclusions. Fourth, the duration of hospitalization is longer than in case of an appendectomy. In the future, however, it will be possible to reduce the durations of hospitalization in patients who have improved sufficiently after 48 hours of IV antibiotics. For safety reasons, this was not done in the current study. Last, our study design is an uncontrolled cohort study. This study was designed as a pilot study to investigate the feasibility and safety of the treatment protocol starting with antibiotics. Eventually, a RCT will be set up comparing both strategies.

In conclusion, our study confirms that a RCT comparing initial antibiotic treatment strategy with urgent appendectomy is feasible in children; the intervention seems to be safe.

The APAC Study Group includes the following contributors: From the VU University Medical Centre, Amsterdam: N. Ahmadi, Department of Radiology; P. Bet, Department of Pharmacology; J. Bonjer, Department of Surgery; F. Galindo, Department of Epidemiology. From the Academic Medical Centre, Amsterdam: R. van Rijn, Department of Radiology; M.A. Benninga, Department of Paediatrics. From the Red Cross Hospital, Beverwijk: D. Hilarius, Department of Pharmacology; S. van Veen, Department of Radiology. From the Antonius Hospital, Nieuwegein: P.M.N.Y.H. Go, Department of Surgery. From the Slotervaartziekenhuis, Amsterdam: Y. Acherman, Department of Surgery.

## REFERENCES

1. Central Agency for Statistics 2014 [cited 2014 Mar 20]. Available from: http://statline.cbs.nl/StatWeb/publication/?VW=T&DM=SLNL&PA=80386NED&LA=NL. Accessed date: 18th of February 2015.
2. Morrow SE, Newman KD. Current management of appendicitis. Semin Pediatr Surg 2007;16:34-40.
3. Fitz RH. Perforating inflammation of the vermiform appendix. Am J Med Sci 1886;92:321-46.
4. Livingstone EH, Woodward WA, Sarosi GA, et al. Disconnect between the incidence of non-perforated and perforated appendicitis: implications for pathophysiology and management. Ann Surg 2007;245:886-92.
5. Andersson RE. The natural history and traditional management of appendicitis revisited: spontaneous resolution and predominance of prehospital perforations imply that a correct diagnosis is more than an early diagnosis. World J Surg 2007;31:86-92.
6. Narsule CK, Kahle EJ, Kim DS, et al. Effect of delay in presentation on rate of perforation in children with appendicitis. Am J Emerg Med 2011;29:890-3.
7. Carr NJ. The pathology of acute appendicitis. Ann Diagn Pathol 2000;4:46-58.
8. Cobben LP, de Van Otterloo AM, Puylaert JB. Spontaneously resolving appendicitis etc. Radiology 2000;215:349-52.
9. Simillis C, Symeonides P, Shorthouse AJ, Tekkis PP. A meta-analysis comparing conservative treatment versus appendectomy for complicated appendicitis (abscess or phlegmon). Surgery 2010;147:818-29.
10. Andersson RE, Petzold MG. Nonsurgical treatment of appendiceal abscess or phlegmon. A systematic review and meta-analysis. Ann Surg 2007;246:741-8.

11. Eriksson S, Granstrom L. Randomized clinical trial of appendectomy versus antibiotic therapy for acute appendicitis. Br J Surg 1995;82:166-9.
12. Styrud J, Eriksson S, Nilsson I, Ahlberg G, Haapaniemi S, Neovius G, et al. Appendectomy versus antibiotic treatment in acute appendicitis. A prospective multicentre randomized controlled trial. World J Surg 2006;30:1033-7.
13. Hansson J, Körner U, Khorram-Manesh A, Solberg A, Lundholm K. Randomized clinical trial of antibiotic therapy versus appendectomy as primary treatment of acute appendicitis in unselected patients. Br J Surg 2009;96:473-81.
14. Malik AA, Bari S. Conservative management of acute appendicitis. J Gastrointest Surg 2009;13:966-70.
15. Vons C, Barry C, Maitre S, Pautrat K, Leconte M, Costaglioli B, et al. Amoxicillin plus clavulanic acid versus appendicectomy for treatment of acute uncomplicated appendicitis. An open label, non-inferiority, randomised controlled trial. Lancet 2011;377:1573-9.
16. Varadhan KK, Neal KR, Lobo DN. Safety and efficacy of antibiotics compared with appendicectomy for treatment of uncomplicated acute appendicitis: meta analysis of randomised controlled trials. BMJ 2012;344:e2156.
17. Wilms IMHA, de Hoog DENM, de Visser DC, Janzing HMJ. Appendectomy versus antibiotic treatment for acute appendicitis (review). Cochrane Database Syst Rev 2011:CD008359.
18. Mason RJ, Moazzez A, Sohn H, Katkhouda N. Meta-analysis of randomized trials comparing antibiotic therapy with appendectomy for acute uncomplicated (no abscess or phlegmon) appendicitis. Surg Infect (Larchmt) 2012;13:74-84.
19. Ansaloni L, Catena F, Coccolini F, Ercolani G, Gazzotti F, Pasqualini E, et al. Surgery versus conservative antibiotic treatment in acute appendicitis: a systematic review and meta-analysis of randomized controlled trials. Dig Surg 2011;28:210-21.
20. Liu K, Fogg L. Use of antibiotics alone for treatment of uncomplicated acute appendicitis: a systematic review and meta-analysis. Surgery 2011;150:673-83.
21. Svensson JF, Hall NJ, Eaton S, Pierro A, Wester T. A review of conservative treatment of acute appendicitis. Eur J Pediatr Surg 2012;22:185-94.
22. Abes M, Petik B, Kazil S. Nonoperative treatment of acute appendicitis in children. J Pediatr Surg 2007;42:1439-42.
23. Armstrong J, Merritt N, Jones S, Scott L, Butter A. Non-operative management of early, acute appendicitis in children: is it safe and effective? J Pediatr Surg 2014;49:782-5.
24. Wiegering VA, Kellenberger CJ, Bodmer N, Bergstraesser E, Niggli F, Grotzer M, et al. Conservative management of acute appendicitis in children with hematologic malignancies during chemotherapy-induced neutropenia. J Pediatr Hematol Oncol 2008;30:464-7.
25. Altman D, Machin D, Bryant T, Gardner S, editors. Statistics with confidence: confidence intervals and statistical guidelines. 2nd ed. London, UK: BMJ Books; 2000.
26. Blomqvist P, Ljung H, Nyren O, Ekbom A. Appendectomy in Sweden 1989-1993 assessed by the inpatient registry. J Clin Epidemiol 1998;51:859-65.
27. Margenthaler J, Longo WE, Virgo KS, Johnson PE, Grossman EM, Schifftner TL, et al. Risk factors for adverse outcomes after surgical treatment of appendicitis in adults. Ann Surg 2003;238:59-66.
28. Markar SR, Blackburn S, Cobb R, Karthikesalingam A, Evans J, Kinross J, et al. Laparoscopic versus open appendectomy for complicated and uncomplicated appendicitis in children. J Gastrointest Surg 2012;16:1993-2004.
29. Lintula H, Kokki H, Vanamo K. Single-blind randomized clinical trial of laparoscopic versus open appendicectomy in children. Br J Surg 2001;88:510-4.
30. Williams RF, Blakely ML, Fischer PE, Streck CJ, Dassinger MS, Gupta H, et al. Diagnosing ruptured appendicitis preoperatively in pediatric patients. J Am Coll Surg 2009;208:819-25.
31. Broker MEE, van Lieshout EMM, van der Elst M, Stassen LPS, Schepers T. Discriminating between simple and perforated appendicitis. J Surg Res 2012;176:79-83.
32. Peng YS, Lee HC, Yeung CY, Sheu JC, Wang NL, Tsai YH. Clinical criteria for diagnosing perforated appendix in pediatric patients. Pediatr Emerg Care 2006;22:475-9.
33. Oliak D, Yamini D, Udani VM, Lewis RJ, Vargas H, Arnell T, et al. Can perforated appendicitis be diagnosed preoperatively based on admission factors. J Gastrointest Surg 2000;4:470-4.
34. Bakker OJ, Go PM, Puylaert JB, Kazemier G, Heij HA. Werkgroep richtlijn diagnostiek en behandeling acute appendicitis. Guideline on diagnosis and treatment of acute appendicitis: imaging prior to appendectomy is recommended. Ned Tijdschr Geneeskd 2010;154:A303.
35. Hopkins KL, Patrick LE, Ball TI. Imaging findings of perforative appendicitis: a pictorial review. Pediatr Radiol 2001;31:173-9.
36. Wiersma F, Sramek A, Holscher HC. US features of the normal appendix and surrounding area in children. Radiology 2005;235:1018-22.
37. Wiersma F, Torenvliet BR, Bloem JL. US examination of the appendix in children with suspected appendicitis; the additional value of secondary signs. Eur Radiol 2009;19:455-61.
38. Goldin AB, Khanna P, Thapa M, McBroom JA, Garrison MM, Parisi MT. Revised ultrasound criteria for appendicitis in children improve diagnostic accuracy. Pediatr Radiol 2011;41:993-9.
39. Park NH, Oh HE, Park HJ, Park JY. Ultrasonography of normal and abnormal appendix in children. World J Radiol 2011;3:85-91.
40. Blumfield E, Nayak G, Srinivasan R, Muranaka MT, Blitman NM, Blumfield A, et al. Ultrasound for differentiation between perforated and nonperforated appendicitis in pediatric patients. AJR Am J Roentgenol 2013;200:957-62.
41. Chandrasegaram MD, Rothwell LA, An EI, Miller RJ. Pathologies of the appendix: a 10-year review of 4670 appendicectomy specimens. ANZ J Surg 2012;82:844-7.
42. Khan RA, Ghani I, Chana RS. Routine histopathological examination of appendectomy specimens in children: is there any rationale? Pediatr Surg Int 2011;27:1313-5.
43. Spunt SL, Pratt CB, Rao BN. Childhood carcinoid tumors: the St. Jude Children's research hospital experience. J Pediatr Surg 2000;35:1282-6.
44. Rabah R. Pathology of the appendix in children: an institutional experience and review of the literature. Pediatr Radiol 2007;37:15-20.
45. Oteo J, Campos J, Lazaro E. Increased amoxicillin-clavulanic acid resistance in Escherichia coli blood isolate, Spain. Emerg Infect Dis 2008;14:1259-62.