Is there a role for systematic hepatic pedicle lymphadenectomy in intrahepatic cholangiocarcinoma? A review of 17 years of experience in a tertiary institution

Dong Hun Kim, MD,[a] Dong Wook Choi, MD, PhD,[b] Seong Ho Choi, MD, PhD,[b] Jin Seok Heo, MD, PhD,[b] *and* **Alfred Wei-Chieh Kow, MBBS, FRCSEd,[c]** *Cheonan and Seoul, Republic of Korea, and Singapore*

Background. *Although use of lymphadenectomy for treatment of extrahepatic cholangiocarcinoma is established, routine lymphadenectomy for intrahepatic cholangiocarcinoma (ICC) remains controversial. We examined the factors predicting survival in patients after ICC resection and compared outcomes of patients with and without systematic hepatic pedicle lymph node dissection (LND).*

Methods. *Data were retrospectively collected for 215 patients with ICC who underwent liver resection during the years 1995–2012. Patients were divided into those (n = 102; 47.4%) who received LND (LN [D]) and those (n = 113; 52.6%) who did not (LN [D0]).*

Results. *Demographic data were similar between the 2 groups except for presence of preoperative symptom (P = .019) and liver cirrhosis (P < .001), carbohydrate antigen 19-9 (P = .003), tumor location according to the hepatic lobe (P < .001), type of hepatectomy (P < .001), adjuvant treatment (P < .001), and postoperative complications (P = .028). Tumor recurrence at a distant site was observed in 102 patients (68.5%). LN metastasis was independently associated with risk of distant recurrence (P = .002). The LN (D) and LN (D0) groups did not differ in overall survival (P = .101) or disease-free survival (P = .111). Poorly differentiated histologic grade (P = .016) and LN metastasis (P < .001) was identified as an independent predictor of overall survival.*

Conclusion. *Routine LND for ICC did not show survival benefits; however, LN sampling might be useful for nodal staging, an essential factor in predicting outcome and deciding whether to apply adjuvant treatment. (Surgery 2015;157:666-75.)*

From the Department of Surgery,[a] Dankook University Hospital, Cheonan; Department of Surgery,[b] Samsung Medical Center, Sungkyunkwan University School of Medicine, Seoul, Republic of Korea; and Department of Hepatopancreatobiliary and Liver Transplantation,[c] University Surgical Cluster, National University Health System, Singapore

Intrahepatic cholangiocarcinoma (ICC) is the second most common primary liver cancer after hepatocellular carcinoma.[1] The origin of ICC is typically defined as the intrahepatic bile duct epithelium beyond the second-order peripheral branches.[2,3] Several countries report an increase in the incidence of ICC.[4,5] Patients with ICC have advanced disease frequently at diagnosis owing to rapid tumor growth, the presence of vascular invasion, perineural invasion, extrahepatic metastases, or multiple intrahepatic metastases.[6-9]

Complete operative resection produces the best long-term outcome for ICC.[3,5,7] For patients with resectable ICC, many surgeons recommend extended operative resection because locoregional extension and lymphatic spread of the disease are usually advanced at diagnosis.[1,10-12] Even patients with late-stage ICC have a median survival time of 14 months after extended hepatectomy and combined resection of adjacent organs.[5] Multiple factors influence survival after resection for ICC, including positive resection margin, lymph node (LN) metastases, intrahepatic metastases, mass-forming (MF) type, tumor multiplicity or size, and macroscopic vascular invasion.[7-9,13-16]

Accepted for publication November 6, 2014.

Reprint requests: Dong Wook Choi, MD, PhD, Department of Surgery, Samsung Medical Center, Sungkyunkwan University School of Medicine, 50 Irwon-dong, Gangnam-gu, Seoul 135-710, Korea. E-mail: dwchoi@skku.edu.

0039-6060/$ - see front matter

© 2015 Elsevier Inc. All rights reserved.

http://dx.doi.org/10.1016/j.surg.2014.11.006

Although positive LN status is an unfavorable prognostic sign, the value of LN dissection (LND) in the course of liver resection is controversial. In some studies, the LN ratio (the ratio of the number of positive LNs to the total harvested nodes) correlated well with outcome; however, this evaluation involves comparison between study groups, and is difficult to apply universally to individual patients unless LND is routinely performed during resection procedures at the same institution.[9,14] Some studies have suggested that routine LND may decrease locoregional nodal recurrence and optimize pathologic staging.[17] Others suggested that routine LND is unnecessary and does not improve patient survival consistently.[2,16] At this time, no clear guidelines exist for use of LND for ICC. In this study, we aimed to evaluate the use of hepatic pedicle lymphadenectomy on ICC treatment and to analyze factors that predict survival in ICC.

METHODS

Patient selection. Data from a prospectively maintained bile duct malignancy database were retrieved and reviewed. From May 1995 to August 2012, surgical resection with curative intent was performed for 316 patients with ICC at Samsung Comprehensive Cancer Center, Samsung Medical Center, Seoul, Republic of Korea. We excluded 4 patients who received neoadjuvant therapy for a huge mass or palliative resection, and 23 patients who were treated for other primary malignancies concurrently (n = 4), preoperatively (n = 12), or postoperatively (n = 7). Also excluded were 56 patients with ICC combined with hepatocellular carcinoma or other histologic cholangiocarcinoma types, including intraductal papillary neoplasm of the bile duct, biliary cystic neoplasm, and adenosquamous or sarcomatous types. We also excluded 18 patients who underwent LN sampling, selectively collected <3 LNs for permanent pathologic evaluation in cases of suspected lymphadenopathy in the hepatoduodenal ligament. We included only patients with tubular adenocarcinoma arising from the intrahepatic bile duct, and identified 215 patients with data suitable for analysis.

Preoperative preparations. Patients with suspected ICC were symptomatic or diagnosed by incidental radiologic study. Tumor markers including carbohydrate antigen (CA) 19-9, α-fetoprotein and carcinoembryonic antigen levels were routinely measured. Triphasic computed tomography (CT) was usually the initial imaging modality. In equivocal situations, further imaging studies, such as magnetic resonance imaging (MRI), were employed. In selected cases for which suspicion of distant metastases was high, positron emission tomography (PET) was performed to rule out extrahepatic metastases, which would preclude curative surgical resection. Portal vein embolization was performed in 8 patients (3.7%) at 2–4 weeks before surgery, at which time the estimated extent of hepatectomy had reached ≥70%.

Criteria for resectable ICC were: (1) absence of distant metastases on imaging scans, (2) absence of intrahepatic metastases to the contralateral lobe of the liver, (3) absence of clinically and/or radiologically evident lymphadenopathy in the para-aortic region, and (4) adequate functional reserve of the liver based on Child-Pugh scoring and an indocyanine-green retention R15 test.

Operative techniques with LND. Type of resection was determined by the lesion location based on Couinaud's classification of hepatic segments. Surgeons chose anatomic liver resection, including extended liver resection with caudate lobectomy, to maximize resection margins for better oncological clearance. En bloc resection of surrounding organs was performed when local invasion of the hepatic lesion was detected intraoperatively.

Three of 9 surgeons adopted the policy that lymphadenectomy of the hepatic pedicle would improve the long-term outcome of ICC patients. This resulted in 2 distinct groups of patients, one with (LN [D]) and one without (LN [D0]) hepatic pedicle lymphadenectomy. We analyzed the outcomes of patients in these 2 groups. Hepatic pedicle lymphadenectomy proceeded according to hepatic lobe. For lesions in the right lobe, systematic lymphadenectomy was performed by removing lymphatic tissues and LNs along the hepatoduodenal ligament, the common hepatic artery and the celiac axis. For tumors in the left hepatic lobe, the lesser omentum and its connective tissue with LNs along the left gastric artery were also dissected. Six surgeons, who took a view that the lymphadenectomy did not improve survival of ICC patients, did not perform it. We did not analyze frozen sections to ascertain metastatic status. However, in patients with lymphadenopathy in the para-aortic region or with large LNs invading the hepatic vasculature, most surgeons ended the operation. These patients were excluded from analysis. In the pathology laboratory, LNs were dissected from resected specimens, examined microscopically, and assessed for tumor metastases by multiple thin sectioning and immunohistochemistry. Peritoneal cytology was not obtained before surgical procedures.

Follow-up schedule. Detailed follow-up information was recorded at visits every 3 months for 2

years after surgery. At the outpatient clinic review, the tumor markers CA 19-9 and carcinoembryonic antigen were assessed and CT was performed routinely. Patients with positive nodal disease in the LN (D) group and selected patients with higher T stage and positive resection margins in the LN (D0) group underwent adjuvant treatment after surgery. Some patients did not undergo adjuvant treatment because they refused or were in poor condition generally. Adjuvant treatment options included concurrent chemotherapy (5-fluorouracil [FU] with or without cisplatin, or gemcitabine and oxaliplatin) and radiotherapy (16–54 Gy), or just radiotherapy in patients with positive resection margins and poor general condition.

Outcome parameters. Data retrieved and reviewed included patient demography and preoperative clinical variables; tumor size, multiplicity, location, and degree of differentiation; macroscopic growth type and resection margin; and presence of vascular and perineural invasion, adjacent organ invasion and intrahepatic metastases. The 7th edition of the American Joint Committee on Cancer was employed for TNM staging.[18] In fact, a comparison of overall stage between groups is impossible except for the T stage because the N status in the LN (D0) group cannot be identified. Macroscopic growth was classified into MF, periductal infiltrating (PI) or intraductal growth types, according to the system proposed by the Liver Cancer Study Group of Japan.[15] Tumor location was classified by pathologic criteria into peripheral and central types. Central tumors involved the first-order branch of the bile duct or expanded nearly to the hilum from the peripheral bile duct. Peripheral tumors were located anywhere from the second-order branch of the bile duct to the peripheral duct.

Statistical analysis. Data were analyzed using PASW Statistics version 20.0 (SPSS, IBM corp., Armonk, NY). Chi-square tests were used to cross-tabulate nominal data. Parametric continuous variables were tested using Student's *t* tests, and the Mann–Whitney test was used for nonparametric continuous variables. Patient survival was calculated using the Kaplan–Meier method, and survival curves were compared using the log-rank test. The Cox proportional hazard model was used to test the prognostic significance of factors related to survival.

RESULTS

Demographics and surgical results. The mean age of the study population was 60.2 ± 9.1 years, and male patients (n = 138; 64.2%) outnumbered females. The type and extent of surgical procedures are presented in Table I. In advanced disease, bile duct resection with Roux-en-Y hepaticojejunostomy (17 patients) or portal vein (6 patients) or hepatic artery (1 patient) segmental resection and primary anastomosis were also performed. Anastomosis was interposed with cadaveric vein graft in one patient with portal vein resection.

Table I. Operative procedures for intrahepatic cholangiocarcinoma

Variable	n *(%)*
Type of hepatectomy (n = 215)	
Minor resections	48 (22.3)
Wedge resection	4 (1.8)
Segmentectomy	12 (5.6)
Bisegmentectomy	32 (14.9)
Major resections (right/left)	123 (57.2)
Hemihepatectomy (+ S1)	119 (55.3)
Central bisectionectomy	4 (1.8)
Extended resections (right/left)	44 (20.5)
Extended hemihepatectomy (+ S1)	35 (16.2)
Trisectionectomy (+ S1)	9 (4.2)
Additional procedure	
Bile duct resection	17 (7.9)
Vascular resection	7 (3.3)
Hepatic artery	1 (0.5)
Portal vein	6 (2.8)
Other organ resection	18 (8.4)
Radiofrequency ablation	1 (0.5)
LN dissection	
None	102 (47.4)
Lymphadenectomy*	113 (42.6)

*Dissected hepatoduodenal ligament, common hepatic artery up to celiac axis or lesser omentum.
LN, Lymph node; *S1*, segment 1.

Among the 215 patients in the study, 113 (52.6%) were in the LN (D) group and 102 (47.4%) were in the LN (D0) group. Demographic parameters of age, gender and risk factors for ICC were the same overall between the 2 groups (Table II). However, more patients in the LN (D0) group had liver cirrhosis ($P < .001$) and no preoperative symptom (P = .019). Symptoms cited for 115 patients (53.5%) were abdominal pain (38.6%), dyspepsia (5.1%), jaundice (3.3%), general weakness and fatigue (4.7%), fever (1.4%), and weight loss (0.5%). Preoperative CA 19-9 levels, tumor location according to hepatic lobe, type of resection, and adjuvant treatment differed significantly between the 2 groups. After resection, 36 patients (16.7%) received adjuvant treatment. Thirty-two patients of them underwent concurrent chemoradiotherapy and 4 radiotherapy alone. Four patients in the LN (D0) group underwent chemoradiotherapy after operative resection and had positive

Table II. Demographics and clinical features in intrahepatic cholangiocarcinoma with or without lymph node dissection

Characteristic	*LN (D0)* (n = *102)*	*LN (D)* (n = *113)*	P *value*
Age, y (range)	60.9 (37–79)	59.6 (37–80)	.289
Gender, *n*			.115
Male	71 (69.6)	67 (59.3)	
Female	31 (30.4)	46 (40.7)	
Symptoms, *n* (%)			.019
Asymptomatic	56 (54.9)	44 (38.9)	
Symptomatic	46 (45.1)	69 (61.1)	
Risk factors			
Intrahepatic duct stone, *n* (%)	11 (10.8)	12 (10.6)	.969
Clonorchis sinensis, *n* (%)	4 (3.9)	5 (4.5)	.843
Liver cirrhosis, *n* (%)	17 (16.7)	3 (2.7)	<.001
Chronic hepatitis B infection, *n* (%)	26 (25.5)	19 (16.8)	.118
Preoperative tumor marker levels			
CA 19-9 (U/mol ± SD)	1,715.81 ± 9,265.0	4,140.9 ± 17,161.3	.003
CEA (U/mol ± SD)	14.3 ± 31.6	6.7 ± 23.2	.095
Tumor location (hepatic lobe)			<.001
Right	70 (68.6)	50 (44.2)	
Left	32 (31.4)	63 (55.8)	
PVE, *n*	4 (3.9)	4 (3.5)	.883
Type of hepatectomy,* *n* (%)			<.001
Minor resections	35 (34.3)	13 (11.5)	
Major resections	54 (52.9)	69 (61.1)	
Extended resections	13 (12.7)	31 (27.4)	
Adjuvant treatment, *n* (%)	4 (3.9)	32 (28.3)	<.001
Hospital stay (days ± SD)	13.7 ± 9.1	13.5 ± 8.1	.757
Postoperative complications, *n* (%)	23 (22.5)	41 (36.3)	.028
Hepatic insufficiency	7 (6.9)	5 (4.4)	
Hepatic failure	1 (1.0)	—	
Portal vein thrombosis	1 (1.0)	2 (1.8)	
Bile leakage	1 (1.0)	6 (5.3)	
Intra-abdominal fluid collection	2 (2.0)	10 (8.8)	
Wound infection	9 (8.8)	11 (9.7)	
Ileus	1 (1.0)	7 (6.2)	
Pleural effusion	4 (3.9)	1 (0.9)	
Pneumonia	2 (2.0)	—	
Other†	1 (1.0)	2 (1.8)	

*Minor hepatectomies defined as resection of 2–3, major defined as 4, and extended defined as ≥5 Couinaud hepatic segments, except segment 1.
†Atrial tachycardia, acute pyelonephritis, and pneumatosis intestinalis.
LN (D) and (D0), With and without lymph node dissection; *PVE,* portal vein embolization; *SD,* standard deviation.

resection margin and higher T stage in pathology. Gemcitabine-based chemotherapy was performed in 5 patients and the others underwent 5-FU–based chemotherapy. During the postoperative period, 64 patients (29.8%) experienced complications. Postoperative complications were significantly higher in the LN (D) group compared with the LN (D0) group ($P = .028$). Interventional procedures, such as percutaneous drainage and endoscopic retrograde cholangiopancreatography, for intra-abdominal fluid collection or bile leakage were performed postoperatively in 15 of 64 patients (23.4%). Two patients (0.9%) underwent reoperation for postoperative complications of pneumatosis intestinalis and mechanical ileus. One patient (0.5%) died postoperatively from hepatic failure.

Pathologic characteristics. No differences were observed between the 2 groups with regard to tumor size, tumor differentiation, tumor multiplicity, or microscopic positive resection margin (Table III). However, a significantly greater proportion of patients in the LN (D) group had lymphovascular ($P < .001$) or perineural invasion ($P = .003$). Tumor distribution with peripheral location ($P < .001$), lower T stage ($P = .001$), intraductal growth and MF growth types ($P < .001$), and adjacent organ invasion ($P = .028$) were significantly

Table III. Pathologic characteristics in intrahepatic cholangiocarcinoma with or without lymph node dissection

Characteristic	*LN (D0)* (n = *102*)	*LN (D)* (n = *113*)	P *value*
Tumor size, (cm ± SD)	4.9 ± 2.8	5.2 ± 2.5	.076
Tumor location*			<.001
Peripheral	91 (89.2)	67 (59.3)	
Central	11 (10.8)	46 (40.7)	
Stratified T stage, *n* (%)			.001
Tis	3 (2.9)	1 (0.9)	
T1/T2	74 (72.5)	59 (52.2)	
T3/T4	25 (24.5)	53 (46.9)	
Tumor differentiation, *n* (%)			.051
Well	17 (16.7)	12 (10.6)	
Moderate	58 (56.9)	52 (46.0)	
Poorly	23 (22.5)	45 (39.8)	
NA	4 (3.9)	4 (3.5)	
Macroscopic growth type, *n* (%)			<.001
Intraductal growth	9 (8.8)	4 (3.5)	
Mass forming	86 (84.3)	79 (69.9)	
Periductal infiltrating	6 (5.9)	15 (13.3)	
Mixed forms†	1 (1.0)	15 (13.3)	
Multiple tumors, *n* (%)	16 (15.7)	22 (19.5)	.468
Lymphovascular invasion, *n* (%)	19 (18.6)	45 (39.8)	<.001
Perineural invasion, *n* (%)	23 (22.5)	50 (44.2)	.003
Adjacent organ invasion, *n* (%)	13 (12.7)	5 (4.4)	.028
Positive resection margin, *n* (%)	5 (4.9)	12 (10.6)	.121

*Central tumor, involvement of first-order branch of bile duct from near the peripheral bile duct; peripheral, anywhere from second-order branch of the bile duct to peripheral duct.
†Mass-forming and periductal infiltrating growth types.
LN (D) and (D0), With and without lymph node dissection; *NA*, not available; *SD*, standard deviation.

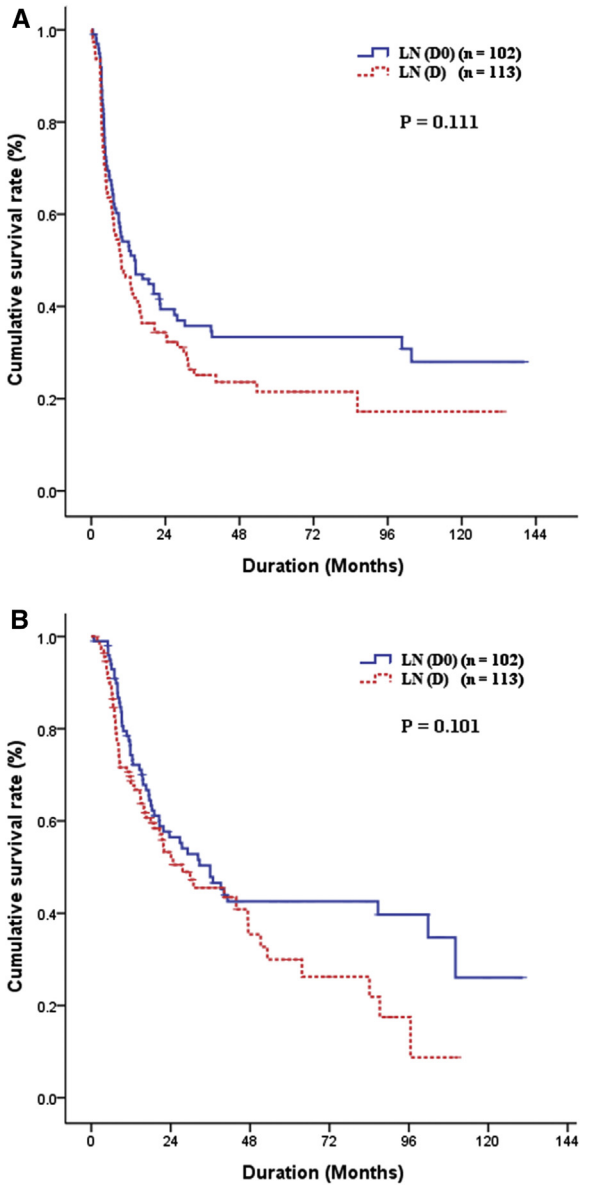

Fig 1. (*A*) Disease-free and (*B*) overall survival in patients with or without lymph node dissection.

greater in the LN (D0) group compared with the LN (D) group.

In patients for whom LND was performed, the mean number of harvested LNs was 12.8 ± 8.0 (range, 4–51) and the mean number of involved LNs was 2.4 ± 3.6 (range, 0–18). Slightly more than one-half of patients (n = 58; 51.3%) in the LN (D) group had metastases to the harvested LNs.

Recurrence patterns. Recurrence rates were 73.5% (n = 83) in the LN (D) group and 64.7% (n = 66) in the LN (D0) group. Locoregional and distant recurrence were seen in 21 and 62 patients, respectively, in the LN (D) group, corresponding with 26 and 40 patients in the LN (D0) group (P = .099). The median disease-free survival was 11.1 months (range, 0.2–140.3). The cumulative 1-, 3-, and 5-year disease-free survival rates in the LN (D) group were 46.9%, 25.4%, and 21.7%, respectively, and 54.1%, 35.8%, and 33.4% in the LN (D0) group. No difference was observed in disease-free survival between the 2 groups (P = .111; Fig 1, *A*). The anatomic sites of initial tumor recurrences are shown in Table IV. Among 149 patients (69.3%) with tumor recurrence, locoregional recurrences were observed in 47 patients (31.5%), and tumor recurrence at a distant site, with or without associated locoregional recurrence, in 102 patients (68.5%). Simultaneous locoregional recurrences were observed in 3

Table IV. Primary recurrence sites of intrahepatic cholangiocarcinoma

Site of recurrence	n *(%)*
Locoregional	
Liver resection margin	20 (13.4)
Porta hepatis or retroperitoneal LN	29 (19.5)
Hepaticojejunostomy site	1 (0.7)
Distant	
Intrahepatic metastases	67 (55.0)
Peritoneum	29 (19.5)
Lung	23 (15.4)
Bone	5 (3.4)
Brain	2 (1.3)
Abdominal wall	2 (1.3)
Skin	1 (0.7)

LN, Lymph node.

patients (2.0%), and simultaneous distant recurrences in 27 patients (18.1%). Fifty-one patients (34.2%) had disease recurrence concomitantly at a locoregional and a distant site. The most frequent site of recurrence was the liver (n = 87; 58.4%), including the liver resection margin and intrahepatic metastases, followed by the peritoneum (n = 29), regional LNs (n = 25), lung (n = 23) and bone (n = 5).

In univariate analyses, T3 and T4 stage, poorly differentiated histologic grade, MF and PI or mixed growth type, tumor multiplicity, LN metastases, and elevated CA 19-9 level were significantly associated with distant recurrence patterns. In multivariate analysis using logistic regression, LN metastasis (odds ratio [OR], 10.42; P = .002) was the only independent predictor of distant recurrence after curative resection (Table V).

Long-term outcome. The median duration of follow-up was 17.0 months (range, 0.7–130.4). The median overall survival for patients was 30.9 months (range, 0.8–130.4). For patients with LND, median overall survival was 27.6 compared with 35.9 months for patients without LND (P = .101; Fig 1, *B*). The cumulative 1-, 3-, and 5-year survival rates in the LN (D) group were 67.7%, 45.5%, and 30.0%, respectively, and those in the LN (D0) group were 74.3%, 47.8%, and 42.5%. Among patients with LND, the presence of LN metastases was associated with significantly shorter overall survival. The median overall survival was 63.7 months for patients without LN metastases and 11.9 months for patients with LN metastases ($P < .001$; Fig 2).

Prognostic factors for overall survival. Univariate analysis showed significant correlations between overall survival and stratified T stage, poorly differentiated histologic grade, tumor size >4 cm, MF and PI or mixed growth type, tumor multiplicity, LN metastases, elevated CA 19-9 level, and adjuvant therapy. However, LND did not significantly influence overall survival (hazard ratio [HR], 1.36; P = .102). In multivariate analysis using Cox proportional hazard regression, poorly differentiated histologic grade (HR, 2.08; P = .016) and LN metastasis (HR, 4.36; $P < .001$) were the independent prognostic factors in overall survival (Table VI).

DISCUSSION

Surgical resection of the liver is the only curative treatment for patients with ICC that achieves long-term survival.[3,7] However, the prognosis of ICC patients is generally poor owing to a high incidence of tumor recurrence.[4,19,20] The reported 5-year survival rates after surgical resection for ICC range from 4.1 to 43.8%,[3,9,21-24] consistent with results of the present study. Although several clinicopathologic factors have been reported to influence survival after resection for ICC,[7-9,13-16] LN status may be the most strongly predictive. In this study, presence of LN metastases was the independent negative predictor of overall survival in multivariate analysis. These results were similar to previous studies on prognostic factors of ICC after operative resection with curative intent. The importance of LN metastasis is a recurrent theme in the investigation of ICC. Results of a multicenter study from Japan[25] demonstrated that LN involvement was the most significant independent negative predictor of outcome. Miwa et al[3] reported that presence of LN metastases at initial hepatectomy strongly correlates with extension of ICC to the hepatic hilum and with larger tumor size. Nakagawa et al[9] showed a significant association of the presence of multiple tumors with involvement of ≥3 LNs, implying that tumor multiplicity predicts metastatic potential. Among a large series of patients who underwent ICC resection at Memorial Sloan-Kettering Cancer Center,[4] those with positive LN status had significantly shorter disease-free survival (median, 7 months) and overall disease-specific survival (median, 14 months). Likewise, we found that patients with LN metastases had significantly shorter overall survival (median, 11.9 months) compared with those without the metastases (median, 63.7 months).

Based on results for management of breast and gastric cancers, removal of regional LNs might improve regional disease control in ICC. However, the putative benefits of axillary LND for survival remain controversial, despite several large-scale

Table V. Univariate and multivariate analyses of prognostic factors for distant recurrence

Characteristic	*Univariate*			*Multivariate*		
	OR	*95% CI*	P *value*	*OR*	*95% CI*	P *value*
LN (D)	1.54	0.84–2.80	.162			
Tumor location*						
Peripheral	1.00					
Central	1.68	0.81–3.46	.162			
T stage						
Tis, T1/T2	1.00			1.00		
T3/T4	2.72	1.40–5.45	.004	0.89	0.26–3.06	.849
Tumor differentiation						
Well to moderate	1.00					
Poor	2.26	1.10–4.64	.027	1.21	0.38–3.86	.752
Macroscopic growth type						
Intraductal growth	1.00			1.00		
Mass forming	35.03	4.38–280.17	.001	2.27	0.17–29.58	.532
Periductal infiltrating or mixed forms†	27.00	3.10–235.02	.003	1.36	0.08–22.03	.828
Multiple tumors	5.20	1.53–17.70	.008	5.2	0.59–46.12	.139
Lymphovascular invasion	1.55	0.53–4.53	.421			
Adjacent organ invasion	2.13	0.59–7.63	.247			
Positive resection margin	1.82	0.50–6.62	.366			
LN metastases	13.419	3.73–48.26	<.001	10.42	2.45–44.364	.002
Elevated CA 19-9 level (≥37 U/mol)	3.38	1.74–6.59	<.001	1.98	0.66–5.99	.225

*Central tumor, involvement of first-order branch of bile duct from near the peripheral bile duct; peripheral, anywhere from second-order branch of the bile duct to peripheral duct.
†Mass-forming and periductal infiltrating growth type.
LN (D), Lymph node dissection; *LN*, lymph node; *CI*, confidence interval.

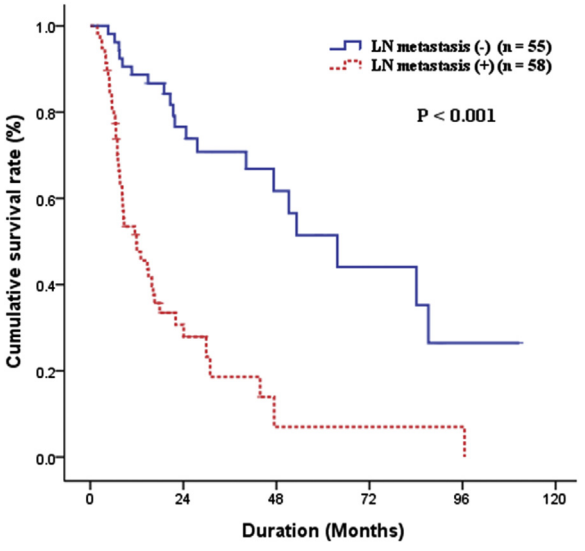

Fig 2. Overall survival in the lymph node (LN) patient group with lymph node dissection according to the presence of LN metastasis. Survival in the node-negative group was significantly higher than in the group with nodal involvement.

trials including the National Surgical Adjuvant Breast and Bowel Project (NSABP) 04 trial. Although studies have reported a survival advantage (5.4% in a meta-analysis) for patients undergoing axillary LND, recent updates of the NSABP 04 trial and the Curie trial suggested otherwise.[26-28] Similar to lymphadenectomy for gastric cancer, the survival benefit of LND as part of surgical treatment for gastric carcinoma is under debate. The extent of LND (conventional D1 vs extended D2/3) is also a topic of contention in the literature. However, LND clearly facilitates the pathologic staging of gastric cancer and is essential for predicting outcome and guiding the use of adjuvant treatment after curative resection.[29,30] Survival benefits after LND for ICC resection are unconfirmed, however. Based on strong evidence supporting the importance of accurate LN metastases evaluation for ICC after operative resection, some centers advocate routine LND during the operation.[2,7] Some studies have reported that selected patients with a small number of LN metastases might benefit from lymphadenectomy, with 5-year survival between 25 and 33%.[6,9,22] Suzuki et al[6] observed favorable long-term survival rates for patients with MF ICC and metastasis limited to a single lesion in regional nodes, after extensive operative procedures, including systematic lymphadenectomy. Similarly, Choi et al[2] concluded that regional plus α-LND may improve survival of ICC patients with LN metastases, and

Table VI. Univariate and multivariate analyses of prognostic factors for overall survival (n = 215)

Characteristic	Univariate			Multivariate		
	HR	*95% CI*	P *value*	*HR*	*95% CI*	P *value*
LN (D)	1.36	0.94–1.96	.102			
Tumor location*						
Peripheral	1.00					
Central	1.33	0.89–2.00	.167			
Left hepatic lobe	1.00					
Right hepatic lobe	0.95	0.66–1.37	.797			
T stage						
Tis, T1/T2	1.00			1.00		
T3/T4	2.12	1.46–3.08	<.001	1.28	0.70–2.33	.424
Tumor differentiation						
Well to moderate	1.00			1.00		
Poor	1.75	1.19–2.58	.005	2.08	1.14–3.77	.016
Tumor size >4 cm	2.22	1.49–3.29	<.001	1.15	0.60–2.23	.671
Macroscopic growth type						
Intraductal growth	1.00			1.00		
Mass forming	12.54	1.74–90.53	.012	1.53	0.19–12.60	.694
Periductal infiltrating or mixed forms†	12.19	1.62–91.56	.015	1.11	0.12–10.10	.928
Multiple tumors	1.87	1.21–2.90	.005	1.22	0.62–2.43	.565
Lymphovascular invasion	1.72	0.86–3.44	.123			
Adjacent organ invasion	1.63	0.90–2.97	.109			
Positive resection margin	1.73	0.90–3.32	.099			
LN metastases	4.29	2.46–7.46	<.001	4.36	2.14–8.85	<.001
Elevated CA 19-9 level (≥37 U/mol)	1.78	1.19–2.66	.005	0.94	0.50–1.78	.851
Adjuvant treatment	1.91	1.19–3.06	.007	0.73	0.37–1.43	.357

*Central tumor, involvement of first-order branch of bile duct from near the peripheral bile duct; peripheral, anywhere from second-order branch of the bile duct to peripheral duct.
†Mass-forming and periductal infiltrating growth type.
LN (D), Lymph node dissection; *LN*, lymph node; *CI* confidence interval.

that LND may reliably establish nodal status. In contrast, Shimada et al,[1] reporting on Japanese patients in Nagoya, suggested that LND may be useful for diagnostic staging and exclusion of positive regional LNs in patients with MF and MF plus PI ICC. In the studies cited, routine LND for ICC was not recommended because overall survival did not improve compared with that of patients who did not undergo LND. Another study from Japan[16,25] also concluded that LND does not improve patient survival clearly. In our study, LND was not associated with improvement of overall survival compared with that of patients without LND. Furthermore, our data suggested that the overall survival in patients with LN metastasis was poor and distant recurrences were more frequent than locoregional as the first site.

In our study, the 5-year disease-free survival rate was 27.6% with a median disease-free survival of 11.1 months. Previous studies had similarly high rates of recurrence with poor disease-free survival.[3,31,32] Hyder et al[33] showed a relatively equal distribution between the liver and extrahepatic recurrence sites. Other reports indicated that remnant liver is the most common site of recurrence.[4,22,32,34] Recurrence patterns after ICC resection in this study showed distant recurrences to be more common than locoregional and remnant liver recurrences, including resection margins, and intrahepatic metastasis was the most common form of recurrence. Furthermore, LN metastasis independently predicted distant recurrence.

Without LND, nodal assessment is incomplete, and the essential component of TNM staging is compromised. The accuracy of CT and/or MRI in the assessment of perihepatic LN metastasis is reported to be 57–77%, and the most common error on preoperative imaging is underestimation of nodal involvement.[2,35,36] LN sampling in the pericholedochal regions may enable clinicians to assess the exact LN status and predict the outcome of the patient.[2] Some investigators suggested that ≥6 or 7 LNs should be assessed for accurate staging of gallbladder cancer or hilar cholangiocarcinoma, respectively; however, no such number has been established for ICC.[37,38] Medical oncologists require appropriate malignancy staging to determine the best adjuvant regimen, and the TNM

staging system provides criteria for matching ICC patients with appropriate adjuvant therapy.[39] The effectiveness of chemotherapy for cholangiocarcinoma is not defined clearly because adequate trials are difficult to conduct for rare tumor types such as this. In general, the response rate of ICC to chemotherapy is low, and an effective standard chemotherapeutic regimen is lacking.[40,41] Recent phase II studies of gemcitabine-based systemic chemotherapy have demonstrated remarkable response rates.[42,43] Yamanaka et al[44] indicated that adjuvant gemcitabine chemotherapy may improve survival after curative resection of advanced stage ICC. Others identified adjuvant chemotherapy as an independent prognostic factor for overall survival.[45] Our study found no association of adjuvant therapy with overall survival. Also, because the health insurance coverage on gemcitabine was lower in Korea, 5-FU chemotherapy was mainly performed in this study, and it may affect outcomes. Nonetheless, we continue to search for multimodal therapies to treat cholangiocarcinoma effectively, because some studies have shown that combination treatments improve long-term outcome.[32,39]

This study had several limitations. First, our institution had no standardized practice regarding LND for ICC treatment. This lack of standardization reflects the absence of guidelines, attributable to contradictory evidence in the literature. Recognizing a need for strong prospective data concerning the routine use of LND for ICC, we conducted this retrospective cohort study. Second, the use of a retrospective study design may introduce selection bias. For example, survival outcomes may have been influenced by statistically different pathologic characteristics of patients, preoperative CA 19-9, effects of adjuvant treatment, or the differences in type of resection or macroscopic growth type between the 2 study groups. Actually, a comparison of survival rate for patients who underwent LND and those who did not is troublesome because the LN status for patients who did not undergo LND cannot be ascertained. Although routine LND for ICC did not show survival benefits in our study, we could not determine exactly the relations between LND and surgical outcomes by these various limitations. However, prospective randomized controlled trials might clarify the impact of hepatic pedicle lymphadenectomy on ICC, although such trials require large study groups for statistical power.

In conclusion, poorly differentiated histologic grade and the presence of LN metastasis were identified as independent factors in predicting overall survival and as positive risk factors for distant metastases after ICC resection. Evaluation of LN, as through LN sampling, may be considered for accurate pathologic staging of ICC, which is important for predicting the course of disease and for decisions regarding adjuvant treatment. Furthermore, this may serve as a stepping stone, with randomized controlled trial to determine the significance of the systematic hepatic pedicle LND in ICC.

REFERENCES

1. Shimada K, Sano T, Nara S, Esaki M, Sakamoto Y, Kosuge T, et al. Therapeutic value of lymph node dissection during hepatectomy in patients with intrahepatic cholangiocellular carcinoma with negative lymph node involvement. Surgery 2009;145:411-6.
2. Choi SB, Kim KS, Choi JY, Park SW, Choi JS, Lee WJ, et al. The prognosis and survival outcome of intrahepatic cholangiocarcinoma following surgical resection: association of lymph node metastasis and lymph node dissection with survival. Ann Surg Oncol 2009;16:3048-56.
3. Miwa S, Miyagawa S, Kobayashi A, Akahane Y, Nakata T, Mihara M, et al. Predictive factors for intrahepatic cholangiocarcinoma recurrence in the liver following surgery. J Gastroenterol 2006;41:893-900.
4. Endo I, Gonen M, Yopp AC, Dalal KM, Zhou Q, Klimstra D, et al. Intrahepatic cholangiocarcinoma: rising frequency, improved survival, and determinants of outcome after resection. Ann Surg 2008;248:84-96.
5. Taylor-Robinson SD, Foster GR, Arora S, Hargreaves S, Thomas HC. Increase in primary liver cancer in the UK, 1979-94. Lancet 1997;350:1142-3.
6. Suzuki S, Sakaguchi T, Yokoi Y, Okamoto K, Kurachi K, Tsuchiya Y, et al. Clinicopathological prognostic factors and impact of surgical treatment of mass-forming intrahepatic cholangiocarcinoma. World J Surg 2002;26:687-93.
7. Shen WF, Zhong W, Xu F, Kan T, Geng L, Xie F, et al. Clinicopathological and prognostic analysis of 429 patients with intrahepatic cholangiocarcinoma. World J Gastroenterol 2009;15:5976-82.
8. Shirabe K, Mano Y, Taketomi A, Soejima Y, Uchiyama H, Aishima S, et al. Clinicopathological prognostic factors after hepatectomy for patients with mass-forming type intrahepatic cholangiocarcinoma: relevance of the lymphatic invasion index. Ann Surg Oncol 2010;17:1816-22.
9. Nakagawa T, Kamiyama T, Kurauchi N, Matsushita M, Nakanishi K, Kamachi H, et al. Number of lymph node metastases is a significant prognostic factor in intrahepatic cholangiocarcinoma. World J Surg 2005;29:728-33.
10. Cherqui D, Tantawi B, Alon R, Piedbois P, Rahmouni A, Dhumeaux D, et al. Intrahepatic cholangiocarcinoma. Results of aggressive surgical management. Arch Surg 1995;130:1073-8.
11. Yamamoto M, Takasaki K, Yoshikawa T. Extended resection for intrahepatic cholangiocarcinoma in Japan. J Hepatobiliary Pancreat Surg 1999;6:117-21.
12. Lang H, Sotiropoulos GC, Fruhauf NR, Domland M, Paul A, Kind EM, et al. Extended hepatectomy for intrahepatic cholangiocellular carcinoma (ICC): when is it worthwhile? Single center experience with 27 resections in 50 patients over a 5-year period. Ann Surg 2005;241:134-43.

13. Jiang BG, Sun LL, Yu WL, Tang ZH, Zong M, Zhang YJ. Retrospective analysis of histopathologic prognostic factors after hepatectomy for intrahepatic cholangiocarcinoma. Cancer J 2009;15:257-61.
14. Tamandl D, Kaczirek K, Gruenberger B, Koelblinger C, Maresch J, Jakesz R, et al. Lymph node ratio after curative surgery for intrahepatic cholangiocarcinoma. Br J Surg 2009; 96:919-25.
15. Uenishi T, Kubo S, Yamazaki O, Yamada T, Sasaki Y, Nagano H, et al. Indications for surgical treatment of intrahepatic cholangiocarcinoma with lymph node metastases. J Hepatobiliary Pancreat Surg 2008;15:417-22.
16. Shimada M, Yamashita Y, Aishima S, Shirabe K, Takenaka K, Sugimachi K. Value of lymph node dissection during resection of intrahepatic cholangiocarcinoma. Br J Surg 2001;88:1463-6.
17. Yamashita Y, Taketomi A, Morita K, Fukuhara T, Ueda S, Sanefuji K, et al. The impact of surgical treatment and poor prognostic factors for patients with intrahepatic cholangiocarcinoma: retrospective analysis of 60 patients. Anticancer Res 2008;28:2353-9.
18. Farges O, Fuks D, Le Treut YP, Azoulay D, Laurent A, Bachellier P, et al. AJCC 7th edition of TNM staging accurately discriminates outcomes of patients with resectable intrahepatic cholangiocarcinoma: by the AFC-IHCC-2009 study group. Cancer 2011;117:2170-7.
19. Tamandl D, Herberger B, Gruenberger B, Puhalla H, Klinger M, Gruenberger T. Influence of hepatic resection margin on recurrence and survival in intrahepatic cholangiocarcinoma. Ann Surg Oncol 2008;15:2787-94.
20. Paik KY, Jung JC, Heo JS, Choi SH, Choi DW, Kim YI. What prognostic factors are important for resected intrahepatic cholangiocarcinoma? J Gastroenterol Hepatol 2008;23: 766-70.
21. Morimoto Y, Tanaka Y, Ito T, Nakahara M, Nakaba H, Nishida T, et al. Long-term survival and prognostic factors in the surgical treatment for intrahepatic cholangiocarcinoma. J Hepatobiliary Pancreat Surg 2003;10:432-40.
22. Ohtsuka M, Ito H, Kimura F, Shimizu H, Togawa A, Yoshidome H, et al. Results of surgical treatment for intrahepatic cholangiocarcinoma and clinicopathological factors influencing survival. Br J Surg 2002;89:1525-31.
23. Jan YY, Yeh CN, Yeh TS, Hwang TL, Chen MF. Clinicopathological factors predicting long-term overall survival after hepatectomy for peripheral cholangiocarcinoma. World J Surg 2005;29:894-8.
24. Weber SM, Jarnagin WR, Klimstra D, DeMatteo RP, Fong Y, Blumgart LH. Intrahepatic cholangiocarcinoma: resectability, recurrence pattern, and outcomes. J Am Coll Surg 2001;193:384-91.
25. Uchiyama K, Yamamoto M, Yamaue H, Ariizumi S, Aoki T, Kokudo N, et al. Impact of nodal involvement on surgical outcomes of intrahepatic cholangiocarcinoma: a multicenter analysis by the Study Group for Hepatic Surgery of the Japanese Society of Hepato-Biliary-Pancreatic Surgery. J Hepatobiliary Pancreat Sci 2011;18:443-52.
26. Quan ML, McCready D. The evolution of lymph node assessment in breast cancer. J Surg Oncol 2009;99:194-8.
27. Orr RK. The impact of prophylactic axillary node dissection on breast cancer survival–a Bayesian meta-analysis. Ann Surg Oncol 1999;6:109-16.
28. Louis-Sylvestre C, Clough K, Asselain B, Vilcoq JR, Salmon RJ, Campana F, et al. Axillary treatment in conservative management of operable breast cancer: dissection or radiotherapy? Results of a randomized study with 15 years of follow-up. J Clin Oncol 2004;22:97-101.
29. Sano T, Sasako M, Yamamoto S, Nashimoto A, Kurita A, Hiratsuka M, et al. Gastric cancer surgery: morbidity and mortality results from a prospective randomized controlled trial comparing D2 and extended para-aortic lymphadenectomy–Japan Clinical Oncology Group study 9501. J Clin Oncol 2004;22:2767-73.
30. de Bree E, Charalampakis V, Melissas J, Tsiftsis DD. The extent of lymph node dissection for gastric cancer: a critical appraisal. J Surg Oncol 2010;102:552-62.
31. Chen LP, Li C, Wang C, Wen TF, Yan LN, Li B. Predictive factors of recurrence for patients with intrahepatic cholangiocarcinoma after hepatectomy. Hepatogastroenterology 2012;59:1765-8.
32. Ercolani G, Vetrone G, Grazi GL, Aramaki O, Cescon M, Ravaioli M, et al. Intrahepatic cholangiocarcinoma: primary liver resection and aggressive multimodal treatment of recurrence significantly prolong survival. Ann Surg 2010; 252:107-14.
33. Hyder O, Hatzaras I, Sotiropoulos GC, Paul A, Alexandrescu S, Marques H, et al. Recurrence after operative management of intrahepatic cholangiocarcinoma. Surgery 2013;153:811-8.
34. Yamamoto M, Takasaki K, Otsubo T, Katsuragawa H, Katagiri S. Recurrence after surgical resection of intrahepatic cholangiocarcinoma. J Hepatobiliary Pancreat Surg 2001;8:154-7.
35. Park MS, Lee DK, Kim MJ, Lee WJ, Yoon DS, Lee SJ, et al. Preoperative staging accuracy of multidetector row computed tomography for extrahepatic bile duct carcinoma. J Comput Assist Tomogr 2006;30:362-7.
36. Vilgrain V. Staging cholangiocarcinoma by imaging studies. HPB (Oxford) 2008;10:106-9.
37. Ito H, Ito K, D'Angelica M, Gonen M, Klimstra D, Allen P, et al. Accurate staging for gallbladder cancer: implications for surgical therapy and pathological assessment. Ann Surg 2011;254:320-5.
38. Ito K, Ito H, Allen PJ, Gonen M, Klimstra D, D'Angelica MI, et al. Adequate lymph node assessment for extrahepatic bile duct adenocarcinoma. Ann Surg 2010;251:675-81.
39. Li T, Qin LX, Zhou J, Sun HC, Qiu SJ, Ye QH, et al. Staging, prognostic factors and adjuvant therapy of intrahepatic cholangiocarcinoma after curative resection. Liver Int 2014;34:953-60.
40. Lee GW, Kang JH, Kim HG, Lee JS, Jang JS. Combination chemotherapy with gemcitabine and cisplatin as first-line treatment for immunohistochemically proven cholangiocarcinoma. Am J Clin Oncol 2006;29:127-31.
41. Patel T, Singh P. Cholangiocarcinoma: emerging approaches to a challenging cancer. Curr Opin Gastroenterol 2007;23:317-23.
42. Kubicka S, Rudolph KL, Tietze MK, Lorenz M, Manns M. Phase II study of systemic gemcitabine chemotherapy for advanced unresectable hepatobiliary carcinomas. Hepatogastroenterology 2001;48:783-9.
43. Knox JJ, Hedley D, Oza A, Feld R, Siu LL, Chen E, et al. Combining gemcitabine and capecitabine in patients with advanced biliary cancer: a phase II trial. J Clin Oncol 2005;23:2332-8.
44. Yamanaka K, Hatano E, Kanai M, Tanaka S, Yamamoto K, Narita M, et al. A single-center analysis of the survival benefits of adjuvant gemcitabine chemotherapy for biliary tract cancer. Int J Clin Oncol 2014;19:485-9.
45. Liu RQ, Shen SJ, Hu XF, Liu J, Chen LJ, Li XY. Prognosis of the intrahepatic cholangiocarcinoma after resection: hepatitis B virus infection and adjuvant chemotherapy are favorable prognosis factors. Cancer Cell Int 2013;13:99.