

CLINICAL PRACTICE

Caren G. Solomon, M.D., M.P.H., *Editor*

Hemorrhoids

Danny Jacobs, M.D., M.P.H.

This Journal feature begins with a case vignette highlighting a common clinical problem. Evidence supporting various strategies is then presented, followed by a review of formal guidelines, when they exist. The article ends with the author's clinical recommendations.

An otherwise healthy 50-year-old woman presents with painless rectal bleeding; she occasionally sees small amounts of red blood on the toilet paper immediately after defecation and in the toilet water. She also has constipation and intermittent perianal itching with a sense of swelling and aching discomfort around the anal orifice. How should her case be evaluated and managed?

THE CLINICAL PROBLEM

From the Office of the Provost, University of Texas Medical Branch at Galveston, Galveston. For reprint requests, contact Dr. Jacobs at UTMB at Galveston, 301 University Blvd., Galveston, TX 77555-0133, or at djacobs@utmb.edu.

N Engl J Med 2014;371:944-51.
DOI: 10.1056/NEJMcp1204188

Copyright © 2014 Massachusetts Medical Society.



An audio version
of this article is
available at
NEJM.org

Symptoms related to hemorrhoids are very common in Western and other industrialized societies. Although published estimates of prevalence vary widely, millions of people in the United States are affected yearly¹⁻³; however, the number of patient encounters for this disease appears to be decreasing. Among gastrointestinal disorders, hemorrhoids are diagnosed in outpatients as frequently as diverticular disease and only less frequently than gastroesophageal reflux disease, abdominal-wall herniation, and functional intestinal disorders.⁴ The most common complications of hemorrhoids are heavy bleeding, chronic unremitting prolapse of mucosal tissue, strangulation, ulceration, and thrombosis.

Hemorrhoids are collections of submucosal, fibrovascular, arteriovenous sinuoids that are part of the normal anorectum.⁵ The purpose of these “vascular cushions” is incompletely understood, but they appear to be important for sensing fullness and pressure and for perceiving anal contents. In addition, they may support anal closure, facilitate continence, and help protect the anal sphincter from injury during defecation.⁶ Hemorrhoidal complexes are normally collected in the left lateral, right anterolateral, and right posterolateral regions of the anal canal but may be found in other locations.

Hemorrhoids are categorized according to their origin relative to the dentate line, which is typically located about 3 to 4 cm proximal to the anal verge. The line represents the site where the squamous epithelial cells derived from the ectoderm interface with the columnar mucosa cells of endodermal origin. Besides being the basis for categorizing hemorrhoidal complexes as internal (if proximal to the dentate line), external (if distal to the dentate line), or mixed (both proximal and distal), the different embryonic origins lead to distinctly different vascular drainages, epithelialization, and innervation (Fig. 1 and 2). Tissues that are distal to the dentate line are innervated by somatic nerves and are more sensitive to pain and irritation than those that are located more proximally, which receive sympathetic or parasympathetic visceral innervation.

Why hemorrhoids become symptomatic is uncertain. In an Austrian observational study involving adults who underwent routine screening colonoscopy, approximately 39% had visibly enlarged hemorrhoidal complexes but only about half

KEY CLINICAL POINTS

HEMORRHOIDS

- Patients who present with any symptoms related to the anorectum need to be carefully evaluated to determine the cause.
- Many patients who are found to have low-grade internal hemorrhoidal disease have a response to conservative medical management, which should include attention to local hygiene and bowel regulation through adequate fiber and water intake and the avoidance of straining.
- Most patients who do not have a response to medical management can be offered an in-office procedure, most commonly rubber-band ligation. This procedure, in concert with bowel regulation, can be highly effective. Excisional therapies are more appropriate for patients in whom rubber-band ligation should not be performed or has failed and for those with grade IV disease or complications.
- Besides traditional excisional hemorrhoidectomy with the use of scissors or scalpels, methods for excising internal hemorrhoidal tissue include cautery, bipolar diathermy, ultrasonography, other energy-based devices, and staple fixation.

of the participants with anatomical abnormalities were symptomatic.⁷ Potential causes of symptoms range from weakening of supportive tissues with prolapse of the cushions to abnormal dilatation of arteriovenous anastomoses and hemorrhoidal venous complexes.^{8,9} With the onset of slippage, venous return may be further compromised, leading to additional swelling and cyclical tissue damage. Patients with symptomatic hemorrhoids may have elevated anal resting pressures and increased tone, although the meaning of this finding is uncertain.¹⁰

The risk of symptomatic disease is increased among persons with increased venous pressure and altered venous drainage (owing to cirrhosis with ascites, pregnancy, frequent straining, or prolonged standing or squatting), abnormal bowel function (diarrhea or constipation), collagen vascular abnormalities, clinically significant pelvic-floor dysfunction, or a low intake of dietary fiber and among those who are obese or sedentary.¹¹⁻¹³ Although it has been suggested that ingestion of spicy foods exacerbates hemorrhoid symptoms, a short-term, randomized trial showed no worsening of symptoms in persons with hemorrhoids who ingested red hot chili pepper.¹⁴

Patients who present for diagnosis and treatment typically report hematochezia (approximately 60%), itching (approximately 55%), perianal discomfort (approximately 20%), soiling (approximately 10%), or some combination of these symptoms. The rectal bleeding typically occurs with or immediately after defecation. Blood may be noticed on toilet paper, in toilet water, or, occasionally, staining the underwear.⁷ Patients should be queried about their fiber and fluid intake, bowel patterns (including stool frequency), bathroom habits (e.g., reading while seated on the toilet), the need for digital manipulation of prolapsed tissue, and whether there is a history of soiling or incontinence.

Other disease processes must be considered. Substantial pain is rare in patients with uncomplicated internal or external hemorrhoids. The presence of severe pain raises the possibility of other conditions, including anal fissure, perirectal or perivaginal infection, abscess, and other inflammatory processes, although severe pain may occur with complications of hemorrhoids (e.g., prolapse with incarceration and ischemia or thrombosis). Bleeding, irritation, or pain may also occur in patients with perianal dermatitis, colorectal cancer, inflammatory bowel disease, diverticular disease, angiodysplasia, anal warts, anal polyps, or rectal ulceration.⁸

Careful examination of the anus and the surrounding pelvic regions is necessary for accurate diagnosis. The prone jackknife position (in which

STRATEGIES AND EVIDENCE**EVALUATION AND DIAGNOSIS**

The clinical manifestations of symptomatic hemorrhoids vary with the extent of the disease pro-

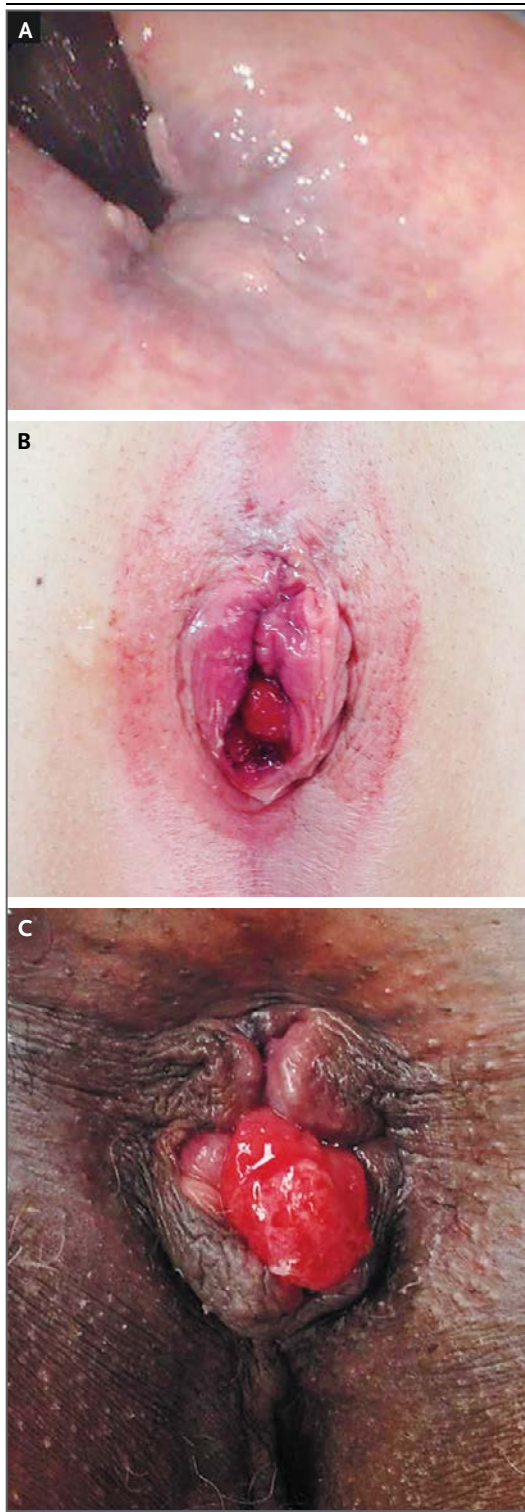


Figure 1. Hemorrhoidal Disease.

Panel A shows a sigmoidoscopic retroflexed view of grade 1 hemorrhoids; the flexible sigmoidoscope is visible in the upper left. Panel B shows grade II to III hemorrhoids with a small external component. Panel C shows grade IV internal hemorrhoids with external components. Photographs courtesy of Dr. Aakash Gajjar, Department of Surgery, University of Texas Medical Branch at Galveston.

the lateral decubitus position may provide adequate visualization for patients who have physical limitations. Examination in the lithotomy position may also be necessary. Inspection may show an anal fissure in patients who report severe pain and bleeding during defecation. A digital rectal examination should be performed if possible.

Many patients with symptomatic hemorrhoids have reducible venous congestion that distorts the normal anorectal architecture. Those with more advanced disease may have friability of the skin overlying the venous complexes, evidence of soiling or seepage, and irritation of surrounding tissues. Any abnormalities discovered in the absence of hemorrhoidal venous dilatation should raise concern about other disease processes. Full-thickness protrusion of rectal tissue with eversion and evidence of concentric mucosal folds is characteristic of rectal prolapse; diagnosis of this disorder may be facilitated by asking the patient to perform a Valsalva maneuver while seated.

All abnormalities should be described according to their location relative to the dentate line — anterior or posterior, left or right, and proximity to normal anatomical structures — rather than relative to their position on a clock face. Anoscopy can identify more than 99% of anorectal diseases and should be performed in any patient suspected of having hemorrhoids.¹⁵

The standard grading system for hemorrhoids should be used (Fig. 2).^{16,17} However, this system does not incorporate other findings that may influence clinical decision making, such as size, presence or absence of discomfort that substantially impairs activities of daily living, or severity of bleeding. Laboratory testing is not necessary for patients with uncomplicated disease.

the patient lies on the stomach, facing downward, with the knees bent at a 90° angle) allows the anorectum to be examined efficiently, although

IMAGING AND ENDOSCOPY

Flexible endoscopy is not as successful as anoscopy for examining the anorectum.¹⁵ Rigid proc-

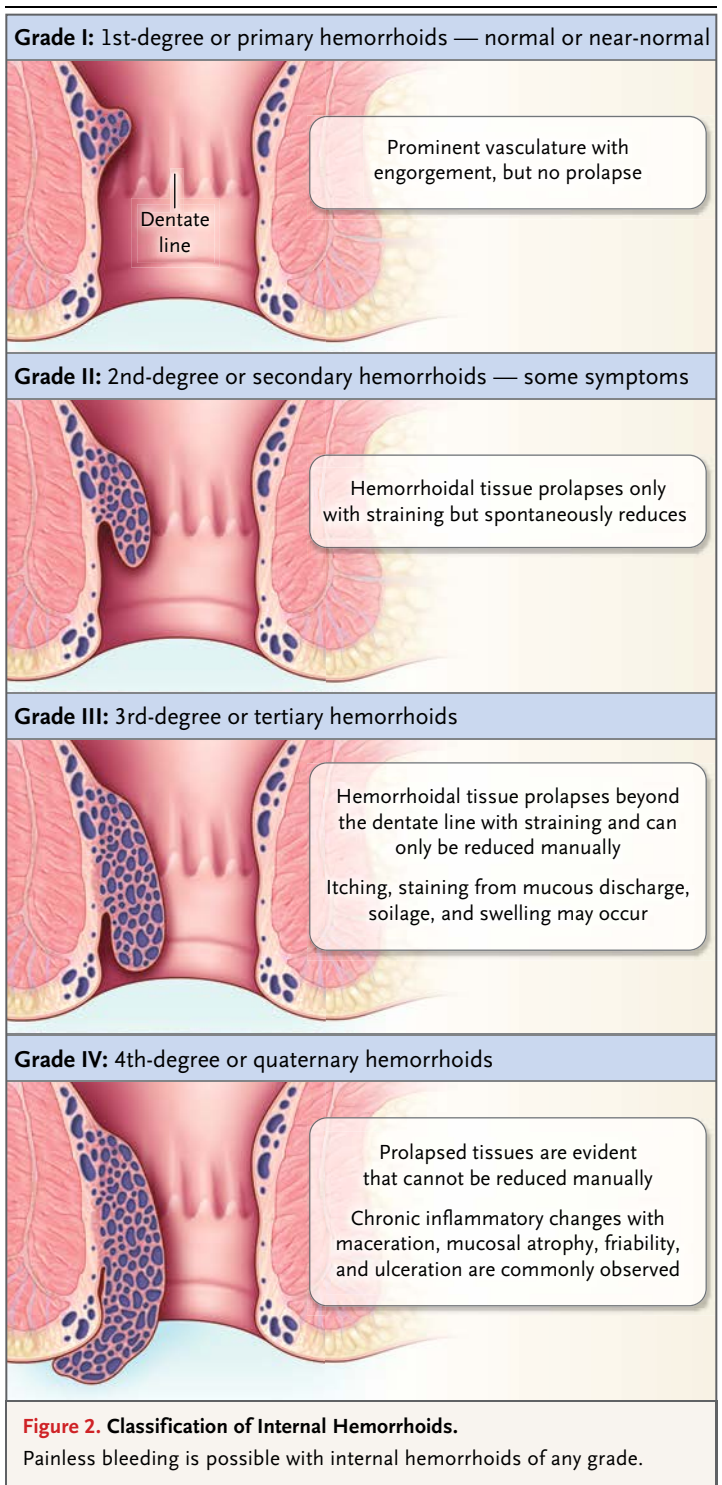
toscopy, though used less commonly now than previously, also allows adequate visualization of structures near the dentate line.

The decision to perform a more extensive colorectal evaluation should be informed by the patient's age, presenting signs and symptoms and their duration, and the nature of bleeding. Evaluation of the entire colon is indicated for patients with any of the following: anemia; bleeding that is not typical of hemorrhoids; a change in bowel patterns; a personal history of rectal or colon polyps; a family history of inflammatory bowel disease, colorectal cancer, or other hereditary colorectal diseases in a first-degree relative; or other suspected pathologic pelvic changes that could contribute to the patient's symptoms. Although sigmoidoscopy may be reasonable as an initial strategy in low-risk patients with hematochezia, double-contrast barium enema or colonoscopy is indicated in patients in whom the presentation or family history raises concern about proximal disease; colonoscopy is preferred by many clinicians.^{18,19}

For symptomatic patients younger than 50 years of age who have no risk factors for colonic disease and no evidence of other anorectal abnormalities and in whom examination confirms the presence of uncomplicated disease, hemorrhoid treatment can be administered in lieu of endoscopy or imaging studies. Persistent bleeding or other symptoms after successful local treatment of hemorrhoids is an indication for further evaluation.

MEDICAL THERAPY

All patients should be encouraged to ingest a sufficient amount of insoluble fiber (typically 25 to 35 g per day) and sufficient water to avoid constipation and straining and to limit the time spent on the toilet. A meta-analysis of controlled trials showed that fiber supplementation was associated with significant reductions in the risk of persistent symptoms and the risk of rectal bleeding, although the effects of fiber supplementation on mucosal prolapse, pain, and itching were not significant.²⁰ Clinical experience indicates that use of topical glucocorticoids, vasoconstrictors (e.g., phenylephrine-based creams or suppositories), or analgesics may provide temporary relief of some symptoms, but data from randomized trials on long-term efficacy and side effects are lacking.



Conservative approaches are recommended initially for patients with low-grade disease. Such approaches are also preferred for most patients who are pregnant, debilitated, or immunocom-

promised; patients with coagulation disorders; and patients with Crohn's disease or conditions that confer a predisposition to poor healing.

OFFICE-BASED THERAPIES AND OTHER PROCEDURES

Several options are available for patients with grade I to III disease who do not have a response to conservative medical management. The primary goals of office-based procedures, which are less costly than excisional therapies, are to decrease the amount of redundant tissue, reduce vascularity, and affix the hemorrhoidal cushions to the rectal wall.⁵ Before such procedures are performed, it is important to inform patients about any external components that will not be addressed by the procedure — for example, residual skin or skin tags that will not be excised or anal contouring that will not be restored.²¹

Rubber-Band Ligation, Sclerotherapy, and Infrared Coagulation

Rubber-band ligation involves identifying a hemorrhoidal complex, using forceps or suction to elevate the cushions, and placing one or more rubber bands around the base of each cushion while taking care to avoid impinging any muscle tissue (Fig. 3). The farther away the bands are from the dentate line, the lower the risk of severe pain.^{22,23} Ligation of the complex ultimately necroses the trapped connective tissue, and the scar is affixed to the rectal wall. No bowel preparation, other than simple enemas, is recommended, and the procedure is most often performed without sedation. Narcotic analgesics are not often required afterward, but patients who have more than two sites banded in any given session are more likely to have prolonged discomfort. If multiple sessions are required, there is typically an interval of at least 6 weeks between sessions to allow sufficient healing to occur.

Rubber-band ligation is appropriate for patients with grade I or II disease and some otherwise healthy patients with grade III disease who are amenable to in-office treatment and whose disease is amenable to less invasive intervention. Complication rates range from 3 to 8%,^{19,24,25} with complications including pain, urinary retention, delayed hemorrhage, hemorrhoidal thrombosis distal to the band, and localized infection. Systemic infection is a rare but serious complication that should be considered in any patient in whom fever develops.

Sclerotherapy involves submucosal injections, which can be repeated over time. The injections cause local thrombosis and fibrosis, reducing vascularity. Sclerotherapy is most effective for grade I or II disease. Postprocedural bleeding is uncommon because there is no eschar creation; thus, this procedure should be considered for patients who have an elevated bleeding risk, such as those receiving anticoagulants. The major complications are most often iatrogenic, owing to misplaced injections.

A meta-analysis of 18 randomized trials comparing various treatment methods for grade I to III hemorrhoids concluded that rubber-band ligation was more effective than sclerotherapy and that patients who underwent ligation were less likely to need subsequent therapy. Rubber-band ligation was less effective than hemorrhoidectomy (see below) but had fewer complications and caused less pain.²⁶ It therefore is considered appropriate as first-line therapy. The reported rate of long-term success of rubber-band ligation (with long-term defined as at least 6 months) is approximately 90% among patients with hemorrhoidal disease of less than grade IV, including the 20% of patients who require repeat procedures.²⁷ Sclerotherapy induces long-term remission in only a third of patients.

Infrared light applied to a site that is immediately proximal to the hemorrhoidal complex induces coagulation necrosis and, ultimately, scarring in patients with low-grade disease. Case studies and randomized trials suggest that the recurrence rate is significantly higher with infrared coagulation than with rubber-band ligation, but the former has fewer complications and causes less discomfort immediately after the procedure.^{2,26-28}

Thrombectomy of External Hemorrhoid

External hemorrhoid thrombosis is often observed in patients with grade III or IV disease. Patients with severe pain attributable to a clot who present within 72 hours after the onset of pain may benefit from incision and evacuation of the clot or excision of the entire hemorrhoidal complex, performed while the patient is under local anesthesia.²⁹ Excision is not recommended when patients present more than 72 hours after the onset of pain, because the discomfort associated with thrombosis usually resolves without intervention after 7 to 10 days.

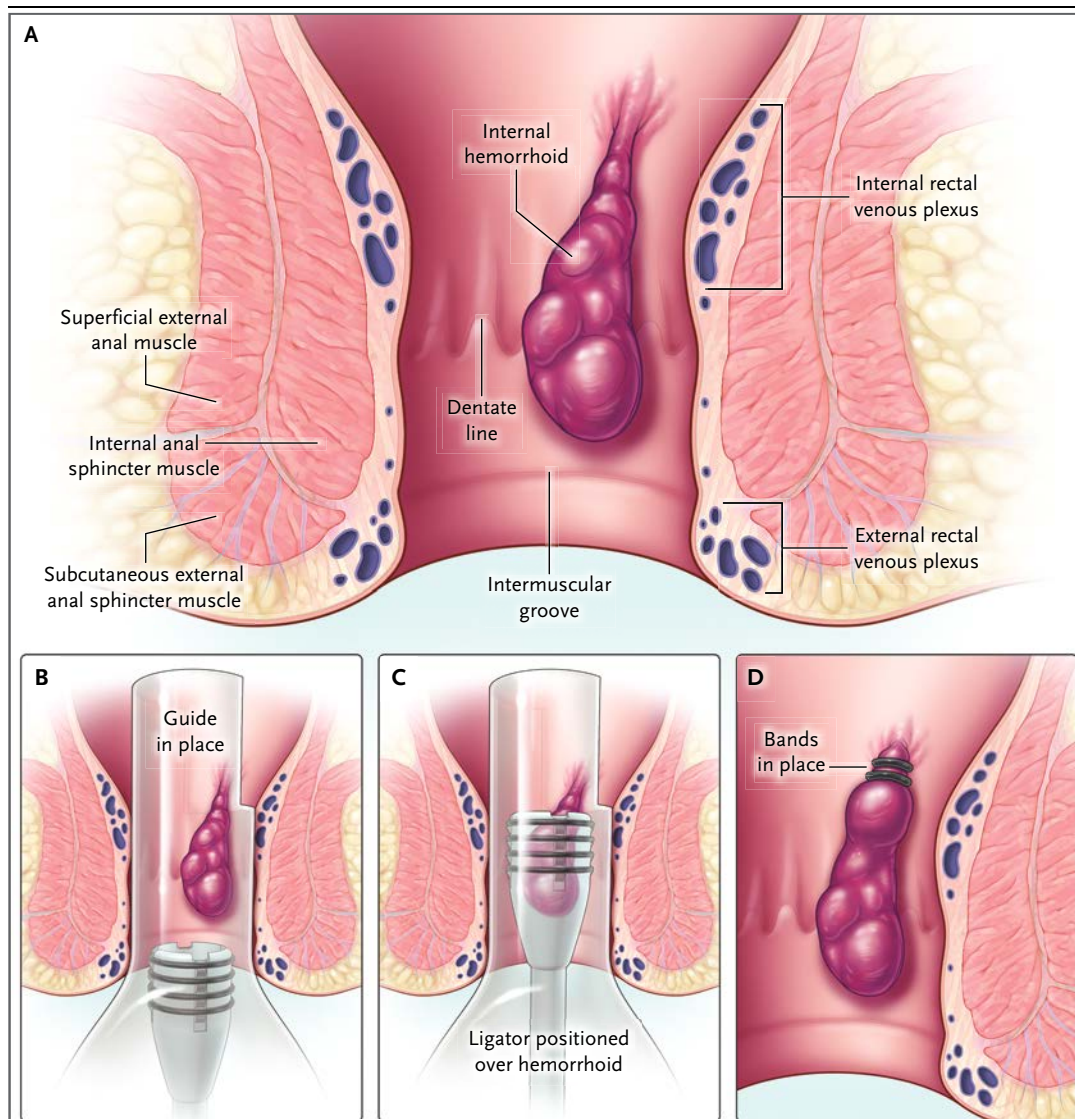


Figure 3. Rubber-Band Ligation.

When an internal hemorrhoid is present in the anorectal canal (Panel A), an anoscope may be used as a guide to identify the hemorrhoidal complex and isolate its base (Panel B). With the lighted guide in place, a ligating device (ligator) is positioned over the base of the hemorrhoid, and the bands are released (Panel C). After the procedure is completed, the constricting bands remain in place until they eventually fall off (typically because the tissue distal to the constricting bands sloughs) (Panel D).

Hemorrhoidectomy

Excisional therapies are most appropriate for patients who have grade IV disease, complications, or clinically significant internal and external disease or in whom nonoperative treatment has failed.^{8,18,19} Hemorrhoidectomy, in which the hemorrhoidal complexes and associated connective tissues are sharply excised and the mucosal defect is closed at least partially, is very effective

but painful.^{30,31} Excess internal hemorrhoidal tissue can also be removed by means of cautery, bipolar diathermy, ultrasonography, and other methods. Hemorrhoidectomy with energy-based devices may cause less pain postoperatively than conventional excisional hemorrhoidectomy.^{32,33}

Stapled hemorrhoidopexy, a newer technique for the treatment of patients with grade III or IV internal disease, involves the use of a circular

Table 1. Rates of Complications of Excisional Therapies.*

Therapy	Pain	Early Bleeding	Late Bleeding	Recurrence of Hemorrhoids	Poor Healing	Urinary Retention	Incontinence	Anal Stricture or Stenosis
<i>percent of patients</i>								
Conventional hemorrhoidectomy	5–76	2–31	<1–16	0–5	0–10	<1–12	2–15	0–5
Stapled hemorrhoidectomy	<1–40	0–7	2–12	4–11	1–6	2–14	0–11	0–5
Hemorrhoidectomy with use of energy device	5–38	0–4	<1–6	0–2	0–5	2–15	0–27	0–3

* Data, reported by De la Garza and Counihan,³⁶ are from randomized, controlled trials or meta-analyses. The duration of follow-up varied but was generally at least 6 months. Pain was defined as a requirement for ongoing analgesic medication 5 days after the procedure. Early bleeding was defined as bleeding that occurred 48 hours or less after the procedure, and late bleeding as bleeding that occurred more than 48 hours after the procedure.

stapler to resect rectal mucosal tissue, interrupt arterial and venous flow, and simultaneously affix the remaining tissue in situ above the dentate line. This procedure does not specifically address any external disease manifestations. Rare but severe complications such as pelvic sepsis, rectal urgency, rectovaginal fistulization, and rectal stricturing have been described.^{34,35} A review of randomized trials assessing outcomes 6 months or more after stapled hemorrhoidopexy performed by skilled surgeons showed a significantly lower recurrence rate and lower rate of hemorrhoidal prolapse after hemorrhoidectomy as compared with the rates with conventional hemorrhoidectomy, but rates of bleeding, pain, or itching did not differ significantly between the two procedures (Table 1).³⁶

AREAS OF UNCERTAINTY

Bioflavonoids, which possess strong antioxidant activity in vitro and may decrease inflammation, are administered orally to treat hemorrhoidal symptoms in some countries, although they have not been approved for this use in the United States. A meta-analysis of randomized trials suggests that treatment with these agents could reduce symptoms and the risk of recurrence, but the quality of the trials analyzed was considered to be poor.³⁷ More study is needed regarding the efficacy of Doppler-guided ligation of hemorrhoidal arteries as a nonexcisional treatment for patients with prolapsing hemorrhoids. Further data are also needed to guide periprocedural care of patients taking anticoagulant medications.

GUIDELINES

The Standards Practice Task Force of the American Society of Colon and Rectal Surgeons,³⁸ the Italian Society of Colorectal Surgery,³⁹ and the Clinical Practice Committee of the American Gastroenterological Association¹⁸ have published guidelines or position statements on the treatment of hemorrhoids. The recommendations in this review are consistent with these statements.

CONCLUSIONS AND RECOMMENDATIONS

The patient described in the vignette has symptoms suggestive of hemorrhoids. Examination would be expected to reveal excess hemorrhoidal tissue originating proximal to the dentate line and consistent with grade I or II disease. Given this patient's age, colonoscopy is warranted if it has not been performed. Initially, attention to bowel regulation and local hygiene is an appropriate approach. If medical management is ineffective after 6 to 8 weeks, subsequent treatment should be guided by the treating clinician's expertise and the patient's preferences, but in-office rubber-band ligation would be a reasonable next step. Excisional therapies are generally reserved for patients in whom rubber-band ligation fails and for those with grade IV disease or complications.

No potential conflict of interest relevant to this article was reported.

Disclosure forms provided by the author are available with the full text of this article at NEJM.org.

REFERENCES

- Johanson JF, Sonnenberg A. The prevalence of hemorrhoids and chronic constipation: an epidemiologic study. *Gastroenterology* 1990;98:380-6.
- Ohning GV, Machicado GA, Jensen DM. Definitive therapy for internal hemorrhoids — new opportunities and options. *Rev Gastroenterol Disord* 2009;9:16-26.
- Baker H. Hemorrhoids. In: Longe JL, ed. *Gale encyclopedia of medicine*. 3rd ed. Detroit: Gale, 2006:1766-9.
- Everhart JE, ed. *The burden of digestive diseases in the United States*. Bethesda, MD: National Institute of Diabetes and Digestive and Kidney Diseases, Department of Health and Human Services, 2008 (<http://www.niddk.nih.gov/about-niddk/strategic-plans-reports/Pages/burden-digestive-diseases-in-united-states-report.aspx>).
- Singer M. Hemorrhoids. In: Beck DE, Robert PL, Saclarides TJ, et al., eds. *The ASCRS textbook of colon and rectal surgery*. 2nd ed. New York: Springer, 2011: 175-202.
- Schubert MC, Sridhar S, Schade RR, Wexner SD. What every gastroenterologist needs to know about common anorectal disorders. *World J Gastroenterol* 2009;15: 3201-9.
- Riss S, Weiser FA, Schwameis K, et al. The prevalence of hemorrhoids in adults. *Int J Colorectal Dis* 2012;27:215-20.
- Ganz RA. The evaluation and treatment of hemorrhoids: a guide for the gastroenterologist. *Clin Gastroenterol Hepatol* 2013;11:593-603.
- Kann BR, Whitlow CB. Hemorrhoids: diagnosis and management. *Tech Gastrointest Endosc* 2004;6:6-11.
- Hancock BD. Internal sphincter and the nature of haemorrhoids. *Gut* 1977;18: 651-5.
- Milsom JW. Hemorrhoidal disease. In: Beck DE, Wexner SD, eds. *Fundamentals of anorectal surgery*. New York: McGraw-Hill, 1992:192-214.
- Haas PA, Fox TA Jr, Haas GP. The pathogenesis of hemorrhoids. *Dis Colon Rectum* 1984;27:442-50.
- Altomare DF, Giuratrabocchetta S. Conservative and surgical treatment of haemorrhoids. *Nat Rev Gastroenterol Hepatol* 2013;10:513-21.
- Altomare DF, Rinaldi M, La Torre F, et al. Red hot chili pepper and hemorrhoids: the explosion of a myth: results of a prospective, randomized, placebo-controlled, crossover trial. *Dis Colon Rectum* 2006;49:1018-23.
- Kelly SM, Sanowski RA, Foutch PG, Bellapravalu S, Haynes WC. A prospective comparison of anoscopy and fiberendoscopy in detecting anal lesions. *J Clin Gastroenterol* 1986;8:658-60.
- Cataldo P, Ellis CN, Gregorcyk S, et al. Practice parameters for the management of hemorrhoids (revised). *Dis Colon Rectum* 2005;48:189-94.
- Haas PA, Haas GP, Schmaltz S, Fox TA Jr. The prevalence of hemorrhoids. *Dis Colon Rectum* 1983;26:435-9.
- Clinical Practice Committee, American Gastroenterological Association. American Gastroenterological Association medical position statement: diagnosis and treatment of hemorrhoids. *Gastroenterology* 2004;126:1461-2.
- Bleday R, Breen E. Treatment of hemorrhoids. UpToDate, 2012 (<http://www.uptodate.com/contents/treatment-of-hemorrhoids>).
- Alonso-Coello P, Mills E, Heels-Ansell D, et al. Fiber for the treatment of hemorrhoids complications: a systematic review and meta-analysis. *Am J Gastroenterol* 2006;101:181-8.
- Hackford AW, Lamb MN, Miller PE. Elective surgery for hemorrhoidal complaints: the decision to operate. *Semin Colon Rectal Surg* 2013;24:1-85.
- Madoff RD, Fleshman JW. American Gastroenterological Association technical review on the diagnosis and treatment of hemorrhoids. *Gastroenterology* 2004;126:1463-73.
- Cleator IGM, Cleator MM. Banding hemorrhoids using the O'Regan disposable bander. *US Gastroenterol Rev* 2005;5: 69-73.
- El Nakeeb AM, Fikry AA, Omar WH, et al. Rubber band ligation for 750 cases of symptomatic hemorrhoids out of 2200 cases. *World J Gastroenterol* 2008;14: 6525-30.
- Iyer VS, Shrier I, Gordon PH. Long-term outcome of rubber band ligation for symptomatic primary and recurrent internal hemorrhoids. *Dis Colon Rectum* 2004;47:1364-70.
- MacRae HM, McLeod RS. Comparison of hemorrhoidal treatments: a meta-analysis. *Can J Surg* 1997;40:14-7.
- Marques CF, Nahas SC, Nahas CS, Sobrado CW Jr, Habr-Gama A, Kiss DR. Early results of the treatment of internal hemorrhoid disease by infrared coagulation and elastic banding: a prospective randomized cross-over trial. *Tech Coloproctol* 2006;10:312-7. [Erratum, *Tech Coloproctol* 2009;13:103.]
- Poen AC, Felt-Bersma RJ, Cuesta MA, Devillé W, Meuwissen SG. A randomized controlled trial of rubber band ligation versus infra-red coagulation in the treatment of internal haemorrhoids. *Eur J Gastroenterol Hepatol* 2000;12:535-9.
- Greenspon J, Williams SB, Young HA, Orkin BA. Thrombosed external hemorrhoids: outcome after conservative or surgical management. *Dis Colon Rectum* 2004;47:1493-8.
- Milone M, Maietta P, Leongito M, Pesce G, Salvatore G, Milone F. Ferguson hemorrhoidectomy: is still the gold standard treatment? *Updates Surg* 2012;64: 191-4.
- Russell MM, Ko CY. Management of hemorrhoids: mainstay of treatment remains diet modification and office-based procedures. Rockville, MD: Agency for Healthcare Research and Quality, July 16, 2012 (<http://www.guideline.gov/expert/expert-commentary.aspx?id=37828>).
- Kwok SY, Chung CC, Tsui KK, Li MK. A double-blind, randomized trial comparing Ligasure and Harmonic Scalpel hemorrhoidectomy. *Dis Colon Rectum* 2005;48:344-8.
- Chung CC, Ha JP, Tai YP, Tsang WW, Li MK. Double-blind, randomized trial comparing Harmonic Scalpel hemorrhoidectomy, bipolar scissors hemorrhoidectomy, and scissors excision: ligation technique. *Dis Colon Rectum* 2002; 45:789-94.
- Jayaraman S, Colquhoun PH, Malthaner RA. Stapled hemorrhoidopexy is associated with a higher long-term recurrence rate of internal hemorrhoids compared with conventional excisional hemorrhoid surgery. *Dis Colon Rectum* 2007;50:1297-305.
- Tjandra JJ, Chan MK. Systematic review on the procedure for prolapse and hemorrhoids (stapled hemorrhoidopexy). *Dis Colon Rectum* 2007;50:878-92.
- De la Garza M, Counihan TC. Complications of hemorrhoid surgery. *Semin Colon Rectal Surg* 2013;24:96-102.
- Alonso-Coello P, Zhou Q, Martinez-Zapata MJ, et al. Meta-analysis of flavonoids for the treatment of haemorrhoids. *Br J Surg* 2006;93:909-20.
- Rivadeneira DE, Steele SR, Ternent C, Chalasani S, Buie WD, Rafferty JL. Practice parameters for the management of hemorrhoids (revised 2010). *Dis Colon Rectum* 2011;54:1059-64.
- Altomare DF, Roveran A, Pecorella G, Gaj F, Stortini E. The treatment of hemorrhoids: guidelines of the Italian Society of Colorectal Surgery. *Tech Coloproctol* 2006;10:181-6.

Copyright © 2014 Massachusetts Medical Society.