Short Esophagus

Nicholas R. Kunio, MD[a], James P. Dolan, MD[b], John G. Hunter, MD[b,*]

KEYWORDS

• Esophagus • Short esophagus • Gastroesophageal reflux disease • Hiatal hernia

KEY POINTS

- In the presence of long-standing and severe gastroesophageal reflux disease, patients can develop various complications, including a shortened esophagus.
- Standard preoperative testing in these patients should include endoscopy, esophagography, and manometry, whereas the objective diagnosis of a short esophagus must be made intraoperatively following adequate mediastinal mobilization.
- If left untreated, it is a contributing factor to the high recurrence rate following fundoplications or repair of large hiatal hernias.
- A laparoscopic Collis gastroplasty combined with an antireflux procedure offers safe and effective therapy.

INTRODUCTION

Hiatal hernias, paraesophageal hernias, and gastroesophageal reflux disease (GERD) are common problems.[1–4] Complications related to these disorders can occur in up to 40% of patients.[5] One of the most controversial complications is the acquired short esophagus. Although numerous studies have been published describing the short esophagus and its pathophysiology, diagnosis, and treatment,[6–10] various reputable investigators have challenged its existence.[11–14] Consequently, this dichotomy contributes to the confusion underlying this entity. This article considers the history, pathophysiology, diagnosis, and current treatment options for the shortened esophagus.

HISTORY

Some investigators have credited Dietlen and Knierim[15] with the first mention of a short esophagus in their description of a pregnant patient whose stomach was found to be intrathoracic on radiograph. However, others have attributed this description to

[a] Division of General and Vascular Surgery, Advocate Medical Group, 745 Fletcher Dr, Suite 302, Elgin, IL 60123, USA; [b] Division of Gastrointestinal and General Surgery, Digestive Health Center, Oregon Health & Science University, 3181 SW Sam Jackson Park Rd, L223A, Portland, OR 97239, USA
* Corresponding author.
E-mail address: hunterj@ohsu.edu

Surg Clin N Am 95 (2015) 641–652
http://dx.doi.org/10.1016/j.suc.2015.02.015 **surgical.theclinics.com**
0039-6109/15/$ – see front matter © 2015 Elsevier Inc. All rights reserved.

Akerlund[16] or Findlay.[17,18] A shortened esophagus shown on esophagram was first reported by Fineman and Conner[19] in 1924,[18] whereas Woodburn Morison[20] provided the earliest endoscopic description in 1930.[18]

The grave operative challenges presented by a shortened esophagus was first shown in Plenk's description of a case of perforation and peritonitis in which the stomach could not be replaced into the abdomen, leading to a fatal situation.[18,21,22] This portrayal is consistent with the modern understanding of shortened esophagus in which esophageal length is insufficient to allow the esophagogastric junction to rest below the diaphragm, as first described by Barrett in 1950.[18,23,24] From this, the theory that chronic reflux disease was the underlying cause for acquired short esophagus was first proposed by Lortat-Jacob[25] a few years later.

INCIDENCE

Depending on the study, the incidence of shortened esophagus can vary widely. It has been reported to be as high as 60%[26] and as low as 0% in older open[11] and more recent laparoscopic series.[27] If the intraoperative requirement for extensive mediastinal dissection or the performance of a Collis gastroplasty is used to define the presence of shortened esophagus then the incidence in the open literature is between 8% and 10%.[28,29] Using the same definition, a wider range (7%–19%) has been documented in various laparoscopic series.[30–33] If the need for a Collis gastroplasty is used as the most restrictive definition, then retrospective review of the literature indicates that between 1% and 5% of patients undergoing GERD-related surgery meet criteria.[30,34–36]

PATHOPHYSIOLOGY

The most common entity associated with acquired short esophagus is chronic GERD, which results in a persistent inflammatory response.[7] In the setting of a dysfunctional lower esophageal sphincter the esophageal mucosa is exposed to either acidic or alkaline reflux and the normal esophageal squamous epithelium provides an inadequate barrier to the damaging effects of refluxed gastric juices. Animal models,[37,38] as well as in-vivo human[10] studies, have shown that refluxed gastric fluid leads to deeper penetration of hydrogen ions into the wall of the esophagus with localized cellular damage. The resulting inflammation causes tissue edema, migration of inflammatory cells into the damaged tissue, attempted healing, and ultimately tissue fibrosis. With repeated exposure over a period of time, the inflammatory process can extend transmurally. Transmural inflammation then leads to longitudinal contracture of the transmural scar and the clinical manifestation of esophageal shortening.[7]

PREOPERATIVE ASSESSMENT

Typical studies used in the preoperative evaluation of patients with GERD include dynamic esophagram, esophagogastroduodenoscopy, and esophageal manometry. Many prior attempts at identifying preoperative indicators of short esophagus have identified factors with low specificity.[31,39–41] Some investigators contend that evidence of a nonreducing type I hiatal hernia greater than 5 cm in length or a type III hiatal hernia on barium esophagram is predictive of short esophagus being present at surgery.[42] However, when a retrospective, blinded review of patients who had undergone Collis gastroplasty was performed, barium esophagram had a positive predictive value of only 50%.[7]

Other studies have attempted to improve on this finding. Awad and colleagues[31] performed a thorough evaluation of the predictive utility of all 3 diagnostic tests (esophagography, endoscopy, and manometry) individually and in conjunction with each other. When all were used together, the specificity for short esophagus was 100% but the sensitivity was only 28%. Esophagography and manometry used together had a 75% positive predictive value but, again, a low sensitivity of 28%. Manometric measurement alone had the best individual positive predictive value, but this was only 36%. Other investigators have also examined these 3 diagnostic modalities and reported that the presence of peptic stricture was the only significantly predictive factor for the need for Collis gastroplasty at surgery. Manometric esophageal length was associated with a short esophagus if the measurement was less than the fifth percentile, but was unable to yield a minimal cutoff in defining a short esophagus because of wide variability in measurements.[39]

Recently, Yano and colleagues[43] examined the utility of the esophageal length index (ELI), defined as the ratio of endoscopic esophageal length (in centimeters) to the patient's height (in meters) in order to help adjust for the variability in individual measurements caused by differences in height. They identified an ELI cutoff of 19.5 or less as having a positive predictive value of 81% (19% false-negative rate) and a negative predictive value of 83%. This index provides the most contemporary and useful tool in anticipating the need for an esophageal lengthening procedure during operation. Current preoperative diagnostic tests can only help surgeons anticipate the potential need for a Collis gastroplasty. They have not yet replaced intraoperative assessment and esophageal measurement as a requirement to make the final decision.

INTRAOPERATIVE ASSESSMENT

In order to define a shortened esophagus, the relationship of the esophagogastric junction to the hiatus must be assessed carefully. Most commonly, a shortened esophagus is associated with the presence of a large paraesophageal hernia. Consequently, after the stomach has been reduced, the hernia sac incised and pulled into the abdomen, and the short gastric vessels divided, mediastinal esophageal dissection is performed. Intra-abdominal esophageal length should be measured after the distal 3 to 4 cm of the mediastinal esophagus has been mobilized (type I dissection).[7] If insufficient length still exists after this, an extended (type II) dissection can be performed. Various investigators have described the limits of this dissection. Johnson and colleagues[34] described up to 8 cm of mediastinal length being mobilized, whereas O'Rourke and colleagues[32] stated that up to 10 cm of mediastinal dissection can be performed. Swanstrom and Hansen[44] used the level of the carina as their upper limit and DeMeester[45] the inferior pulmonary veins. Extended dissection may be necessary and beneficial in some cases. In their series of 106 patients, Bochkarev and colleagues[46] found that, with extended mediastinal dissection, adequate intra-abdominal esophageal length could be obtained, and this obviated a Collis gastroplasty.

Any traction on the esophagogastric junction should be relieved following the completion of the dissection. This relief should include removal of the nasogastric tube or bougie, because these can provide superior displacement and lead to inaccurate measurement of intra-abdominal esophageal length. Assuming the esophagogastric junction can be easily identified, the distance between it and the hiatus is measured.[7,34] The authors prefer to use the open jaws of a laparoscopic grasper for this measurement. When fully open, these measure 2.5 cm across. The graspers can then be placed alongside the dissected intra-abdominal esophagus to determine

whether sufficient length for a fundoplication has been achieved (**Fig. 1**). If less than this distance is present after an extended mediastinal dissection, then a shortened esophagus is confirmed and a Collis-type gastroplasty is needed.

In situations in which the esophagogastric junction cannot easily be delineated, certain steps must be taken before intra-abdominal esophageal measurements are made. Conditions that can make visualization of the esophagogastric junction difficult include a large redundant hernia sac or a prominent junction fat pad that obscures the landmark. Dissection and removal of this excess tissue may be needed in order to properly identify the junction,[45,47] and this is commonly performed in our practice. When this proves insufficient for proper identification of the esophagogastric junction, endoscopic evaluation can be performed to aid with identification. By endoscopically identifying the junction and then transilluminating the esophageal wall the location can be seen laparoscopically and this can be successfully completed in almost all cases. Other investigators have also described how endoscopic measurement of the distance between the junction and the crural arch can also be used to determine whether sufficient length has been obtained.[7,40]

TREATMENT

The importance of identifying and correcting a short esophagus is underscored because the risk of fundoplication failure or crural disruption with wrap herniation is increased in cases in which a tension-free repair was not successfully performed.[48,49] This failure to treat a shortened esophagus is thought to be, in part, responsible for the 20% to 33% rate of repair failure in cases of giant paraesophageal hernias.[50–52]

The most commonly used method to obtain esophageal lengthening is the Collis gastroplasty and its current variation. Initially, this operation involved mobilization of the esophagus to the level of the aortic arch and was performed through a thoracoabdominal incision.[53] A dilator was inserted along the lesser curvature. Two clamps were then attached to the cardia parallel to the dilator and the stomach was divided, followed by oversewing the resection lines. The tubularized portion of the stomach then acted as a neoesophagus that, when combined with a standard antireflux procedure, allowed a tension-free repair.

With the advent of minimally invasive surgery as well as advances in surgical equipment, several novel adaptations of the Collis gastroplasty have evolved. Swanstrom and colleagues[30] first described their combination of a thoracoscopic and

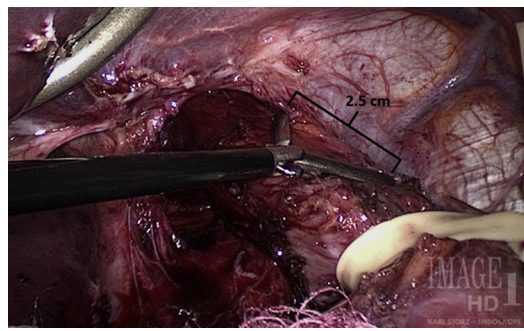

Fig. 1. Intra-abdominal esophageal length measurement using atraumatic grasper during a laparoscopic paraesophageal hernia repair. (*Courtesy of* Oregon Health & Science University, Portland, OR; with permission.)

laparoscopic gastroplasty with a Nissen fundoplication. In their approach an endoscopic linear stapler was introduced through the right chest, brought across the mediastinal pleura, and then brought trans-hiatally inserted into the abdomen. After a bougie had been inserted, the stapler was fired parallel to the lesser curvature against the left aspect of the bougie.[54] A similar technique, by means of a left-sided thoracoscopic stapler approach, was first described by Awad and colleagues[31] in 2000.[55] Taken together, the major disadvantage to these approaches was the need to enter 2 separate body cavities. In theory, this increased the risk of injury to intrathoracic structures.

The first totally laparoscopic approach to a modified Collis technique was described by Johnson and colleagues[34] in 1998. They used a laparoscopic version of the open approach initially described by Steichen.[56] With a 48-French bougie in place along the lesser curvature, a sealed transgastric window was created in the fundus using a circular stapling device. A linear stapler was then fired alongside the bougie dividing the fundus from the superior aspect of the fundal window to the angle of His, creating the neoesophagus. A floppy Nissen fundoplication was then created. After this description, an additional step, involving resection of the fundal apex, was described because of concerns for tissue ischemia.[57] This approach is technically challenging and involves a minilaparotomy in order to accommodate the circular stapler. In addition, Pierre and colleagues[58] reported a staple line leak in 3% of patients who underwent the procedure.

The fully laparoscopic approach to the Collis-type gastroplasty was made possible by the development of the articulating endoscopic linear stapler. Terry and colleagues[57] reported that this technique was first developed for a laparoscopic vertical banded gastroplasty by Champion,[59] and this remains our technique of choice. The wedge gastroplasty is performed using the same port placement as is used for standard laparoscopic fundoplication (**Fig. 2**). After completion of all dissection, a 48-French bougie is inserted alongside the lesser curvature. The assistant retracts the gastric fundus inferiorly while the surgeon maintains traction on the greater curvature just below the level of the angle of His. An articulating endoscopic linear stapler is then placed through the left subcostal port, maximally articulated and fired transversely

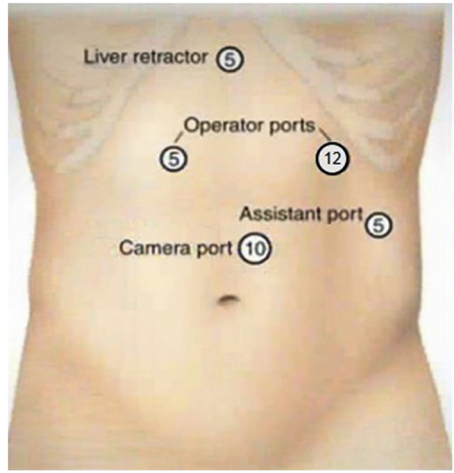

Fig. 2. Standard port placement for laparoscopic wedge Collis gastroplasty.

across the superior fundus to a point approximately 3 cm below the angle of His and abutting the bougie. While the assistant applies lateral traction on the wedge of fundus to be resected, a vertical firing of the linear stapler is then made parallel to the esophagus against the bougie, completing the wedge resection (Fig. 3). The resected portion is then removed from the stomach. A floppy fundoplication is then performed over a 56-French to 60-French bougie.

RESULTS OF OPERATIVE REPAIR

Before the advent of minimally invasive transabdominal surgery, the transthoracic Collis gastroplasty had been shown to have excellent long-term results. Symptomatic reflux control at 10 years following surgery was reported to be as high as 88%.[60,61] More recently, minimally invasive techniques have been used to perform a Collis gastroplasty from a transabdominal approach. Short-term results have been satisfactory. However, it is difficult to identify a single approach as producing superior outcomes given the paucity of long-term data.

As minimally invasive approaches to the Collis gastroplasty have evolved, an improvement in operative time has been seen. Mean operative time for the combined thoracoscopic/laparoscopic technique was 257 minutes.[54] It increased to 294 minutes with the challenging dual-stapler transabdominal approach.[34] At 184 minutes the transabdominal wedge gastroplasty showed the shortest mean operative time of all the minimally invasive techniques.[57]

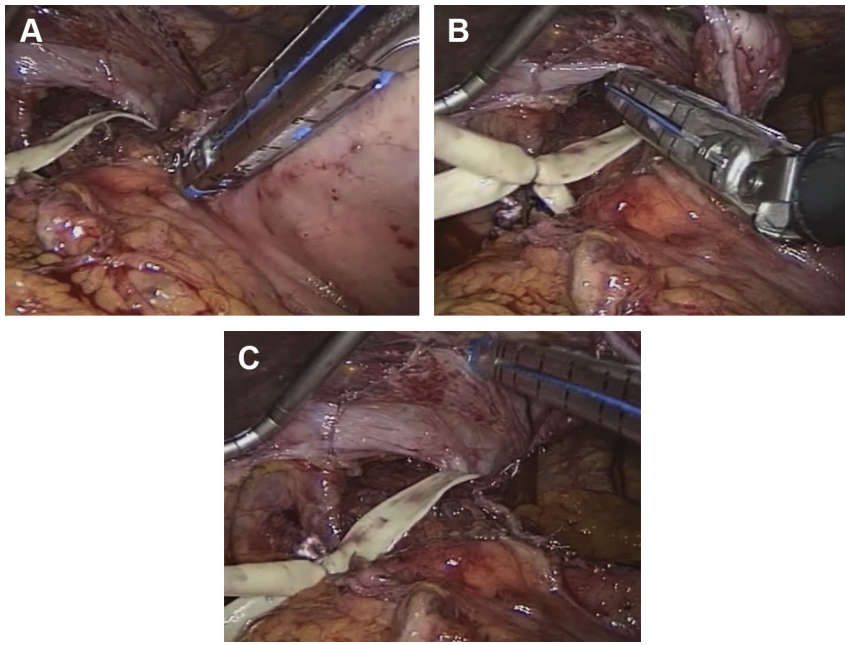

Fig. 3. Important steps in constructing a wedge Collis gastroplasty during a laparoscopic paraesophageal hernia repair. (*A*) Articulating stapler fired across fundus perpendicular to bougie. (*B*) Articulating stapler fired parallel and abutting bougie. (*C*) Completed wedge gastroplasty with creation of neoesophagus. (*Courtesy of* Oregon Health & Science University, Portland, OR; with permission.)

Perioperative morbidity following a Collis gastroplasty has been shown to occur in as few as 8% of cases,[62] but more commonly ranges between 19% and 36% (**Table 1**).[34,54,55,58,63–65] Complications commonly seen following a Collis gastroplasty included atelectasis, atrial fibrillation, ileus, pneumonia, and urinary tract infection,[34,55,62–64] whereas pneumothorax and pleural effusion were more often shown in series using a combined thoracoscopic/laparoscopic approach.[55,63] Of particular importance in Collis gastroplasty is the risk of postoperative leak. Houghton and colleagues[66] showed a similar incidence of perforation or leak when comparing patients having a Collis gastroplasty with those having a fundoplication alone, whereas Nason and colleagues[65] showed a significantly increased risk of leak (2.7% vs 0.6%) when comparing patients after Collis and standard fundoplication. Both studies showed similar overall morbidity between groups. All studies to date have shown a very low incidence of perioperative mortality, similar to that seen with standard fundoplication (see **Table 1**).

Clinical outcomes have shown consistent improvement across studies following performance of a Collis gastroplasty. The incidence of persistent or recurrent reflux symptoms following a Collis gastroplasty since the advent of minimally invasive techniques ranges between 7% and 24%. Postoperative dysphagia rates have been shown to be between 10% and 28% (see **Table 1**). Comparing standard fundoplication with Collis gastroplasty, Houghton and colleagues[66] showed a significantly increased incidence of requiring postoperative dilatation in patients after Collis gastroplasty (6% vs 2%). Overall the Collis gastroplasty has shown good patient satisfaction, ranging from 77%[63] to 93%,[58] and this is comparable with that seen in patients undergoing fundoplication alone.

As shown in **Table 1**, the incidence of postoperative hernia recurrence or wrap failure following a Collis gastroplasty and antireflux procedure can be low (0% to 18%). These reported rates are in contrast with prior studies examining the risk of hernia recurrence following laparoscopic paraesophageal hernia repair. The patients included in these studies did not undergo esophageal lengthening procedures and recurrence rates seen in those having a minimally invasive approach ranged from 32% to 42%.[67–69] It has been suggested that these high rates of recurrence can be attributed to the failure to identify a short esophagus and perform a lengthening procedure.[50–52,58] This theory is reinforced by the significant reduction in recurrence rates seen to date in series examining patients undergoing a Collis gastroplasty and antireflux procedure.

Two main concerns have been raised with regard to the Collis gastroplasty. The first is that the neoesophagus lacks motility and in theory may contribute to postoperative dysphagia. Although postoperative dysphagia rates range between 3% and 13%,[31,34,54,58,62–64] dysphagia was generally improved in comparisons between postoperative and preoperative incidence. The second concern centers on the presence of acid-secreting gastric mucosa within the neoesophagus, which can potentially contribute to ongoing esophagitis. During 24-hour pH testing, Jobe and colleagues[54] found that 7 out of 14 patients in their series of combined thoracoscopic/laparoscopic gastroplasty had abnormal findings, with a mean DeMeester score of 100. More recently, Mor and colleagues[70] compared the acid clearance time between normal patients, those following Nissen fundoplication, and those following Nissen-Collis gastroplasty. Esophageal acid clearance time was significantly greater in the Nissen-Collis group. Pathologic esophageal acid exposure was seen in 10% of patients after Nissen fundoplication and 22% of patients after Nissen-Collis gastroplasty; however, this difference was not statistically significant.

Table 1
Postoperative functional results after Collis gastroplasty

Study	Type	Approach	n	n, Follow-up	Follow-up	Antireflux Procedure	Mortality, n (%)	Morbidity, n (%)	Outcomes		
									Reflux Symptoms, n (%)	Dysphagia, n (%)	Recurrence, n (%)
Pearson et al,[26] 1987	Open	Thoracic	215	NA	1–15 y	Toupet	NA	NA	6 (3)	24 (11)	6 (3)
Stirling & Orringer,[60] 1989	Open	Thoracic	353	261	44 mo	Nissen	4 (1.1)	28 (8)	65 (25)	44 (17)	26 (10)
Swanstrom et al,[30] 1996 & Jobe et al,[54] 1998	Laparoscopic	Thoracic/ Abdominal	15	14	14 mo	Nissen or Toupet	0	3 (20)	2 (14)	2 (14)	0
Johnson et al,[34] 1998	Laparoscopic	Abdominal	9	9	12 mo	Nissen	0	2 (22)	1 (11)	1 (11)	NA
Awad et al,[31] 2001 & Awad et al,[55] 2000	Laparoscopic	Thoracic/ Abdominal	11	11	6–35 mo	Nissen or Toupet	0	4 (36)	1 (9)	0	2 (18)
Pierre et al,[58] 2002	Laparoscopic	Abdominal	112	NA	1–78 mo	Nissen	1 (0.8)	31 (28)	NA	NA	3 (3)
Garg et al,[63] 2009	Open/ Laparoscopic	Thoracic/ Abdominal	85	50	9–111 mo	Nissen or Toupet	1 (1)	26 (31)	12 (24)	14 (28)	NA
Houghton et al,[64] 2007	Open/ Laparoscopic	Abdominal	63	62	1–64 mo	Nissen or Toupet	0	12 (19)	12 (20)	6 (10)	1 (2)
Nason et al,[65] 2011	Laparoscopic	Abdominal	454	368	33 mo	Nissen, Toupet, Dor	7 (1.5)	89 (20)	NA	NA	53 (16)
Zehetner et al,[62] 2014	Laparoscopic	Abdominal	85	NA	12 mo	Nissen or Toupet	0	7 (8)	6 (7)	14 (16)	2 (2.4)

Abbreviation: NA, not available.
Data from Refs.[26,30,31,34,55,58,60,62–65]

SUMMARY

In the presence of long-standing and severe GERD, patients can develop various complications, including a shortened esophagus. Standard preoperative testing in these patients should include endoscopy, esophagography, and manometry, whereas the objective diagnosis of a short esophagus must be made intraoperatively following adequate mediastinal mobilization. Some debate still persists as to the validity of this entity but there are now significant data available to support its existence. If left untreated, it is a contributing factor to the high recurrence rate following fundoplications or repair of large hiatal hernias. A laparoscopic Collis gastroplasty combined with an antireflux procedure offers safe and effective therapy.

REFERENCES

1. Draaisma WA, Gooszen HG, Tournoij E, et al. Controversies in paraesophageal hernia repair. Surg Endosc 2005;19:1300–8.
2. Altorki NK, Yankelevitz D, Skinner DB. Massive hiatal hernias: the anatomic basis of repair. J Thorac Cardiovasc Surg 1998;115:828–35.
3. Andujar JJ, Papasavas PK, Birdas T, et al. Laparoscopic repair of large paraesophageal hernia is associated with a low incidence of recurrence and reoperation. Surg Endosc 2004;18:444–7.
4. Spechler SJ. Epidemiology and natural history of gastro-oesophageal reflux disease. Digestion 1992;51(Suppl 1):24–9.
5. Stein HJ, Barlow AP, DeMeester TR, et al. Complications of gastroesophageal reflux disease. Role of the lower esophageal sphincter, esophageal acid and acid/alkaline exposure, and duodenogastric reflux. Ann Surg 1992;216:35–43.
6. Durand L, De Antón R, Caracoche M, et al. Short esophagus: selection of patients for surgery and long-term results. Surg Endosc 2012;26:704–13.
7. Horvath K, Swanström L, Jobe B. The short esophagus: pathophysiology, incidence, presentation, and treatment in the era of laparoscopic antireflux surgery. Ann Surg 2000;232:630–40.
8. Paterson WG, Kolyn DM. Esophageal shortening induced by short-term intraluminal acid perfusion in opossum: a cause for hiatus hernia? Gastroenterology 1994;107:1736–40.
9. Paterson WG. Role of mast cell-derived mediators in acid induced shortening of the esophagus. Am J Physiol Gastrointest Liver Physiol 1998;274:385–8.
10. Gozzetti G, Pilotti V, Spangaro M, et al. Pathophysiology and natural history of acquired short esophagus. Surgery 1987;102:507–14.
11. Hill LD, Gelfand M, Bauermeister D. Simplified management of reflux esophagitis with stricture. Ann Surg 1970;172:638–51.
12. Korn O, Csendes A, Burdiles P, et al. Length of the esophagus in patients with gastroesophageal reflux disease and Barrett's esophagus compared to controls. Surgery 2003;133:358–63.
13. Madan AK, Frantzides CT, Patsavas KL. The myth of the short esophagus. Surg Endosc 2004;18:31–4.
14. Larrain A, Csendes A, Strauszer T. The short esophagus: a surgical myth? Acta Gastroenterol Latinoam 1971;3:125–33.
15. Dietlen H, Knierim G. Hernia diaphragmatica dextra. Berl klin Wchnschr 1910;1:1174–7.
16. Akerlund AI. Hernia diaphragmatica Hiatus oesophagei vom anatomischen und roentgenologischen Gesichstounkt. Acta Radiol 1926;6:3–22.

17. Findlay L, Kelly B. Congenital shortening of the oesophagus and the thoracic stomach resulting therefrom. J Laryng & Otol 1931;46:797–816.
18. Herbella FM, Patti MG, Del Grande JC. When did the esophagus start shrinking? The history of the short esophagus. Dis Esophagus 2009;22:550–8.
19. Fineman S, Conner HM. Right diaphragmatic hernia of the short esophagus type. Am J Med Sci 1924;3:672.
20. Woodburn Morison JM. Diaphragmatic hernia. Proc R Soc Med 1930;23(11): 1615–34.
21. Plenk A. Zur Kazuistik der Zwechfellhernien. Wien klin Wchnschr 1922;35: 339–41.
22. Barrett NR. Chronic peptic ulcer of the esophagus and 'oesophagitis'. Br J Surg 1950;38:175–82.
23. Large AM. The problem of short oesophagus with oesophagitis. Br J Surg 1962; 49:527–32.
24. Spechler SJ, Goyal RK. The columnar-lined esophagus, intestinal metaplasia, and Norman Barrett. Gastroenterology 1996;110:614–21.
25. Lortat-Jacob JL. L'endo-brachyesophage [Barrett's esophagus]. Ann Chir 1957; 11:1247 [in French].
26. Pearson FG, Cooper JD, Patterson GA, et al. Gastroplasty and fundoplication for complex reflux problems. Long-term results. Ann Surg 1987;206:473–81.
27. Coster DD, Bower W, Wilson VT, et al. Laparoscopic partial fundoplication vs. laparoscopic Nissen-Rossetti fundoplication: short-term results of 231 cases. Surg Endosc 1997;11:625–31.
28. Polk HC. Fundoplication for reflux esophagitis: misadventures with the operation of choice. Ann Surg 1976;183:645–52.
29. Kauer WK, Peters JH, DeMeester TR, et al. A tailored approach to antireflux surgery. J Thorac Cardiovasc Surg 1995;110:141–7.
30. Swanstrom LL, Marcus DR, Galloway GQ. Laparoscopic Collis gastroplasty is the treatment of choice for the shortened esophagus. Am J Surg 1996;171:477–81.
31. Awad ZT, Mittal SK, Roth TA, et al. Esophageal shortening during the era of laparoscopic surgery. World J Surg 2001;25:558–61.
32. O'Rourke RW, Khajanchee YS, Urbach DR, et al. Extended transmediastinal dissection: an alternative to gastroplasty for short esophagus. Arch Surg 2003; 138:735–40.
33. Mattioli S, Lugaresi M, Costantini M, et al. The short esophagus: intraoperative assessment of esophageal length. J Thorac Cardiovasc Surg 2008;136:834–41.
34. Johnson AB, Oddsdottir M, Hunter JG. Laparoscopic Collis gastroplasty and Nissen fundoplication: a new technique for the management of esophageal foreshortening. Surg Endosc 1998;12:1055–60.
35. Terry M, Smith CD, Branum GD, et al. Outcomes of laparoscopic fundoplication for gastroesophageal reflux disease and paraesophageal hernia. Surg Endosc 2001;15:691–9.
36. Richardson JD, Richardson RL. Collis-Nissen gastroplasty for shortened esophagus: longterm evaluation. Ann Surg 1998;227:735–40 [discussion: 740–2].
37. Lillemoe KD, Johnson LF, Harmon JW. Role of the components of the gastroduodenal contents in experimental acid esophagitis. Surgery 1982;92: 276–84.
38. Lillemoe KD, Johnson LF, Harmon JW. Taurodeoxycholate modulates the effects of pepsin and trypsin in experimental esophagitis. Surgery 1985;97:662–7.
39. Gastal OL, Hagen JA, Peters JH, et al. Short esophagus: analysis of predictors and clinical implications. Arch Surg 1999;134:633–6 [discussion: 637–8].

40. Mittal SK, Awad ZT, Tasset M, et al. The preoperative predictability of the short esophagus in patients with stricture or paraesophageal hernia. Surg Endosc 2000;14:464–8.
41. Yau P, Watson DI, Jamieson GG, et al. The influence of esophageal length on outcomes after laparoscopic fundoplication. J Am Coll Surg 2000;191:360–5.
42. Bremner RM, Bremner CG, Peters JH. Fundamentals of antireflux surgery. In: Peters JH, DeMeester TR, editors. Minimally invasive surgery of the foregut. 1st edition. St Louis (MO): Quality Medical Publishing; 1994. p. 119–243.
43. Yano F, Stadlhuber RJ, Tsuboi K, et al. Preoperative predictability of the short esophagus: endoscopic criteria. Surg Endosc 2009;23:1308–12.
44. Swanstrom LL, Hansen P. Laparoscopic total esophagectomy. Arch Surg 1997; 132:943–9.
45. DeMeester SR. Laparoscopic paraesophageal hernia repair: critical steps and adjunct techniques to minimize recurrence. Surg Laparosc Endosc Percutan Tech 2013;23:429–35.
46. Bochkarev V, Lee Y, Vitamvas M, et al. Short esophagus: how much length can we get? Surg Endosc 2008;22:2123–7.
47. Maziak DE, Todd TR, Pearson FG. Massive hiatus hernia: evaluation and surgical management. J Thorac Cardiovasc Surg 1998;115:53–60 [discussion: 61–2].
48. Peters JH, DeMeester TR. The lessons of failed antireflux repairs. In: Peters JH, DeMeester TR, editors. Minimally invasive therapy of the foregut. 1st edition. St Louis (MO): Quality Medical Publishing; 1994. p. 190–200.
49. Juhasz A, Sundaram A, Hoshino M, et al. Outcomes of surgical management of symptomatic large recurrent hiatus hernia. Surg Endosc 2012;26:1501–8.
50. Ellis FH Jr, Gibb SP, Heatley GJ. Reoperation after failed antireflux surgery. Review of 101 cases. Eur J Cardiothorac Surg 1996;10:225–31 [discussion: 231–2].
51. Siewert JR, Isolauri J, Feussner H. Reoperation following failed fundoplication. World J Surg 1989;13:791–6 [discussion: 796–7].
52. DePaula AL, Hashiba K, Bafutto M, et al. Laparoscopic reoperations after failed and complicated antireflux operations. Surg Endosc 1995;9:681–6.
53. Collis JL. An operation for hiatus hernia with short esophagus. Thorax 1957;12: 181–8.
54. Jobe BA, Horvath KD, Swanstrom LL. Postoperative function following laparoscopic Collis gastroplasty for shortened esophagus. Arch Surg 1998;133:867–74.
55. Awad ZT, Filipi CJ, Mittal SK, et al. Left side thoracoscopically assisted gastroplasty: a new technique for managing the shortened esophagus. Surg Endosc 2000;14:508–12.
56. Steichen FM. Abdominal approach to the Collis gastroplasty and Nissen fundoplication. Surg Gynecol Obstet 1986;162:372–4.
57. Terry ML, Vernon A, Hunter JG. Stapled-wedge Collis gastroplasty for the shortened esophagus. Am J Surg 2004;188:195–9.
58. Pierre AF, Luketich JD, Fernando HC, et al. Results of laparoscopic repair of giant paraesophageal hernias: 200 consecutive patients. Ann Thorac Surg 2002;74: 1909–15 [discussion: 1915–6].
59. Champion JK. Laparoscopic vertical banded gastroplasty with wedge resection of gastric fundus. Obes Surg 2003;13:465 [author reply: 465].
60. Stirling MC, Orringer MB. Continued assessment of the combined Collis-Nissen operation. Ann Thorac Surg 1989;47:224–30.
61. Orringer MB, Sloan H. Combined Collis-Nissen reconstruction of the esophagogastric junction. Ann Thorac Surg 1978;25:16–21.

62. Zehetner J, DeMeester S, Ayazi S, et al. Laparoscopic wedge fundectomy for Collis gastroplasty creation in patients with a foreshortened esophagus. Ann Surg 2014;00:1–4.
63. Garg N, Yano F, Filipi C, et al. Long-term symptomatic outcomes after Collis gastroplasty with fundoplication. Dis Esophagus 2009;22:532–8.
64. Houghton S, Deschamps C, Cassivi S, et al. The influence of transabdominal gastroplasty: early outcomes of hiatal hernia repair. J Gastrointest Surg 2007;11:101–6.
65. Nason K, Luketich J, Awais O, et al. Quality of life after Collis gastroplasty for short esophagus in patients with paraesophageal hernia. Ann Thorac Surg 2011;92:1854–61.
66. Houghton S, Deschamps C, Cassivi S, et al. Combined transabdominal gastroplasty and fundoplication for shortened esophagus: impact on reflux-related and overall quality of life. Ann Thorac Surg 2008;85:1947–53.
67. Hashemi M, Peters JH, DeMeester TR, et al. Laparoscopic repair of large type III hiatal hernia: objective followup reveals high recurrence rate. J Am Coll Surg 2000;190:553–60 [discussion: 560–1].
68. Khaitan L, Houston H, Sharp K, et al. Laparoscopic paraesophageal hernia repair has an acceptable recurrence rate. Am Surg 2002;68:546–51 [discussion: 551–2].
69. Jobe BA, Aye RW, Deveney CW, et al. Laparoscopic management of giant type III hiatal hernia and short esophagus. Objective follow-up at three years. J Gastrointest Surg 2002;6:181–8 [discussion: 188].
70. Mor A, Lutfi R, Torquati A. Esophageal acid-clearance physiology is altered after Nissen-Collis gastroplasty. Surg Endosc 2013;27:1334–8.