Surgical Treatment of Gastroesophageal Reflux Disease

Robert B. Yates, MD[a,*], Brant K. Oelschlager, MD[b]

KEYWORDS

• Gastroesophageal reflux disease • Laparoscopic antireflux surgery • Hiatal hernia • Fundoplication

KEY POINTS

- Gastroesophageal reflux disease is abnormal distal esophageal acid exposure that results in bothersome symptoms. It is caused by the failure of endogenous antireflux barriers, including the lower esophageal sphincter and esophageal clearance mechanisms.
- Appropriate preoperative patient evaluation increases the likelihood that gastroesophageal reflux disease–related symptoms will improve after laparoscopic antireflux surgery.
- In patients that have a clinical history suggestive of gastroesophageal reflux disease, diagnostic testing should include ambulatory pH monitoring, esophageal manometry, esophagogastroduodenoscopy, and upper gastrointestinal series.
- Correct construction of the fundoplication reduces the risk of postoperative dysphagia caused by an inappropriately tight fundoplication, posterior herniation of gastric fundus, and slipped fundoplication.
- Recurrent symptoms of gastroesophageal reflux disease should be evaluated with esophageal manometry and ambulatory pH testing.
- Reoperative antireflux surgery should be performed by experienced gastroesophageal surgeons.

INTRODUCTION

Gastroesophageal reflux disease (GERD) is the most common benign medical condition of the stomach and esophagus. GERD is defined by abnormal distal esophageal acid exposure that is associated with patient symptoms. Most patients who present to their primary medical doctor with typical GERD symptoms (ie, heartburn and regurgitation) never undergo formal diagnostic evaluation and are effectively managed with nonoperative therapy, specifically proton pump inhibitors (PPIs). PPIs are so effective at decreasing

[a] Department of General Surgery, Center for Videoendoscopic Surgery, University of Washington, 1959 NE Pacific Street, Box 356410/Suite BB-487, Seattle, WA 98195, USA; [b] Division of General Surgery, Department of Surgery, Center for Esophageal and Gastric Surgery, University of Washington, 1959 NE Pacific Street, Box 356410/Suite BB-487, Seattle, WA 98195, USA
* Corresponding author.
E-mail address: rby2@uw.edu

Surg Clin N Am 95 (2015) 527–553
http://dx.doi.org/10.1016/j.suc.2015.02.007 surgical.theclinics.com
0039-6109/15/$ – see front matter © 2015 Elsevier Inc. All rights reserved.

Abbreviations

BOS	Bronchiolitis obliterans syndrome
EGD	Esophagogastroduodenoscopy
FEV_1	Forced expiratory volume in 1 second
GEJ	Gastroesophageal junction
GER	Gastroesophageal reflux
GERD	Gastroesophageal reflux disease
IPF	Idiopathic pulmonary fibrosis
LARS	Laparoscopic antireflux surgery
LES	Lower esophageal sphincter
PEH	Paraesophageal hernia
PPI	Proton pump inhibitor
UGI	Upper gastrointestinal series

gastric acid production that they provide some improvement in typical GERD-related symptoms in nearly all patients with GERD. Consequently, an empirical trial of PPI therapy has become viewed as both diagnostic and therapeutic for patients that present with typical GERD symptoms. Moreover, improvement in GERD symptoms with the initiation of PPI therapy is considered a predictor of good response to antireflux surgery.

In patients that experience persistent, life-limiting symptoms despite maximal PPI therapy, a formal diagnostic evaluation should be completed. This evaluation includes ambulatory esophageal pH monitoring, esophageal manometry, upper gastrointestinal series (UGI), and esophagogastroduodenoscopy (EGD). For patients who exhibit elevated distal esophageal acid exposure and life-limiting symptoms despite maximal medical therapy, antireflux surgery should be strongly considered. Importantly, patients that experience no improvement in their symptoms with PPI use may not have GERD; surgeons must carefully consider alternative causes before offering surgical treatment. Endoscopic evidence of severe esophageal injury (eg, ulcerations, peptic strictures, and Barrett esophagus) can be considered evidence of gastroesophageal reflux (GER); however, these findings should not be considered an indication for operative therapy by themselves.

The application of laparoscopy to antireflux surgery has decreased perioperative morbidity, hospital length of stay, and cost compared with open operations. Conceptually, laparoscopic antireflux surgery (LARS) is straightforward; however, the correct construction of a fundoplication requires significant operative experience and skills in complex laparoscopy. In patients who present with late complications of antireflux surgery, including recurrent GERD and dysphagia, reoperative antireflux surgery can be effectively performed. Compared with first-time operations, however, reoperative antireflux surgery is technically more challenging, associated with a higher risk for perioperative complications, and results in less durable symptom improvement. Therefore, compared with first-time antireflux surgery, surgeons should have a higher threshold for offering patients reoperation; reoperations should be performed by experienced, high-volume gastroesophageal surgeons.

The purpose of this article is to review the surgical management of GERD, including relevant preoperative and postoperative patient care, operative technique, and the common complications of LARS and their management.

RELEVANT ANATOMY, PHYSIOLOGY, AND PATHOPHYSIOLOGY

Endogenous antireflux mechanisms include the lower esophageal sphincter (LES) and spontaneous esophageal clearance. GERD results from the failure of these endogenous antireflux mechanisms.

The LES has the primary role of preventing reflux of gastric contents into the esophagus. Rather than a distinct anatomic structure, the LES is a zone of high pressure located just cephalad to the gastroesophageal junction (GEJ). The LES can be identified during esophageal manometric evaluation.

The LES is made up of 4 anatomic structures (**Box 1**):

1. The *intrinsic musculature of the distal esophagus* is in a state of tonic contraction. With the initiation of a swallow, these muscle fibers relax and then return to a state of tonic contraction.
2. *Sling fibers of the gastric cardia* are at the same anatomic depth as the circular muscle fibers of the esophagus but are oriented diagonally from the cardia-fundus junction to the lesser curve of the stomach (**Fig. 1**). The sling fibers contribute significantly to the high-pressure zone of the LES.
3. The *crura of the diaphragm* surround the esophagus as it passes through the esophageal hiatus. During inspiration, when intrathoracic pressure decreases relative to intra-abdominal pressure, the anteroposterior diameter of the crural opening is decreased, compressing the esophagus and increasing the measured pressure at the LES.
4. With the GEJ firmly anchored in the abdominal cavity, increased *intra-abdominal pressure* is transmitted to the GEJ, which increases the pressure on the distal esophagus and prevents reflux of gastric contents.

GER occurs when intragastric pressure is greater than the high-pressure zone of the distal esophagus and can develop under two conditions: (1) the LES resting pressure is too low (ie, hypotensive LES) and (2) the LES relaxes in the absence of peristaltic contraction of the esophagus (ie, spontaneous LES relaxation).[1] Small changes in this high-pressure zone can compromise its effectiveness, and GER is a normal physiologic process that occurs even in the setting of a normal LES. Importantly, the distinction between physiologic reflux (ie, GER) and pathologic reflux (ie, GERD) hinges on the total amount of esophageal acid exposure, patient symptoms, and the presence of mucosal damage of the esophagus.

GERD is often associated with a hiatal hernia. Although any type of hiatal hernia may give rise to an incompetent LES, the most common is the type I hiatal hernia, also called a sliding hiatal hernia (**Fig. 2**). A type I hernia is present when the GEJ is not maintained in the abdominal cavity by the phrenoesophageal ligament, a continuation of the endoabdominal peritoneum that reflects onto the esophagus at the hiatus. Thus, the cardia migrates back and forth between the posterior mediastinum and peritoneal cavity. The presence of a small sliding hernia does not necessarily imply an incompetent cardia. Although a patient with typical symptoms of GERD may be found to have a hiatal or paraesophageal hernia (PEH), these hernias are neither necessary nor sufficient to make the diagnosis of GERD; the presence of such a hernia does not constitute an indication for operative correction. In fact, many patients with hiatal hernias do not have symptoms and do not require treatment.

Box 1
The anatomic components of the LES

1. Intrinsic musculature of the distal esophagus
2. Sling fibers of the gastric cardia
3. Diaphragmatic crura at the esophageal hiatus
4. Intra-abdominal pressure exerted on the gastroesophageal junction

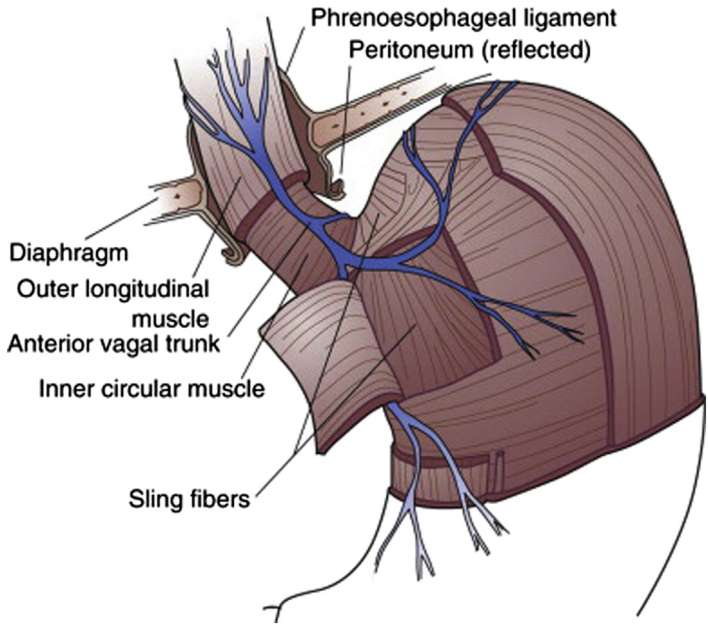

Fig. 1. The muscle layers at the GEJ. The intrinsic muscle of the esophagus, diaphragm, and sling fibers contribute to the LES pressure. The sling fibers of the cardia are located at the same depth as the circular muscle fibers of the esophagus. (*From* Oelschlager BK, Eubanks TR, Pellegrini CA. Hiatal hernis and gastroesophageal reflux disease. In: Townsend CM, Beauchamp RD, Evers MB, et al, editors. Sabiston Textbook of Surgery. 19th edition. Philadelphia: Elsevier; 2012; with permission.)

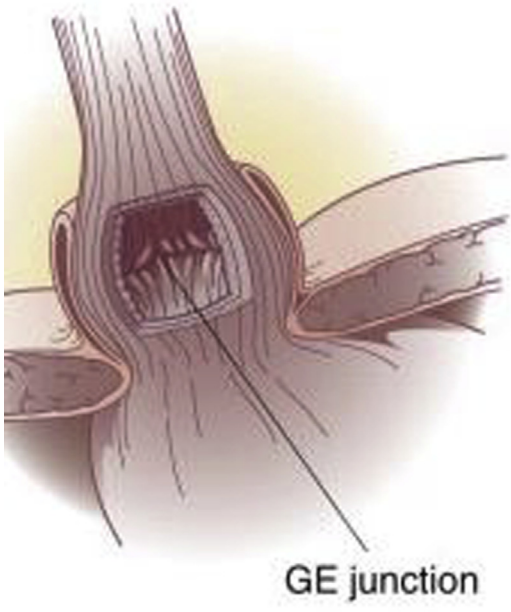

Fig. 2. Type I, or sliding, hiatal hernia. GE, gastroesophageal. (*From* Oelschlager BK, Eubanks TR, Pellegrini CA. Hiatal hernis and gastroesophageal reflux disease. In: Townsend CM, Beauchamp RD, Evers MB, et al, editors. Sabiston Textbook of Surgery. 19th edition. Philadelphia: Elsevier; 2012; with permission.)

CLINICAL PRESENTATION OF GASTROESOPHAGEAL REFLUX DISEASE

Typical Symptoms of Gastroesophageal Reflux Disease

The prevalence of symptoms among 1000 patients with GERD is presented in **Table 1**. Heartburn, regurgitation, and water brash are the 3 typical esophageal symptoms of GERD. Heartburn is very specific to GERD and described as epigastric and/or retrosternal caustic or stinging sensation. Typically, it does not radiate to the back and is not described as a pressure sensation, both of which are more characteristic of pancreatitis and acute coronary syndrome, respectively. It is important to ask patients about their symptoms in detail to differentiate typical heartburn from symptoms of peptic ulcer disease, cholelithiasis, or coronary artery disease.

The presence of regurgitation often indicates progression of GERD. In severe cases, patients will be unable to bend over without experiencing an episode of regurgitation. Regurgitation of gastric contents to the oropharynx and mouth can produce a sour taste that patients will describe as either acid or bile. This phenomenon is referred to as water brash. In patients that report regurgitation as a frequent symptom, it is important to distinguish between regurgitation of undigested and digested food. Regurgitation of undigested food is not common in GERD and suggests the presence of a different pathologic process, such as an esophageal diverticulum or achalasia.

Extraesophageal Symptoms of Gastroesophageal Reflux Disease

Extraesophageal symptoms of GERD arise from the respiratory tract and include both laryngeal and pulmonary symptoms (**Box 2**). Two mechanisms may lead to extraesophageal symptoms of GERD.[2] First, proximal esophageal reflux and microaspiration of gastroduodenal contents cause direct caustic injury to the larynx and lower respiratory tract; this is probably the most common mechanism. Second, distal esophageal acid exposure triggers a vagal nerve reflex that results in bronchospasm and cough. The latter mechanism is caused by the common vagal innervation of the trachea and esophagus.

Unlike typical GERD symptoms (ie, heartburn and regurgitation), extraesophageal symptoms of reflux are not specific to GERD. Before performing LARS, it is necessary to determine whether a patient's extraesophageal symptoms are caused by abnormal GER or a primary laryngeal-bronchial-pulmonary cause. This endeavor can be challenging. A lack of response of extraesophageal symptoms to a trial of PPI therapy

Table 1
Prevalence of symptoms occurring more than once per week among 1000 patients with GERD

Symptom	Prevalence (%)
Heartburn	80
Regurgitation	54
Abdominal pain	29
Cough	27
Dysphagia for solids	23
Hoarseness	21
Belching	15
Bloating	15
Aspiration	14
Wheezing	7
Globus	4

Box 2
Extraesophageal symptoms of GERD

Laryngeal symptoms of reflux

1. Hoarseness/dysphonia
2. Throat clearing
3. Throat pain
4. Globus
5. Choking
6. Postnasal drip
7. Laryngeal and tracheal stenosis
8. Laryngospasm
9. Contact ulcers

Pulmonary symptoms of reflux

1. Cough
2. Shortness of breath
3. Wheezing
4. Pulmonary disease (idiopathic pulmonary fibrosis, chronic bronchitis, asthma, and others)

cannot reliably refute GERD as the cause of extraesophageal symptoms. Although PPI therapy can improve or completely resolve *typical* GERD symptoms, patients with *extraesophageal symptoms* experience a variable response to medical treatment.[3–5] This variability may be explained by recent evidence that suggests acid is not the only underlying caustic agent that results in laryngeal and pulmonary injury.[6–8] PPI therapy will suppress gastric acid production; but microaspiration of nonacid refluxate, which contains caustic bile salts and pepsin, can cause ongoing injury and symptoms. Therefore, in patients with extraesophageal symptoms of GERD, a mechanical barrier to reflux (ie, esophagogastric fundoplication) may be necessary to prevent ongoing laryngeal-tracheal-bronchial injury.

In patients that present with abnormal GER and bothersome extraesophageal symptoms, a thorough evaluation must be completed to rule out a primary disorder of their upper or lower respiratory tract. This evaluation should be completed whether or not typical GERD symptoms are also present. At the University of Washington Center for Esophageal and Gastric Surgery, the authors frequently refer patients with extraesophageal symptoms to an otolaryngologist and/or a pulmonologist to determine if a nongastrointestinal condition is present. If nonreflux causes of the extraesophageal symptoms are not identified, then proceeding with an antireflux operation is acceptable. The authors counsel these patients that there is a 70% likelihood of improvement in extraesophageal symptoms following LARS.[9] If a patient's laryngeal or pulmonary symptoms are not caused by abnormal GER, an antireflux operation is not performed.

Pulmonary Disease, Gastroesophageal Reflux Disease, and Antireflux Surgery

Increasing evidence suggests GERD is a contributing factor to the pathophysiology of several pulmonary diseases.[10,11] In their extensive review, Bowrey and colleagues[12] examined medical and surgical antireflux therapy in patients with GERD and asthma.

In these patients, the use of antisecretory medications was associated with improved respiratory symptoms in only 25% to 50% of patients with GERD-induced asthma. Furthermore, less than 15% of these patients experienced objective improvement in pulmonary function. One explanation for these results is that most of these studies lasted 3 months or less, which is potentially too short to see any improvement in pulmonary function. Additionally, in several trials, gastric acid secretion was incompletely blocked by acid suppression therapy, and patients experienced ongoing GERD.

In patients with asthma and GERD, antireflux surgery seems to be more effective than medical therapy at managing pulmonary symptoms. Antireflux surgery is associated with improvement in respiratory symptoms in nearly 90% of children and 70% of adults with asthma and GERD. Several randomized trials have compared histamine-2 receptor antagonists and antireflux surgery in the management of GERD-associated asthma. Compared with patients treated with antisecretory medications, patients treated with antireflux surgery were more likely to experience relief of asthma symptoms, discontinue systemic steroid therapy, and improve peak expiratory flow rate.

Idiopathic pulmonary fibrosis (IPF) is a severe, chronic, and progressive lung disease that generally results in death within 5 years of diagnosis. Recently, the pathophysiology of IPF has been shown to hinge on alveolar epithelial injury followed by abnormal tissue remodeling. Proximal esophageal reflux and microaspiration of acid and nonacid gastric contents has been implicated as one possible cause of alveolar epithelial injury that can lead to IPF.

The incidence of GERD in patients with IPF has been reported to be between 35% and 94%.[13–16] Importantly, typical symptoms of GERD are not sensitive for abnormal reflux in patients with IPF; many patients with IPF do not experience any heartburn, regurgitation, or acid brash.[17] Consequently, the threshold to test for GERD in patients with IPF should be low; several authors have recommended ambulatory pH monitoring in all patients with IPF.[18,19] Several studies have demonstrated that the severity of reflux measured by ambulatory pH monitoring does not seem to be associated with the severity of pulmonary disease in patients with IPF.[20] Therefore, a mildly abnormal pH study does not mean that GERD is playing a minor role in a patient's IPF.

Several studies have investigated the effect of GERD treatment on pulmonary function and survival in patients with IPF. In reviewing the charts of 204 patients with IPF, Lee and colleagues[21] used logistic regression to show that both acid suppression therapy and history of Nissen fundoplication were associated with longer survival and slower pulmonary decline. As previously stated, nonacid reflux has been implicated in both extraesophageal symptoms of reflux as well as IPF. Although PPI use suppresses gastric acid production, it does not prevent reflux of nonacid gastroduodenal contents. In 18 patients with IPF, Kilduff and colleagues[22] demonstrated PPI use was associated with fewer episodes of acid reflux on pH monitoring; however, these patients experienced no change in reported cough severity and were found to have persistent and significant nonacid reflux on esophageal impedance testing. Therefore, in patients with IPF with significant GERD, the argument could be made that a mechanical barrier to both acid and nonacid reflux (ie, LARS) is more appropriate than PPI therapy.

Although very little literature exists on LARS in patients with IPF, it seems to be safe, provide effective control of distal esophageal acid exposure, and may mitigate decline in pulmonary function. Raghu and colleagues[23] published their experience with LARS in one patient with IPF and GERD. During 72 months of follow-up, they demonstrated stabilization of forced vital capacity, diffusion capacity of the lung to carbon monoxide, room air oxygen saturation, and exercise capacity on 6-minute walk test. Although this represents a single case report, these results are profound, given that most patients

with IPF would have experienced rapid deterioration in lung function over the study time period.

Linden and colleagues[24] performed LARS on 19 patients with chronic lung disease (14 with IPF) and GERD. No patient deaths occurred within 30 days of the operation. When the 14 patients with IPF who underwent LARS were compared with non-GERD matched controls, there was a significant decrease in supplemental oxygen requirement for patients that underwent LARS. However, no other objective measurements of lung function differed between the groups at a mean follow-up of 15 months. These patients did not undergo postoperative pH monitoring; therefore, potentially ongoing, yet unidentified, reflux could explain these results. At the time of this publication, a National Institutes of Health–funded multicenter prospectively randomized trial in patients with IPF and GERD is comparing LARS with PPI therapy. The results of this study may profoundly impact the management of these patients.

Survival after lung transplant is limited by the function of the transplanted lungs, and bronchiolitis obliterans syndrome (BOS) is a major contributing factor to allograft dysfunction. At 5 years after transplant, BOS can affect up to 80% of lung transplant patients; by 3 years after transplant, it accounts for up to 30% of all deaths.[25] There is increasing evidence that GERD may contribute to BOS. GERD is found in as many as 75% of patients after lung transplant, and it is now viewed as a modifiable risk factor for allograft deterioration. Consequently, it is becoming more common for lung transplant patients to be evaluated for GERD and undergo LARS.

Lung transplant patients are a high operative risk group. Compared with a matched cohort of patients without pulmonary disease undergoing elective LARS, they have a higher overall comorbidity burden and higher rates of diabetes mellitus and chronic renal disease; and pulmonary allografts do not function as well as healthy native lungs.[26] A single-center study found pulmonary transplant patients undergoing LARS have a longer postoperative length of stay (2.89 vs 0.71 days) and higher readmission rate (25% vs 3%) compared with the general population.[27] In a nationwide study using propensity-matched controls without a history of lung transplant, Kilic and colleagues[26] found that lung transplant patients undergoing antireflux surgery had similar rates of postoperative mortality as well as overall and individual morbidity (cardiac, pulmonary, renal, wound, hollow viscous injury). Similar to single-center studies, hospital length of stay and estimated costs of care were higher in lung transplant patients.

In lung transplant patients with GERD, LARS is associated with improved objective measurement of allograft function. Hoppo and colleagues[28] retrospectively reviewed their experience with LARS in 22 lung transplant patients with GERD. After LARS, 91% of patients experienced significant improvement in forced expiratory volume in 1 second (FEV_1). In 12 patients that had decreasing FEV_1 before LARS, 11 patients experienced a reversal of this trend after LARS. Additionally, following LARS, there were fewer episodes of pneumonia and rejection.

DIAGNOSTIC PROCEDURES

Frequently, the diagnosis of GERD is made clinically based on the presence of typical GERD symptoms and improvement in those symptoms with PPI therapy. However, when patients are referred to a surgeon for antireflux surgery, 4 tests are helpful to establish the diagnosis and, thus, should strongly be considered (**Box 3**): (1) Ambulatory pH monitoring confirms the presence of elevated distal esophageal acid exposure. (2) Esophageal manometry identifies esophageal motility disorders that may affect the type of antireflux operation performed. (3) EGD can identify the competence

Box 3
Four key diagnostic tests in the evaluation of GERD

1. Ambulatory pH monitoring
2. Esophageal manometry
3. Esophagogastroduodenoscopy
4. Upper gastrointestinal series (esophagram)

of the antireflux valve and gastroesophageal mucosal changes (eg, erosive esophagitis and Barrett esophagus). (4) UGI provides the surgeon detailed anatomy of the esophagus and stomach, including the presence of hiatal and PEH.

ADDITIONAL PREOPERATIVE CONSIDERATIONS

Dysphagia

Occasionally, patients with GERD will experience dysphagia. The causes of dysphagia are listed in **Box 4**. In patients with GERD, reflux-associated peptic strictures are pathognomonic for long-standing reflux and develop from the chronic mucosal inflammation that occurs with GERD. When strictures result in significant dysphagia, patients can experience weight loss and protein/calorie malnutrition. Additionally, strictures can be associated with esophageal shortening, which makes obtaining adequate intra-abdominal esophageal length at the time of operation more difficult (see section on Intraoperative Management of Short Esophagus). Since the widespread adoption of PPI therapy in patients with reflux, peptic strictures are much less common.

In patients with peptic strictures, it can be challenging to document GERD on ambulatory pH monitoring because the presence of a tight stricture may prevent reflux of acid, resulting in a false-negative pH study. In patients with typical GERD symptoms and a peptic stricture, it is reasonable to forego ambulatory pH monitoring because the presence of a peptic stricture is considered pathognomonic for severe GER. If pH monitoring is performed, it is ideally completed after dilation of the

Box 4
Causes of dysphagia in patients undergoing evaluation for GERD

Esophageal obstruction

1. Peptic strictures
2. Schatzki ring
3. Malignant neoplasm
4. Benign neoplasm
5. Foreign body

Esophageal motility disorders

1. Diffuse esophageal spasm
2. Hypercontractile (nutcracker) esophagus
3. Ineffective esophageal motility
4. Achalasia

stricture to increase the validity of the test. Importantly, because they are associated with long-standing GER, peptic strictures should be biopsied to rule out intestinal metaplasia, dysplasia, and malignancy.

Most peptic strictures are effectively treated with dilation and PPI therapy. Successful dilation can be performed with either a balloon dilator or Savary dilator, and no strong data exist to support the superiority of one dilation technique over another. Refractory peptic strictures are defined as strictures that recur after dilation despite PPI therapy. Although rare, refractory strictures can pose significant challenge to surgeons and gastroenterologists. In these patients, LARS should be strongly considered. For patients who are unfit for or do not wish to undergo an operation, steroid injections of the stricture have been shown to result in fewer dilations.[29]

A second common cause of dysphagia in patients with GERD is a Schatzki ring. Similar to peptic strictures, these are located in the distal esophagus. However, Schatzki rings are submucosal fibrotic bands (as opposed to mucosal strictures). Typically, peptic strictures and Schatzki rings can be differentiated on endoscopy. Both should be dilated to relieve obstruction; but Schatzki rings develop in the submucosal space, so in the absence of other endoscopically identified mucosal abnormalities, biopsies do not need to be performed. Furthermore, Schatzki rings are not pathognomonic for GERD, so abnormal distal esophageal acid exposure must be documented on ambulatory pH monitoring to confirm the presence of abnormal GER before performing LARS.

In patients who present with dysphagia and GERD, other causes of dysphagia must be excluded, including tumors, diverticula, and esophageal motor disorders. Although these conditions are much less common than peptic strictures and Schatzki rings, they require dramatically different treatments. In patients that report simultaneous onset of dysphagia to liquids and solids, one must have a high suspicion for a neuromuscular or autoimmune disorder as the cause. Finally, it is important to recognize that some patients with GERD report dysphagia without any anatomic or physiologic abnormality. The authors have found that such patients typically experience improvement in dysphagia following LARS.

Obesity

Obesity is a significant risk factor for the development of GERD. Compared with patients of normal weight, obese patients have increased intra-abdominal pressure, decreased LES pressure, and more frequent transient LES relaxations.[30] Obese patients with GERD present a particular challenge to surgeons. Although it is clear that LARS can be performed safely in obese patients, the literature is mixed on the ability of LARS to provide long-term control of GERD-related symptoms.[30–33] In appropriately selected patients, laparoscopic Roux-en-Y gastric bypass is the most durable method of weight loss and control of obesity-related comorbidities, including GERD.[31,32] In severely obese patients with GERD, serious consideration should be given to performing a laparoscopic Roux-en-Y gastric bypass instead of a fundoplication. Ultimately, the decision to pursue gastric bypass instead of fundoplication must include a careful balance of the patients' interest in bariatric surgery, presence of other medical comorbidities, and availability of a surgeon to perform the operation.

Partial Versus Complete Fundoplication

Antireflux operations include partial posterior (180° and 270°), partial anterior (90° and 180°), and 360° esophagogastric fundoplications. In antireflux surgery, there has been a long-standing debate over which fundoplication provides superior control of GERD

symptoms while mitigating postoperative side effects (eg, dysphagia and gas-bloat). Furthermore, studies have attempted to determine whether the type of fundoplication performed should be tailored to the patients' preoperative esophageal motility and symptoms.

In patients with GERD and esophageal dysmotility, it has been suggested that partial fundoplication should be performed because of concern that a Nissen fundoplication will lead to greater postoperative dysphagia. Booth and colleagues[34] completed a randomized controlled trial to compare laparoscopic Nissen fundoplication with Toupet fundoplication in patients who were stratified based on preoperative manometry. At 1 year postoperatively, there were no differences between the Nissen and Toupet groups for heartburn and regurgitation. Dysphagia was more frequent in patients that underwent Nissen fundoplication. However, when a Nissen fundoplication was constructed, patients with normal and impaired esophageal motility experienced similar rates of postoperative dysphagia. Similarly, the authors have shown that a Nissen fundoplication can be performed in patients with ineffective esophageal motility without an increase in development of dysphagia.[35]

Fein and Seyfried[36] reviewed 9 randomized trials that evaluated laparoscopic anterior, partial posterior, and total fundoplications in the management of GERD. Anterior fundoplication was associated with greater risk of recurrent GERD symptoms. Nissen was associated with increased postoperative dysphagia, but these patients required minimal treatment and no reoperations. In the randomized trials reviewed, no difference in gas-bloat symptoms was seen between Nissen and Toupet fundoplication. However, Nissen was associated with more gas-bloat in nonrandomized trials.

Shan and colleagues[37] reviewed 32 studies, including 9 randomized controlled trials, that compared laparoscopic Nissen fundoplication with laparoscopic Toupet fundoplication. No differences were noted between the groups concerning patient satisfaction with the operation or perioperative morbidity and mortality. In 24 studies that assessed postoperative dysphagia, no difference was noted between fundoplication types when esophageal motility was normal. However, in patients with abnormal esophageal motility, laparoscopic Nissen fundoplication was associated with greater rates of dysphagia. An additional analysis was performed that compared rates of dysphagia in patients with normal motility who underwent a Nissen and patients with abnormal motility who underwent a Toupet. In this comparison, the patients who underwent a Nissen fundoplication reported more dysphagia. Finally, this meta-analysis found increased rates of postoperative gas-bloat and an inability to belch in patients that underwent Nissen. This review would suggest that Toupet fundoplication is the treatment of choice, leading to effective GERD symptom control and less postoperative side effects.

As evidenced earlier, despite numerous randomized clinical trials and 2 meta-analyses, there still remains conflicting evidence regarding which fundoplication provides the most durable control of reflux and the best side-effect profile. The reason for this is likely the heterogeneity of these studies in terms of patient characteristics, patient selection, and operative technique. For example, in the studies evaluated by Fein and Seyfried,[36] there were 4 different bougie sizes used (34 F to 60 F); fixation of the stomach to the esophagus and hiatus was inconsistent among surgeons; and division of the short gastric vessels was not always performed. Currently, the only consistent finding in these studies is that anterior fundoplications provide less durable control of GERD than posterior partial and total fundoplications. Otherwise, surgeons should perform the fundoplication that they are most comfortable performing and not tailor the fundoplication type to esophageal dysmotility.

OPERATIVE TECHNIQUE

The authors perform all laparoscopic antireflux operations with patients in the low lithotomy position. This position provides the surgeon improved ergonomics by standing between the patients' legs; the assistant stands at the patients' left. Additionally, patients are placed in steep reverse Trendelenburg position, which allows for an unobstructed view of the esophageal hiatus. Patients are appropriately padded to prevent pressure ulcers and neuropathies. Preoperative antibiotics are administered to reduce the risk of surgical site infection, and subcutaneous heparin and sequential compression devices are used to reduce the risk of venous thromboembolic events.

Access to the abdomen is obtained using a Veress needle at Palmer's point in the left upper quadrant of the abdomen. Three additional trocars and a Nathanson liver retractor are placed. The surgeon operates through the two most cephalad ports, and the assistant operates through the two caudad ports. The liver retractor is placed in the subxiphoid region, just left of the midline (**Fig. 3**).

The authors begin the dissection at the left crus by dividing the phrenogastric membrane and then enter the lesser sac at the level of the inferior edge of the spleen. Doing so allows for early ligation of the short gastric vessels and mobilization of the gastric fundus (**Fig. 4**). After the fundus is mobilized, the left phrenoesophageal membrane is divided to expose the length of the left crus (**Fig. 5**).

Right crural dissection is then performed. The gastrohepatic ligament is divided, and the right phrenoesophageal membrane is opened to expose the right crus. A retroesophageal window is created. Care is taken to preserve the anterior and posterior vagi during this mobilization. A Penrose drain is placed around the esophagus to facilitate the posterior mediastinal dissection and assist with creation of the fundoplication.

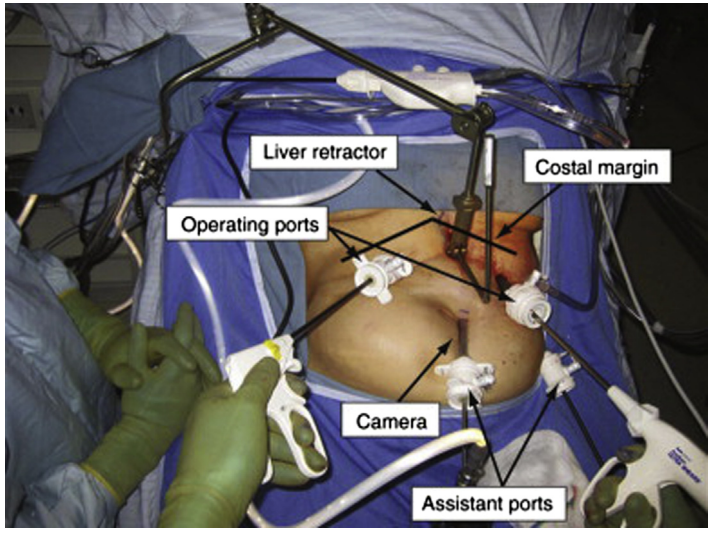

Fig. 3. Port placement for LARS. The surgeon operates through the 2 cephalad ports, and the assistant operates through the 2 caudad ports. A Nathanson liver retractor is placed in the subxiphoid location. (*From* Oelschlager BK, Eubanks TR, Pellegrini CA. Hiatal hernis and gastroesophageal reflux disease. In: Townsend CM, Beauchamp RD, Evers MB, et al, editors. Sabiston Textbook of Surgery. 19th edition. Philadelphia: Elsevier; 2012; with permission.)

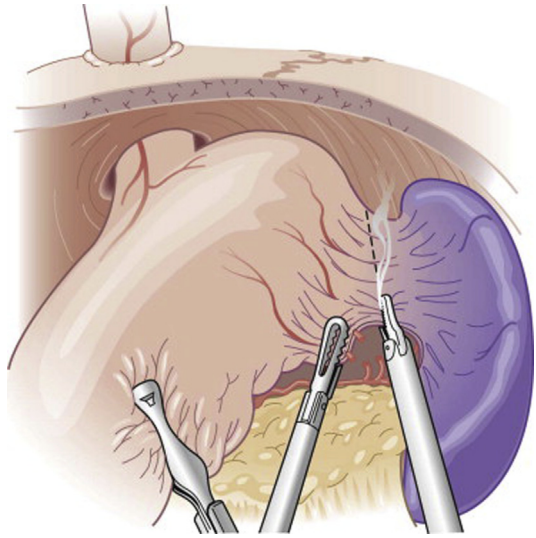

Fig. 4. In the left crus approach to the esophageal hiatus, the fundus of the stomach is mobilized early during the operation to provide early visualization of the spleen, which helps prevent splenic injury. (*From* Oelschlager BK, Eubanks TR, Pellegrini CA. Hiatal hernis and gastroesophageal reflux disease. In: Townsend CM, Beauchamp RD, Evers MB, et al, editors. Sabiston Textbook of Surgery. 19th edition. Philadelphia: Elsevier; 2012; with permission.)

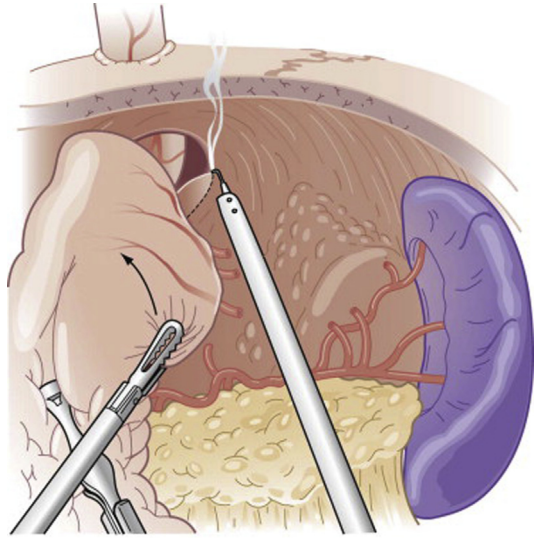

Fig. 5. After the fundus has been mobilized, the phrenoesophageal membrane is incised at the left crus, taking care to avoid injury to the esophagus and posterior vagus. (*From* Oelschlager BK, Eubanks TR, Pellegrini CA. Hiatal hernis and gastroesophageal reflux disease. In: Townsend CM, Beauchamp RD, Evers MB, et al, editors. Sabiston Textbook of Surgery. 19th edition. Philadelphia: Elsevier; 2012; with permission.)

The esophagus is mobilized in the posterior mediastinum to obtain a minimum of 3 cm of intra-abdominal esophagus. Then, the crura are approximated posteriorly with permanent sutures. The esophagus should maintain a straight orientation without angulation, and a 52-F bougie should easily pass beyond the esophageal hiatus and into the stomach (Fig. 6). At this point, the fundoplication is created.

Creation of a 360° Fundoplication

When performing a Nissen fundoplication, the most common technical failure is incorrect construction of the fundoplication. The description that follows clearly explains the authors' method of performing a correct, effective, and reproducible Nissen. During creation of the fundoplication, it is necessary to maintain appropriate orientation of the gastric fundus. To do this, the posterior aspect of the fundus is marked with a suture 3 cm distal to the GEJ and 2 cm off the greater curvature (Fig. 7). The posterior fundus is then passed behind the esophagus from the patients' left to right. The anterior fundus on the left side of the esophagus is then grasped 2 cm from the greater curvature and 3 cm from the GEJ, and both portions of the fundus are positioned on the anterior aspect of the esophagus. As demonstrated in Fig. 8, it is of paramount importance that the two points at which the fundus is grasped are equidistant from the greater curvature. Creation of the fundoplication in this manner decreases the chance of constructing the fundoplication with the body of the stomach, which creates a redundant posterior aspect of the wrap that can impinge on the distal esophagus and cause dysphagia. Using 3 or 4 interrupted permanent sutures, the fundoplication is created to a length of 2.5 to 3.0 cm. Similar to the crural repair, the completed fundoplication should allow the easy passage of a 52-F bougie. After removal of the bougie, the wrap is anchored to the esophagus and crura (Fig. 8, inset) to help prevent herniation into the mediastinum and slipping of the fundoplication over the body of the stomach. The suture line of the fundoplication should lie parallel to the right-anterior aspect esophagus.

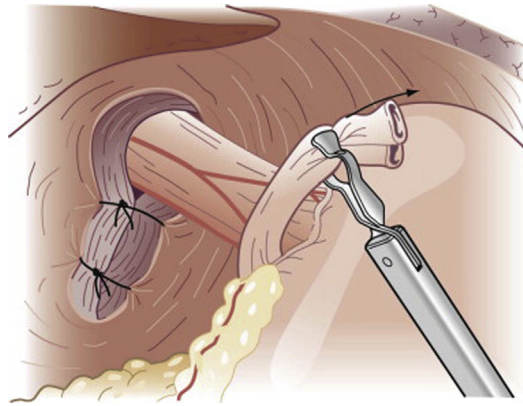

Fig. 6. Posterior crural closure is performed with heavy permanent suture taking care to incorporate the peritoneum into the closure. The exposure is facilitated by displacement of the esophagus anteriorly and to the left using the Penrose drain. (*From* Oelschlager BK, Eubanks TR, Pellegrini CA. Hiatal hernis and gastroesophageal reflux disease. In: Townsend CM, Beauchamp RD, Evers MB, et al, editors. Sabiston Textbook of Surgery. 19th edition. Philadelphia: Elsevier; 2012; with permission.)

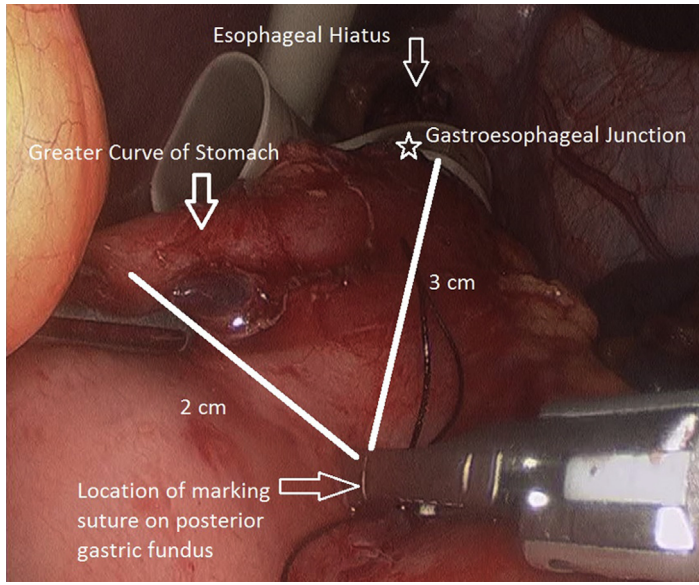

Fig. 7. With the greater curvature of the stomach rotated to the patients right, the posterior stomach is exposed. The authors place a marking stitch on the posterior fundus located 3 cm from the GEJ and 2 cm from the greater curvature to facilitate the creation of a geometrically appropriate Nissen fundoplication.

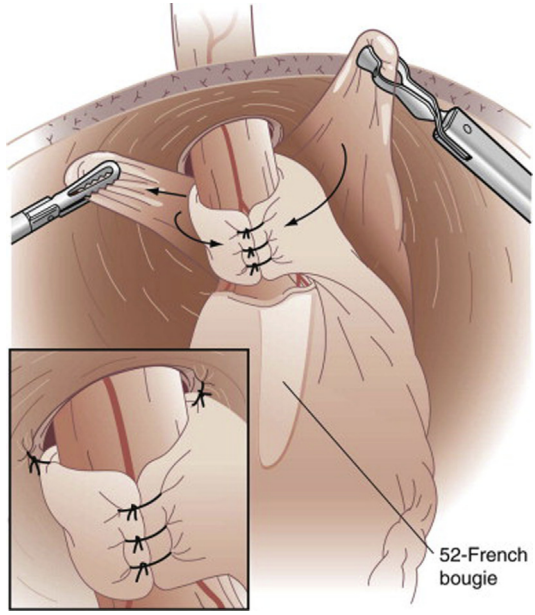

Fig. 8. Creation of a 360° (Nissen) fundoplication. The posterior (patients' *right*) and anterior (patients' *left*) gastric fundus are grasped by the surgeon 3 cm from the GEJ and 2 cm from the greater curvature. The fundoplication is then created over a 52-F bougie and anchored to the diaphragm using permanent sutures (*inset*). (*From* Oelschlager BK, Eubanks TR, Pellegrini CA. Hiatal hernis and gastroesophageal reflux disease. In: Townsend CM, Beauchamp RD, Evers MB, et al, editors. Sabiston Textbook of Surgery. 19th edition. Philadelphia: Elsevier; 2012; with permission.)

Creation of a Partial Fundoplication

There are several types of partial fundoplications. The most commonly performed is the Toupet fundoplication. In this operation, the gastric and esophageal dissections, as well as the repair of the crura, are the same as for a 360° fundoplication. Additionally, the fundoplication must be created with the fundus, and not the body, of the stomach. The key difference is that the stomach is positioned 180° to 270° (compared with 360°) around the posterior aspect of the esophagus (Fig. 9). On both sides of the esophagus, the most cephalad sutures of the fundoplication incorporate the fundus, crus, and esophagus; the remaining sutures anchor the fundus to either the crura or the esophagus.

If an anterior fundoplication is to be performed (eg, Thal or Dor), there is no need to disrupt the posterior attachments of the esophagus; the fundus is folded over the anterior aspect of the esophagus and anchored to the hiatus and esophagus (Fig. 10).

Intraoperative Management of Short Esophagus

Normal esophageal length exists when the GEJ rests at or below the esophageal hiatus. As the GEJ becomes displaced cephalad to the esophageal hiatus, the esophagus effectively shortens. At the time of LARS, a minimum of 3 cm of intra-abdominal esophagus should be obtained. When the GEJ is mildly displaced cephalad to the GEJ, adequate intra-abdominal esophageal length can be obtained with distal esophageal mobilization in the posterior mediastinum. However, if the GEJ migrates high into the posterior mediastinum, as occurs with a large hiatal or PEH, the effective length of the esophagus can decrease significantly. Furthermore, this process causes adhesions to develop between the esophagus and the mediastinum, which anchor the

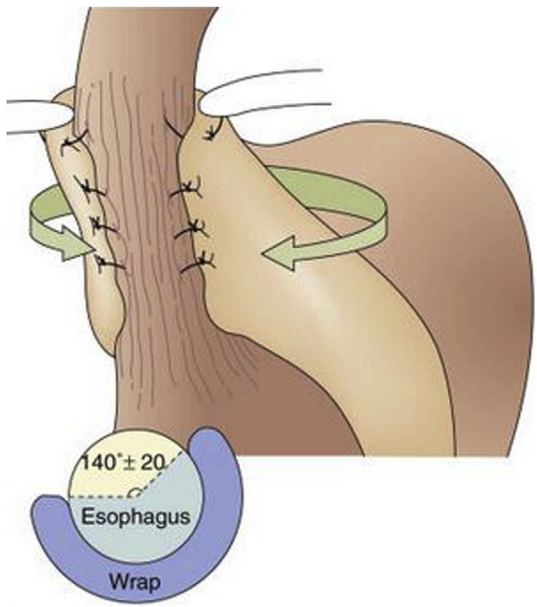

Fig. 9. Partial posterior (Toupet) fundoplication. (*From* Oelschlager BK, Eubanks TR, Pellegrini CA. Hiatal hernis and gastroesophageal reflux disease. In: Townsend CM, Beauchamp RD, Evers MB, et al, editors. Sabiston Textbook of Surgery. 19th edition. Philadelphia: Elsevier; 2012; with permission.)

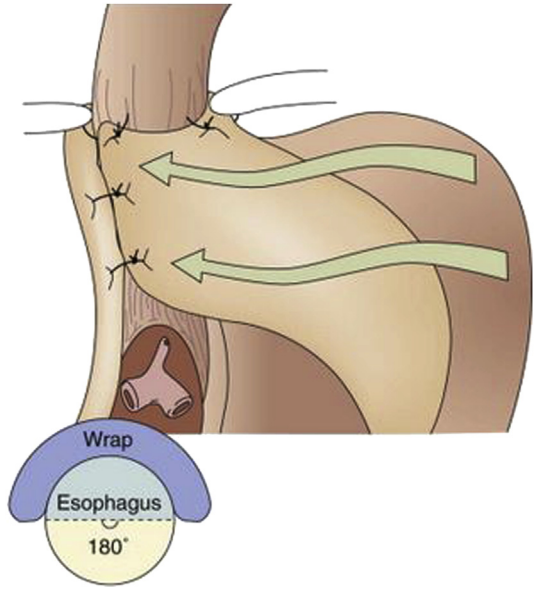

Fig. 10. Partial anterior (Dor) fundoplication. (*From* Oelschlager BK, Eubanks TR, Pellegrini CA. Hiatal hernis and gastroesophageal reflux disease. In: Townsend CM, Beauchamp RD, Evers MB, et al, editors. Sabiston Textbook of Surgery. 19th edition. Philadelphia: Elsevier; 2012; with permission.)

contracted esophagus in the chest. When this occurs, extensive mobilization of the esophagus must be undertaken, sometimes to the level of the inferior pulmonary veins. However, even in the case of large hiatal or PEHS, usually mediastinal dissection alone can return the GEJ to the abdominal cavity.

In some cases, adequate esophageal length cannot be obtained despite extensive mediastinal mobilization of the esophagus. In these rare cases, a unilateral vagotomy provides an additional 1 to 2 cm of esophageal length; division of both vagi typically yields 3 to 4 cm of additional esophagus. Many surgeons hesitate to electively transect the vagi because of concern for patients developing postoperative delayed gastric emptying. However, the authors have shown this not to be the case. In the authors' study of 102 patients who underwent reoperative LARS (n = 50) or PEH repair (n = 52), they performed a vagotomy in 30 patients (29%) to increase intra-abdominal esophageal length following extensive mediastinal mobilization.[38] Compared with patients that did not undergo vagotomy, patients that underwent vagotomy reported similar severity of abdominal pain, bloating, diarrhea, and early satiety.

Finally, if adequate intra-abdominal esophageal length cannot be accomplished with the aforementioned techniques, a Collis gastroplasty may be performed. A double-staple technique may be used to create the neoesophagus (**Fig. 11**). However, it should be emphasized that in only a very small number of patients have the authors found this technique necessary.

Robotic Antireflux Surgery

In 2000, the Food and Drug Administration approved the da Vinci Surgical System (Intuitive Surgical, Sunnyvale, CA) for general laparoscopic surgery. Touted for providing surgeons with improved manual dexterity, visualization, and ergonomics over traditional laparoscopic surgical equipment, robotic surgery has been widely

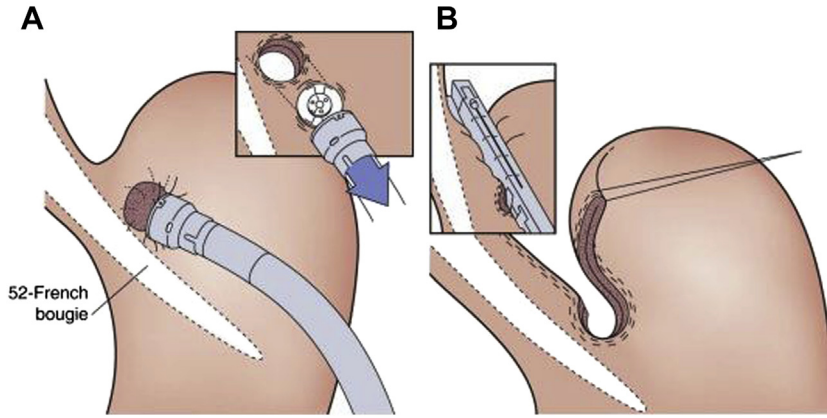

Fig. 11. Double-staple technique for esophageal lengthening. (*A*) A circular stapling and cutting device is used to create a through-and-through opening of the cardia-fundus junction. (*B*) A linear stapling and cutting device is then used to transect the remaining stomach toward the GEJ. (*From* Oelschlager BK, Eubanks TR, Pellegrini CA. Hiatal hernis and gastroesophageal reflux disease. In: Townsend CM, Beauchamp RD, Evers MB, et al, editors. Sabiston Textbook of Surgery. 19th edition. Philadelphia: Elsevier; 2012; with permission.)

advertised and applied to a variety of surgical fields. Markar and colleagues[39] completed a meta-analysis of prospective randomized trials comparing robotic Nissen fundoplication with laparoscopic Nissen fundoplication. They reviewed 6 trials for 3 primary outcome measures (postoperative dysphagia, requirement for reoperation, and mortality) and 4 secondary outcome measures (operative time, operative complications, hospital length of stay, and cost). There were no differences in clinical outcomes between patients that underwent robotic versus laparoscopic Nissen fundoplication. However, both cost of the operation and operative time were greater for robotic Nissen fundoplication. Importantly, none of these studies evaluated postoperative improvement in GERD symptoms, recurrence of GERD symptoms, or normalization of distal esophageal acid exposure. Although it seems robotic Nissen fundoplication is safe, there are no studies that support its clinical superiority over laparoscopy. Furthermore, robotic Nissen fundoplication costs more and takes longer to perform than laparoscopic Nissen fundoplication.

POSTOPERATIVE CARE AND RECOVERY

Except when the patients' comorbid medical conditions dictate otherwise, postoperatively patients are admitted to a general surgical floor without cardiac or pulmonary monitoring. Patients are given a clear-liquid diet the evening of the operation and are advanced to a full-liquid diet on postoperative day 1. Discharge requirements include tolerance of a diet to maintain hydration and nutrition, adequate pain control on oral analgesics, and ability to void without a Foley catheter. After discharge from the hospital, patients can slowly introduce soft foods into their diet; they should expect to resume a diet without limitations in about 4 to 6 weeks.

OPERATIVE COMPLICATIONS AND SIDE EFFECTS OF ANTIREFLUX SURGERY

LARS is a safe operation when performed by experienced surgeons. Mortality rates at 30 days postoperatively are far less than 1%.[40] Rates of general complications vary

according to surgeon, technique, and extent of patient follow-up. Since 1993, using the National Inpatient Database, the rate of complications following LARS has fluctuated between 4.7% and 8.3%.[41–43]

These complications are typically minor; not related specifically to LARS; and include urinary retention, wound infection, venous thrombosis, and ileus. Complications that are specific to antireflux surgery include pneumothorax, gastric/esophageal injury, splenic/liver injury, and bleeding. Additionally, LARS can result in postoperative side effects, including bloating and dysphagia. Complications in 400 patients that have undergone LARS at the University of Washington are listed in **Table 2**.

Operative Complications

Pneumothorax

Although pneumothorax is one of the most common intraoperative complications, it is reported to occur in only approximately 2% of patients.[44] Although postoperative chest radiographs are not obtained in all patients, pneumothorax should rarely be missed, as intraoperative identification of pleural violation should be identified. The pleural violation results in intrathoracic infusion of carbon dioxide, which is absorbed rapidly. Because no underlying lung injury exists, the lung will re-expand without incident. When violation of the pleura is identified intraoperatively, the pleural should be closed with a suture, and a postoperative radiograph should be obtained. If a pneumothorax is identified on this radiograph, patients may be maintained on oxygen therapy to facilitate its resolution. Unless patients experience shortness of breath or persistent oxygen therapy to maintain hemoglobin oxygenation saturation, no further radiographs are obtained.

Gastric and esophageal injuries

Gastric and esophageal injuries have been reported to occur in approximately 1% of patients undergoing LARS.[44–46] Typically, these injuries result from overaggressive manipulation of these organs or at the time the bougie is passed into the stomach. Injuries are more likely to occur in reoperative cases and should be rare during initial operations. If identified at the time of operation, repair of these injuries can be performed with suture or stapler without sequelae. If the injury is not identified intraoperatively, patients will likely need a second operation to repair the viscus, unless the leak is small and contained.

Table 2
Complications in 400 laparoscopic antireflux procedures at the University of Washington

Complication	No. of Patients (%)
Postoperative ileus	28 (7)
Pneumothorax	13 (3)
Urinary retention	9 (2)
Dysphagia	9 (2)
Other minor complications	8 (2)
Liver trauma	2 (0.5)
Acute herniation	1 (0.25)
Perforated viscus	1 (0.25)
Death	1 (0.25)
Total:	**72 (17.25)**

Splenic/liver injuries and bleeding

The incidence of splenic parenchymal injury that results in bleeding is about 2.3% in population-based studies, and major liver injury is rarely reported.[47] Although splenic bleeding is relatively uncommon, in rare cases, it can require splenectomy. Most commonly, splenic parenchymal injury occurs during mobilization of the fundus and greater curvature of the stomach. For this reason, the authors prefer to begin laparoscopic Nissen fundoplication with the left crus approach. Dividing the phrenogastric ligament and the short gastric vessels early in the operation provides a direct view of the short gastric vessels and the spleen. Care must be taken during mobilization of the fundus to avoid excessive traction on the splenogastric ligament.

A second type of injury that can occur to the spleen is a partial splenic infarction. This injury typically occurs during transection of the short gastric vessels and inadvertent coagulation of superior pole branch of the main splenic artery.[48] Partial splenic infarction rarely causes any symptoms. Finally, lacerations and subcapsular hematomas of the left lateral section of the liver can be avoided by carefully retracting it out of the operative field using a fixed retractor.

Side Effects

Bloating

The normal swallowing of air is the main factor leading to gastric distention, and the physiologic mechanism for venting this air is belching. Gastric belching occurs via vagal nerve–mediated transient LES relaxation. Following antireflux surgery, patients experience fewer transient LES relaxations[49] and, therefore, decreased belching. Consequently, patients can experience abdominal bloating. Kessing and colleagues[50] investigated the impact of gas-related symptoms on the objective and subjective outcomes of both Nissen and Toupet fundoplications. They demonstrated that preoperative belching and air swallowing was not predictive of postoperative gas-related symptoms, including bloating. They concluded that gas-related symptoms are, in part, caused by gastrointestinal hypersensitivity to gaseous distention. In this study, all patients experienced postoperative normalization of esophageal acid exposure. However, these investigators found that patients who developed postoperative gas symptoms were less satisfied with LARS when compared with patients who did not experience these symptoms.

During the early postoperative period, patients who report persistent nausea or demonstrate inadequate intake of a liquid diet should undergo an abdominal radiograph. If significant gastric distention is identified, a nasogastric tube can safely be placed to decompress the stomach for 24 hours. Few patients require further intervention for gastric bloating.

Dysphagia

It is expected that patients will experience mild, temporary dysphagia during the first 2 to 4 weeks postoperatively. This dysphagia is thought to be a result of postoperative edema at the fundoplication and esophageal hiatus. In most of these patients, this dysphagia spontaneously resolves. A second, but less common, cause of dysphagia is a hematoma of the stomach and/or esophageal wall that develops during the placement of the sutures to create the fundoplication. Although this may create more severe dysphagia, typically it resolves in several days. In both these situations, surgeons should ensure that patients can maintain their nutrition and hydration on a liquid or soft diet; however, additional interventions are rarely needed.

If severe dysphagia exists and patients cannot tolerate liquids, a UGI should be obtained to ensure no anatomic abnormality exists, such as an early hiatal hernia.

Assuming there is no early recurrent hiatal hernia, and patients can tolerate liquids, patience should be used for 3 months. If patients cannot maintain hydration, or dysphagia persists beyond 3 months, a UGI should be obtained to ensure that there is no anatomic abnormality that could explain the dysphagia. If the UGI demonstrates an appropriate positioned fundoplication below the diaphragm, an EGD with empirical dilation of the GEJ may provide relief.

CLINICAL OUTCOMES OF ANTIREFLUX SURGERY

The results of antireflux surgery can be measured by relief of symptoms, improvement in esophageal acid exposure, operative complications, and failures. Several randomized trials with long-term follow-up have compared medical and surgical therapy for GERD (Table 3). Spechler and colleagues[51] found that surgical therapy results in good symptom control after a 10-year follow-up. Although they reported 62% of patients in the surgical group were taking antisecretory medications at the long-term follow-up, the indications for this medication use were not necessarily GERD; reflux symptoms did not change significantly when these patients stopped taking these medications.

Lundell and colleagues[52] randomized patients with erosive esophagitis into surgical or medical therapy. Treatment failure was defined as moderate or severe symptoms of heartburn, regurgitation, dysphagia and/or odynophagia, recommencement of PPI therapy, reoperation, or grade 2 esophagitis. At the 7-year follow-up, fewer treatment failures were seen in patients managed with fundoplication than omeprazole (33% vs 53%, $P = .002$). In patients who did not respond to the initial dose of omeprazole,

Table 3
Randomized controlled trials comparing surgery and medical therapies for GERD

Study, Year	Study Groups	Follow-up (y)	Outcome
Grant et al,[57] 2008	PPI, $n = 179$ ARS, $n = 178$	1	Reflux score: PPI, 73; ARS, 85; $P<.05$
Lundell et al,[53] 2009	Omeprazole, $n = 71$ ARS, $n = 53$	12	Treatment failure: Omeprazole, 55%; ARS, 47%; $P = .022$
Lundell et al,[52] 2007	Omeprazole, $n = 119$ ARS, $n = 99$	7	Treatment failure: Omeprazole, 53%; ARS, 33%; $P = .002$
Mahon et al,[58] 2005	PPI, $n = 108$ ARS, $n = 109$	1	12-mo GI well-being score: PPI, 35; ARS, 37; $P = .003$ 3-mo DeMeester score: PPI, 17.7; ARS, 8.6; $P<.001$ 3-mo % time pH <4: PPI, 3.8; ARS, 1.4; $P = .002$
Cookson et al,[59] 2005	Omeprazole, $n = 50$ ARS, $n = 50$	1	Cost-analysis: ARS broke even toward end of year 8, with cost differential between ARS and PPI therapy of ≈$1300 at year 5
Spechler et al,[51] 2001	PPI, $n = 91$ ARS, $n = 38$	10	GRACI score: PPI, 83; ARS, 79; $P = .07$

Abbreviations: ARS, Antireflux surgery; GI, gastrointestinal; GRACI, gastroesophageal reflux disease activity index.
Data from Refs.[51–53,57]

dose-escalation was completed; however, surgical intervention remained superior. Patients treated with fundoplication experienced more obstructive and gas-bloat symptoms (eg, dysphagia, flatulence, inability to belch) compared with the medically treated cohort. At the 12-year follow-up, the durability of these results remained: Patients who underwent fundoplication had fewer treatment failures compared with patients treated with medical therapy (47% vs 55%, $P = .022$).[53]

Over the past 25 years, surgeon experience with LARS has increased dramatically. With increased experience, the durability of symptom improvement has increased and perioperative complications have decreased. This finding is especially true in high-volume centers. In one single-institution study that followed 100 patients for 10 years after LARS, 90% of patients remained free of GERD symptoms.[54] The authors recently published their experience in a cohort of 288 patients undergoing LARS. With a median follow-up of greater than 5 years, symptom improvement for heartburn was 90% and regurgitation was 92%.[55] These results confirm that LARS can provide excellent durable relief of GERD when patients are appropriately selected and excellent technique is used.

FAILED ANTIREFLUX SURGERY

Antireflux surgery fails because of anatomic problems with the fundoplication or the hiatus. These problems include persistent or recurrent hiatal hernia, slipped fundoplication, and incorrectly constructed fundoplication. The most common symptoms of failed LARS are typical symptoms of GERD (ie, heartburn, regurgitation, and water brash sensation) and dysphagia. One large retrospective review of more than 1700 patients that underwent antireflux surgery found that 5.6% of patients ultimately required a reoperation for symptoms of recurrent GERD or dysphagia.[56]

All patients who present with recurrent or persistent symptoms of GERD should be evaluated with esophageal manometry and ambulatory pH study. If the pH study demonstrates elevated distal esophageal acid exposure, then an esophagram and upper endoscopy should be performed. Once the diagnosis of persistent or recurrent GERD is made, treatment with PPI therapy should be instituted. Most of these patients experience resolution of their symptoms with resumption of PPI therapy. If the patients' symptoms are not effectively managed by medical therapy, then reoperation should be performed to create an effective antireflux valve.

The late development of dysphagia following LARS suggests esophageal obstruction. In this setting, esophageal obstruction most frequently results from a recurrent hiatal hernia or a slipped fundoplication. A UGI and EGD should be the initial study obtained in these patients. If a clear anatomic abnormality is visualized (**Fig. 12**), reoperation can be performed without further investigation. If concurrent GERD symptoms are present, ambulatory pH testing should be performed. To achieve resolution of symptoms, reoperation is almost always necessary in these patients.

Some patients experience no improvement, or even worsened symptoms, following LARS. In these patients, poor operative technique is generally the culprit. An incorrectly constructed fundoplication (generally created out of the body of the stomach and not the fundus) fails to treat GER and can cause new-onset gastroesophageal obstructive symptoms. Failure to completely excise the sac of a hiatal or PEH frequently leads to an early recurrence of hiatal hernia. In the authors' experience, patients who present with persistent symptoms or early recurrence of symptoms following LARS typically require operative management. Following appropriate evaluation with pH testing, manometry, UGI, and EGD, patients should undergo operative

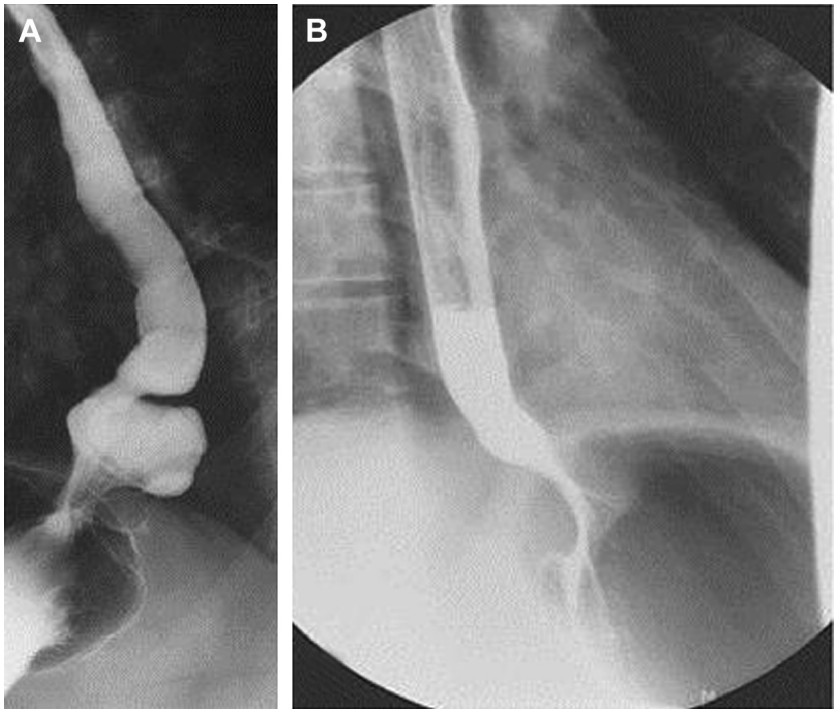

Fig. 12. Esophagram provides excellent assessment of anatomic abnormalities that can cause postoperative dysphagia. (*A*) Patient with dysphagia secondary to postoperative hiatal hernia. (*B*) Normal anatomic appearance of 360° fundoplication. (*From* Oelschlager BK, Eubanks TR, Pellegrini CA. Hiatal hernis and gastroesophageal reflux disease. In: Townsend CM, Beauchamp RD, Evers MB, et al, editors. Sabiston Textbook of Surgery. 19th edition. Philadelphia: Elsevier; 2012; with permission.)

correction of the anatomic problem with creation of an appropriately constructed fundoplication.

It is important to understand that reoperative antireflux surgery comes with higher stakes than first-time antireflux surgery. Tissues are less pliable, making it more challenging for surgeons to construct an effective antireflux valve. In addition, adhesions and less visible tissue planes contribute to increased rates of intraoperative injury of the stomach and esophagus. Consequently, we have a higher threshold to perform reoperative antireflux surgery. With the exceptions described earlier, the authors reserve reoperation for patients with significant symptoms despite maximal nonoperative management.

SUMMARY

Operative treatment of GERD has become more common since the introduction of LARS. Careful patient selection based on symptoms, response to medical therapy, and preoperative testing will optimize the chances for effective and durable postoperative control of symptoms. Complications of the LARS are rare and generally can be managed without reoperation. When reoperation is necessary for failed antireflux surgery, it should be performed by high-volume gastroesophageal surgeons.

REFERENCES

1. Galmiche JP, Janssens J. The pathophysiology of gastro-oesophageal reflux disease: an overview. Scand J Gastroenterol Suppl 1995;211:7–18.
2. Moore JM, Vaezi MF. Extraesophageal manifestations of gastroesophageal reflux disease: real or imagined? Curr Opin Gastroenterol 2010;26(4):389–94.
3. Chang AB, Lasserson TJ, Kiljander TO, et al. Systematic review and meta-analysis of randomised controlled trials of gastro-oesophageal reflux interventions for chronic cough associated with gastro-oesophageal reflux. BMJ 2006; 332(7532):11–7.
4. Vaezi MF, Richter JE. Twenty-four-hour ambulatory esophageal pH monitoring in the diagnosis of acid reflux-related chronic cough. South Med J 1997;90(3): 305–11.
5. Waring JP, Lacayo L, Hunter J, et al. Chronic cough and hoarseness in patients with severe gastroesophageal reflux disease. Diagnosis and response to therapy. Dig Dis Sci 1995;40(5):1093–7.
6. Mainie I, Tutuian R, Shay S, et al. Acid and non-acid reflux in patients with persistent symptoms despite acid suppressive therapy: a multicentre study using combined ambulatory impedance-pH monitoring. Gut 2006;55(10): 1398–402.
7. Vela MF. Non-acid reflux: detection by multichannel intraluminal impedance and pH, clinical significance and management. Am J Gastroenterol 2009;104(2):277–80.
8. Wassenaar E, Johnston N, Merati A, et al. Pepsin detection in patients with laryngopharyngeal reflux before and after fundoplication. Surg Endosc 2011; 25(12):3870–6.
9. Worrell SG, DeMeester SR, Greene CL, et al. Pharyngeal pH monitoring better predicts a successful outcome for extraesophageal reflux symptoms after antireflux surgery. Surg Endosc 2013;27(11):4113–8.
10. Ducoloné A, Vandevenne A, Jouin H, et al. Gastroesophageal reflux in patients with asthma and chronic bronchitis. Am Rev Respir Dis 1987;135(2):327–32.
11. Davis MV. Relationship between pulmonary disease, hiatal hernia, and gastroesophageal reflux. N Y State J Med 1972;72(8):935–8.
12. Bowrey DJ, Peters JH, DeMeester TR. Gastroesophageal reflux disease in asthma: effects of medical and surgical antireflux therapy on asthma control. Ann Surg 2000;231(2):161–72.
13. Bandeira CD, Rubin AS, Cardoso PF, et al. Prevalence of gastroesophageal reflux disease in patients with idiopathic pulmonary fibrosis. J Bras Pneumol 2009; 35(12):1182–9.
14. Raghu G, Freudenberger TD, Yang S, et al. High prevalence of abnormal acid gastro-oesophageal reflux in idiopathic pulmonary fibrosis. Eur Respir J 2006; 27(1):136–42.
15. Salvioli B, Belmonte G, Stanghellini V, et al. Gastro-oesophageal reflux and interstitial lung disease. Dig Liver Dis 2006;38(12):879–84.
16. Tobin RW, Pope CE, Pellegrini CA, et al. Increased prevalence of gastroesophageal reflux in patients with idiopathic pulmonary fibrosis. Am J Respir Crit Care Med 1998;158(6):1804–8.
17. Allaix ME, Fisichella PM, Noth I, et al. Idiopathic pulmonary fibrosis and gastroesophageal reflux. Implications for treatment. J Gastrointest Surg 2014;18(1): 100–4 [discussion: 104–5].
18. Fahim A, Crooks M, Hart SP. Gastroesophageal reflux and idiopathic pulmonary fibrosis: a review. Pulm Med 2010;2011:e634613.

19. Sweet MP, Patti MG, Leard LE, et al. Gastroesophageal reflux in patients with idiopathic pulmonary fibrosis referred for lung transplantation. J Thorac Cardiovasc Surg 2007;133(4):1078–84.
20. Hershcovici T, Jha LK, Johnson T, et al. Systematic review: the relationship between interstitial lung diseases and gastro-oesophageal reflux disease. Aliment Pharmacol Ther 2011;34(11–12):1295–305.
21. Lee JS, Ryu JH, Elicker BM, et al. Gastroesophageal reflux therapy is associated with longer survival in patients with idiopathic pulmonary fibrosis. Am J Respir Crit Care Med 2011;184(12):1390–4.
22. Kilduff CE, Counter MJ, Thomas GA, et al. Effect of acid suppression therapy on gastroesophageal reflux and cough in idiopathic pulmonary fibrosis: an intervention study. Cough 2014;10:4.
23. Raghu G, Yang ST, Spada C, et al. Sole treatment of acid gastroesophageal reflux in idiopathic pulmonary fibrosis: a case series. Chest 2006;129(3):794–800.
24. Linden PA, Gilbert RJ, Yeap BY, et al. Laparoscopic fundoplication in patients with end-stage lung disease awaiting transplantation. J Thorac Cardiovasc Surg 2006;131(2):438–46.
25. D'Ovidio F, Keshavjee S. Gastroesophageal reflux and lung transplantation. Dis Esophagus 2006;19(5):315–20.
26. Kilic A, Shah AS, Merlo CA, et al. Early outcomes of antireflux surgery for United States lung transplant recipients. Surg Endosc 2013;27(5):1754–60.
27. O'Halloran EK, Reynolds JD, Lau CL, et al. Laparoscopic Nissen fundoplication for treating reflux in lung transplant recipients. J Gastrointest Surg 2004;8(1):132–7.
28. Hoppo T, Jarido V, Pennathur A, et al. Antireflux surgery preserves lung function in patients with gastroesophageal reflux disease and end-stage lung disease before and after lung transplantation. Arch Surg 2011;146(9):1041–7.
29. Wong RK, Hanson DG, Waring PJ, et al. ENT manifestations of gastroesophageal reflux. Am J Gastroenterol 2000;95(Suppl 8):S15–22.
30. Luketina RR, Koch OO, Köhler G, et al. Obesity does not affect the outcome of laparoscopic antireflux surgery. Surg Endosc 2014. [Epub ahead of print].
31. Mion F, Dargent J. Gastro-oesophageal reflux disease and obesity: pathogenesis and response to treatment. Best Pract Res Clin Gastroenterol 2014;28(4):611–22.
32. Perez AR, Moncure AC, Rattner DW. Obesity adversely affects the outcome of antireflux operations. Surg Endosc 2001;15(9):986–9.
33. Tekin K, Toydemir T, Yerdel MA. Is laparoscopic antireflux surgery safe and effective in obese patients? Surg Endosc 2012;26(1):86–95.
34. Booth MI, Stratford J, Jones L, et al. Randomized clinical trial of laparoscopic total (Nissen) versus posterior partial (Toupet) fundoplication for gastro-oesophageal reflux disease based on preoperative oesophageal manometry. Br J Surg 2008;95(1):57–63.
35. Oleynikov D, Eubanks TR, Oelschlager BK, et al. Total fundoplication is the operation of choice for patients with gastroesophageal reflux and defective peristalsis. Surg Endosc 2002;16(6):909–13.
36. Fein M, Seyfried F. Is there a role for anything other than a Nissen's operation? J Gastrointest Surg 2010;14(Suppl 1):S67–74.
37. Shan CX, Zhang W, Zheng XM, et al. Evidence-based appraisal in laparoscopic Nissen and Toupet fundoplications for gastroesophageal reflux disease. World J Gastroenterol 2010;16(24):3063–71.
38. Oelschlager BK, Yamamoto K, Woltman T, et al. Vagotomy during hiatal hernia repair: a benign esophageal lengthening procedure. J Gastrointest Surg 2008; 12(7):1155–62.

39. Markar SR, Karthikesalingam AP, Hagen ME, et al. Robotic vs laparoscopic Nissen fundoplication for gastro-oesophageal reflux disease: systematic review and meta-analysis. Int J Med Robot 2010;6(2):125–31.
40. Stefanidis D, Hope WW, Kohn GP, et al. Guidelines for surgical treatment of gastroesophageal reflux disease. Surg Endosc 2010;24(11):2647–69.
41. Wang YR, Dempsey DT, Richter JE. Trends and perioperative outcomes of inpatient antireflux surgery in the United States, 1993-2006. Dis Esophagus 2011; 24(4):215–23.
42. Richter JE. Gastroesophageal reflux disease treatment: side effects and complications of fundoplication. Clin Gastroenterol Hepatol 2013;11(5):465–71 [quiz: e39].
43. Cadiere GB, Himpens J, Rajan A, et al. Laparoscopic Nissen fundoplication: laparoscopic dissection technique and results. Hepatogastroenterology 1997; 44(13):4–10.
44. Bizekis C, Kent M, Luketich J. Complications after surgery for gastroesophageal reflux disease. Thorac Surg Clin 2006;16(1):99–108.
45. Collet D, Cadière GB. Conversions and complications of laparoscopic treatment of gastroesophageal reflux disease. Formation for the Development of Laparoscopic Surgery for Gastroesophageal Reflux Disease Group. Am J Surg 1995; 169(6):622–6.
46. Hunter JG, Smith CD, Branum GD, et al. Laparoscopic fundoplication failures: patterns of failure and response to fundoplication revision. Ann Surg 1999; 230(4):595–604 [discussion: 604–6].
47. Watson DI, de Beaux AC. Complications of laparoscopic antireflux surgery. Surg Endosc 2001;15(4):344–52.
48. Odabasi M, Abuoglu HH, Arslan C, et al. Asymptomatic partial splenic infarction in laparoscopic floppy Nissen fundoplication and brief literature review. Int Surg 2014;99(3):291–4.
49. Bredenoord AJ, Draaisma WA, Weusten BL, et al. Mechanisms of acid, weakly acidic and gas reflux after anti-reflux surgery. Gut 2008;57(2):161–6.
50. Kessing BF, Broeders JAJL, Vinke N, et al. Gas-related symptoms after antireflux surgery. Surg Endosc 2013;27(10):3739–47.
51. Spechler SJ, Lee E, Ahnen D, et al. Long-term outcome of medical and surgical therapies for gastroesophageal reflux disease: follow-up of a randomized controlled trial. JAMA 2001;285(18):2331–8.
52. Lundell L, Miettinen P, Myrvold HE, et al. Seven-year follow-up of a randomized clinical trial comparing proton-pump inhibition with surgical therapy for reflux oesophagitis. Br J Surg 2007;94(2):198–203.
53. Lundell L, Miettinen P, Myrvold HE, et al. Comparison of outcomes twelve years after antireflux surgery or omeprazole maintenance therapy for reflux esophagitis. Clin Gastroenterol Hepatol 2009;7(12):1292–8.
54. Dallemagne B, Weerts J, Markiewicz S, et al. Clinical results of laparoscopic fundoplication at ten years after surgery. Surg Endosc 2006;20(1):159–65.
55. Oelschlager BK, Eubanks TR, Oleynikov D, et al. Symptomatic and physiologic outcomes after operative treatment for extraesophageal reflux. Surg Endosc 2002;16(7):1032–6.
56. Lamb PJ, Myers JC, Jamieson GG, et al. Long-term outcomes of revisional surgery following laparoscopic fundoplication. Br J Surg 2009;96(4):391–7.
57. Grant AM, Wileman SM, Ramsay CR, et al. Minimal access surgery compared with medical management for chronic gastro-oesophageal reflux disease: UK collaborative randomised trial. BMJ 2008;337:a2664.

58. Mahon D, Rhodes M, Decadt B, et al. Randomized clinical trial of laparoscopic Nissen fundoplication compared with proton-pump inhibitors for treatment of chronic gastro-oesophageal reflux. Br J Surg 2005;92(6):695–9.
59. Cookson R, Flood C, Koo B, et al. Short-term cost effectiveness and long-term cost analysis comparing laparoscopic Nissen fundoplication with proton-pump inhibitor maintenance for gastro-oesophageal reflux disease. Br J Surg 2005; 92(6):700–6.