Endoscopic Dilatation, Heller Myotomy, and Peroral Endoscopic Myotomy

Treatment Modalities for Achalasia

Marco E. Allaix, MD, PhD[a], Marco G. Patti, MD[b,*]

KEYWORDS

• Achalasia • Endoscopic botulinum toxin injection • Pneumatic dilatation • Myotomy • Fundoplication • POEM • Dysphagia • Reflux

KEY POINTS

- Endoscopic botulinum toxin injection (EBTI) should be used only in patients who cannot be treated with pneumatic dilatation (PD) or surgery.
- The short-term results of PD are similar to those of surgery. The available literature, however, suggests that the effect of surgery is for a longer duration.
- Laparoscopic Heller myotomy (LHM) is the approach of choice for achalasia in most centers.
- A partial fundoplication is associated with a lower risk of postoperative reflux compared with myotomy alone.
- A partial fundoplication achieves better functional results than a total fundoplication, with lower rates of postoperative dysphagia.
- There are no significant differences in reflux control after partial anterior or partial posterior fundoplication.
- Peroral endoscopic myotomy (POEM) is a novel promising approach to achalasia with good short-term outcomes.

INTRODUCTION

Esophageal achalasia is a primary esophageal motility disorder characterized by the absence of esophageal peristalsis and failure of the lower esophageal sphincter (LES) to relax in response to swallowing. In about 50% of patients, the LES is

Conflict of Interest: The authors have no conflicts of interest to declare.

[a] Department of Surgical Sciences, University of Torino, Corso A. M. Dogliotti 14, Torino 10126, Italy; [b] Center for Esophageal Diseases, Department of Surgery, University of Chicago Pritzker School of Medicine, 5841 South Maryland Avenue, MC 5095, Room G-207, Chicago, IL 60637, USA

* Corresponding author.

E-mail address: mpatti@surgery.bsd.uchicago.edu

Surg Clin N Am 95 (2015) 567–578

http://dx.doi.org/10.1016/j.suc.2015.02.009 **surgical.theclinics.com**

0039-6109/15/$ – see front matter © 2015 Elsevier Inc. All rights reserved.

hypertensive. These abnormalities lead to impaired emptying of food from the esophagus into the stomach with consequent food stasis.

This article reviews the most clinically relevant aspects of both diagnosis and management of patients with achalasia, focusing on the several treatment modalities available.

PATHOPHYSIOLOGY

Esophageal achalasia is a rare disease that can occur at any age, even though it is more frequent between 30 and 60 years.[1] The cause is unknown; however, the following 2 theories have been proposed:

1. A degenerative disease of the neurons
2. Infections of the neurons by a virus or another agent, such as *Trypanosoma cruzi.*

In patients with achalasia, the degeneration of the myenteric plexus leads to loss of the postganglionic inhibitory neurons, which mediate LES relaxation by producing nitric oxide and vasoactive intestinal polypeptide. As a consequence, there is unopposed cholinergic stimulation by postganglionic cholinergic neurons, which increases LES resting pressure and decreases LES relaxation. There is no propagation of peristaltic waves in response to swallowing, but rather the presence of simultaneous contractions.[2]

CLINICAL PRESENTATION

- Dysphagia is present in about 95% of patients with achalasia. Often, it occurs for both solids and liquids.
- Regurgitation of retained and undigested food and saliva is the second most frequent symptom, being reported by about 60% of patients. Aspiration of esophageal contents can lead to respiratory symptoms including cough, hoarseness, wheezing, and recurrent episodes of pneumonia.
- Heartburn is present in about 40% of patients, and it is secondary to stasis and fermentation of undigested food in the esophageal lumen.
- Chest pain occurs in about 40% of patients, usually at the time of a meal, and it is probably caused by esophageal distention.

DIAGNOSTIC PROCEDURES

- Upper endoscopy is usually the first test that is performed in patients presenting with dysphagia for ruling out a stricture secondary to gastroesophageal reflux or cancer.
- Barium swallow shows narrowing at the level of the gastroesophageal junction, the presence of an air-fluid level secondary to slow esophageal emptying, and tertiary contractions of the esophageal wall (**Fig. 1**). The barium swallow defines both diameter and axis of the esophagus and reveals the presence of associated pathologic findings, such as an epiphrenic diverticulum.
- Esophageal manometry is the gold standard for the diagnosis of achalasia. Absence of esophageal peristalsis and impaired relaxation of the LES in response to wet swallows are the key criteria for the diagnosis of achalasia. With the adoption of high-resolution manometry (HRM), a new classification of esophageal achalasia has been proposed with 3 distinct manometric patterns: type I, classic, with minimal esophageal pressurization; type II, with panesophageal pressurization; and type III, with spasm, characterized by rapidly propagated esophageal pressurization attributable to spastic contractions (**Fig. 2**).[3]

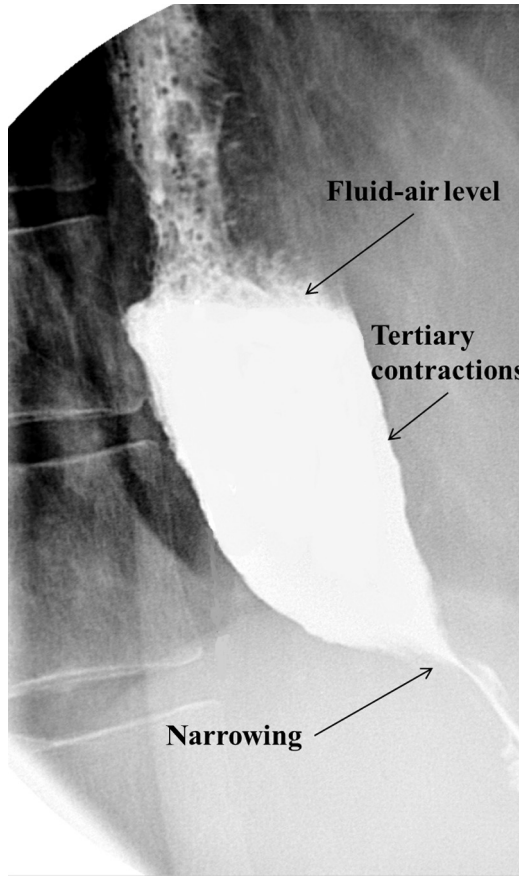

Fig. 1. Barium swallow.

Patients with type II achalasia have the best prognosis, because they are significantly more likely to respond to PD or LHM than patients with type I or type III achalasia.[4] These 3 subtypes may represent 3 distinct pathophysiologic conditions, thus explaining some of the observed variability in treatment response.

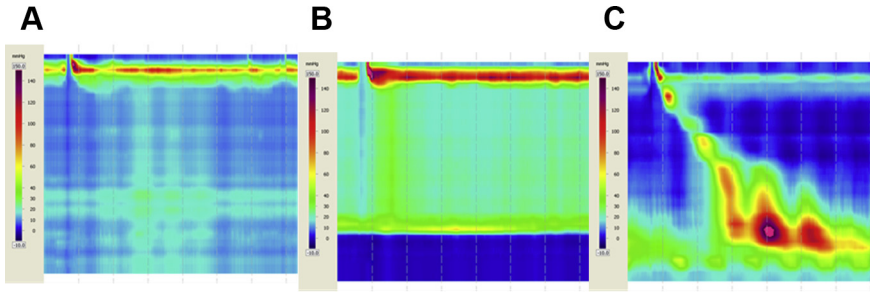

Fig. 2. Achalasia patterns according to the Chicago classification: (*A*) type I, (*B*) type II, (*C*) type III.

- Ambulatory pH monitoring differentiates between gastroesophageal reflux and achalasia when the diagnosis is uncertain in untreated patients who complain of heartburn, and it assesses the presence of pathologic reflux after treatment.

TREATMENT

Because the pathogenesis of achalasia is unknown, treatment aims to improve esophageal emptying and the patient's symptoms by relieving the functional obstruction at the level of the gastroesophageal junction. The following treatment modalities are available:

1. EBTI
2. PD
3. LHM
4. POEM

Endoscopic Botulinum Toxin Injection

EBTI into the LES decreases the LES pressure by preventing acetylcholine release at the level of the cholinergic synapses. This treatment option is safe and achieves immediate symptom relief or improvement in about 80% of patients.[5] Lack of an initial symptomatic response to EBTI and residual LES pressure of 18 mm Hg or greater after EBTI are associated with a poor response. The effect progressively declines over time, with only about 40% patients being symptom free at 12 months.[6] Most patients need repeated EBTIs, with short-lasting clinical benefits, probably secondary to the formation of antibodies.[7–9]

Transmural inflammation and fibrosis frequently occur at the level of the gastroesophageal junction after repeated EBTI, making a subsequent LHM more challenging and the outcome less predictable.[10,11] Horgan and colleagues[12] analyzed the effect of EBTI on the technical aspects and outcome of LHM in 57 patients with achalasia. Of these patients, 15 had received 1 or more EBTIs preoperatively. Dissection of the submucosal plane was difficult in 8 patients (53.3%), and esophageal perforation occurred in 2 cases (13.3%). Among the 42 patients who had not received any EBTI, difficulty in identifying or following the submucosal plane was encountered in 3 patients (7%), and esophageal perforation occurred in 1 patient only (2.4%). All mucosal injuries were repaired laparoscopically, with no clinical sequelae.

Smith and colleagues[11] reported the outcomes in 209 patients with achalasia undergoing HM, with most cases completed laparoscopically (98%). Of these, 154 had undergone EBTI and/or PD preoperatively (100 PD only, 33 EBTI only, and 21 both). Intraoperative complications were more common in the endoscopically treated group, with gastroesophageal perforation being the most common complication (9.7% vs 3.6%). Of note, esophageal perforation was experienced only by patients who had undergone prior endoscopic treatment. Postoperative complications, primarily severe dysphagia, and pulmonary complications were more common after endoscopic treatment (10.4% vs 5.4%). The rate of myotomy failure was higher in the endoscopically treated group (19.5% vs 10.1%).

Compared with PD, ETBI is associated with significantly higher symptom recurrence rates at 12 months. Vaezi and colleagues[13] randomized patients who had symptoms of achalasia to EBTI (22 patients) or PD (20 patients). Symptom scores were assessed at baseline and at 1, 3, 6, 9, and 12 months after treatment. Esophageal manometry was performed before treatment, while a barium esophagram was

obtained initially and at 1, 6, and 12 months posttreatment. At 12 months, 14 of 20 (70%) patients who received PD and 7 of 22 (32%) patients who received EBTI showed symptom remission ($P = .017$).

Similarly, EBTI is less effective than LHM at 2-year follow-up. In 2004, Zaninotto and colleagues[14] randomized 40 patients with achalasia to 2 EBTIs 1 month apart (100 units each) and 40 patients with achalasia to LHM. At 2-year follow-up, 34% of patients who received EBTI were asymptomatic compared with 87.5% of those who received LHM.

Based on the evidence currently available, EBTI should be used only in patients who are not candidates for more effective therapeutic options, such as PD and LHM.

Pneumatic Dilatation

PD is currently the most effective nonsurgical treatment of achalasia.[15] This procedure has been standardized with the introduction of Rigiflex balloons (Boston Scientific Corporation, MA, USA). A 30-mm, 35-mm, or 40-mm balloon is inserted fluoroscopically over a guidewire and inflated at the level of the gastroesophageal junction to achieve progressive and controlled tearing of the muscle fibers. Esophageal perforation after PD is the most common complication, with a rate that ranges between 0% and 8%.[5] PD relieves or improves dysphagia in about 85% of patients at 1 month after the procedure, while it has little effect on chest pain.[16] PD success rate steadily declines over time to less than 60% after 3 years. Additional PDs are necessary in about 25% of patients, with poorer results in those with persistent or early recurrent dysphagia after the first PD session. After PD, abnormal gastroesophageal reflux is detected by 24-hour pH monitoring in up to 33% of the patients studied.[17–19]

Eckardt and colleagues[20] reported the late results of a prospective study including 54 patients with achalasia treated with PD and followed up for a median of 13.8 years. A single PD resulted in a 5-year remission rate of 40% and a 10-year remission rate of 36%. Repeated PDs only mildly improved the clinical response. Patients undergoing more than 1 PD had a slightly better outcome after the second dilatation: the 5-year remission rate was 6% after the first and 28% after the second PD. Patients requiring 3 PDs did not have a better long-term response after the second PD compared with after the first PD. After 5 years, only 12% and 6% remained in clinical remission after the first and second PD, respectively. A third PD improved the clinical remission rate to 35% at 5 years but to only 19% at 10 years. Significant predictors of favorable long-term outcome were age greater than 40 years ($P = .0014$) and a post-PD LES pressure of less than 10 mm Hg ($P = .0001$).

Therefore, young patients (<40 years) and those who do not respond to a single PD should be referred for LHM.

The past 3 decades have witnessed a progressive shift from PD to surgery for the treatment of achalasia. In the 1980s and in the 1990s, PD was considered the main treatment modality for the patient with achalasia, while surgery had a secondary role in case of PD failure (perforation or recurrent dysphagia). The beginning of this century has witnessed a progressive greater use of minimally invasive surgery for the treatment of achalasia.[21,22]

Laparoscopic Heller Myotomy

In 1991, the first minimally invasive esophageal myotomy was performed in the United States by a left thoracoscopic approach. Pellegrini and colleagues[23] treated 17 patients with achalasia by a thoracoscopic Heller myotomy (15 patients) or LHM (2 patients). The mean hospital stay was 3 days; no deaths or major complications

occurred. With regard to dysphagia, final results were excellent in 12 patients (70%), good in 2 patients (12%), fair in 2 patients (12%), and poor in 1 patient (6%). In 3 patients the myotomy was not carried far enough onto the stomach; in 2 patients dysphagia resolved after a second myotomy was performed laparoscopically. Postoperative esophageal manometry was done in 8 patients, and a mean LES pressure of 10 $\pm$ 2 mm Hg was obtained. Ambulatory 24-hour pH monitoring was performed in 4 patients 1 to 13 months after the operation, showing abnormal acid exposure in 2 cases.

The quick introduction and widespread use of the laparoscopic approach to many digestive diseases has raised the debate about the best minimally invasive approach to achalasia: thoracoscopic or laparoscopic? For instance, Patti and colleagues[24] compared 30 patients with achalasia who had undergone thoracoscopic Heller myotomy with 30 patients who had an LHM with a Dor fundoplication. There were no differences between the 2 groups in terms of demographic data, symptoms, and manometric findings. Pathologic gastroesophageal reflux was present at the preoperative pH monitoring in 2 patients who had undergone laparoscopy. The mean hospital stay was shorter after laparoscopic surgery (42 hours vs 84 hours). Similar results were achieved in terms of relief of dysphagia, with excellent (no dysphagia) or good (dysphagia less than once a week) outcomes in 87% of patients in the thoracoscopic group and in 90% of patients in the laparoscopic group. Esophageal manometry and 24-hour pH monitoring were performed 2 to 3 months after surgery in 10 patients in each group. No changes in esophageal body motility were noted in either group of patients. Postoperative 24-hour pH monitoring showed pathologic gastroesophageal reflux in 6 (60%) of 10 patients in the thoracoscopic group and in 1 (10%) of 10 patients in the laparoscopic group. The 2 patients in the laparoscopic group who had preoperative evidence of pathologic reflux had normal reflux scores postoperatively.

LHM with partial fundoplication has several advantages when compared with thoracoscopic Heller myotomy. First, the thoracoscopic approach is more challenging because (1) it requires the use of a double-lumen endotracheal tube and the lateral decubitus position of the patient, (2) the distal extent of the myotomy on the gastric wall is difficult, and (3) intraoperative upper endoscopy is necessary to check the completion of the LES myotomy. Second, the postoperative course after LHM is simpler, with less pain and shorter hospital stay, mainly because a chest tube is not necessary. Third, even though both approaches are similar in relieving dysphagia, the incidence of postoperative pathologic gastroesophageal reflux (by 24-hour pH monitoring) is lower after LHM and partial fundoplication. As patients are often asymptomatic, pH monitoring is recommended to assess the presence of reflux postoperatively.[25] Finally, the fundoplication may correct pathologic reflux when present preoperatively because of a prior PD.

LHM alone is associated with postoperative reflux in about 50% to 60% of patients. Richards and colleagues[26] conducted a prospective randomized clinical trial comparing 21 patients treated by LHM alone and 22 patients undergoing LHM and Dor fundoplication. Patients underwent esophageal manometry and 24-hour pH study at 6 months after surgery. Pathologic gastroesophageal reflux was present in 10 of 21 patients (47.6%) after LHM alone and in 2 of 22 patients (9.1%) after LHM plus Dor (P = .005). Postoperative LES pressure and postoperative dysphagia score were similar in the 2 groups.

Therefore, LHM with partial fundoplication is currently the preferred treatment modality for achalasia in most centers in Europe and the United States, with durable relief of dysphagia in most patients at 5 years[27] and beyond.[28,29]

Briefly, the operation consists of the following steps:

- Division of the gastrohepatic ligament.
- Dissection of the right and left pillars of the crus from the anterior wall of the esophagus after division of the phrenoesophageal ligament. No posterior dissection is necessary if a partial anterior fundoplication is planned.
- Division of the short gastric vessels.
- Excision of the fat pad to expose the gastroesophageal junction, after identification of the anterior vagus nerve.
- Myotomy on the right side of the esophagus in the 11-o'clock position; it is extended proximally for about 6 cm above the gastroesophageal junction and distally for 2.5 to 3 cm onto the gastric wall.
- Construction of a partial fundoplication to relieve dysphagia and prevent gastroesophageal reflux.

A partial fundoplication added to the myotomy is associated with lower rates of postoperative dysphagia than a total fundoplication. Rebecchi and colleagues[30] randomized 144 patients with achalasia to LHM and anterior partial fundoplication or to LHM and total fundoplication. With a mean follow-up of 125 months, they found no significant differences in postoperative pathologic reflux, whereas a significantly higher dysphagia rate was observed after total fundoplication (2.8% vs 15%; $P<.001$).

Based on the evidence currently available, both partial anterior and partial posterior fundoplication achieve similar results in terms of control of reflux after LHM. In 2012, Rawlings and colleagues[31] published the results of a multicenter, prospective, randomized controlled trial aiming to compare Dor versus Toupet fundoplication after LHM in patients with achalasia in terms of reflux control at 6 to 12 months. A total of 60 patients (36 Dor and 24 Toupet fundoplications) were available for analysis. The analysis of 24-hour pH monitoring in 43 patients (24 Dor and 19 Toupet) showed similar reflux scores and total acid exposure between the 2 groups.

Some investigators argue that partial posterior fundoplication should be the antireflux procedure of choice because it may be more effective in preventing reflux and keeps the distal edges of the myotomy separated.[32] Others prefer the partial anterior fundoplication because it is simpler to perform and covers the exposed esophageal mucosa (**Fig. 3**).

Increased age and esophageal diameter do not adversely influence the outcome of LHM. For instance, Salvador and colleagues[33] analyzed the influence of age on the surgical outcomes of 571 patients with achalasia treated by LHM and Dor fundoplication. Patients were classified into 3 age groups: group A ($\leq$45 years), group B (45–70 years), and group C ($\geq$70 years). A similar rate of esophageal perforation in the 3 groups of patients and a trend toward a longer postoperative hospital stay for older patients was reported. The treatment failure rate based on the postoperative symptom score did not differ significantly between the 3 groups of patients: 31 failures in group A (10.1%), 19 in group B (8.4%), and 3 in group C (7.5%; $P = .80$).

Sweet and colleagues[34] divided 113 patients with achalasia into 4 groups according to the maximal diameter of the esophageal lumen and the shape of the esophagus: group A, diameter less than 4.0 cm (46 patients); group B, esophageal diameter 4.0 to 6.0 cm (32 patients); group C, diameter greater than 6.0 cm and straight axis (23 patients); and group D, diameter greater than 6.0 cm and sigmoid-shaped esophagus (12 patients). All patients underwent LHM and Dor fundoplication. The median length of follow-up was 45 months (range, 7 months–12.5 years). Excellent or good results were obtained in 89% of group A and 91% of groups B, C, and D. Postoperative

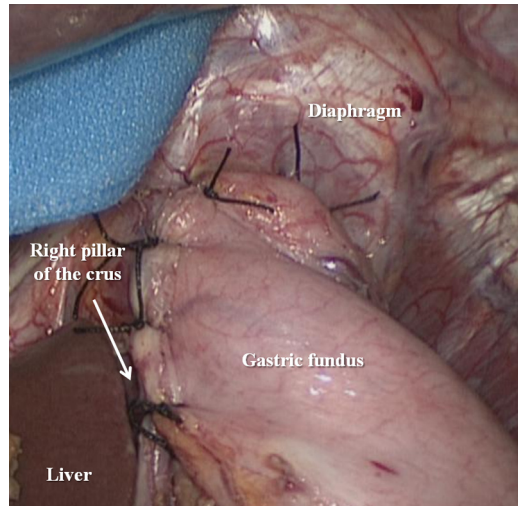

Fig. 3. Partial anterior fundoplication.

PDs were necessary in 23 patients (20%) to treat dysphagia, whereas a second myotomy was performed in 5 patients (4%). No patient required an esophagectomy.

Therefore, LHM can also be performed in elderly patients and in those with a dilated and sigmoid esophagus, whereas esophagectomy should be considered only in case of failure of LHM.

At present, even though there is evidence supporting the long-lasting results of surgery, the role of PD and LHM is under debate. In 2011, a randomized, multicenter European trial[35] aimed to compare the outcomes at 2-year follow-up in 201 patients with untreated esophageal achalasia: 95 underwent PD and 106 underwent LHM and Dor fundoplication. The primary outcome was therapeutic success (defined as a drop in the Eckardt score to $\leq$3) at the yearly follow-up assessment. The secondary outcomes included the need for re-treatment, LES pressure, esophageal emptying on a timed barium esophagram, quality of life, and the complications rate.

The investigators found no significant difference in the outcome between PD and LHM (at 1 year: PD 90% vs LHM 93%; at 2 years: PD 86% vs LHM 90%). At 2-year follow-up, LES pressure was similar in the 2 groups; no differences were observed in terms of esophageal emptying and quality of life. Esophageal perforation occurred in 4% of the patients who underwent PD and in 12% of the patients who underwent LHM. The study confirmed the superiority of LHM for patients younger than 40 years.

Even though in this study the short-term results of PD and LHM were similar, longer follow-up is needed to support the equivalence of these procedures.

Per Oral Endoscopic Myotomy

Recently, a novel procedure for the treatment of achalasia termed peroral endoscopic myotomy has been proposed. POEM is an endoscopic procedure performed under general anesthesia. Briefly, saline with indigocarmine and epinephrine is injected in the submucosal layer approximately 12 to 13 cm proximal to the gastroesophageal junction at the 2-o'clock position. Then, a 2-cm longitudinal incision is made on the mucosal surface and the submucosal space is entered. A submucosal tunnel is created on the anterior wall of the esophagus extending down onto the first 3 cm of

the stomach. After completing the submucosal tunnel, the circular muscular fibers are selectively sectioned beginning 2 to 3 cm distal to the mucosal entry and extending about 3 cm distal to the gastroesophageal junction. Hemostatic clips are used to close the site of the mucosal entry.

The first report of POEM in 17 consecutive patients with achalasia was published by Inoue and colleagues[36] in 2010. Mean length of the myotomy was 8.1 cm (about 6 cm on the esophagus and 2 cm on the proximal stomach). In all cases, the resting LES pressure significantly decreased after POEM (from mean 52.4 mm Hg to 19.9 mm Hg; $P = .0001$). With a mean follow-up of 5 months, no patient had recurrent dysphagia, while 1 patient developed grade B esophagitis according to Los Angeles classification. No patient underwent further endoscopic or surgical procedures during the follow-up.

In 2012, Swanstrom and colleagues[37] published the outcomes in 18 patients with achalasia treated with POEM. Median length of myotomy was 9 cm. The investigators reported 3 intraoperative complications, including 2 gastric mucosotomies and 1 full-thickness esophagotomy, which were all repaired endoscopically with no postoperative sequelae. Median hospital stay was 1 day. At a mean follow-up of 11.4 months, relief of dysphagia was reported in all patients, with a significant drop of the median Eckardt score from 6 to 0. Postoperative upper endoscopy was performed in 14 patients, showing esophagitis in 4 cases (28%). Postoperative HRM performed in 12 patients showed significant improvements in LES resting pressure (from 45 to 16.8 mm Hg; $P = .009$). The 24-hour pH monitoring performed in 13 patients objectively diagnosed pathologic gastroesophageal reflux in 46% of cases.

In 2013, von Renteln and colleagues[38] reported the results of a prospective, international, multicenter trial including 70 patients with achalasia undergoing POEM in 5 centers in Europe and North America. The mean length of the myotomy was 13 cm (range, 5–23 cm). The number of patients available for analysis progressively decreased during the follow-up period from 70 at 3 months, to 61 at 6 months, and 51 at 1 year. At 3 months after POEM, esophageal manometry was obtained in 61 patients: mean LES pressure significantly decreased from 28 to 9 mm Hg ($P<.001$). An upper endoscopy revealed the presence of esophagitis in 42% of patients. The symptom remission rate at 3, 6, and 12 months was 97%, 89%, and 82%, respectively. Symptoms of gastroesophageal reflux were reported by 37% of patients at 12 months after the procedure. However, no objective evaluation of reflux by 24-hour pH monitoring was performed.

Only a few nonrandomized studies comparing POEM and LHM have been published. For instance, Hungness and colleagues[39] reported the short-term outcomes in 18 patients with achalasia undergoing POEM and in 55 patients treated by LHM. Length of the myotomy, complication rate, and length of hospital stay were similar in the 2 groups. At 6 weeks after POEM, normalization of esophagogastric junction pressure and contrast column height were showed by esophageal HRM and timed esophagram, respectively. Postoperative upper endoscopy was obtained in 15 patients at a median follow-up interval of 1.5 (1.5–12) months after POEM, showing esophagitis in 5 (33%) patients. Treatment success, defined as Eckardt score less than or equal to 3 after POEM, was achieved in 16 (89%) patients at median 6-month follow-up.

Recently, a comparative study by Bhayani and colleagues[40] including 64 patients with achalasia undergoing LHM (42% with Toupet and 58% with Dor fundoplication) and 37 undergoing POEM showed significantly longer median operative time (149 vs 120 min, $P<.001$) and median hospitalization (2.2 vs 1.1 days, $P<.0001$) among patients undergoing LHM, with no differences in postoperative morbidity. Patients

underwent esophageal manometry at a median of 6.8 (range, 5.7–10) months. Significant improvement in LES pressure was observed in both groups of patients postoperatively; however, LES resting pressure was lower after LHM than after POEM (7.1 vs 16 mm Hg, $P = .006$). Abnormal acid exposure documented by 24-hour pH monitoring was observed in 39% of patients after POEM and in 32% of patients after LHM. At 6-month follow-up, 29% of patients who underwent LHM reported dysphagia to solids compared with none of the patients who underwent POEM ($P = .001$).

Based on the limited evidence available, POEM seems to be a promising new procedure. Even though it has been claimed that POEM has the surgical efficacy of an LHM with the recovery profile of an endoscopy,[41] there are some concerns about this new technique:

1. Superior endoscopic skills are required to perform this demanding procedure.
2. Even though significant reduction in post-POEM LES pressure has been reported, it is greater than 10 mm Hg, a value that predicts long-term failure.
3. Pathologic gastroesophageal reflux is common after POEM.
4. The formation of adhesions between the submucosal and the longitudinal muscular layer after POEM might make the dissection at this level challenging in case a surgical revision is needed to treat recurrent or persistent dysphagia after POEM.

Therefore, the authors believe that longer follow-up and large randomized clinical trials are needed before validating the use of POEM in the routine clinical practice for the treatment of esophageal achalasia.

SUMMARY

At present, LHM with partial fundoplication is considered the gold standard for the treatment of patients with esophageal achalasia. Endoscopic procedures such as EBTI and PD should be considered as primary treatment modalities only in frail patients. POEM is a new approach with promising short-term results.

REFERENCES

1. Mayberry JF. Epidemiology and demographics of achalasia. Gastrointest Endosc Clin N Am 2001;11:235–48.
2. Park W, Vaezi MF. Etiology and pathogenesis of achalasia: the current understanding. Am J Gastroenterol 2005;100:1404–14.
3. Pandolfino JE, Ghosh SK, Rice J, et al. Classifying esophageal motility by pressure topography characteristics: a study of 400 patients and 75 controls. Am J Gastroenterol 2008;103:27–37.
4. Pandolfino JE, Kwiatek MA, Nealis T, et al. Achalasia: a new clinically relevant classification by high- resolution manometry. Gastroenterology 2008;135:1526–33.
5. Campos GM, Vittinghoff E, Rabl C, et al. Endoscopic and surgical treatments for achalasia: a systematic review and meta-analysis. Ann Surg 2009;249:45–57.
6. Allescher HD, Storr M, Seige M, et al. Treatment of achalasia: botulinum toxin injection vs. pneumatic balloon dilation. A prospective study with long-term follow-Up. Endoscopy 2001;33:1007–17.
7. Pasricha PJ, Rai R, Ravich WJ, et al. Botulinum toxin for achalasia: long-term outcome and predictors of response. Gastroenterology 1996;110:1410–5.
8. Fishman VM, Parkman HP, Schiano TD, et al. Symptomatic improvement in achalasia after botulinum toxin injection of the lower esophageal sphincter. Am J Gastroenterol 1996;91:1724–30.

9. Annese V, Basciani M, Perri F, et al. Controlled trial of botulinum toxin injection versus placebo and pneumatic dilation in achalasia. Gastroenterology 1996;111: 1418–24.
10. Patti MG, Feo CV, Arcerito M, et al. Effects of previous treatment on results of laparoscopic Heller myotomy for achalasia. Dig Dis Sci 1999;44(11):2270–6.
11. Smith CD, Stival A, Howell DL, et al. Endoscopic therapy for achalasia before Heller myotomy results in worse outcomes than Heller myotomy alone. Ann Surg 2006;243:579–86.
12. Horgan S, Hudda K, Eubanks T, et al. Does botulinum toxin injection make esophagomyotomy a more difficult operation? Surg Endosc 1999;13:576–9.
13. Vaezi MF, Richter JE, Wilcox CM, et al. Botulinum toxin versus pneumatic dilatation in the treatment of achalasia: a randomised trial. Gut 1999;44:231–9.
14. Zaninotto G, Annese V, Costantini M, et al. Randomized controlled trial of botulinum toxin versus laparoscopic Heller myotomy for esophageal achalasia. Ann Surg 2004;239:364–70.
15. Stefanidis D, Richardson W, Farrell TM, et al. Society of American Gastrointestinal and Endoscopic Surgeons. SAGES guidelines for the surgical treatment of esophageal achalasia. Surg Endosc 2012;26:296–311.
16. Katz PO, Gilbert J, Castell DO. Pneumatic dilatation is effective long-term treatment for achalasia. Dig Dis Sci 1998;43:1973–7.
17. Wehrmann T, Jacobi V, Jung M, et al. Pneumatic dilation in achalasia with a low-compliance balloon: results of a 5-year prospective evaluation. Gastrointest Endosc 1995;42:31–6.
18. Aguilar-Paiz LA, Valdovinos-Diaz MA, Flores-Soto C, et al. Prospective evaluation of gastroesophageal reflux in patients with achalasia treated with pneumatic dilatation, thoracic or abdominal myotomy. Rev Invest Clin 1999;51:345–50.
19. Karamanolis G, Sgouros S, Karatzias G, et al. Long-term outcome of pneumatic dilation in the treatment of achalasia. Am J Gastroenterol 2005;100:270–4.
20. Eckardt VF, Gockel I, Bernhard G. Pneumatic dilation for achalasia: late results of a prospective follow-up investigation. Gut 2004;53:629–33.
21. Patti MG, Fisichella PM, Perretta S, et al. Impact of minimally invasive surgery on the treatment of esophageal achalasia: a decade of change. J Am Coll Surg 2003;196:698–705.
22. Wang YR, Dempsey DT, Friedenberg FK, et al. Trends of Heller myotomy hospitalizations for achalasia in the United States, 1993–2005: effect of surgery volume on perioperative outcomes. Am J Gastroenterol 2008;103:2454–64.
23. Pellegrini CA, Wetter LA, Patti MG, et al. Thoracoscopic esophagomyotomy. Initial experience with a new approach for the treatment of achalasia. Ann Surg 1992; 216:291–6.
24. Patti MG, Arcerito M, De Pinto M, et al. Comparison of thoracoscopic and laparoscopic Heller myotomy for achalasia. J Gastrointest Surg 1998;2:561–6.
25. Patti MG, Arcerito M, Tong J, et al. Importance of preoperative and postoperative pH monitoring in patients with esophageal achalasia. J Gastrointest Surg 1997;1:505–10.
26. Richards WO, Torquati A, Holzman MD, et al. Heller myotomy versus Heller myotomy with Dor fundoplication. A prospective randomized double-blind clinical trial. Ann Surg 2004;240:405–15.
27. Wright AS, Williams CW, Pellegrini CA, et al. Long-term outcomes confirm the superior efficacy of extended Heller myotomy with Toupet fundoplication for achalasia. Surg Endosc 2007;21:713–8.
28. Patti MG, Pellegrini CA, Horgan S, et al. Minimally invasive surgery for achalasia. An 8-year experience with 168 patients. Ann Surg 1999;230:587–93.

29. Cowgill SM, Villadolid D, Boyle R, et al. Laparoscopic Heller myotomy for achalasia: results after 10 years. Surg Endosc 2009;23:2644–9.
30. Rebecchi F, Giaccone C, Farinella E, et al. Randomized controlled trial of laparoscopic Heller myotomy plus Dor fundoplication versus Nissen fundoplication for achalasia. Ann Surg 2008;248:1023–30.
31. Rawlings A, Soper NJ, Oelschlager B, et al. Laparoscopic Dor versus Toupet fundoplication following Heller myotomy for achalasia: results of a multicenter, prospective, randomized-controlled trial. Surg Endosc 2012;26:18–26.
32. Hunter JG, Trus TL, Branum GD, et al. laparoscopic Heller myotomy and fundoplication for achalasia. Ann Surg 1997;225:655–65.
33. Salvador R, Costantini M, Cavallin F, et al. Laparoscopic Heller myotomy can be used as primary therapy for esophageal achalasia regardless of age. J Gastrointest Surg 2014;18:106–11.
34. Sweet MP, Nipomnick I, Gasper WJ, et al. The outcome of laparoscopic Heller myotomy for achalasia is not influenced by the degree of esophageal dilatation. J Gastrointest Surg 2008;12:159–65.
35. Boeckxstaens GE, Annese V, des Varannes SB, et al. European Achalasia Trial Investigators. Pneumatic dilation versus laparoscopic Heller's myotomy for idiopathic achalasia. N Engl J Med 2011;364:1807–16.
36. Inoue H, Minami H, Kobayashi Y, et al. Peroral endoscopic myotomy (POEM) for esophageal achalasia. Endoscopy 2010;42:265–71.
37. Swanstrom LL, Kurian A, Dunst CM, et al. Long-term outcomes of an endoscopic myotomy for achalasia: the POEM procedure. Ann Surg 2012;256:659–67.
38. Von Renteln D, Fuchs KH, Fockens P, et al. Peroral endoscopic myotomy for the treatment of achalasia: an international prospective multicenter study. Gastroenterology 2013;145:309–11.e1–3.
39. Hungness ES, Teitelbaum EN, Santos BF, et al. Comparison of perioperative outcomes between peroral esophageal myotomy (POEM) and laparoscopic Heller myotomy. J Gastrointest Surg 2013;17:228–35.
40. Bhayani NH, Kurian AA, Dunst CM, et al. A comparative study on comprehensive, objective outcomes of laparoscopic Heller myotomy with per-oral endoscopic myotomy (POEM) for achalasia. Ann Surg 2014;259:1098–103.
41. Swanstrom LL. Poetry is in the air: first multi-institutional results of the per-oral endoscopic myotomy procedure for achalasia. Gastroenterology 2013;145:272–3.