Anatomy of Hepatic Resectional Surgery

Michael C. Lowe, MD[a], Michael I. D'Angelica, MD[a,b,*]

KEYWORDS

- Liver anatomy • Hepatic resections • Parenchymal-sparing resections
- Intraoperative management

KEY POINTS

- Liver anatomy can be variable, and understanding of anatomic variations is crucial to performing hepatic resections, particularly parenchymal-sparing resections.
- Anatomic knowledge is a critical prerequisite for effective hepatic resection with minimal blood loss, parenchymal preservation, and optimal oncologic outcome.
- Each anatomic resection has pitfalls, about which the operating surgeon should be aware and comfortable managing intraoperatively.

LIVER ANATOMY

Historical Definitions

Historically, the liver was described as having 2 anatomic lobes, the larger right lobe and the smaller left lobe. These lobes are separated on the anterior surface of the liver by the falciform ligament, and on the inferior surface by the ligamentum teres as it enters the umbilical fissure. The liver is invested by peritoneum except on its posterior surface, where the peritoneum reflects to create the right and left triangular ligaments. The area between the folds of peritoneum that create the triangular ligaments is devoid of peritoneum and is referred to as the bare area. The retrohepatic inferior vena cava (IVC) lies within this bare area on the undersurface of the liver. The gastrohepatic ligament attaches to the ligamentum venosum, which separates the historically defined right and left lobes of the liver on its posterior surface (**Fig. 1**). This common early definition of liver anatomy was based on external landmarks and has no real relationship to functional anatomy. In fact, the liver does not have reliable external landmarks for most current functional definitions.

Conflicts of Interest/Funding Sources: None.
[a] Department of Surgery, Memorial Sloan Kettering Cancer Center, 1275 York Avenue, New York, NY 10065, USA; [b] Weill Cornell University School of Medicine, New York, NY 10065, USA
* Corresponding author.
E-mail address: dangelim@mskcc.org

Surg Clin N Am 96 (2016) 183–195
http://dx.doi.org/10.1016/j.suc.2015.11.003 **surgical.theclinics.com**
0039-6109/16/$ – see front matter © 2016 Elsevier Inc. All rights reserved.

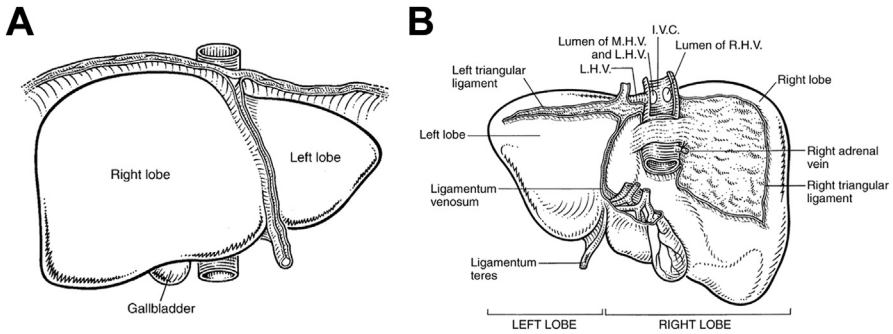

Fig. 1. The external anatomy of the liver as seen from the anterior (*A*) and posterior (*B*) surfaces. (*From* Blumgart LH, Hann LE. Surgical and radiologic anatomy of the liver, biliary tract, and pancreas. In: Jarnagin WR, Blumgart LH, eds. Blumgart's surgery of the liver, biliary tract and pancreas. 5th edition. Philadelphia: Elsevier; 2012; with permission.)

Vascular Anatomy

The hepatic veins drain the liver directly into the suprahepatic IVC. The larger right hepatic vein has a short 1 cm extrahepatic course, while the smaller middle and left hepatic veins usually join a common trunk 1 to 2 cm in length before entering the IVC separately from the right hepatic vein. Occasionally, the left and middle hepatic veins will drain separately into the IVC. The umbilical vein typically runs anterior to the umbilical fissure and most commonly drains into the left hepatic vein, but can join into the middle hepatic vein or join both the middle and left hepatic veins as a trifurcation. Although intrahepatic venous branching can be variable, there are common branches found in most cases. The right hepatic vein provides the dominant drainage of the posterior sector, and its branches typically drain from the right into the main trunk. The middle hepatic vein commonly drains a large right-sided branch which serves as the principal drainage of segment VIII. Segment IV typically derives its venous drainage from branches of the left hepatic and umbilical veins. There are variable and typically numerous retrohepatic venous branches that drain directly from the caudate lobe into the vena cava. Accessory hepatic veins are common and most frequently involve the right side of the liver as an inferior right hepatic vein draining directly into the vena cava independent of the right hepatic vein.

The hepatic artery and portal vein inflow to and biliary drainage of the liver have many anatomic variations. With conventional anatomy, the portal vein, common bile duct, and hepatic artery run in the porta hepatis. The portal vein sits posteriorly, while the bile duct runs anteriorly and to the right of the portal vein; the hepatic artery runs anteriorly and to the left of the portal vein.

The hepatic artery arises from the celiac axis and becomes the proper hepatic artery after giving off the gastroduodenal and right gastric arteries. It then branches into the right and left hepatic arteries. The left branch extends toward the base of the umbilical fissure and gives off branches to the caudate lobe and segments II-IV. Often the left hepatic artery branches into lateral and medial branches extrahepatically that feed segments II, II, and IV, respectively. The segment IV branch can also arise from the right hepatic artery and was historically referred to as the middle hepatic artery. The right hepatic artery usually passes posterior to the common hepatic duct, although it passes anteriorly in about 10% to 20% of cases. The right hepatic artery typically splits into an anterior and posterior branch, which can often be dissected in an extrahepatic location.

The most common variations in arterial anatomy are replaced or accessory right or left hepatic arteries arising from the superior mesenteric or left gastric arteries, respectively. A replaced branch has an aberrant origin and provides complete blood supply to a hemi-liver, whereas an accessory branch has an aberrant origin but only provides additional blood supply to a hemi-liver. Aberrant arterial anatomy occurs in approximately 40% of individuals, and almost any combination of arterial branches can be present. A replaced right hepatic artery runs laterally to the common bile duct and can easily be injured when dissecting the porta hepatis without prior knowledge of its aberrant location. A replaced left hepatic artery runs in the gastrohepatic ligament and can be injured when mobilizing the left lobe of the liver. The common hepatic artery can also originate from the superior mesenteric artery and run in the same plane as a replaced right hepatic artery. A summary of the most frequently occurring arterial anomalies can be found in Fig. 2.

The portal vein is created by the confluence of the splenic and superior mesenteric veins behind the neck of the pancreas. It ascends behind the common bile duct and the hepatic artery into the hilus of the liver, where it bifurcates into a larger right portal vein and smaller left portal vein. The left branch enters the umbilical fissure and supplies the left liver. The right branch, which has a much shorter extrahepatic course, divides into the right anterior and the right posterior sectoral branches. The most common variations of portal venous anatomy can be seen in Fig. 3. Although almost any variation is possible, the most common anatomic variation involves the branching of the right portal vein with either a lack of a main right portal vein or separate origins of the anterior and posterior sectoral branches.

Biliary drainage follows a remarkably similar anatomic pathway as the portal inflow. The right anterior and right posterior sectoral branches combine to form the right hepatic duct, which has a short extrahepatic course before joining the left hepatic duct at the biliary confluence to form the common hepatic duct. The left hepatic duct courses along the base of segment IV; it can be accessed by incising Glisson capsule at the base of the quadrate lobe, a maneuver referred to as lowering the hilar plate. Common anomalies in biliary anatomy include a trifurcation (12%) and ectopic drainage of right sectoral ducts into the common or left hepatic duct (20%). These and the remaining biliary anomalies can be seen in Fig. 4.

Functional Surgical Anatomy

Couinaud segments

Understanding the internal anatomy of the liver is essential to performing hepatic resections, and in particular, parenchymal-preserving resections. The functional anatomy of the liver described by Couinaud serves as the most useful for the surgeon and is quite different from the historically defined hepatic lobes based on external landmarks.[1] According to Couinaud descriptions, the 3 main hepatic veins separate the liver into 4 sectors, each of which is fed by a portal pedicle that includes a branch of the hepatic artery, portal vein, and bile duct. The right and left hemi-livers are divided by the main portal scissura, which contains the middle hepatic vein. This main portal scissura progresses from the gallbladder fossa anteriorly to the left of the IVC posteriorly, and these landmarks serve as external boundaries of the line between the functional right and left liver. Both the right and left hemi-livers are further divided into sectors by scissurae containing the right and left hepatic veins, respectively (Fig. 5).

The right portal scissura separates the right liver into the anterior and posterior sectors, which are further subdivided into segments. The right anterior sector is comprised of segments V inferiorly and VIII superiorly, and the right posterior sector

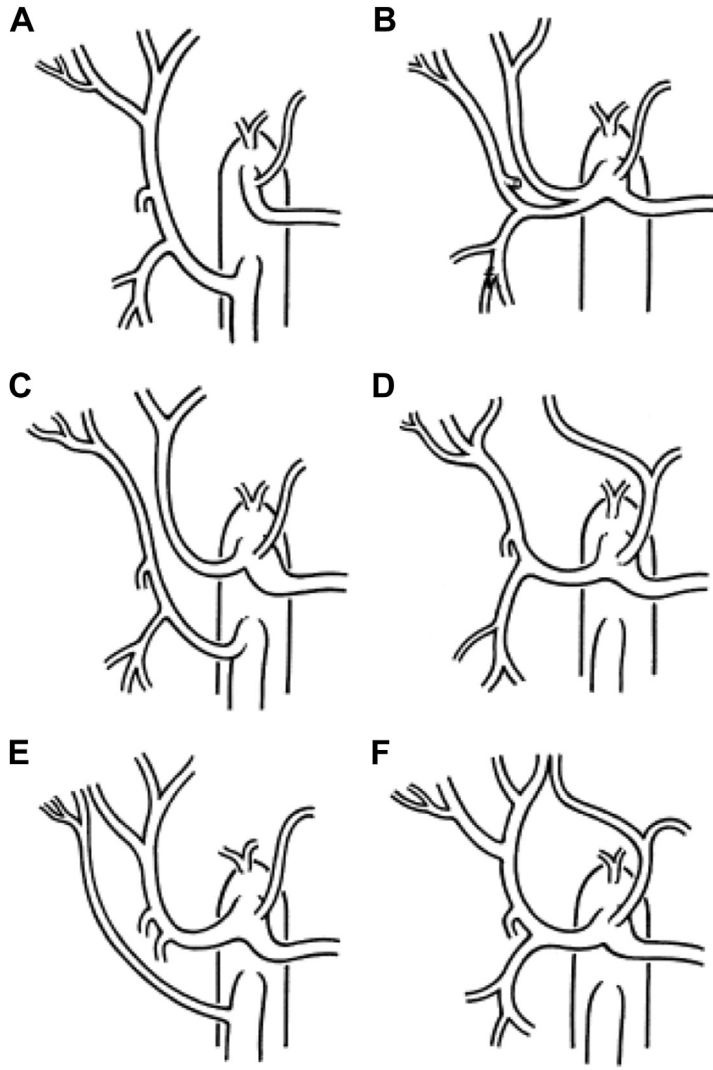

Fig. 2. Variations in hepatic arterial anatomy. These include a replaced common hepatic artery (*A*), a very short common hepatic artery origin from the celiac axis (*B*), a replaced (*C*) or accessory (*E*) right hepatic artery arising from the superior mesenteric artery, and a replaced (*D*) or accessory (*F*) left hepatic artery arising from the left gastric artery. (*From* Blumgart LH, Hann LE. Surgical and radiologic anatomy of the liver, biliary tract, and pancreas. In: Jarnagin WR, Blumgart LH, eds. Blumgart's surgery of the liver, biliary tract and pancreas. 5th edition. Philadelphia: Elsevier; 2012; with permission.)

is comprised of segments VI inferiorly and VII superiorly. The left portal scissura, which runs to the left of and posterior to the ligamentum teres along the course of the left hepatic vein, separates the left liver into the anterior and posterior sectors. Segments IV and III make up the anterior sector, and the posterior sector is comprised only of segment II (Fig. 6). Segment IV can further be divided into segment IVA superiorly and segment IVB inferiorly based on the branching of the left portal pedicle (see

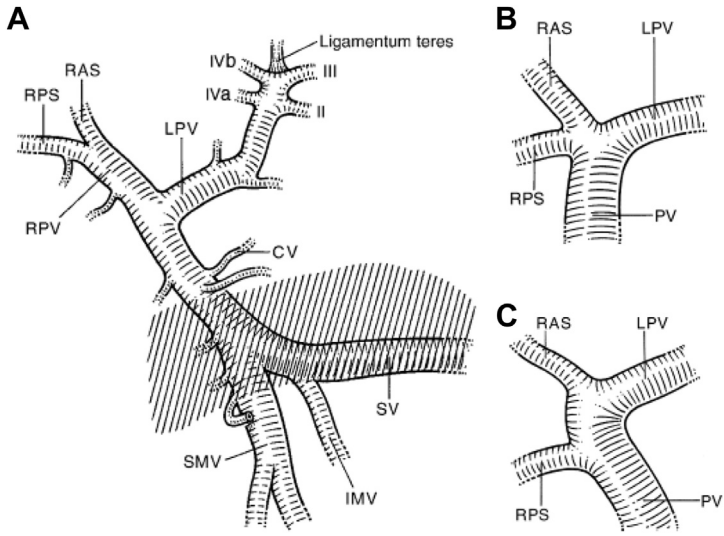

Fig. 3. Variations in portal venous anatomy. In normal anatomy the splenic vein (SV) and superior mesenteric vein combine to form the portal vein, which branches into the right portal vein (RPV) and left portal vein (LPV). The RPV further branches in right anterior sectoral (RAS) and right posterior sectoral (RPS) branches (*A*). The RAS, RPS, and LPV can all arise independently from the main portal vein (*B*). The RPS may arise early from the portal vein, which then bifurcates in the RAS and LPV (*C*). CV, coronary vein; IMV, inferior mesenteric vein; SMV, superior mesenteric vein. (*From* Blumgart LH, Hann LE. Surgical and radiologic anatomy of the liver, biliary tract, and pancreas. In: Jarnagin WR, Blumgart LH, eds. Blumgart's surgery of the liver, biliary tract and pancreas. 5th edition. Philadelphia: Elsevier; 2012; with permission.)

Fig. 5), although this branching is variable and does not often result in an easily defined segment IVA and B. The caudate lobe (segment I) is the portion of liver that lies between the IVC and the main portal pedicle and straddles the retrohepatic IVC (Fig. 7). It is supplied by vessels from both the right and left portal pedicles, and biliary drainage follows a similar pattern. The caudate lobe is the only portion of the liver that drains directly into the IVC.

Brisbane terminology

An alternative nomenclature was devised by the Scientific Committee of the International Hepato-Pancreato-Biliary Association (IHPBA) in Brisbane, Australia, in 2000.[2] This terminology was created in an attempt to clarify the confusion surrounding the terminology of liver anatomy and resections. The main difference between the Couinaud description and the Brisbane 2000 Terminology is the renaming of Couinaud sectors as sections. Furthermore, the left liver is not divided into 2 sectors based on the left hepatic vein. The left liver is defined as having a lateral section (segments II and III) and a medial section (segment IV). This new classification of the left liver is not based on the left portal scissura, but rather on the division of the left liver by the line between the falciform ligament and the umbilical fissure. The anatomic terms, Couinaud segments, and surgical resection terms for all anatomic resections are included in Table 1.

Variations in Anatomy

Ultimately, the true definition of segmental anatomy is dictated by the vascular/biliary pedicle supplying each segment. While the previously described anatomic

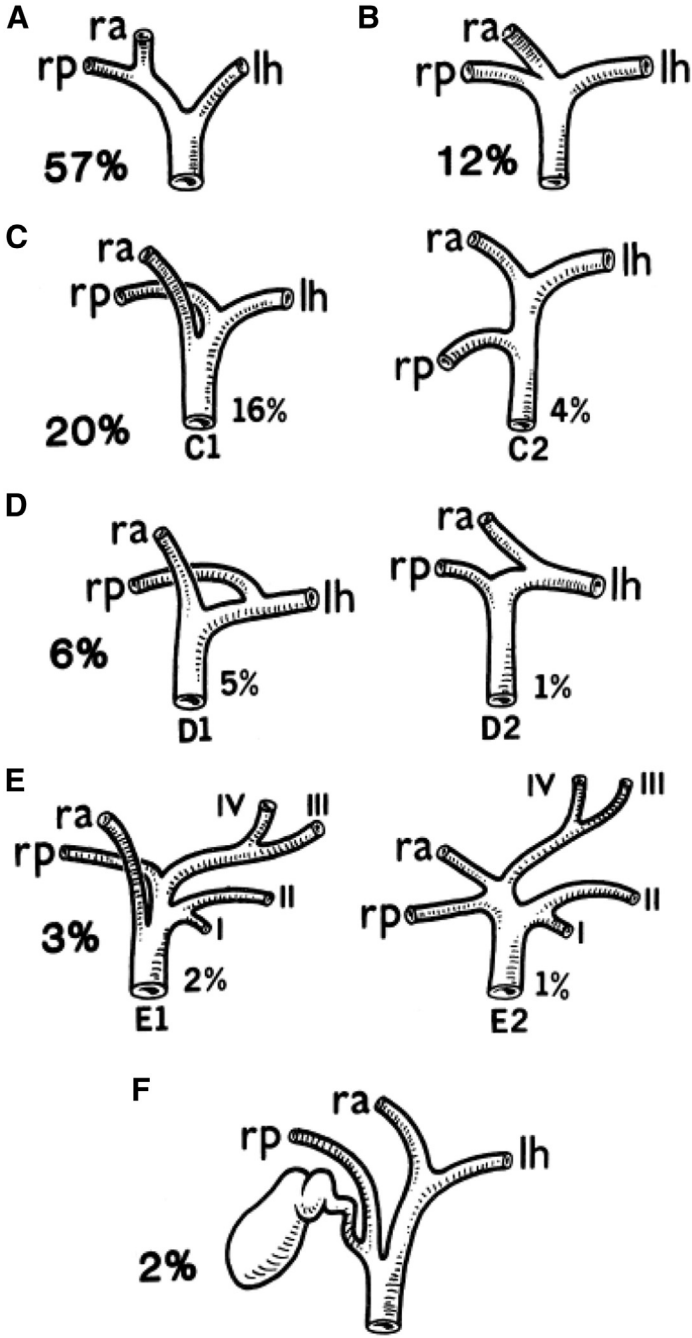

Fig. 4. Variations in biliary anatomy. With typical anatomy the right anterior and posterior sectoral branches combine to form the right hepatic duct, which combines with left hepatic duct to form the common hepatic duct (*A*). Variations include a triple confluence (*B*), ectopic drainage of the right sectoral duct into the common hepatic duct (*C*), ectopic drainage of either of the right sectoral branches into the left hepatic duct (*D*), absence of the confluence (*E*), and absence of the right hepatic duct and drainage of the right posterior duct into the cystic duct (*F*). (*From* Blumgart LH, Hann LE. Surgical and radiologic anatomy of the liver, biliary tract, and pancreas. In: Jarnagin WR, Blumgart LH, eds. Blumgart's surgery of the liver, biliary tract and pancreas. 5th edition. Philadelphia: Elsevier; 2012; with permission.)

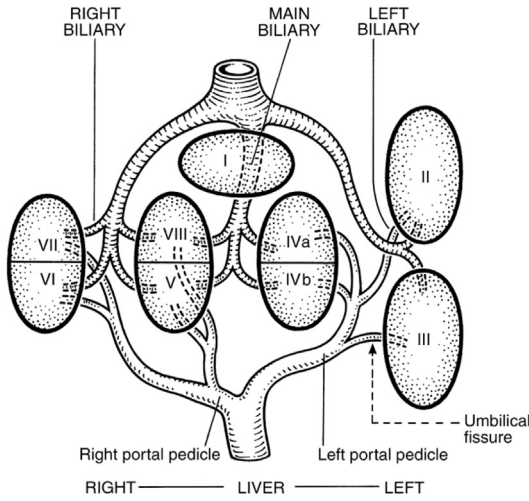

Fig. 5. The segmental anatomy of the liver, which is determined by the portal inflow and hepatic outflow. (*From* Blumgart LH, Hann LE. Surgical and radiologic anatomy of the liver, biliary tract, and pancreas. In: Jarnagin WR, Blumgart LH, eds. Blumgart's surgery of the liver, biliary tract and pancreas. 5th edition. Philadelphia: Elsevier; 2012; with permission.)

descriptions serve as a guide for resectional surgery, it is vital to recognize anatomic variations on preoperative imaging and confirm these findings using intraoperative ultrasound. There are an infinite number of anatomic variations in vascular branching patterns as well as segmental size and location that will not always follow the textbook definitions provided in this article. Every planned resection should be preceded by high-quality cross-sectional imaging with an assessment of vascular and segmental anatomy. Alterations in planned resections may be required if anatomic variations or additional malignant-appearing tumors are found. The ultimate goal is to accomplish an oncologically appropriate resection leaving a remnant with sufficient portal venous and hepatic arterial supply, biliary drainage, and unopposed venous outflow.

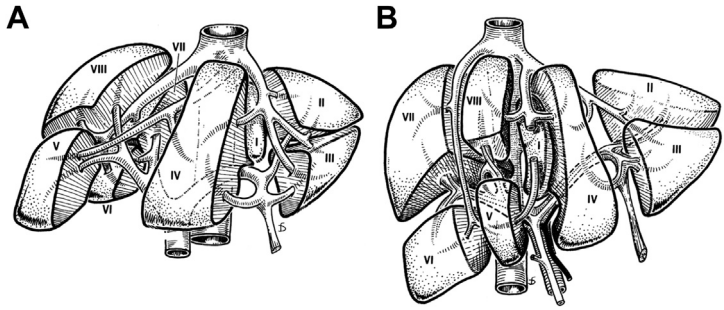

Fig. 6. The functional division of the liver as seen in the patient (*A*) and ex vivo (*B*). (*From* Blumgart LH, Hann LE. Surgical and radiologic anatomy of the liver, biliary tract, and pancreas. In: Jarnagin WR, Blumgart LH, eds. Blumgart's surgery of the liver, biliary tract and pancreas. 5th edition. Philadelphia: Elsevier; 2012; with permission.)

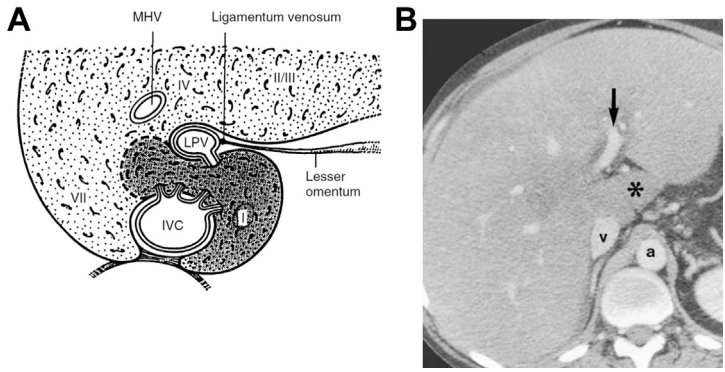

Fig. 7. (*A*) The relationship of the caudate lobe (I) to the IVC, portal vein (LPV), middle hepatic vein (MHV), and segments II/III and VII. (*B*) A CT scan demonstrating the caudate lobe (*asterisk*) situated between the portal vein (*arrow*) and the IVC (V). a, Aorta. (*From* Blumgart LH, Hann LE. Surgical and radiologic anatomy of the liver, biliary tract, and pancreas. In: Jarnagin WR, Blumgart LH, eds. Blumgart's surgery of the liver, biliary tract and pancreas. 5th edition. Philadelphia: Elsevier; 2012; with permission.)

USING ANATOMY TO GUIDE RESECTIONAL SURGERY

Minimizing Operative Morbidity

Parenchymal preservation without oncologic compromise

Historically, liver resection was associated with high morbidity and mortality related to blood loss and hepatic failure. With recent advancements in surgical technique and anesthesia, morbidity and mortality rates have dramatically decreased. A major part of the reason for this decrease is the increased use of parenchymal-preserving liver resection. In a recent single-institution analysis of 3876 patients undergoing 4152 liver resections for cancer from 1993 to 2012, the percentage of major hepatectomies

Table 1
Surgical resection terms and their related anatomic terms and Couinaud segments

Couinaud Segments	Anatomic Term	Surgical Resection Term
5–8	Right liver	Right hepatectomy
2–4	Left liver	Left hepatectomy
5, 8	Right anterior section/ sector	Right anterior sectionectomy/ sectorectomy
6, 7	Right posterior section/ sector	Right posterior sectionectomy/ sectorecomty
4	Left medial section	Left medial sectionectomy
2, 3	Left lateral section	Left lateral sectionectomy
4, 3	Left medial sector	Left medial sectorectomy
2	Left lateral sector	Left lateral sectorectomy
4–8	—	Right trisectionectomy/ extended right hepatectomy
2–4, 5, 8	—	Left trisectionectomy/ extended left hepatectomy
Any segment 1–8	Segment	Segmentectomy
Any 2 contguous segments	—	Bisegmentectomy

decreased from 66% to 36%. During this same period, the 90-day mortality decreased from 5% to 1.6%, and the perioperative morbidity decreased from 53% to 20%. Over this period of time, the mortality of major resections such as trisectionectomy (6%) and right hepatectomy (3%) did not change, strongly suggesting that the improvements in perioperative outcome were mostly related to the increase in the percentage of parenchymal-sparing resections.[3] The theoretic concern with parenchymal-sparing surgery is compromised oncologic outcome. To the contrary, numerous studies have shown that performing parenchymal-sparing resections does not result in inferior survival, particularly for colorectal liver metastases.[4–10] A meta-analysis of 7 non-randomized controlled studies found no significant difference in surgical margins, overall survival, and disease-free survival between patients undergoing anatomic and nonanatomic resections.[11]

Minimizing blood loss

Although specific techniques employed to minimize blood loss will be covered elsewhere, it is important to appreciate the importance of limiting hemorrhage, which historically has contributed to significant perioperative morbidity. This can be accomplished most successfully by maintaining a low central venous pressure (CVP) during parenchymal resection. This reduces hepatic venous distention, which significantly decreases backbleeding when the liver parenchymal is transected.[12] Maintaining low CVP during liver resection reduces intraoperative blood loss, in-hospital mortality, and postoperative morbidity.[13] Postoperative renal failure is possible after low CVP anesthesia, but this complication is rare if the patient is resuscitated to euvolemia immediately upon completion of the parenchymal transection. In a recent study of 2116 patients undergoing low CVP-assisted hepatectomy, less than 1% of patients developed clinically relevant acute kidney injury.[14]

Vascular occlusion also can contribute to control of intraoperative blood loss. Hepatic inflow arrest was first described by Pringle in the setting of trauma,[15] and this remains the standard method by which control of portal venous and hepatic arterial inflow is gained. Encircling the hepatoduodenal ligament allows for simultaneous occlusion of the portal vein and hepatic artery. Intermittent occlusion permits longer periods of occlusion, but the length of inflow occlusion should be limited as much as possible, particularly with an abnormal liver. More complex vascular exclusion techniques, such as hepatic vascular exclusion, will be covered elsewhere. Although inflow occlusion is not required for all cases, it is an important tool to be used if there is inflow bleeding during hepatic transection.

GENERAL ANATOMIC CONCEPTS AND PITFALLS IN SPECIFIC RESECTIONS

Right Hepatectomy

Descriptions of this operation are common, and there are numerous techniques to accomplish a safe and effective right hepatectomy. Most commonly, the right liver is mobilized completely off of the diaphragm and vena cava by dividing the often numerous retrohepatic venous branches. The right caval ligament, which runs laterally to the right hepatic vein and envelops the vena cava posteriorly circumferentially to join the left side of the caudate, must be encircled and divided to expose the right hepatic vein. Dissection along the vena cava to encircle the right hepatic vein can be accomplished after this ligament is divided. Inflow to the liver can be taken in a number of ways, including extrahepatic ligation of inflow vessels or ligation of the right inflow pedicle inside the liver. Pedicle ligation can be carried out through hepatotomies or by splitting the liver down to the pedicle in an anterior approach. If an extrahepatic ligation of vessels is carried out, it is advisable, if possible, to take the right hepatic bile duct

intrahepatically in the main pedicle to minimize the chance of contralateral biliary injury. Regardless of the approach to the inflow vessels, knowledge of the inflow vessels and their anatomy and variation is critical. Once inflow is taken, the right hepatic vein is divided and most commonly divided extrahepatically. The line of transection is along the middle hepatic vein, which can be taken or preserved depending on the location of the tumor to be resected. Maintaining transection in this plane is important in order to prevent leaving ischemic liver tissue behind.

There are several anatomic variations that are relevant to the performance of this operation. A large inferior right hepatic vein can be present and serve as the primary venous drainage of segment VI. This needs to be divided as the liver is mobilized off of the vena cava. The right portal vein has a wide range of anatomic presentations ranging from a long segment prior to sectoral/segmental branching, to the complete lack of a true right portal vein with immediate branching into segmental/sectoral branches. Lastly, the right anterior portal vein and pedicle can originate off of the left inflow and necessitate intrahepatic control. The right portal vein almost always gives off a small posterior branch to the caudate process that can be a common source of bleeding during extrahepatic dissection. The right hepatic artery typically runs posterior to the common hepatic duct, but in about 10% to 20% of cases, it runs anterior to the duct. A replaced right hepatic artery is common and runs posteriorly in the porta between the portal vein and common bile duct. The most common biliary anomalies include a right sectoral branch draining into the left hepatic duct. Lastly, the left hepatic duct as it arises from the common hepatic duct can originate close to the right inflow, and injury to this duct during transection of right-sided inflow structures can be disastrous. Lowering of the hilar plate is helpful to both identify and protect the left hepatic duct. These abnormalities can all be detected on high-quality cross-sectional imaging and should be evaluated prior to operation.

Right Posterior Sectorectomy

This resection removes segments VI and VII of the liver, and the principle transection plane is the right portal scissura along the right hepatic vein. The right liver should be mobilized as is done for a right hepatectomy. Although not critical for every case, it is advisable to dissect and control the right hepatic vein. Knowledge of the posterior sectoral inflow anatomy is important. There often is not a common posterior sectoral trunk dividing into segment VI and VII branches. Often the segment VI and VII inflow pedicles branch almost immediately off of the right inflow pedicle. This requires taking these pedicles individually inside the liver. Although the posterior sectoral inflow vessels can be dissected extrahepatically, this is, in general, difficult and not necessary. The plane of the right hepatic vein can be visualized by intraoperative ultrasound and marked. The transection plane is somewhat horizontal toward the right edge of the vena cava. The transection plane is divided down to the inflow pedicles, which are divided intrahepatically to ensure that the dissection has not gone too far to the left into the anterior sectoral pedicles. Although preferable to preserve the right hepatic vein, this vessel can be taken, since the middle hepatic vein is the principal venous drainage for the anterior sector.

Right Anterior Sectorectomy

This resection is challenging in that it requires 2 long lines of transection to encompass segments V and VIII. The main anterior pedicle at its origin will almost always take all of the inflow to these segments, although occasionally segment V will have extra inflow pedicles from the posterior sectoral pedicle or the central inflow pedicles at the main branching points in the porta. The key to the operation is identification and ligation of

the main anterior pedicle, which, is best accomplished intrahepatically if the tumor allows. The main anterior pedicle can be found by transecting along the middle hepatic vein, since it terminates in branches coursing to the left of and anterior to the anterior pedicle. Thus transection of the liver in the main portal scissura exposes the main right anterior pedicle after ligating and dividing these terminal middle hepatic vein branches. The middle hepatic vein can be taken in this operation, since segment IV can drain into the umbilical vein, which most commonly originates from the left hepatic vein. It is critical to preserve the right hepatic vein, since this is the venous drainage of the posterior sector. The posterior extent of dissection does not require division down to the vena cava, since the well-vascularized caudate lobe lies posteriorly and does not need to be taken as part of this operation.

Central Hepatectomy

This resection is similar to an anterior sectorectomy, except that the left extent of the resection takes some or all of segment IV and mandates resection of the middle hepatic vein. The inflow to segment IV can easily be taken intrahepatically while transecting the liver to the right of the umbilical fissure. The segment IV pedicles are almost always multiple and do not neatly divide into segment IVA and IVB branches. At the base of segment IV, the dissection must turn sharply to the right to avoid the main left inflow structures. Similar to an anterior sectorectomy, dissection then commences to the right, taking terminal middle hepatic vein branches to isolate the main right anterior inflow pedicle. Other technical issues are the same as an anterior sectorectomy.

Left Hepatectomy

The left liver is situated anterior to the caudate lobe and therefore does not require mobilization off of the vena cava. The inflow to the left liver is more accessible than the right-sided structures, and extrahepatic isolation and division are fairly straightforward. The left hepatic artery courses cephalad along the left side of the porta hepatis anteriorly and is relatively easy to encircle. Once encircled, it should be ensured that one has not come around the proper hepatic artery prior to branching; this can happen easily if the branching is more distal. Simple dissection or clamping with palpation of a right-sided pulse is sufficient. Often the left hepatic artery branches into medial (segment IV) and lateral (segments II and III) branches, but a common variation is that the segment IV branch (previously called the middle hepatic artery) comes off the right hepatic artery. Posteriorly, the left portal vein can be dissected. Confirmation of portal anatomy requires visualization of the portal bifurcation. The left portal vein gives off a small branch to the caudate lobe, which should be identified and preserved if possible. Just beyond the caudate branch, the ligamentum venosum inserts into the left portal vein and can be seen with careful dissection. This area of insertion usually is surrounded by fibrous tissue. The safest place to divide the left portal vein is between the caudate branch and the insertion of the ligamentum venosum. The left bile duct runs at the base of segment IV before branching into the left liver. Whenever possible, the left bile duct should be divided within the main left pedicle intrahepatically. Biliary anomalies are most relevant for left-sided resections, since right sectoral branches can be found draining into the left bile duct. If a tumor mandates division of the left bile duct extrahepatically, these biliary anomalies should be sought and defined with preoperative imaging and during dissection. The left hepatic vein typically courses anterior to the segment II pedicle and then runs posterior to the segment III pedicle.

A left hepatectomy can be performed either by taking or preserving the middle hepatic vein. Although the middle hepatic vein is typically the dominant venous drainage

of the right anterior sector, there is almost always sufficient venous collateral to the right hepatic vein to provide adequate drainage. It is often difficult to isolate the left and middle hepatic vein individually in an extrahepatic location, but sometimes with careful dissection this can be done. In order to divide the left and middle hepatic veins at their common trunk extrahepatically, dissection between the right and middle hepatic veins superiorly at the suprahepatic vena cava demonstrates a wide tunnel. Posterior to the left liver, the ligamentum venosum is divided and retracted cephalad to expose a space anterior to the caudate lobe and between the hepatic parenchyma and the left/middle hepatic vein common trunk. This is often a tight space and requires meticulous dissection to avoid vascular injury or bleeding. Alternatively, either vein can be approached by splitting the liver back to its origin and dividing the veins after the parenchymal dissection has exposed their origin. As for a right hepatectomy, the plane of transection is in the main portal scissura in the plain of the middle hepatic vein.

Left Lateral Sectionectomy

A left lateral sectionectomy is a relatively straightforward resection that is most easily accomplished by taking inflow and outflow structures intrahepatically. The segment II and III pedicles are relatively constant in branching and location but can occasionally vary. Sometimes their origins are close, and they may even share a common trunk. Small branches other than the main segmental pedicles are commonly encountered. Although these inflow pedicles can be dissected in the umbilical fissure or encircled by making flanking hepatotomies, the simplest method to expose them is to split the liver in the plane just to the left of the umbilical fissure down to their origins. In this manner, each pedicle can be encircled and divided. The left hepatic vein typically joins the middle hepatic vein in a relatively intrahepatic position, and therefore isolating the left hepatic vein extrahepatically can be difficult and is usually not necessary. The left hepatic vein origin can be defined by splitting the liver to the point where the left hepatic vein joins the middle hepatic vein. The umbilical vein runs in the plane anterior to the umbilical fissure and most commonly joins the left hepatic vein, although sometimes it will come off the common channel or middle hepatic vein. The umbilical vein is in the plane of resection for a left lateral sectionectomy and can be preserved or taken; either way, its location should be noted as it can be a source of bleeding during transection.

Wedge/Atypical/Single Segment Resections

Detailed descriptions of every potential atypical or single segment resection are beyond the scope of this article. Nonetheless, careful review of anatomic variation and careful intrahepatic dissection with the help of intraoperative ultrasound should be able to identify any inflow or outflow structure in order to accomplish any of these resections in proper anatomic planes without devascularizing large amounts of hepatic parenchyma. Single-segment resections require careful isolation of the inflow pedicle or pedicles, and knowledge of common variations is necessary. For example, segment VIII typically has a single dominant pedicle that divides into a ventral and dorsal branch. This is a remarkably consistent anatomic finding. On the other hand, segment V typically does not have a dominant inflow pedicle and has numerous inflow branches, most commonly coming off the main right anterior pedicle. Segmental resections also mandate that parenchymal transection takes place in a scissura along the main hepatic veins. As operations for multiple bilobar tumors have become more common the use of wedge and atypical resections has become more common. From an anatomic perspective, the surgeon, with careful review of imaging and use of intraoperative ultrasound, must ensure that these

resections do not divide major inflow and outflow vessels to other parts of the liver. As long as major vessels are preserved, these atypical resections outside of typical anatomic planes are safe and effective.

REFERENCES

1. Couinaud C. Anatomic principles of left and right regulated hepatectomy: technics. J Chir (Paris) 1954;70(12):933–66 [in French].
2. Strasberg SM. Nomenclature of hepatic anatomy and resections: a review of the Brisbane 2000 system. J Hepatobiliary Pancreat Surg 2005;12(5):351–5.
3. Kingham TP, Correa-Gallego C, D'Angelica MI, et al. Hepatic parenchymal preservation surgery: decreasing morbidity and mortality rates in 4,152 resections for malignancy. J Am Coll Surg 2015;220(4):471–9.
4. Gold JS, Are C, Kornprat P, et al. Increased use of parenchymal-sparing surgery for bilateral liver metastases from colorectal cancer is associated with improved mortality without change in oncologic outcome: trends in treatment over time in 440 patients. Ann Surg 2008;247(1):109–17.
5. Karanjia ND, Lordan JT, Quiney N, et al. A comparison of right and extended right hepatectomy with all other hepatic resections for colorectal liver metastases: a ten-year study. Eur J Surg Oncol 2009;35(1):65–70.
6. Kokudo N, Tada K, Seki M, et al. Anatomical major resection versus nonanatomical limited resection for liver metastases from colorectal carcinoma. Am J Surg 2001;181(2):153–9.
7. Lalmahomed ZS, Ayez N, van der Pool AE, et al. Anatomical versus nonanatomical resection of colorectal liver metastases: is there a difference in surgical and oncological outcome? World J Surg 2011;35(3):656–61.
8. Stewart GD, O'Súilleabháin CB, Madhavan KK, et al. The extent of resection influences outcome following hepatectomy for colorectal liver metastases. Eur J Surg Oncol 2004;30(4):370–6.
9. Tanaka K, Shimada H, Matsumoto C, et al. Impact of the degree of liver resection on survival for patients with multiple liver metastases from colorectal cancer. World J Surg 2008;32(9):2057–69.
10. von Heesen M, Schuld J, Sperling J, et al. Parenchyma-preserving hepatic resection for colorectal liver metastases. Langenbecks Arch Surg 2012;397(3):383–95.
11. Sui CJ, Cao L, Li B, et al. Anatomical versus nonanatomical resection of colorectal liver metastases: a meta-analysis. Int J Colorectal Dis 2012;27(7):939–46.
12. Jones RM, Moulton CE, Hardy KJ. Central venous pressure and its effect on blood loss during liver resection. Br J Surg 1998;85(8):1058–60.
13. Chen H, Merchant NB, Didolkar MS. Hepatic resection using intermittent vascular inflow occlusion and low central venous pressure anesthesia improves morbidity and mortality. J Gastrointest Surg 2000;4(2):162–7.
14. Correa-Gallego C, Berman A, Denis SC, et al. Renal function after low central venous pressure-assisted liver resection: assessment of 2116 cases. HPB (Oxford) 2015;17(3):258–64.
15. Pringle JH. V. Notes on the arrest of hepatic hemorrhage due to trauma. Ann Surg 1908;48(4):541–9.