

Epidemiology and Etiology of Sarcomas



Jane Y.C. Hui, MD, MSc, FRCSC

KEYWORDS

• Sarcoma • Epidemiology • Etiology • Li-Fraumeni • Radiation

KEY POINTS

- Sarcomas are rare malignant tumors of mesenchymal origin, accounting for less than 1% of all new cancer diagnoses.
- The extremity (particularly the thigh) is the most common location for soft tissue sarcoma. Bone sarcomas are rare and are more commonly seen in the pediatric population.
- Most sarcomas are sporadic and idiopathic, with no associated inherited genetic defect or environmental factor identified as the cause.
- Genetic syndromes associated with sarcoma development include Li-Fraumeni syndrome, retinoblastoma, neurofibromatosis type 1, and familial adenomatous polyposis syndrome.
- Ionizing radiation is strongly linked to subsequent development of bone sarcoma and soft tissue sarcoma. In cases of prior radiation therapy, the secondary sarcoma develops within the radiation field.

INTRODUCTION

Sarcomas make up a broad group of malignant neoplasms of mesenchymal origin. More than 70 histologic subtypes have been identified. However, sarcomas can be classified into 2 broad categories: (1) soft tissue sarcomas (STS), and (2) sarcomas of the bone. In the former group, sarcomas that have histologic resemblance to fat, muscle, nerve sheath, and blood vessels are included and are named accordingly.

EPIDEMIOLOGY

Sarcomas are rare, making up less than 1% of all new cancer diagnoses. There will have been an estimated 1.66 million new cancer diagnoses in 2015 in the United States, of which, only 11,930 cases will have been STS, and 2970 cases, bone sarcomas.¹

Disclosure: Dr J. Hui has no commercial or financial conflicts of interest or any funding sources. Division of Surgical Oncology, Department of Surgery, University of Minnesota, 420 Delaware Street Southeast, Mayo Mail Code 195, Minneapolis, MN 55455, USA
E-mail address: jhui@umn.edu

Surg Clin N Am 96 (2016) 901–914
<http://dx.doi.org/10.1016/j.suc.2016.05.005>

surgical.theclinics.com

0039-6109/16/\$ – see front matter © 2016 Elsevier Inc. All rights reserved.

Soft Tissue Sarcoma

According to the Surveillance, Epidemiology, and End Results Program of the National Cancer Institute, the incidence of STS is approximately 3.4 per 100,000.² The true incidence of STS is likely somewhat underestimated, as some visceral sarcomas are likely counted with their organ of origin rather than with STS. There is a slight male preponderance of 1.4:1.² The median age at diagnosis is 59,² with a bimodal distribution that peaks in the fifth and eighth decades.³

STS occur most commonly on the extremities; upper and lower extremity STS account for 12% and 28%,⁴ respectively, of all STS. The thigh is the most common site of STS, accounting for 44% of all extremity STS.⁴ The most common type of extremity STS is liposarcoma (LPS).⁴ Visceral STS account for 22% of all STS⁴ and include gastrointestinal stromal tumors (GIST) and uterine leiomyosarcoma (LMS). GISTs are most commonly located in the stomach (59%), followed by small intestine (31%), with rectal (3.3%), colonic (2.7%), and esophageal (0.6%) locations being rare.⁵ The median age at diagnosis for GIST is 62.⁵ Retroperitoneal sarcomas account for 16% of all STS, whereas trunk and other sites (including the head and neck) account for 10% and 12%, respectively.⁴ Retroperitoneal sarcomas are typically LPS and LMS.

Overall, LPS is the most common type of STS, accounting for approximately 20% to 25% of all STS.^{2,4,6} LPS can be further subdivided into well-differentiated LPS (also called *atypical lipomatous tumor*), dedifferentiated LPS, myxoid LPS, and pleomorphic LPS.⁷ Other common STS histologic subtypes include LMS (14%) and undifferentiated pleomorphic sarcoma (14%),⁴ formerly known as *malignant fibrous histiocytoma*. The histologic distribution of STS among the various sites is found in [Fig. 1](#).

Bone Sarcoma

Bone sarcomas are even more uncommon, accounting for 0.2% of all new cancer diagnoses.² This disease tends to affect the younger population, most frequently diagnosed in those 20 years or younger.² The age at diagnosis also varies with the histologic subtype. Osteosarcoma is the most common bone sarcoma overall and is more frequently seen in adolescents than in adults.⁸ Similarly, Ewing sarcoma is more common in children and adolescents⁸ but can also be seen in adults. The median age at diagnosis is 15.⁸ Although any bone (or even soft tissue) can be involved,

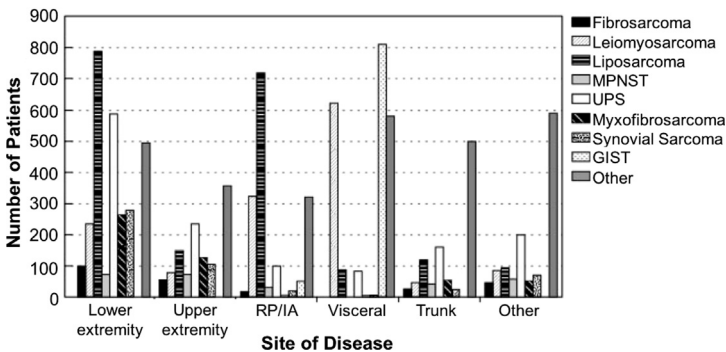


Fig. 1. Histopathology of soft tissue sarcomas by site of disease, N = 10,000. IA, intraabdominal; RP, retroperitoneum; UPS, undifferentiated pleomorphic sarcoma. (From Brennan MF, Antonescu CR, Moraco N, et al. Lessons learned from the study of 10,000 patients with soft tissue sarcoma. *Ann Surg* 2014;260(3):419; with permission.)

Ewing sarcoma is found commonly in the extremities.⁸ Ewing sarcoma is most common in Caucasians and is rare in African-American or Asian populations.⁸ The primary site of Ewing sarcoma also varies by race. In the Caucasian population, Ewing sarcoma is more frequently identified in the bone (80%) than in soft tissues (20%), whereas in the African-American population, the split is more even, with 55% located in bone and 45% located in the soft tissues.⁹

Although bone sarcoma primarily affects the younger population, certain types have a predilection for the adult population. Chondrosarcoma is typically diagnosed between ages 30 and 60 and is the most common subtype of bone sarcoma in adults.⁸ Chordomas are rare, with an incidence of 0.5 per 1 million person-years.⁸ The peak incidence of chordomas is between 50 to 60 years of age, and is rarely seen in patients younger than 40.¹⁰ Although primarily thought of as a disease of the sacrum, there is actually a nearly equal distribution of chordoma between skull base (32%), mobile spine (33%), and sacrum (29%).¹⁰

Cutaneous Sarcoma

Cutaneous sarcomas are far less common than bone sarcomas or STS. The incidence of cutaneous sarcoma is 24.4 per 1 million person-years.¹¹ Kaposi sarcoma is the most common, making up 71% of cutaneous sarcomas.¹¹ Dermatofibrosarcoma protuberans is the second most common, constituting 18% of cutaneous sarcomas, with an incidence of 4.5 per 1 million person-years.¹¹ Dermatofibrosarcoma protuberans is more common in the African-American population than in Caucasians¹¹ and is most commonly identified on the trunk.^{11,12} The mean age at diagnosis is 42.¹² Rare histologic subtypes of cutaneous sarcomas include undifferentiated pleomorphic sarcoma, LMS, and angiosarcoma.¹¹

Pediatric Sarcoma

Despite its rarity, sarcomas can have a significant impact on the population, particularly for those younger than 20 years. STS and bone sarcomas are the third and fourth leading cause of cancer death in this age group, respectively.¹ The incidence of bone sarcomas in children is approximately 9.1 per 1,000,000; this has been stable over the last 4 decades.² The most commonly seen histologic subtypes are osteosarcoma (5.3 per 1,000,000) and Ewing sarcoma (2.8 per 1,000,000).² The childhood incidence of STS is 12.5 per 1,000,000, which has slightly increased over time.² The most common histology is rhabdomyosarcoma, with an incidence of 4.9 per 1,000,000.²

Pediatric Ewing sarcoma (of both bone and soft tissue) is most commonly identified in the extremities and the pelvis.¹³ Specifically, in children ages 1 to 19, 29.4% and 22.8% of Ewing sarcoma are located in the lower extremity and pelvis, respectively.¹⁴ In contrast, the distribution of Ewing sarcoma in infants is relatively even across the various sites: head (17.7%), upper extremity (17.7%), lower extremity (11.8%), pelvis (17.7%), chest (14.7%), abdomen (11.8%), and spine (8.8%).¹⁴

ETIOLOGY

Although there are some genetic defects and environmental factors that have been linked to the development of sarcoma, the most sarcomas are sporadic and idiopathic. The etiology of most sarcomas remains largely unknown.

Genetic Susceptibility

The genetic defects that lead to sarcoma development can be divided into 2 groups (Table 1): (1) simple karyotypic defects, and (2) complex karyotypic defects.¹⁵

Table 1 Types of genetic defects that lead to sarcoma development	
Genetic Defect	Example of Sarcoma Type
Simple karyotypic defect <ul style="list-style-type: none">• Disease-specific chromosomal translocation	<ul style="list-style-type: none">• Ewing sarcoma• Alveolar rhabdomyosarcoma• Synovial sarcoma• Dermatofibrosarcoma protuberans• Desmoplastic small round-cell tumor
Complex karyotypic defect <ul style="list-style-type: none">• Severe genetic instability• Disturbances in cell cycle genes	<ul style="list-style-type: none">• Leiomyosarcoma• Liposarcoma• Undifferentiated pleomorphic sarcoma• Osteosarcoma• Angiosarcoma• Malignant peripheral nerve-sheath tumor

Simple karyotypic defects consist of disease-specific chromosomal translocations that lead to abnormal gene (and protein) function that facilitate sarcoma development. Sarcomas associated with simple karyotypic defects include Ewing sarcoma, alveolar rhabdomyosarcoma, and synovial sarcoma.¹⁵ In Ewing sarcoma, the simple karyotypic defect occurs from the fusion of the DNA-binding domain of *FLI1* (a transcription factor) with the transactivation domain of *EWSR1* (another transcription factor).¹⁵

In contrast, complex karyotypic defects, such as complex chromosomal rearrangements, lead to disturbances in cell cycle genes and severe genetic instability. Sarcomas borne of this pathway tend to occur in older patients, and have a high frequency of mutations in the p53 and retinoblastoma (Rb) signaling pathways.^{15,16} LMS, LPS, angiosarcoma, and osteosarcomas are examples of such tumors.¹⁵ Sarcomas with complex karyotypic defects can also occur as secondary malignancies after prior radiation therapy (RT).

Germline genetic defects are seen in genetic syndromes (Table 2). In a single-center review, approximately 3% of STS were linked to a genetic syndrome.¹⁷ The median age of diagnosis was 37 in patients with a genetic syndrome, significantly younger than in the sporadic population, with a median age of diagnosis of 53.¹⁷ In addition, LPS was seen less frequently in patients with genetic syndromes than in patients with sporadic STS.¹⁷

Li-Fraumeni syndrome

In 1969, Li and Fraumeni¹⁸ described 4 families with development of STS, breast cancer, and other malignant neoplasms in an autosomal dominant fashion.¹⁸ Germline mutations in *TP53* were ultimately identified as the culprit. The loss of p53 protein function impairs the ability of cells with DNA damage to undergo apoptosis.¹⁵ Although germline *TP53* mutations are associated with a variety of cancer types, sarcomas account for 25% of the cancer diagnoses in these patients.¹⁹ Patients with *TP53* mutation-associated sarcoma tend to be younger than patients with sporadic sarcoma. The histology of *TP53* mutation-associated sarcomas tend to also be different from sporadic sarcoma. These differences are illustrated in Fig. 2. Patients with *TP53* mutations are more likely to have osteosarcoma at any age, and rhabdomyosarcoma at age less than 5, than those without germline *TP53* mutations.¹⁹ Furthermore, LMS and LPS are less commonly seen in *TP53* mutation carriers (12%) than in sporadic sarcoma patients (52%).¹⁹ Li-Fraumeni is rare; only 3.6% of adult-onset sarcoma patients carry a germline *TP53* mutation.²⁰ Thus, specific clinical criteria (the Chompret criteria) have been developed to guide germline *TP53* mutation

Table 2
Genetic syndromes and their associated sarcomas

Genetic Syndrome	Mutation	Associated Sarcoma
Li-Fraumeni syndrome	<i>TP53</i>	<ul style="list-style-type: none"> • Osteosarcoma • Rhabdomyosarcoma • Liposarcoma
Retinoblastoma	<i>RB1</i>	<ul style="list-style-type: none"> • Osteosarcoma • Chondrosarcoma • Ewing sarcoma • Uterine leiomyosarcoma • Fibrosarcoma • Rhabdomyosarcoma
Neurofibromatosis type 1	<i>NF-1</i>	<ul style="list-style-type: none"> • Rhabdomyosarcoma • Gastrointestinal stroma tumor • Malignant peripheral nerve sheath tumor
Familial adenomatous polyposis	<i>APC</i>	Desmoid tumor
Familial gastrointestinal stromal tumors	<i>KIT</i> <i>PDGFRA</i>	Gastrointestinal stromal tumor
Carney-Stratakis syndrome	<i>SDH</i>	Gastrointestinal stromal tumor
Bloom's syndrome	<i>BLM</i>	Osteosarcoma
Werner's syndrome	<i>WRN</i>	Osteosarcoma
Rothmund-Thomson syndrome	<i>RECQ4</i>	Osteosarcoma

screening. Other malignancies within the Li-Fraumeni tumor spectrum include brain tumors, premenopausal breast cancer, adrenocortical carcinoma, leukemia, and bronchoalveolar cancer.^{21–23}

Only a small proportion of sarcomas that are associated with an aberrant p53 pathway develop as a result of a germline *TP53* mutation. An alternate loss of the p53 protein has been characterized by the amplification of the *MDM2* gene product. The protein product of the *MDM2* gene functions to bind the p53 protein and to inhibit the transcriptional activity of *TP53*,²⁴ thus resulting in a functional loss of *TP53* activity. This interaction has been found in retroperitoneal LPS, in which *MDM2* and *TP53* expression were seen in both well-differentiated and dedifferentiated LPS but were absent in myxoid and round cell LPS.²⁵ Additionally, well-differentiated LPS can be distinguished diagnostically from lipomas by *MDM2* expression, as lipomas do not overexpress *MDM2*.^{25,26}

Retinoblastoma

Hereditary retinoblastoma (Rb) is caused by a germline mutation in the *RB1* gene, with high penetrance. Approximately 80% to 90% of carriers subsequently have ocular tumors.¹⁶ The *RB1* gene is a tumor-suppressor gene, which encodes the Rb protein. Rb normally functions as a cell cycle regulator by blocking entry to the S phase of the cell cycle.¹⁶ Sarcomas occur in Rb survivors as a result of 2 contributing factors: (1) genetic susceptibility, and (2) prior RT for the Rb.^{16,27} Bone sarcomas account for 25% to 30% of secondary cancers in Rb survivors; they tend to develop at around age 10 to 20 and are thought to be a result of RT and the high accumulative doses of alkylating chemotherapy given for the Rb, although up to 40% of these tumors occur outside of the radiation field.¹⁶ Osteosarcoma is the most common sarcoma of the bone in this population.¹⁶ Other histologic subtypes of bone sarcomas seen are chondrosarcoma and Ewing sarcoma.¹⁶ STS generally develop later than bone

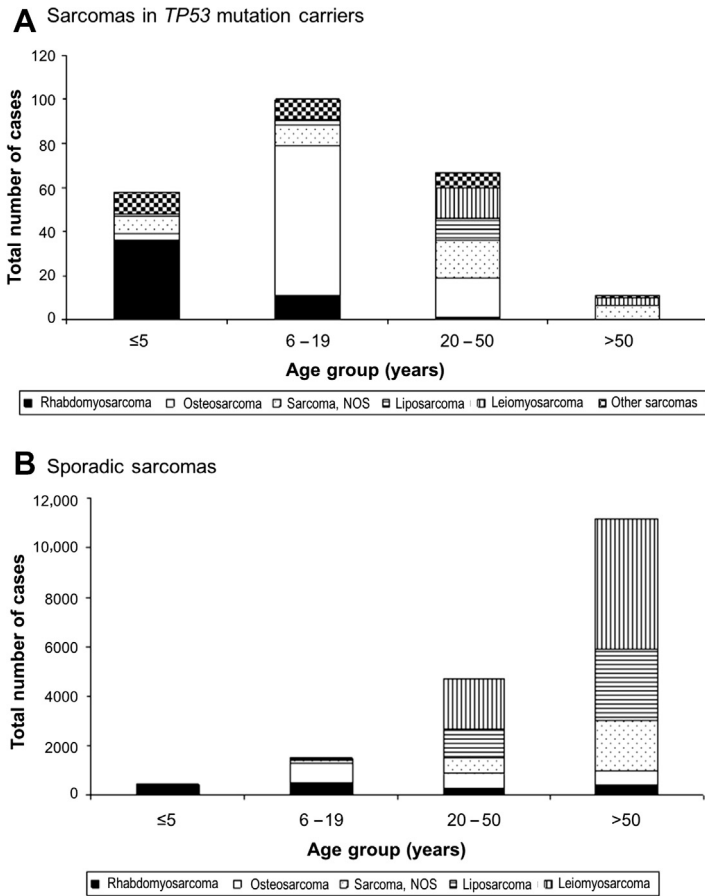


Fig. 2. Distribution of different histologic subtypes by age group, in (A) *TP53* mutation carriers from the International Agency for Research on Cancer *TP53* database, and (B) sporadic sarcoma patients from the Surveillance, Epidemiology, and End Results database. NOS, not otherwise specified. (From Ognjanovic S, Olivier M, Bergemann TL, et al. Sarcomas in *TP53* germline mutation carriers: a review of the IARC *TP53* database. Cancer 2012;118(5):1391; with permission.)

sarcomas, occurring from within 10 years to 50 years after Rb diagnosis. STS make up 12% to 32% of secondary cancers in Rb survivors.¹⁶ The most commonly identified STS in this setting are uterine LMS.¹⁶

Neurofibromatosis type 1

Neurofibromatosis type 1 (NF-1) is also known as von Recklinghausen disease, with an incidence of 1 in 3000 live births, although the phenotype is variable.²⁸ The *NF-1* gene is a tumor-suppressor gene. It normally encodes the protein neurofibromin, a negative regulator of the RAS-MAPK pathway.²⁸ NF-1 is characterized by specific clinical features consisting of neurofibromas (benign tumors arising from Schwann cells), café-au-lait spots, neurofibromas, axillary or inguinal freckling, optic glioma, bony dysplasia, and Lisch nodules.^{28,29} The prevalence of rhabdomyosarcoma in children with NF-1 is 0.02% to 0.03%, which is 20 times higher than in the general

population.²⁸ Rhabdomyosarcoma associated with NF-1 commonly develops in the bladder and prostate.²⁸ There are also STS that are associated with NF-1 in adults, GIST and malignant peripheral nerve sheath tumor (MPNST). The lifetime risk of GIST development for NF-1 patients is 6%.²⁸ Unlike sporadic GISTs, which tend to be solitary gastric tumors, GISTs of NF-1 patients manifest as multifocal disease and are more commonly found in the small intestine.²⁸ The annual incidence of MPNST in NF-1 patients is 0.16%, significantly higher than that of the general population (0.001%).²⁸ These tumors arise typically from preexisting plexiform neurofibromas and have a poorer overall survival than sporadic MPNST.²⁸

Familial adenomatous polyposis

In familial adenomatous polyposis (FAP), a germline mutation in the adenomatous polyposis coli (*APC*) gene results in the development of innumerable colorectal adenomas that ultimately lead to colorectal carcinoma. However, in addition to colorectal carcinoma, a subset (approximately 10%)^{30,31} of FAP patients are also at risk for desmoid tumors. Desmoid tumors can also occur sporadically but are 850 to 1000 times more likely to occur in FAP patients.^{32,33} Desmoid tumors are myofibroblastic tumors that are histologically benign but can be locally aggressive. These tumors commonly occur in the abdominal wall or within the mesentery but can also be found on other extra-abdominal musculoaponeurotic tissues such as the chest wall or inguinal region. Although the etiology of desmoid tumors is unclear, some risk factors have been suggested, such as trauma (ie, surgery),^{30–32} pregnancy,³⁴ and female gender.³² Desmoid tumors are also associated with a mutation 3' to codon 1399³² and codon 1444³¹ of the *APC* gene.^{31,32}

Gastrointestinal stromal tumors

GIST is the most common mesenchymal tumor in the gastrointestinal tract and arises from the interstitial cells of Cajal. The first associated genetic mutation associated with GIST was an activating *KIT* mutation.³⁵ Unlike *TP53*, *RB1*, or *NF-1*, *KIT* is a proto-oncogene. *KIT* mutation results in the gain of function of a tyrosine kinase receptor and subsequent downstream signaling that supports cell proliferation. *KIT* mutations (particularly exons 8, 9, 11, 13, and 17) are seen in 70% to 80% of GIST.³⁶ Subsequently, activating *PDGFRA* (platelet-derived growth factor receptor alpha) mutations (exons 12, 14, 18) were also identified, accounting for 5% to 15% of all GIST.³⁶ Although most GISTs are sporadic (with somatic *KIT* or *PDGFRA* mutations), a small subset occurs as familial GIST, with germline *KIT* or *PDGFRA* mutations, resulting in an inherited predisposition to GIST development.^{36–38} More recently, mutations of succinate dehydrogenase (SDH) have been implicated in patients with wild type *KIT* and *PDGFRA* GISTs. A germline mutation in the SDH enzyme subunits results in Carney-Stratakis syndrome. These patients present with multifocal GISTs, paragangliomas, and pheochromocytomas.^{36,39}

Bloom's syndrome, Werner's syndrome, and Rothmund-Thomson syndrome

Bloom's syndrome was first described as a case of congenital telangiectatic erythema in a patient with dwarfism.⁴⁰ It is an extremely rare autosomal recessive disorder that is more common in the Ashkenazi Jewish population.⁴¹ Clinical characteristics include intrauterine growth restriction, growth deficiency that is persistent into childhood and adulthood, telangiectatic erythema that resembles lupus erythematosus in sun-exposed areas, and the development of malignancies.⁴² A germline mutation in the *BLM* gene on chromosome 15 has been identified. *BLM* normally encodes for a DNA helicase in the RecQ family, which maintains genomic stability.^{41,43} Patients

are at increased risk of all types of malignancies,⁴¹ including osteosarcoma, which is more common in pediatric patients with Bloom's syndrome.⁴²

Werner's syndrome is marked by a germline mutation in the *WRN* gene on chromosome 8.⁴¹ A founder mutation in the *WRN* gene has been identified in the Japanese population.⁴¹ Like Bloom's syndrome, Werner's syndrome is an autosomal recessive disorder, is extremely rare, and is a result of a mutant DNA helicase in the RecQ family.⁴¹ However, unlike Bloom's syndrome, patients with Werner's syndrome are phenotypically normal until adolescence, when an absence of a growth spurt is noted; thus, adults with Werner's syndrome are typically of short stature.⁴¹ Werner's syndrome was first described in 1904 in a family with symptoms of early-onset of age-related diseases, similar to premature aging. The syndrome is associated with early-onset arteriosclerosis, diabetes mellitus, hyperlipidemia, osteoporosis, malignancy of epithelial and mesenchymal origins.⁴⁴ In a review of Japanese case reports, common malignancies were reported to be osteosarcoma, thyroid cancer, and malignant melanoma.^{44,45}

A third syndrome associated with a mutant DNA helicase of the RecQ family is the Rothmund-Thomson syndrome.⁴¹ Most cases of Rothmund-Thomson syndrome are caused by a germline mutation in the *RECQ4* gene on chromosome 8.⁴¹ Patients with Rothmund-Thomson syndrome have characteristic poikiloderma, alopecia, and juvenile cataracts.^{41,46} They, too, are at increased risk of malignancy development, also most notably osteosarcoma.⁴⁷

Ionizing Radiation

Ionizing radiation has been found to increase the risk of subsequent sarcoma development.^{48–51} Those with ionizing radiation exposure include atomic bomb survivors and patients previously treated with RT. In the Life Span Study of Japanese atomic bomb survivors of Hiroshima and Nagasaki, increased cases of bone sarcoma (particularly osteosarcoma) and STS (most commonly leiomyosarcoma) have been reported.^{52,53}

In 1948, diagnostic criteria were outlined for a radiation-induced sarcoma,⁵⁰ which were subsequently modified by Arlen and colleagues⁵¹ (**Box 1**). Briefly, the diagnosis requires prior RT with a new sarcoma arising within the radiation field at least 3 years later. The most common prior cancers associated with subsequent radiation-induced sarcomas are breast cancer and non-Hodgkin's lymphoma^{17,49,54}; therefore, these secondary sarcomas tend to occur on the chest wall or upper extremity.^{17,49} Another common prior cancer is prostate cancer.⁵⁵ Most of these sarcomas are high grade⁴⁹ and are commonly undifferentiated pleomorphic sarcoma, angiosarcoma, undifferentiated spindle cell carcinoma, or leiomyosarcoma.^{17,49,55} Liposarcoma, normally a common histologic subtype of STS, is less frequent among radiation-induced

Box 1

The modified Cahan criteria: diagnosis of a radiation-induced sarcoma.

1. Previous receipt of radiation therapy (RT) for benign or malignant disease.
2. Subsequent sarcoma development within the RT field.
3. Sarcoma is histologically different from the primary cancer for which the RT was given.
4. Latent period of 3 years (between RT and sarcoma development).

Data from Cahan WG, Woodard HQ, et al. Sarcoma arising in irradiated bone; report of 11 cases. Cancer 1948;1(1):3–29; and Arlen M, Higinbotham NL, Huvos AG, et al. Radiation-induced sarcoma of bone. Cancer 1971;28(5):1087–99.

sarcomas.^{17,49} The median latent period between receipt of RT and subsequent sarcoma development in general is approximately 16 years.⁴⁹

Prior breast cancer

Breast cancer is commonly treated with breast conservation therapy, consisting of a segmental mastectomy followed by adjuvant RT. This treatment strategy is equivalent in efficacy to mastectomy for early-stage breast cancer management. There have been reports of subsequent radiation-induced sarcomas in treated breast cancer patients.^{56–61} The first case of radiation-induced angiosarcoma was reported in 1981.⁶² Angiosarcoma is the classical sarcoma subtype associated with radiation for breast cancer. The clinical presentation consists of discolored cutaneous lesions along the surgical scar within the radiation field. These tumors also tend to be high grade.^{54,60} The mean latency period between treatment of the breast cancer with RT and onset of the angiosarcoma is between 6 and 8 years.^{57,60,63} Angiosarcoma of the breast can also be a sporadic disease, albeit rare. Patients with angiosarcoma who received prior RT are significantly older than RT-naïve angiosarcoma patients, although no differences were observed between the 2 groups of patients in terms of tumor size or grade.⁶⁰ Other STS types that have been seen after RT-treated breast cancer are undifferentiated pleomorphic sarcoma and fibrosarcoma.^{57,61} The risk of STS development is 30 times higher after RT doses in excess of 44 Gy than after doses less than 15 Gy.⁶¹ RT, however, has not been found to increase the risk of STS development outside the field of radiation.⁵⁷

Another described sarcoma after the treatment of breast cancer is lymphangiosarcoma, so-called Stewart-Treves syndrome. This syndrome is a rare disease^{17,59} with a poor prognosis. Although classically associated with chronic lymphedema after radical mastectomy, this syndrome can be applied to lymphangiosarcoma that develops from chronic lymphedema of any reason, such as, filariasis, venous stasis, trauma, or groin dissection for melanoma, cervical, or penile cancer.⁶⁴

Despite the descriptions of STS development after treatment of breast cancer, it should be noted that the absolute incidence of these secondary cancers is extremely low (31 STS per 100,000 person-years and 7 angiosarcomas per 100,000 person-years). Reports of these extremely rare secondary sarcomas do not outweigh the benefits gained from adjuvant RT in the treatment of breast cancer, that is, a significant reduction in the risk of local recurrence.

Other Environmental Factors

The strongest link in the environment for sarcoma development is with ionizing radiation, described above. However, other environmental factors have been examined. Exposure to vinyl chloride has been found to increase the risk of angiosarcoma of the liver. Vinyl chloride was used in the plastics industry extensively in the 1970s. The mean latency period from exposure to hepatic angiosarcoma development was 36 years.⁶⁵ Other occupational exposures have been examined in an epidemiologic study in Europe, suggesting an increased risk of bone sarcoma development in blacksmiths, carpenters, bricklayers, and toolmakers, although no specific chemical was identified or implicated.⁶⁶ Finally, certain viruses, particularly in the setting of immunosuppression, have been implicated in the development of STS. The most well known is the association between Kaposi sarcoma and the Kaposi sarcoma-associated herpesvirus, also known as *the human herpesvirus 8*, in patients with human immunodeficiency virus-1.⁶⁷ Kaposi sarcomas are also seen in patients who are immunosuppressed in the absence of human immunodeficiency viral infection, including posttransplant patients^{68–71} and, rarely, even patients with ulcerative colitis treated

with immunosuppressive agents.^{72,73} In particular, the incidence of Kaposi sarcoma was found to be increased in post-renal transplant patients during immunosuppression but not after transplant failure, when immunosuppression was reduced or ceased.⁷⁴ There are also rare reports of an association between the Epstein-Barr virus and smooth muscle tumors, including LMS, which also appears to be related to immunosuppression.^{75–78}

SUMMARY

Bone and soft tissue sarcomas are rare malignancies with largely unknown etiology. Most of these tumors are sporadic, although small subsets can be associated with genetic susceptibility and environmental factors. Genetic syndromes associated with sarcoma development include Li-Fraumeni syndrome, retinoblastoma, neurofibromatosis-1, and familial adenomatous polyposis syndrome. Ionizing radiation is the strongest environmental factor leading to subsequent sarcoma development, particularly RT in a medical setting.

REFERENCES

1. Siegel RL, Miller KD, Jemal A. Cancer statistics, 2015. *CA Cancer J Clin* 2015; 65(1):5–29.
2. Howlader N, Noone AM, Krapcho M, et al. SEER cancer statistics review, 1975–2012. Based on November 2014 SEER data submission, posted to the SEER web site. 2015. Available at: http://seer.cancer.gov/csr/1975_2012/. Accessed December 22, 2015.
3. Bauer HC, Trovik CS, Alvegard TA, et al. Monitoring referral and treatment in soft tissue sarcoma: study based on 1,851 patients from the Scandinavian Sarcoma Group Register. *Acta Orthop Scand* 2001;72(2):150–9.
4. Brennan MF, Antonescu CR, Moraco N, et al. Lessons learned from the study of 10,000 patients with soft tissue sarcoma. *Ann Surg* 2014;260(3):416–22.
5. Guller U, Tarantino I, Cerny T, et al. Population-based SEER trend analysis of overall and cancer-specific survival in 5138 patients with gastrointestinal stromal tumor. *BMC Cancer* 2015;15:557.
6. Toro JR, Travis LB, Wu HJ, et al. Incidence patterns of soft tissue sarcomas, regardless of primary site, in the surveillance, epidemiology and end results program, 1978–2001: an analysis of 26,758 cases. *Int J Cancer* 2006;119(12):2922–30.
7. Fletcher CD, Bridge JA, Hogendoorn PC, et al. WHO Classification of Tumours of Soft Tissue and Bone. Lyon (France): International Agency for Research on Cancer (IARC); 2013.
8. The ESMO/European Sarcoma Network Working Group. Bone sarcomas: ESMO clinical practice guidelines for diagnosis, treatment and follow-up. *Ann Oncol* 2014;25(Suppl 3):iii113–23.
9. Worch J, Matthay KK, Neuhaus J, et al. Ethnic and racial differences in patients with Ewing sarcoma. *Cancer* 2010;116(4):983–8.
10. McMaster ML, Goldstein AM, Bromley CM, et al. Chordoma: incidence and survival patterns in the United States, 1973–1995. *Cancer Causes Control* 2001; 12(1):1–11.
11. Rouhani P, Fletcher CD, Devesa SS, et al. Cutaneous soft tissue sarcoma incidence patterns in the U.S. : an analysis of 12,114 cases. *Cancer* 2008;113(3): 616–27.

12. Kuzel P, Metelitsa AI, Dover DC, et al. Epidemiology of dermatofibrosarcoma protuberans in Alberta, Canada, from 1988 to 2007. *Dermatol Surg* 2012;38(9):1461–8.
13. Lee J, Hoang BH, Ziogas A, et al. Analysis of prognostic factors in Ewing sarcoma using a population-based cancer registry. *Cancer* 2010;116(8):1964–73.
14. Wong T, Goldsby RE, Wustrack R, et al. Clinical features and outcomes of infants with Ewing sarcoma under 12 months of age. *Pediatr Blood Cancer* 2015;62(11):1947–51.
15. Helman LJ, Meltzer P. Mechanisms of sarcoma development. *Nat Rev Cancer* 2003;3(9):685–94.
16. Kleinerman RA, Schonfeld SJ, Tucker MA. Sarcomas in hereditary retinoblastoma. *Clin Sarcoma Res* 2012;2(1):15.
17. Penel N, Grosjean J, Robin YM, et al. Frequency of certain established risk factors in soft tissue sarcomas in adults: a prospective descriptive study of 658 cases. *Sarcoma* 2008;2008:459386.
18. Li FP, Fraumeni JF Jr. Soft-tissue sarcomas, breast cancer, and other neoplasms. A familial syndrome? *Ann Intern Med* 1969;71(4):747–52.
19. Ognjanovic S, Olivier M, Bergemann TL, et al. Sarcomas in TP53 germline mutation carriers: a review of the IARC TP53 database. *Cancer* 2012;118(5):1387–96.
20. Mitchell G, Ballinger ML, Wong S, et al. High frequency of germline TP53 mutations in a prospective adult-onset sarcoma cohort. *PLoS One* 2013;8(7):e69026.
21. Chompret A, Abel A, Stoppa-Lyonnet D, et al. Sensitivity and predictive value of criteria for p53 germline mutation screening. *J Med Genet* 2001;38(1):43–7.
22. Bougeard G, Sesboue R, Baert-Desurmont S, et al. Molecular basis of the Li-Fraumeni syndrome: an update from the French LFS families. *J Med Genet* 2008;45(8):535–8.
23. Tinat J, Bougeard G, Baert-Desurmont S, et al. 2009 version of the Chompret criteria for Li Fraumeni syndrome. *J Clin Oncol* 2009;27(26):e108–9 [author reply: e110].
24. Oliner JD, Pietenpol JA, Thiagalingam S, et al. Oncoprotein MDM2 conceals the activation domain of tumour suppressor p53. *Nature* 1993;362(6423):857–60.
25. Pilotti S, Torre GD, Lavarino C, et al. Distinct mdm2/p53 expression patterns in liposarcoma subgroups: implications for different pathogenetic mechanisms. *J Pathol* 1997;181(1):14–24.
26. Ito M, Barys L, O'Reilly T, et al. Comprehensive mapping of p53 pathway alterations reveals an apparent role for both SNP309 and MDM2 amplification in sarcomagenesis. *Clin Cancer Res* 2011;17(3):416–26.
27. Kleinerman RA, Tucker MA, Tarone RE, et al. Risk of new cancers after radiotherapy in long-term survivors of retinoblastoma: an extended follow-up. *J Clin Oncol* 2005;23(10):2272–9.
28. Brems H, Beert E, de Ravel T, et al. Mechanisms in the pathogenesis of malignant tumours in neurofibromatosis type 1. *Lancet Oncol* 2009;10(5):508–15.
29. Korf BR. Neurofibromatosis. *Handb Clin Neurol* 2013;111:333–40.
30. Gurbuz AK, Giardiello FM, Petersen GM, et al. Desmoid tumours in familial adenomatous polyposis. *Gut* 1994;35(3):377–81.
31. Nieuwenhuis MH, Lefevre JH, Bulow S, et al. Family history, surgery, and APC mutation are risk factors for desmoid tumors in familial adenomatous polyposis: an international cohort study. *Dis Colon Rectum* 2011;54(10):1229–34.
32. Sinha A, Tekkis PP, Gibbons DC, et al. Risk factors predicting desmoid occurrence in patients with familial adenomatous polyposis: a meta-analysis. *Colorectal Dis* 2011;13(11):1222–9.

33. Fallen T, Wilson M, Morlan B, et al. Desmoid tumors – a characterization of patients seen at Mayo Clinic 1976-1999. *Fam Cancer* 2006;5(2):191–4.
34. Burtenshaw SM, Cannell AJ, McAlister ED, et al. Toward observation as first-line management in abdominal desmoid tumors. *Ann Surg Oncol* 2016;23(7):2212–9.
35. Hirota S, Isozaki K, Moriyama Y, et al. Gain-of-function mutations of c-kit in human gastrointestinal stromal tumors. *Science* 1998;279(5350):577–80.
36. Patil DT, Rubin BP. Genetics of gastrointestinal stromal tumors: a heterogeneous family of tumors? *Surg Pathol Clin* 2015;8(3):515–24.
37. Neuhaan TM, Mansmann V, Merkelbach-Bruse S, et al. A novel germline KIT mutation (p.L576P) in a family presenting with juvenile onset of multiple gastrointestinal stromal tumors, skin hyperpigmentations, and esophageal stenosis. *Am J Surg Pathol* 2013;37(6):898–905.
38. Nishida T, Hirota S, Taniguchi M, et al. Familial gastrointestinal stromal tumours with germline mutation of the KIT gene. *Nat Genet* 1998;19(4):323–4.
39. Gaal J, Stratakis CA, Carney JA, et al. SDHB immunohistochemistry: a useful tool in the diagnosis of Carney-Stratakis and Carney triad gastrointestinal stromal tumors. *Mod Pathol* 2011;24(1):147–51.
40. Bloom D. Congenital telangiectatic erythema resembling lupus erythematosus in dwarfs; probably a syndrome entity. *AMA Am J Dis Child* 1954;88(6):754–8.
41. Hickson ID. RecQ helicases: caretakers of the genome. *Nat Rev Cancer* 2003;3(3):169–78.
42. German J. Bloom's syndrome. XX. The first 100 cancers. *Cancer Genet Cytogenet* 1997;93(1):100–6.
43. Ellis NA, Groden J, Ye TZ, et al. The Bloom's syndrome gene product is homologous to RecQ helicases. *Cell* 1995;83(4):655–66.
44. Yamamoto K, Imakiire A, Miyagawa N, et al. A report of two cases of Werner's syndrome and review of the literature. *J Orthop Surg (Hong Kong)* 2003;11(2):224–33.
45. Goto M, Miller RW, Ishikawa Y, et al. Excess of rare cancers in Werner syndrome (adult progeria). *Cancer Epidemiol Biomarkers Prev* 1996;5(4):239–46.
46. Simon T, Kohlhase J, Wilhelm C, et al. Multiple malignant diseases in a patient with Rothmund-Thomson syndrome with RECQL4 mutations: Case report and literature review. *Am J Med Genet A* 2010;152A(6):1575–9.
47. Hicks MJ, Roth JR, Kozinetz CA, et al. Clinicopathologic features of osteosarcoma in patients with Rothmund-Thomson syndrome. *J Clin Oncol* 2007;25(4):370–5.
48. Henderson TO, Whitton J, Stovall M, et al. Secondary sarcomas in childhood cancer survivors: a report from the Childhood Cancer Survivor Study. *J Natl Cancer Inst* 2007;99(4):300–8.
49. Riad S, Biau D, Holt GE, et al. The clinical and functional outcome for patients with radiation-induced soft tissue sarcoma. *Cancer* 2012;118(10):2682–92.
50. Cahan WG, Woodard HQ, Higinbotham NL, et al. Sarcoma arising in irradiated bone; report of 11 cases. *Cancer* 1948;1(1):3–29.
51. Arlen M, Higinbotham NL, Huvos AG, et al. Radiation-induced sarcoma of bone. *Cancer* 1971;28(5):1087–99.
52. Samartzis D. Exposure to ionizing radiation and development of bone sarcoma: new insights based on atomic-bomb survivors of Hiroshima and Nagasaki. *J Bone Joint Surg Am* 2011;93(11):1008.
53. Samartzis D, Nishi N, Cologne J, et al. Ionizing radiation exposure and the development of soft-tissue sarcomas in atomic-bomb survivors. *J Bone Joint Surg Am* 2013;95(3):222–9.

54. Brady MS, Gaynor JJ, Brennan MF. Radiation-associated sarcoma of bone and soft tissue. *Arch Surg* 1992;127(12):1379–85.
55. Cha C, Antonescu CR, Quan ML, et al. Long-term results with resection of radiation-induced soft tissue sarcomas. *Ann Surg* 2004;239(6):903–10.
56. Karlsson P, Holmberg E, Johansson KA, et al. Soft tissue sarcoma after treatment for breast cancer. *Radiother Oncol* 1996;38(1):25–31.
57. Mery CM, George S, Bertagnolli MM, et al. Secondary sarcomas after radiotherapy for breast cancer: sustained risk and poor survival. *Cancer* 2009;115(18):4055–63.
58. D'Angelo SP, Antonescu CR, Kuk D, et al. High-risk features in radiation-associated breast angiosarcomas. *Br J Cancer* 2013;109(9):2340–6.
59. Kirova YM, Gambotti L, De Rycke Y, et al. Risk of second malignancies after adjuvant radiotherapy for breast cancer: a large-scale, single-institution review. *Int J Radiat Oncol Biol Phys* 2007;68(2):359–63.
60. Vorburger SA, Xing Y, Hunt KK, et al. Angiosarcoma of the breast. *Cancer* 2005;104(12):2682–8.
61. Rubino C, Shamsaldin A, Le MG, et al. Radiation dose and risk of soft tissue and bone sarcoma after breast cancer treatment. *Breast Cancer Res Treat* 2005;89(3):277–88.
62. Maddox JC, Evans HL. Angiosarcoma of skin and soft tissue: a study of forty-four cases. *Cancer* 1981;48(8):1907–21.
63. Depla AL, Scharloo-Karels CH, de Jong MA, et al. Treatment and prognostic factors of radiation-associated angiosarcoma (RAAS) after primary breast cancer: a systematic review. *Eur J Cancer* 2014;50(10):1779–88.
64. Sharma A, Schwartz RA. Stewart-Treves syndrome: pathogenesis and management. *J Am Acad Dermatol* 2012;67(6):1342–8.
65. Collins JJ, Jammer B, Sladeczek FM, et al. Surveillance for angiosarcoma of the liver among vinyl chloride workers. *J Occup Environ Med* 2014;56(11):1207–9.
66. Merletti F, Richiardi L, Bertoni F, et al. Occupational factors and risk of adult bone sarcomas: a multicentric case-control study in Europe. *Int J Cancer* 2006;118(3):721–7.
67. Newton R, Carpenter L, Casabonne D, et al. A prospective study of Kaposi's sarcoma-associated herpesvirus and Epstein-Barr virus in adults with human immunodeficiency virus-1. *Br J Cancer* 2006;94(10):1504–9.
68. Carencio C, Faure S, Ursic-Bedoya J, et al. Solid, non-skin, post-liver transplant tumors: key role of lifestyle and immunosuppression management. *World J Gastroenterol* 2016;22(1):427–34.
69. Rossetto A, Tulissi P, De Marchi F, et al. De Novo solid tumors after kidney transplantation: is it time for a patient-tailored risk assessment? Experience from a single center. *Transplant Proc* 2015;47(7):2116–20.
70. Hosseini-Moghaddam SM, Soleimanirahbar A, Mazzulli T, et al. Post renal transplantation Kaposi's sarcoma: a review of its epidemiology, pathogenesis, diagnosis, clinical aspects, and therapy. *Transpl Infect Dis* 2012;14(4):338–45.
71. Engels EA, Pfeiffer RM, Fraumeni JF Jr, et al. Spectrum of cancer risk among US solid organ transplant recipients. *JAMA* 2011;306(17):1891–901.
72. Svrcek M, Tiret E, Bennis M, et al. KSHV/HHV8-associated intestinal Kaposi's sarcoma in patient with ulcerative colitis receiving immunosuppressive drugs: report of a case. *Dis Colon Rectum* 2009;52(1):154–8.
73. Rodriguez-Pelaez M, Fernandez-Garcia MS, Gutierrez-Corral N, et al. Kaposi's sarcoma: an opportunistic infection by human herpesvirus-8 in ulcerative colitis. *J Crohns Colitis* 2010;4(5):586–90.

74. van Leeuwen MT, Webster AC, McCredie MR, et al. Effect of reduced immunosuppression after kidney transplant failure on risk of cancer: population based retrospective cohort study. *BMJ* 2010;340:c570.
75. Miettinen M. Smooth muscle tumors of soft tissue and non-uterine viscera: biology and prognosis. *Mod Pathol* 2014;27(Suppl 1):S17–29.
76. Hussein K, Rath B, Ludewig B, et al. Clinico-pathological characteristics of different types of immunodeficiency-associated smooth muscle tumours. *Eur J Cancer* 2014;50(14):2417–24.
77. Nur S, Rosenblum WD, Katta UD, et al. Epstein-Barr virus-associated multifocal leiomyosarcomas arising in a cardiac transplant recipient: autopsy case report and review of the literature. *J Heart Lung Transplant* 2007;26(9):944–52.
78. Rogatsch H, Bonatti H, Menet A, et al. Epstein-Barr virus-associated multicentric leiomyosarcoma in an adult patient after heart transplantation: case report and review of the literature. *Am J Surg Pathol* 2000;24(4):614–21.