World J Surg (2017) 41:1705–1711
DOI 10.1007/s00268-017-3977-8

SURGICAL SYMPOSIUM CONTRIBUTION

Endoscopic Treatment of High-Grade Dysplasia and Early Esophageal Cancer

Francisco Schlottmann[1] · Marco G. Patti[1,2] · Nicholas J. Shaheen[2]

Published online: 8 March 2017
© Société Internationale de Chirurgie 2017

Abstract

Background The emergence of novel endoscopic modalities has challenged the role of surgery for patients with Barrett's esophagus (BE) and high-grade dysplasia (HGD) or early esophageal adenocarcinoma.

Aim The aim of this study was to review the available evidence of the endoscopic treatment of HGD and early esopahgeal adenocarcinoma.

Results For most patients with BE and HGD, endoscopic ablative therapy is the preferred treatment strategy. Patients with intramucosal adenocarcinoma (T1a) should be treated with endoscopic mucosal resection (EMR) followed by ablative therapy, in order to eradicate the remaining intestinal metaplasia. The best approach to treatment of adenocarcinoma with submucosal invasion (T1b) remains elusive. Endoscopic resection may be suitable for low-risk T1b tumors (well differentiated, without lymphovascular invasion and with superficial submucosal invasion); however, further data are necessary to better risk stratify this group. Careful endoscopic surveillance is recommended following complete eradication of intestinal metaplasia to detect recurrent disease.

Conclusion Patients with BE and HGD should undergo endoscopic ablative therapy. Patients with T1a adenocarcinoma should be treated with EMR and subsequent ablation of the entire BE segment. Low-risk T1b tumors may be suitable for endoscopic resection.

Introduction

Barrett's esophagus (BE) is defined as the presence of at least 1 cm of salmon-colored mucosa proximal to the gastroesophageal junction with biopsy confirmation of intestinal metaplasia [1]. BE is considered a premalignant condition, and the presence and grading of dysplasia is the most important predictive factor for the development of esophageal adenocarcinoma. Patients with high-grade dysplasia (HGD) present an annual incidence of adenocarcinoma of 7% [2].

Traditionally, esophagectomy has been the standard treatment for patients who have BE with HGD and/or intramucosal adenocarcinoma (IMC). The basis for this practice was evidence showing a 17–40% prevalence of occult adenocarcinoma and 1–2% prevalence of nodal metastasis in surgical esophagectomy specimens [3–6]. However, this treatment modality is associated with relatively high morbidity and some mortality, even at experienced centers [7, 8].

Endoscopic therapy has evolved over the last decade, and therapeutic procedures such as radiofrequency ablation

✉ Nicholas J. Shaheen
nshaheen@med.unc.edu

[1] Department of Surgery and Center for Esophageal Diseases and Swallowing, University of North Carolina, Chapel Hill, NC, USA

[2] Division of Gastroenterology and Hepatology, Department of Medicine, Center for Esophageal Diseases and Swallowing, University of North Carolina at Chapel Hill, CB#7080, Chapel Hill, NC 27599-7080, USA

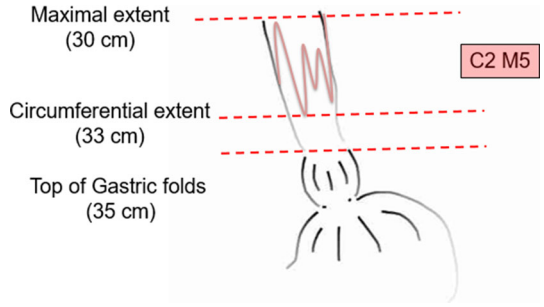

Fig. 1 Prague classification for Barrett's esophagus

(RFA) and endoscopic mucosal resection (EMR) have challenged the role of surgery for early stage cancers. Clearly, an advantage of endoscopic treatment is very low complication rate and procedural mortality [9]. Given the risk profile associated with the surgical treatment, endoscopic therapy could be favorable for early tumors if adequate oncologic outcomes could be achieved.

This review will discuss the diagnosis and endoscopic treatment of dysplastic BE and superficial esophageal adenocarcinoma.

Diagnosis

Endoscopic evaluation should be performed with high-resolution white light endoscopy to optimize visualization of mucosal details. A segment of BE $\geq$3 cm is defined as long-segment BE, while segments <3 cm are defined as short-segment BE [10]. In order to provide a uniform description, the Prague classification should be employed in the report of BE [11]. This classification assesses the circumferential extent of metaplasia (C) and the maximal extent of metaplasia (M) (Fig. 1). Biopsies every 2 cm of segment length or a total of eight biopsies if the segment is <2 cm are recommended at the initial exam. Electronic chromoendoscopy enhances imaging of the mucosal and vascular patterns in BE and may increase the detection of dysplasia [12]. More recently, confocal and volumetric laser endomicroscopy has shown promising results for the endoscopic diagnosis of BE [13]. In addition, EMR should be employed for diagnosis if nodularity is found during inspection.

As dysplasia remains the best surrogate marker for cancer risk in patients with BE, an accurate diagnosis of dysplasia is essential. HGD is diagnosed when there is marked nuclear pleomorphism (more pronounced than in low-grade dysplasia) and a loss of cellular polarity. Unfortunately, the grading of dysplasia remains subjective and is often inaccurate, especially in centers without expert gastrointestinal pathologists [14]. Due to interobserver variability in the interpretation of dysplasia, current guidelines of the American College of Gastroenterology [1] recommend that patients with BE and dysplasia undergo a review by two pathologists, at least one of whom has specialized expertise in gastrointestinal pathology.

Invasive adenocarcinoma is diagnosed when neoplastic cells are seen crossing the basement membrane of the epithelium. Early adenocarcinomas are defined as those that do not extend beyond the submucosa layer of the esophagus. In the American Joint Committee on Cancer (AJCC) staging system, they are grouped as T1 tumors, and further subdivided in intramucosal lesions (T1a), limited to the lamina propria or muscularis mucosae, and submucosal lesions (T1b), with extension through the muscularis mucosae into the submucosal layer [15]. If malignancy is detected, an accurate clinical staging is crucial. Endoscopic ultrasound (EUS) remains the gold standard for staging esophageal cancer and is appropriate to rule out lymph nodes metastasis, as a suspicious node can be detected and biopsied for cytological evaluation [16]. However, EUS cannot be considered a reliable test to assess the depth of the tumor invasion in early adenocarcinomas. To address this limitation, EMR provides a large tissue specimen that is generally well orientated, which allows accurate histological staging of the infiltration depth [17].

Endoscopic management of HGD

Endoscopic intervention should be considered for patients with HGD with two main objectives: treatment of the primary lesion and eradication of the remaining intestinal metaplasia to decrease the risk of metachronous tumors. The best studied endoscopic ablative therapies for dysplastic BE include photodynamic therapy, radiofrequency ablation, and cryotherapy.

Photodynamic therapy (PDT) employs photosensitizing agents and subsequent activating light to damage tissue. Photosensitizing drugs are inactive until they are exposed to a certain wavelength of light, in which case the drug absorbs the light energy and transfers its energy to an oxygen molecule, creating a high-energy singlet oxygen molecule that causes tissue necrosis. This technique usually requires multiple administrations to completely eradicate columnar-lined epithelium in the esophagus. There are two forms of commonly used photosensitizing agents: the intravenous (IV) porfimer sodium or hematoporphyrin derivative, and orally administered 5-aminolevulinic acid. PDT may result in complete eradication of HGD in some patients and was demonstrated in a randomized controlled trial to decrease the occurrence of adenocarcinoma when compared with untreated controls (13 vs. 28%) [18]. Long-term survival in patients with HGD treated with PDT



Fig. 2 Radiofrequency ablation catheters

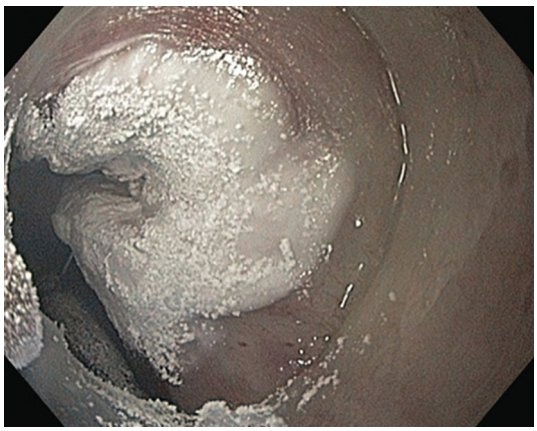

Fig. 3 Spray liquid nitrogen cryotherapy

appears to be comparable to that of patients treated with esophagectomy [19]. Over a 5-year follow-up, mortality in the PDT group was 9% (11/129) and in the surgery group was 8.5% (6/70) [19]. However, the high expenses of the procedures and the relatively high incidence of fibrotic strictures have limited its use.

Radiofrequency ablation (RFA) is currently the preferred ablation method, as it has proven to be highly effective for the eradication of intestinal metaplasia and dysplasia [20, 21]. RFA is delivered through either a balloon-based, fully circumferential device or a cap-based focal device (Fig. 2). This heat-based technique aims to destroy the mucosal tissue, while limiting the damage to the muscularis mucosa and deeper structures to prevent stricture formation. Multiple endoscopic treatments may be required depending on the length of the BE segment and the tissue response. Treatment is often performed every 2–3 months until complete eradication is achieved, using a variety of RFA catheters. The first randomized controlled trial included 127 patients with dysplastic BE, and participants were assigned in a 2:1 ratio to RFA or a sham-controlled procedure [20]. Complete eradication of HGD was achieved in 81% of the patients with RFA versus 19% of those in the control group ($p < 0.001$). In addition, 2.4% of the treated patients with HGD progressed to cancer, compared with 19% of those in the sham arm. Adverse events were limited, and no procedure-related deaths were recorded. This study showed that RFA was associated with a low complication rate while preventing progression in most patients with HGD.

Cryoablation (CRY) is a non-contact method that consists in a directed spray of liquid nitrogen at—196 °C onto the Barrett's mucosa (Fig. 3). Deep freezing and slow thawing causes disruption of cells, vascular ischemia, and thrombosis, resulting in necrosis of the superficial esophageal layers. In contrast to heat-based ablation, cryotherapy leaves the tissue architecture intact and may result in less stricture formation. However, the CRY technique harbors some drawbacks. First, an equal distribution in the application of the cryogenic fluid onto the esophageal mucosa may be challenging, especially in cases when the esophageal mucosa is irregular, such as in patients with strictures. Second, contact between the cryogenic fluid and the esophageal tissue results in the development of gas that needs direct ventilation using an orogastric tube to prevent complications due to barotrauma. Despite these challenges, retrospective studies have shown high rates of complete eradication of intestinal metaplasia and dysplasia with minimal side effects [22, 23]. More recently, a balloon-based cryotherapy device has become commercially available [24]. This device uses a through-the-scope device to deliver liquid nitrous oxide into a balloon placed in apposition to the Barrett's epithelium. Preliminary data on this technique are promising [25].

Overall, given the safety profile and well-documented efficacy of RFA, this procedure remains the preferred modality for most patients with BE and flat HGD (absence of ulcers or nodules). Patients with discrete visible lesions should undergo EMR prior to ablation therapy.

Endoscopic management of early esophageal cancer

The management of superficial adenocarcinoma, in contrast to BE with HGD, requires consideration of multiple other factors. Nodal status is one of the most important long-term prognostic factors for esophageal adenocarcinoma [26, 27]. For this reason, while EMR for T1a tumors has gained acceptance, endoscopic resection for T1b cancers remains under debate due to the increased risk of nodal involvement in these tumors. The risk of lymph node

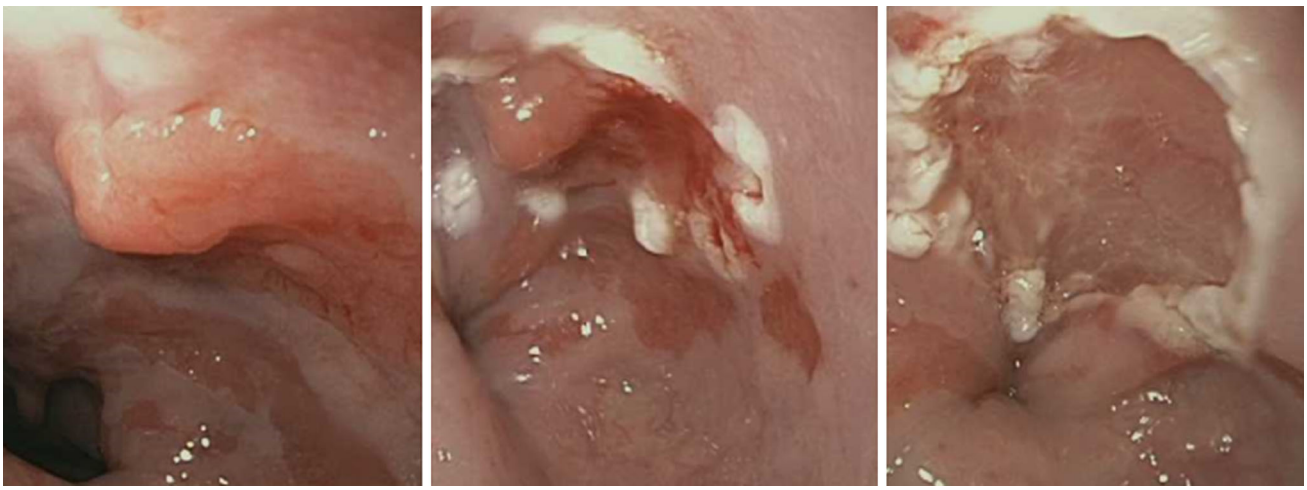

Fig. 4 Endoscopic mucosal resection of esophageal lesion

metastases for a T1b adenocarcinoma is reported variably, but reaches 30% in some reports [28–30].

EMR can be performed using a number of different techniques, with the choice depending on the size of the lesion being treated, its contour and the experience of the operator. Early techniques involved injecting a cushion of fluid, for instance a 1:100,000 solution of epinephrine in normal saline, into the submucosal layer underneath the desired lesion in order to lift it. Afterward, a barbed snare was used to resect the lesion. This technique is well-suited to polypoid lesions, but sometimes left unresected pieces of the lesion when the lesion was very flat or depressed. A second technique uses a band ligator to create a "pseudopolyp." The lesion is first suctioned into the ligation cap of the endoscope, and a band is released around the base of the lesion, in a manner similar to that used to band an esophageal varix. The lesion, now artificially elevated at the tip of the pseudopolyp, is then resected with a snare. This technique is maybe successfully performed even in flat, depressed, or ulcerated lesions. Finally, a third technique employs a cap with a rim. On the inner surface of the cap rim, a snare is deployed. The lesion is sucked into the cap, and the snare is tightened, such that all the tissue in the cap is now ensnared. Electrocautery is then used to resect the tissue in the snare (Fig. 4).

Encouraging survival outcomes for selected T1a tumors have been reported with EMR. Ell and colleagues selected 100 subjects with lesion of <2 cm diameter, which were moderately or well differentiated, and without invasion into the submucosa or evidence of lymph node metastases. Endoscopic treatment of these lesions resulted in a 98% 5-year survival in these patients [9]. Most recently, the same group confirmed the long-term efficacy and safety of EMR in a series of 1000 patients with intramucosal adenocarcinoma with 91.5% 5-year survival [31]. These excellent outcomes may be due to the low rate of nodal involvement in patients with T1a tumors [32]. It is worth mentioning that patients with complete endoscopic resection of a T1a adenocarcinoma should undergo subsequent ablation of the entire BE segment. The risk of development metachronous neoplasia is decreased when remaining non-dysplastic BE tissue is treated with ablation after EMR. A prospective case series showed a 16.5% rate of neoplasia recurrence after combined resection and ablation, compared to 29.9% recurrence without ablation [33].

As mentioned above, data are conflicting regarding the endoscopic treatment of T1b tumors. The possibility of avoiding esophagectomy and the frequent existence of these lesions in poor surgical candidates has led to the increasing use of endotherapy for tumors extending into the submucosa. Previous studies have determined risk factors for nodal involvement in T1b tumors, in order to select appropriate candidates for curative endoscopic therapy. Histological characteristics such as poor differentiation, depth of submucosal invasion, and lymphovascular invasion (LVI) have been related to increased risk of lymphatic spread [34–36]. In a study of 74 patients who had endoscopic mucosal resection and then subsequent esophagectomy, Boys and colleagues reported that none of the patients with submucosal invasion $\leq$500 μm, no LVI, and no poor differentiation had involved nodes. However, with an increasing number of risk factors, the likelihood of involved lymph nodes increased, reaching 50% when all three factors were present [36]. A prospective study of 66 patients with low-risk T1b tumors (superficial submucosal invasion (sm1), good to moderate differentiation (G1-G2) and without lymphovascular invasion) showed a 84% 5-year survival rate with endoscopic therapy [37]. Over the

course of this study, however, 18.9% of these patients developed metachronous neoplasia and 1.9% had lymph node metastases discovered by EUS-guide aspirate during follow-up. Since fine needle aspirate of periesophageal nodes was not routinely performed, the rate of nodal metastatic recurrence may have been underestimated. Molena et al. [38] analyzed the outcomes of 23 patients with T1b adenocarcinoma who underwent surgical resection. A total of 6 patients (26.1%) had lymph node involvement on the final pathology and the disease-specific 5-years survival was 88%, with no significant difference between those with or without nodal involvement, concluding that esophagectomy was curative in the majority of patients with submucosal tumors even in the presence of nodal metastases [38]. Whether T1b tumors with favorable features are best treated with endoscopic or surgical approaches remains unclear.

Overall, we believe endoscopic therapy is the preferred therapeutic approach for patients with T1a adenocarcinoma. In patients with T1b adenocarcinoma, endoscopic resection may be an alternative strategy to esophagectomy in those tumors which are superficial (sm1), well differentiated and without lymphovascular invasion, as well as in patients who are poor surgical candidates.

Surveillance

Endoscopic surveillance should follow complete eradication of intestinal metaplasia to help detect recurrent disease. Surveillance for patients with baseline HGD or intramucosal adenocarcinoma is recommended every 3 months for the first year, every 6 months in the second year, and annually thereafter [1]. During endoscopic surveillance, careful inspection of the gastroesophageal junction should be performed with high-resolution white light imaging and narrow band imaging in order to detect mucosal abnormalities that may reflect recurrent intestinal metaplasia or dysplasia [1]. Routine biopsies of both the distal esophagus and the high cardia may reveal recurrent or residual dysplasia which is not evident to the eye endoscopically.

Recurrent intestinal metaplasia in the tubular esophagus is not an uncommon event after initially successful RFA and occurs in as many as one in four patients. In a recent report of 5521 patients undergoing RFA as part of a registry, recurrence of intestinal metaplasia in the esophagus occurred in 20% of patients who achieve complete eradication, at a mean follow-up of 2.4 years [39]. Fortunately, recurrent metaplasia and dysplasia after endoscopic therapy are usually amenable to further EMR and ablation [40, 41]. Development of subsquamous BE, on the other hand, may not be detected during surveillance and remains a concern. Gray and colleagues performed a systematic review and reported that subsquamous intestinal metaplasia was found in 14.2% of the patients after PDT and in 0.9% of the patients after RFA [42]. It is worth to mention, however, that most of the studies analyzed did not describe how frequently biopsy specimens contained sufficient subepithelial lamina propria to be informative for buried metaplasia. Thus, buried disease may have been underestimated in these reports. In fact, Zhou et al. [43], using endoscopic three-dimensional optical coherence tomography, found buried disease in 63% of the patients after RFA. Nevertheless, considering the low rates of subsquamous adenocarcinoma after ablative therapy, the real clinical value of the detection of residual buried disease remains uncertain [44], as does the most appropriate therapy for buried intestinal metaplasia when it is found.

Conclusions

Endoscopic therapy is an effective modality for the management of patients with BE and HGD or early esophageal adenocarcinoma. For most patients with BE and HGD, endoscopic mucosal resection of any visible mucosal lesion, followed by RFA of the remaining flat intestinal metaplasia, is the preferred treatment strategy. Patients with intramucosal adenocarcinoma (T1a) should be treated with EMR followed by ablative therapy, in order to eradicate the remaining intestinal metaplasia. The best approach to treatment of adenocarcinoma with submucosal invasion (T1b) remains elusive, as relevant data are conflicting. Endoscopic resection may be suitable for low-risk T1b tumors (well differentiated, without lymphovascular invasion and with superficial submucosal invasion); however data on this approach are preliminary. Careful endoscopic surveillance is recommended following complete eradication of intestinal metaplasia to detect recurrent disease.

Compliance with ethical standards

Conflict of interest The authors have no conflict of interest to declare.

References

1. Shaheen NJ, Falk GW, Iyer PG, Gerson LB (2016) ACG clinical guideline: diagnosis and management of Barrett's esophagus. Am J Gastroenterol 111:30–50
2. Rastogi A, Puli S, El-Serag HB et al (2008) Incidence of esophageal adenocarcinoma in patients with Barrett's esophagus and high-grade dysplasia: a meta-analysis. Gastrointest Endosc 67:394–398
3. Heitmiller RF (2003) Prophylactic esophagectomy in Barrett esophagus with high-grade dysplasia. Langenbecks Arch Surg 388(2):83–87

4. Tseng EE, Wu TT, Yeo CJ, Heitmiller RF (2003) Barrett's esophagus with high grade dysplasia: surgical results and long-term outcome–an update. J Gastrointest Surg 7(2):164–170
5. Reed MF, Tolis G Jr, Edil BH, Allan JS, Donahue DM, Gaissert HA, Moncure AC, Wain JC, Wright CD, Mathisen DJ (2005) Surgical treatment of esophageal high-grade dysplasia. Ann Thorac Surg 79(4):1110–1115
6. Dunbar KB, Spechler SJ (2012) The risk of lymph-node metastases in patients with high-grade dysplasia or intramucosal carcinoma in Barrett's esophagus: a systematic review. Am J Gastroenterol 107(6):850–862
7. Markar SR, Karthikesalingam A, Thrumurthy S, Low DE (2012) Volume-outcome relationship in surgery for esophageal malignancy: systematic review and meta-analysis 2000–2011. J Gastrointest Surg 16(5):1055–1063
8. Raymond DP, Seder CW, Wright CD, Magee MJ, Kosinski AS, Cassivi SD, Grogan EL, Blackmon SH, Allen MS, Park BJ, Burfeind WR, Chang AC, DeCamp MM, Wormuth DW, Fernandez FG, Kozower BD (2016) Predictors of major morbidity or mortality after resection for esophageal cancer: a society of thoracic surgeons general thoracic surgery database risk adjustment model. Ann Thorac Surg 102(1):207–214
9. Ell C, May A, Pech O, Gossner L, Guenter E, Behrens A, Nachbar L, Huijsmans J, Vieth M, Stolte M (2007) Curative endoscopic resection of early esophageal adenocarcinomas (Barrett's cancer). Gastrointest Endosc 65(1):3–10
10. Sharma P, Morales TG, Sampliner RE (1998) Short segment Barrett's esophagus–the need for standardization of the definition and of endoscopic criteria. Am J Gastroenterol 93(7): 1033–1036
11. Sharma P, Dent J, Armstrong D, Bergman JJ, Gossner L, Hoshihara Y, Jankowski JA, Junghard O, Lundell L, Tytgat GN, Vieth M (2006) The development and validation of an endoscopic grading system for Barrett's esophagus: the Prague C & M criteria. Gastroenterology 131(5):1392–1399
12. Qumseya BJ, Wang H, Badie N, Uzomba RN, Parasa S, White DL, Wolfsen H, Sharma P, Wallace MB (2013) Advanced imaging technologies increase detection of dysplasia and neoplasia in patients with Barrett's esophagus: a meta-analysis and systematic review. Clin Gastroenterol Hepatol 11(12):1562–1570
13. Canto MI, Anandasabapathy S, Brugge W, Falk GW, Dunbar KB, Zhang Z, Woods K, Almario JA, Schell U, Goldblum J, Maitra A, Montgomery E, Kiesslich R (2014) Confocal endomicroscopy for Barrett's esophagus or Confocal Endomicroscopy for Barrett's Esophagus (CEBE) Trial Group. In vivo endomicroscopy improves detection of Barrett's esophagus-related neoplasia: a multicenter international randomized controlled trial (with video). Gastrointest Endosc 79(2):211–221
14. Alikhan M, Rex D, Khan A, Rahmani E, Cummings O, Ulbright TM (1999) Variable pathologic interpretation of columnar lined esophagus by general pathologists in community practice. Gastrointest Endosc 50:23–26
15. Edge SB, Byrd DR, Compton CC et al (2010) AJCC cancer, staging manual, 7th edn. Springer, New York
16. Marsman WA, Brink MA, Bergman JJ, Tytgat GN, ten Kate FJ, van Lanschot JJ, Fockens P (2006) Potential impact of EUS-FNA staging of proximal lymph nodes in patients with distal esophageal carcinoma. Endoscopy 38:825–829
17. Pouw RE, Heldoorn N, Alvarez Herrero L, ten Kate FJ, Visser M, Busch OR, van Berge Henegouwen MI, Krishnadath KK, Weusten BL, Fockens P, Bergman JJ (2011) Do we still need EUS in the workup of patients with early esophageal neoplasia? A retrospective analysis of 131 cases. Gastrointest Endosc 73(4):662–668
18. Overholt BF, Lightdale CJ, Wang KK, Canto MI, Burdick S, Haggitt RC, Bronner MP, Taylor SL, Grace MG, Depot M (2005) International photodynamic group for high-grade dysplasia in Barrett's esophagus. Photodynamic therapy with porfimer sodium for ablation of high-grade dysplasia in Barrett's esophagus: international, partially blinded, randomized phase III trial. Gastrointest Endosc 62(4):488–498
19. Prasad GA, Wang KK, Buttar NS, Wongkeesong LM, Krishnadath KK, Nichols FC 3rd, Lutzke LS, Borkenhagen LS (2007) Long-term survival following endoscopic and surgical treatment of high-grade dysplasia in Barrett's esophagus. Gastroenterology 132(4):1226–1233
20. Shaheen NJ, Sharma P, Overholt BF, Wolfsen HC, Sampliner RE, Wang KK, Galanko JA, Bronner MP, Goldblum JR, Bennett AE, Jobe BA, Eisen GM, Fennerty MB, Hunter JG, Fleischer DE, Sharma VK, Hawes RH, Hoffman BJ, Rothstein RI, Gordon SR, Mashimo H, Chang KJ, Muthusamy VR, Edmundowicz SA, Spechler SJ, Siddiqui AA, Souza RF, Infantolino A, Falk GW, Kimmey MB, Madanick RD, Chak A, Lightdale CJ (2009) Radiofrequency ablation in Barrett's esophagus with dysplasia. N Engl J Med 360(22):2277–2288
21. Shaheen NJ, Overholt BF, Sampliner RE, Wolfsen HC, Wang KK, Fleischer DE, Sharma VK, Eisen GM, Fennerty MB, Hunter JG, Bronner MP, Goldblum JR, Bennett AE, Mashimo H, Rothstein RI, Gordon SR, Edmundowicz SA, Madanick RD, Peery AF, Muthusamy VR, Chang KJ, Kimmey MB, Spechler SJ, Siddiqui AA, Souza RF, Infantolino A, Dumot JA, Falk GW, Galanko JA, Jobe BA, Hawes RH, Hoffman BJ, Sharma P, Chak A, Lightdale CJ (2011) Durability of radiofrequency ablation in Barrett's esophagus with dysplasia. Gastroenterology 141(2):460–468
22. Shaheen NJ, Greenwald BD, Peery AF, Dumot JA, Nishioka NS, Wolfsen HC, Burdick JS, Abrams JA, Wang KK, Mallat D, Johnston MH, Zfass AM, Smith JO, Barthel JS, Lightdale CJ (2010) Safety and efficacy of endoscopic spray cryotherapy for Barrett's esophagus with high-grade dysplasia. Gastrointest Endosc 71(4):680–685
23. Gosain S, Mercer K, Twaddell WS, Uradomo L, Greenwald BD (2013) Liquid nitrogen spray cryotherapy in Barrett's esophagus with high-grade dysplasia: long-term results. Gastrointest Endosc 78(2):260–265
24. Friedland S, Triadafilopoulos G (2011) A novel device for ablation of abnormal esophageal mucosa (with video). Gastrointest Endosc 74(1):182–188
25. Canto MI, Shin EJ, Khashab MA et al. (2016) Multifocal nitrous oxide cryoballoon ablation with or without Endoscopic mucosal resection (EMR) for treatment of neoplastic Barrett's Esophagus (BE): preliminary results of a prospective clinical trial in treatment-naive and previously ablated patients. Digestive Disease Week (DDW) presentation 638
26. Cabau M, Luc G, Terrebonne E, Belleanne G, Vendrely V, Sa Cunha A, Collet D (2013) Lymph node invasion might have more prognostic impact than R status in advanced esophageal adenocarcinoma. Am J Surg 205(6):711–717
27. Bhamidipati CM, Stukenborg GJ, Thomas CJ, Lau CL, Kozower BD, Jones DR (2012) Pathologic lymph node ratio is a predictor of survival in esophageal cancer. Ann Thorac Surg 94(5):1643–1651
28. Pennathur A, Farkas A, Krasinskas AM, Ferson PF, Gooding WE, Gibson MK, Schuchert MJ, Landreneau RJ, Luketich JD (2009) Esophagectomy for T1 esophageal cancer: outcomes in 100 patients and implications for endoscopic therapy. Ann Thorac Surg 87:1048–1054
29. Sepesi B, Watson TJ, Zhou D, Polomsky M, Litle VR, Jones CE, Raymond DP, Hu R, Qiu X, Peters JH (2010) Are endoscopic therapies appropriate for superficial submucosal esophageal adenocarcinoma? An analysis of esophagectomy specimens. J Am Coll Surg 210:418–427

30. Hagen JA, DeMeester TR (2001) Esophageal adenocarcinoma. Ann Thorac Surg 72:1430–1432
31. Pech O, May A, Manner H, Behrens A, Pohl J, Weferling M, Hartmann U, Manner N, Huijsmans J, Gossner L, Rabenstein T, Vieth M, Stolte M, Ell C (2014) Long-term efficacy and safety of endoscopic resection for patients with mucosal adenocarcinoma of the esophagus. Gastroenterology 146(3):652–660
32. Leers JM, DeMeester SR, Oezcelik A, Klipfel N, Ayazi S, Abate E, Zehetner J, Lipham JC, Chan L, Hagen JA, DeMeester TR (2011) The prevalence of lymph node metastases in patients with T1 esophageal adenocarcinoma a retrospective review of esophagectomy specimens. Ann Surg 253(2):271–278
33. Pech O, Behrens A, May A, Nachbar L, Gossner L, Rabenstein T, Manner H, Guenter E, Huijsmans J, Vieth M, Stolte M, Ell C (2008) Long-term results and risk factor analysis for recurrence after curative endoscopic therapy in 349 patients with high-grade intraepithelial neoplasia and mucosal adenocarcinoma in Barrett's oesophagus. Gut 57(9):1200–1206
34. Cen P, Hofstetter WL, Correa AM, Wu TT, Lee JH, Ross WA, Davilla M, Swisher SG, Fukami N, Rashid A, Maru D, Ajani JA (2008) Lymphovascular invasion as a tool to further subclassify T1b esophageal adenocarcinoma. Cancer 112(5):1020–1027
35. Ancona E, Rampado S, Cassaro M, Battaglia G, Ruol A, Castoro C, Portale G, Cavallin F, Rugge M (2008) Prediction of lymph node status in superficial esophageal carcinoma. Ann Surg Oncol 15(11):3278–3288
36. Boys JA, Worrell SG, Chandrasoma P, Vallone JG, Maru DM, Zhang L, Blackmon SH, Dickinson KJ, Dunst CM, Hofstetter WL, Lada MJ, Louie BE, Molena D, Watson TJ, DeMeester SR (2016) Can the risk of lymph node metastases be gauged in endoscopically resected submucosal esophageal adenocarcinomas? A multi-center study. J Gastrointest Surg 20:6–12
37. Manner H, Pech O, Heldmann Y, May A, Pohl J, Behrens A, Gossner L, Stolte M, Vieth M, Ell C (2013) Efficacy, safety, and longterm results of endoscopic treatment for early stage adenocarcinoma of the esophagus with low-risk sm1 invasion. Clin Gastroenterol Hepatol 11(6):630–635
38. Molena D, Schlottmann F, Boys JA, Blackmon SH, Dickinson KJ, Dunst CM, Hofstetter WL, Lada MJ, Louie BE, Mungo B, Watson TJ, DeMeester SR (2016) Esophagectomy following endoscopic resection of submucosal esophageal cancer: a highly curative procedure even with nodal metastases. J Gastrointest Surg 21(1):62–67
39. Pasricha S, Bulsiewicz WJ, Hathorn KE, Komanduri S, Muthusamy VR, Rothstein RI, Wolfsen HC, Lightdale CJ, Overholt BF, Camara DS, Dellon ES, Lyday WD, Ertan A, Chmielewski GW, Shaheen NJ (2014) Durability and predictors of successful radiofrequency ablation for Barrett's esophagus. Clin Gastroenterol Hepatol 12(11):1840–1847
40. Phoa KN, Pouw RE, van Vilsteren FG, Sondermeijer CM, Ten Kate FJ, Visser M, Meijer SL, van Berge Henegouwen MI, Weusten BL, Schoon EJ, Mallant-Hent RC, Bergman JJ (2013) Remission of Barrett's esophagus with early neoplasia 5 years after radiofrequency ablation with endoscopic resection: a Netherlands cohort study. Gastroenterology 145(1):96–104
41. Gaddam S, Singh M, Balasubramanian G, Thota P, Gupta N, Wani S, Higbee AD, Mathur SC, Horwhat JD, Rastogi A, Young PE, Cash BD, Bansal A, Vargo JJ, Falk GW, Lieberman DA, Sampliner RE, Sharma P (2013) Persistence of nondysplastic Barrett's esophagus identifies patients at lower risk for esophageal adenocarcinoma: results from a large multicenter cohort. Gastroenterology 145(3):548–553
42. Gray NA, Odze RD, Spechler SJ (2011) Buried metaplasia after endoscopic ablation of Barrett's esophagus: a systematic review. Am J Gastroenterol 106(11):1899–1908
43. Zhou C, Tsai TH, Lee HC, Kirtane T, Figueiredo M, Tao YK, Ahsen OO, Adler DC, Schmitt JM, Huang Q, Fujimoto JG, Mashimo H (2012) Characterization of buried glands before and after radiofrequency ablation by using 3-dimensional optical coherence tomography (with videos). Gastrointest Endosc 76(1):32–40
44. Shafa S, Shaheen NJ (2016) Buried Barrett's esophagus-a sheep in sheep's clothing. J Gastrointest Surg 20:1281–1283