Tomosynthesis in Breast Cancer Imaging

How Does It Fit into Preoperative Evaluation and Surveillance?

Mohammad Eghtedari, MD, PhD[a], Catherine Tsai, MD[b], Julie Robles, MD[b], Sarah L. Blair, MD[c], Haydee Ojeda-Fournier, MD[a,*]

KEYWORDS

• Breast cancer • Digital mammography • Digital breast tomosynthesis
• Breast imaging • Diagnostic breast imaging • Mammography
• Image-guided interventions

KEY POINTS

- Digital breast tomosynthesis is a quasi-three-dimensional radiograph mammogram with radiation dose well below the maximum allowed by the Mammography Quality Standards Act.
- Digital breast tomosynthesis has been shown to increase the number of breast cancers detected while lowering the callback rates when compared with full-field digital mammography.
- Availability of digital breast tomosynthesis–guided breast interventions allows for the minimally invasive sampling of lesions detected with this new modality.
- Digital breast tomosynthesis shows increase in the detection of sclerosing papillary lesions and scars; however, fewer cysts and fibroadenomas are called back for evaluation.

INTRODUCTION

Screening mammography has been shown in multiple, long-term, randomized clinical trials to decrease breast cancer mortality rates by 30% and possibly more.[1–6] These randomized clinical trials were started 40 years ago and used screen-film mammography. In 2005, the Food and Drug Administration (FDA) approved the use of

Disclosure Statement: The authors have nothing to disclose.

[a] Department of Radiology, Breast Imaging Section, UC San Diego Health, Moores Cancer Center, 3855 Health Sciences Drive, #0846, La Jolla, CA 92093-0846, USA; [b] Department of Surgery, University of California San Diego, 9500 Gilman drive, La Jolla, CA 92093-0846, USA; [c] Department of Surgery, Division of Surgical Oncology, UC San Diego Health, Moores Cancer Center, 3855 Health Sciences Drive, La Jolla, CA 92093-0846, USA
* Corresponding author.
E-mail address: hojeda@ucsd.edu

Surg Oncol Clin N Am 27 (2018) 33–49
http://dx.doi.org/10.1016/j.soc.2017.07.004
surgonc.theclinics.com
1055-3207/18/© 2017 Elsevier Inc. All rights reserved.

full-field digital mammography (FFDM) and since then, most mammographic units in the United States are FFDM. The DIMIST trial[7] showed that there was no difference in breast cancer detection between screen-film mammography and FFDM except in three groups of women: (1) those younger than 50 years old, (2) those with dense breast tissue, and (3) premenopausal or perimenopausal women. In that subgroup of women, FFDM found more cancers. Both screen-film mammography and FFDM use x-ray to create a two-dimensional (2D) image of the breast. The main limitation of 2D mammography is that the entire volume of tissue is displayed as a planar image with tissue overlap. In dense breasts, the overlap may obscures masses, the so-called masking effect.[8] In 2011, the FDA approved the first digital breast tomosynthesis (DBT) unit. Since then, additional vendors have obtained FDA approval for commercial DBT units. DBT overcomes the overlapping of tissue limitation of 2D mammography by generating images of the breast in planes.

In addition to screening for breast cancer, x-ray mammography is used to evaluate patients presenting with breast clinical findings as the first-line imaging modality in patients 30 years old or older. Mammography is also used in the preoperative- and postoperative evaluation of patients with breast cancer and for image guidance in patients requiring wire localization or biopsy of nonpalpable breast lesions that are not seen on ultrasound. DBT has rapidly been adopted in clinical practices across the United States because it detects more invasive breast cancers and reduces the callback rate. DBT is also used in the diagnostic setting and is referred to as a better mammogram, which is specifically true in the evaluation of patients with dense breast tissue.

This article reviews the technology used to create a DBT study, summarizes recent clinical studies, and focuses on the utility of DBT in the preoperative evaluation and surveillance of patients.

TECHNIQUE

DBT, first described by Niklason and colleagues[9] in 1997, reconstructs a tomographic quasi-three-dimensional (3D) radiographic image of the breast by applying a mathematical algorithm to a few low-dose 2D projection images. Reconstructed 3D images are superior to 2D mammograms mainly because they provide blurring of the tissue above and below the selected plane lowering the effect of overlapping breast tissue. A composite 2D image, which looks like a conventional FFDM image, can also be generated from the projection images, the so-called synthetic view.

In DBT, the breast is compressed against a detector while the x-ray tube rotates around the breast in an arc and captures a series of 2D images that are known as projections.[10,11] Because of the limited angular rotation of the x-ray tube, the z-resolution of the 3D (ie, perpendicular to the detector surface) is worse than that of in-plane resolution. However, even this limited z-resolution seems to be sufficient to lower the superimposition of breast tissue resulting in better cancer detection and lower callback rates as reported in the literature.

The FDA has approved the following DBT systems with the year approved shown in parenthesis: Hologic Selenia Dimensions (2011), GE SenoClaire (2014), Siemens Mammomat Inspiration (2015), Fujifilm ASPIRE Cristalle (2017), and GE Senographe Pristina (2017). Most DBT machines use similar components, such as a full-field digital detector, breast compression mechanism, and an x-ray tube mounted on an arm that rotates around the compressed static breast. The x-ray tube may rotate continuously (Hologic, Bedford, MA, USA and Siemens, Malvern, MA, USA) or may rotate in steps (GE, Waukesha, WI, USA). The detector is usually static; however, Hologic Selenia

uses a rotating detector. The angular range of rotation of the x-ray tube is 15° acquiring 15 projections for (Hologic, Bedford, MA, USA and Fujifilm, Torrance, CA, USA), 25° acquiring nine projections for GE, and 50° acquiring 25 images for (Siemens malvern, PA, USA).[10,12] Hologic and Siemens use a filtered back projection algorithm; this is the same algorithm that is used to reconstruct computed tomography images. However, the GE machines use an iterative method to reconstruct 3D images. The optimal parameters, such as the number of projections and the extent of angular rotation to obtain DBT, are the subject of continued debate.

Because of the limited number of projection images, reconstructed DBT images are prone to artifacts.[13] The most common artifact is the repeated and shifted projection of a high-density object, such as calcification and metallic markers on adjacent images, the "zippering" artifact. Mathematical algorithms are suggested to minimize this artifact.[14] Another artifact is truncation artifact that generates bright horizontal lines at the edge of the reconstructed image.

Because tomosynthesis enables separation of tissue in the z-axis, one may conclude that the DBT would not require the breast to be compressed. Förnvik and colleagues[15] investigated the effect of reduced compression on the breast during DBT by allowing three radiologists to subjectively rate the quality of visualizing glandular tissue on DBT obtained with full compression and reduced compression; they concluded that the reviewer radiologists significantly preferred the DBT obtained with full compression. Compression of the breast spreads the glandular tissue, reduces the scattering of photons, decreases the dose to the breast, and reduces motion artifact. Therefore, all DBT machines use a breast compression mechanism similar to FFDM.

Fig. 1 shows images from a DBT study including a thin slice and a thick slab. In a different patient, the standard 2D and the synthetic craniocaudal views are shown in a heterogeneously dense breast. DBT vendors have gained FDA approval, or are in the process of gaining approval, to have the synthetic view replace the 2D view, a move that will further decrease radiation dose from DBT.

Radiation Dose

The radiation dose of a DBT is the summation of the absorbed glandular tissue dose (AGD) from all low-dose projections.[16] The estimated AGD for a standard breast size during DBT has been reported to be in the range of 1.74 to 1.9 mGy, which is lower than the Mammography Quality Standards Act limit of 3 mGy per view.[17] Paulis and colleagues[18] calculated the radiation exposure of breasts undergoing DBT using GE SenoClaire and compared it with FFDM and concluded that the AGD was lower with DBT as compared with FFDM for breast thickness more than 50 mm and was equivalent between DBT and FFDM when the thickness of the breast was 50 mm or less. Shin and colleagues[19] calculated AGD for 149 subjects who underwent mammography with both FFDM and DBT and concluded that mediolateral oblique projection DBT with craniocaudal projection FFDM resulted in maximum detection of lesions with minimal increase in AGD when compared with conventional FFDM obtained in craniocaudal and mediolateral oblique projections.

Svahn and colleagues[17] compared the dose of radiation of DBT with that of FFDM and concluded that the dose for obtaining each view between DBT and FFDM is comparable; however, the glandular dose increases up to 2.23 times when two-view DBT is obtained along with FFDM. Synthetic 2D images, which are reconstructed from projection images, reduce the total glandular dose when they are substituted for FFDM.

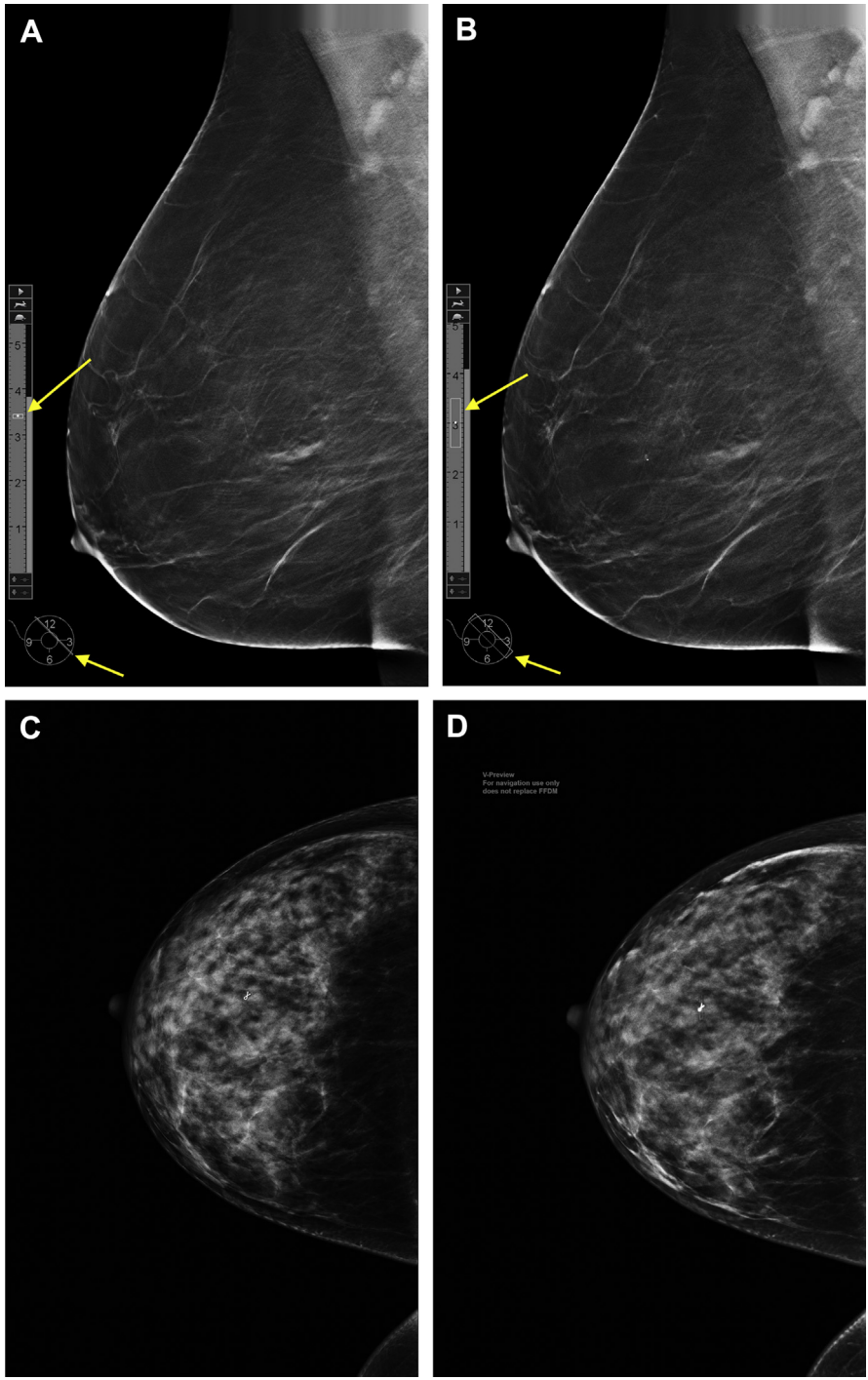

Fig. 1. The DBT study is a combination of 2D views and a cine displayed (similar to computed tomography) stack of slices or slabs. (*A*) Single DBT slice. Note the navigation sidebar on the

Breast Density

Heterogeneously dense and extremely dense breast tissue decreases the sensitivity of mammograms and increases the chance of developing an interval cancer despite mammographic screening.[20] A meta-analysis of screen-detected cancers in more than 10,000 subjects with dense breast tissue who underwent mainly biennial mammography using both DBT and FFDM demonstrated detection of an additional 3.9 cancers per 1000 screens when DBT was used. Houssami[21] suggested that based on the reported literature on the performance of DBT in dense breasts, patients with dense breast tissue may not need an "adjunct" screening method if DBT is used. A review article by Destounis and colleagues[22] shows that the greatest reduction in callback rate happens when DBT is used for women with dense breast tissue and in those younger than 50 years old. Overall, it seems that the benefit of DBT for women with dense breast tissue is related to both increasing the sensitivity of mammogram to detect cancer and reducing callback rate.

Contraindications to Digital Breast Tomosynthesis

There is no absolute contraindication for breast tomosynthesis; however, it is found that the deleterious effect of silicone implants in obscuring findings is more prominent for DBT as compared with FFDM.[23] Another factor that may limit the application of DBT is related to the longer exposure time during DBT as compared with FFDM and the fact that the x-ray tube rotates around the patient's breast. Therefore, patients with severe kyphosis and those with limited mobility may not be ideal candidates for DBT. In these types of patients, comfort is the limiting factor for performing DBT.

CLINICAL TRIALS

STORM Trial

Several clinical trials have been performed to study the diagnostic utility of DBT when used in conjunction with 2D mammography screening. Although there are few trials to date on this new modality of breast imaging, studies generally show a significant improvement in diagnostic accuracy with the addition of DBT to conventional screening methods.

The STORM[24] trial was a large prospective study that compared 2D mammography with DBT to 2D mammography alone. The patient population comprised of 7292 asymptomatic Italian women aged 48 and older at standard risk for breast cancer. A total of 59 cancers were detected from this population, 39 were detected using conventional 2D mammography. An additional 20 cancers were detected when DBT was used with 2D mammography. There were no cancers detected with 2D only that were not detected with combination study (DBT with 2D mammography modality). The results also showed that there was a decrease in false positives when DBT was used in conjunction with 2D mammography compared with mammography alone (36% compared with 18%). This study showed that the addition of DBT in screening a

left side of the image is a thin bar on both the slice number and the anatomic diagram (*arrows*). (*B*) In comparison, a slab is a thicker volume represented by a bar rather than line on the navigation tools (*arrows*). The slices allows for better margin analysis, whereas the slabs are better at identifying calcifications. (*C*) 2D craniocaudal view mammogram obtained at the time of combination study (2D and DBT) in a heterogeneously dense breast. (*D*) For comparison the synthetic view generated from the DBT data, which is FDA approved in some vendors to completely replace the 2D portion of the examination.

population of asymptomatic women at average risk of breast cancer could increase the detection of breast cancer while decreasing the rate of false-positive results.

TOMMY Trial

The TOMMY trial[25] was a multicenter retrospective reading study that compared the diagnostic performance among three separate reading arms of the study: conventional 2D mammography alone versus 2D mammography with DBT versus synthetic 2D mammography with DBT in women 47 to 73 years old. Synthetic 2D mammograms were created using existing software that created 2D images from single DBT scans, simulating a conventional 2D image. The readers in the study consisted of radiologists, advanced practitioner radiographers, and breast clinicians that had a track record of high-volume film reading and met minimum experience criteria. The readers assessed level of suspicion for cancer for each lesion and recorded decisions to recall or not. Readers also made assessments of lesion visibility, extent, density, and discrimination. The results showed that there was a significant improvement in specificity when DBT was used in conjunction with 2D images or synthetic images compared with 2D images alone. This result was observed irrespective of mammographic density, age, tumor size, and dominant radiologic feature and in invasive carcinoma and ductal carcinoma in situ (DCIS).

In a substudy of the TOMMY trial, the main radiologic features were assessed in the three reading arms. It was observed that DBT was more advantageous for lesions in which a mass was the main radiologic feature rather than microcalcifications. Tomosynthesis facilitated detection of stellate lesions, which tend to have greater desmoplastic reaction, resulting in more spiculated lesions. However, there was also an increase in detection of benign lesions with tomosynthesis, including radial scars and complex sclerosing lesions (discussed later), increasing false positives that may lead to a higher negative biopsy rate. However, disadvantages of identifying these lesions may be outweighed by the increased detection of malignant lesions.

It is well known that dense breast tissue increases the risk of breast cancer, and that dense breasts make imaging interpretation more difficult. Another substudy of the TOMMY trial showed that although there is a high degree of variation in observed breast density between image readers, commercially available software can provide a more reliable assessment of breast density. Comparing reader assessments of lesions with various breast densities, there was a significant improvement in sensitivity in women with breast density greater than 50% when DBT is used in conjunction with 2D mammography.

Clinical Performance Reader Trials

A recent radiologist performance study by Rafferty and colleagues[26] found that the diagnostic accuracy for combined DBT and 2D mammography was superior to that of 2D mammography alone. The increase in sensitivity was the largest in cases of invasive cancers. It was thought that DBT reduced tissue superimposition, rendering lesions more visible, especially for masses, asymmetries, and areas of architectural distortion. When lesions were broken down into calcification or noncalcification lesions, nearly all the gain in reader performance was attributable to noncalcification cases. The study also showed that recall rates for noncancer cases for all readers was significantly decreased with the addition of DBT, similar to results seen in the STORM trial. This study concluded that given the emotional, financial, and clinical costs of false positives, DBT has the potential to reduce the risks associated with callbacks.

Table 1 summarizes the clinical performance of DBT compared with conventional 2D mammography.

BENEFITS OF SCREENING WITH DIGITAL BREAST TOMOSYNTHESIS

In the randomized European clinical trials of DBT the two demonstrated benefits of screening with DBT have been an increase in breast cancer detection and, more importantly, a decrease in callback rates. The callback rate is the number of women that are asked to return for diagnostic evaluation from a screening mammogram study. The national benchmark for callback rates is 10% or less.[27] Calling a patient back from screening mammogram is expensive and anxiety inducing; most callbacks result in a negative diagnostic evaluation, with the inciting finding deemed to be overlapping tissue. Additional retrospective trials are discussed next.

Cancer Detection Rates

The thin slices obtained through the breast during DBT allows for better lesion visualization and margin analysis and increased cancer detection rates, benefiting patients with all types of breast density. For example, in a study by Friedewald and colleagues,[28] the detection of invasive breast cancer increased from 2.9 to 4.1 per 1000 women screened. This is a relative increase of 41%. The detection of DCIS, however, was unchanged. A tissue density subanalysis of the Friedewald study by Rafferty and colleagues[29] showed that although the dense and the nondense groups benefited from DBT, the heterogeneously dense group of women had the largest benefit, even over the extremely dense group. In addition to showing increased cancer detection rates, the Friedewald study showed a statistically significant decrease in callback rates.

Callback Rates

Some studies have shown no significant increase in cancer detection rates but have demonstrated a significant decrease in callback rates. For example, Hass and colleagues[30] showed a 29.7% decrease in callback rates and no significant increase in cancer detection. Sharpe and colleagues,[31] however, showed an 18.8% decrease in callback rates while demonstrating a 54.3% increase in cancer detection rates. Sharpe's study also suggested that patients with dense breast tissue benefit more from DBT.

Fig. 2 is an example of a breast cancer detected only on DBT in a patient with dense breasts.

Table 1
Summary of clinical performance of digital breast tomosynthesis compared with full-field digital mammography 2D mammography

	Sensitivity (%)	Specificity (%)	Accuracy (%)	False Positives (%)	PPV (%)	NPV (%)
2D Mammo	63–87	58–95	86.9	4.5	43–96	69–92
Tomosynthesis	91	88	90	—	95.5	77
2D Mammo + Tomo	76–99	69–96	—	6.6	50–93	95
2D Mammo + Tomo + US	97.7	82.8	93.7	—	94.0	96.3
Synthetic 2D Mammo + Tomo	88	71	—	—	—	—

Abbreviations: Mammo, mammography; NPV, negative predictive value; PPV, positive predictive value; Tomo, tomosynthesis; US, ultrasound.

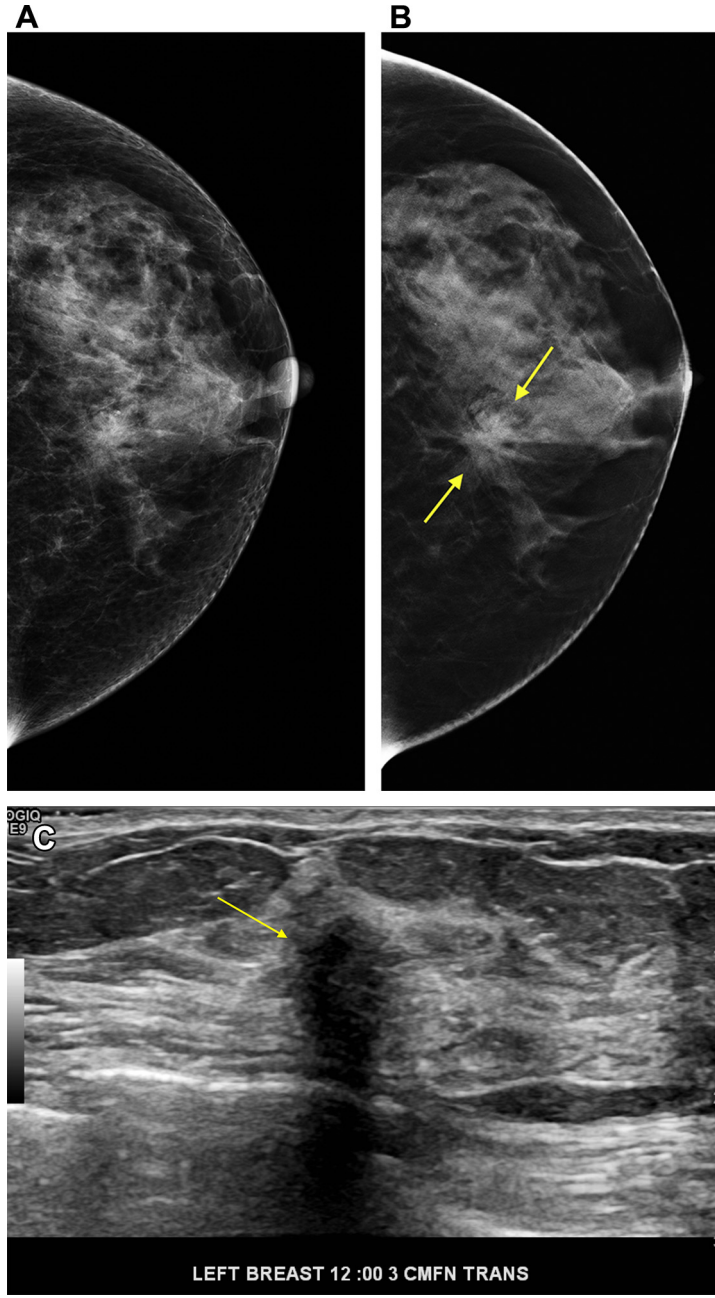

Fig. 2. 2D craniocaudal view (*A*) demonstrates no significant abnormality. (*B*) Single-slice DBT image demonstrates an irregular mass with spiculated margins in the posterior central left breast (*shown between the arrows*). A targeted ultrasound (*C*) of the lesion in question (*arrow*) demonstrates a nonparallel mass with angular margins and posterior shadowing, biopsy proven to be an invasive lobular breast cancer.

CALCIFICATIONS

Detection

Kopans and colleagues[32] had two radiologists compare the clarity of visualizing calcifications in mammograms of 119 women who underwent both 2D and DBT in a nonblinded study and concluded that DBT showed calcifications with superior clarity in 41.6% and with equal clarity in 50.4% when compared with 2D.

However, Tagliafico and colleagues[33] had six radiologists randomly, and in a blinded study, classify 109 microcalcifications on DBT and 2D and concluded that the 2D imaging provided higher sensitivity as compared with DBT (100% vs 91.1%), whereas the specificity of DBT was better than 2D (100% vs 94.6%).

Another nonblinded study compared the visibility of 179 microcalcifications on 2D with that of DBT and concluded that in 92.2% of cases, DBT provided equivalent or superior visualization of microcalcifications.[34]

Fig. 3 shows a case of DBT screen detected DCIS in a patient with dense breasts.

Extent of Ductal Carcinoma In Situ by Digital Breast Tomosynthesis

Berger and colleagues[35] determined the size of DCIS in 33 known cases of DCIS reviewed by three radiologists using FFDM and DBT and compared them with the final size on the pathology report of the surgical specimen. The results indicated that the estimated size of DCIS was more accurate when DBT was used. Another study evaluated the size estimation of 173 malignant breast lesions using DBT and 2D and concluded that "mis-sizing" was significantly less when DBT was used.[36]

EXTENT OF DISEASE

Imaging assessment of newly diagnosed breast cancer is integral to staging disease and can dictate the treatment course. Therefore, it is paramount that preoperative evaluation reflects the extent of disease before surgical intervention.

Assessment

Mun and colleagues[36] showed DBT to be more accurate than the current standard of 2D mammography in determining the local extent of breast cancer in the preoperative planning stage, especially in women with dense breasts. The study population was comprised of 169 women with one or more BI-RADS 4, 5, or 6 lesions. The lesions were then characterized as "mis-sized" if the predicted size differed by more than 1 cm than the size at the time of surgery. The results of the study showed that lesion size was more often overestimated with 2D compared with DBT. Furthermore, 2D mammography more commonly mis-sized lesions in women with dense breasts compared with size estimates using DBT.

A study by Mariscotti and coworkers[37] showed that DBT performs as well as MRI when added to conventional imaging (2D mammography and ultrasound) for preoperative assessment in women with breast cancer. The study examined 200 women with histologically proven breast cancer who had undergone DBT, MRI, 2D mammography, and ultrasound imaging. The addition of DBT to 2D mammography increased sensitivity of detecting breast cancer to 97.7%, which is close to the 98.8% sensitivity of MRI. Furthermore, when ultrasound was added to DBT and 2D mammography, sensitivity was nearly equal when compared with MRI (93.7% vs 92.3%). In another study comparing these modalities, Kim and colleagues[38] showed that the addition of DBT to 2D mammography also increased the positive predictive value and lowered false-positive rates when compared with digital mammography with MRI. Although these small, single institutions studies suggest that DBT may be equivalent to preoperative

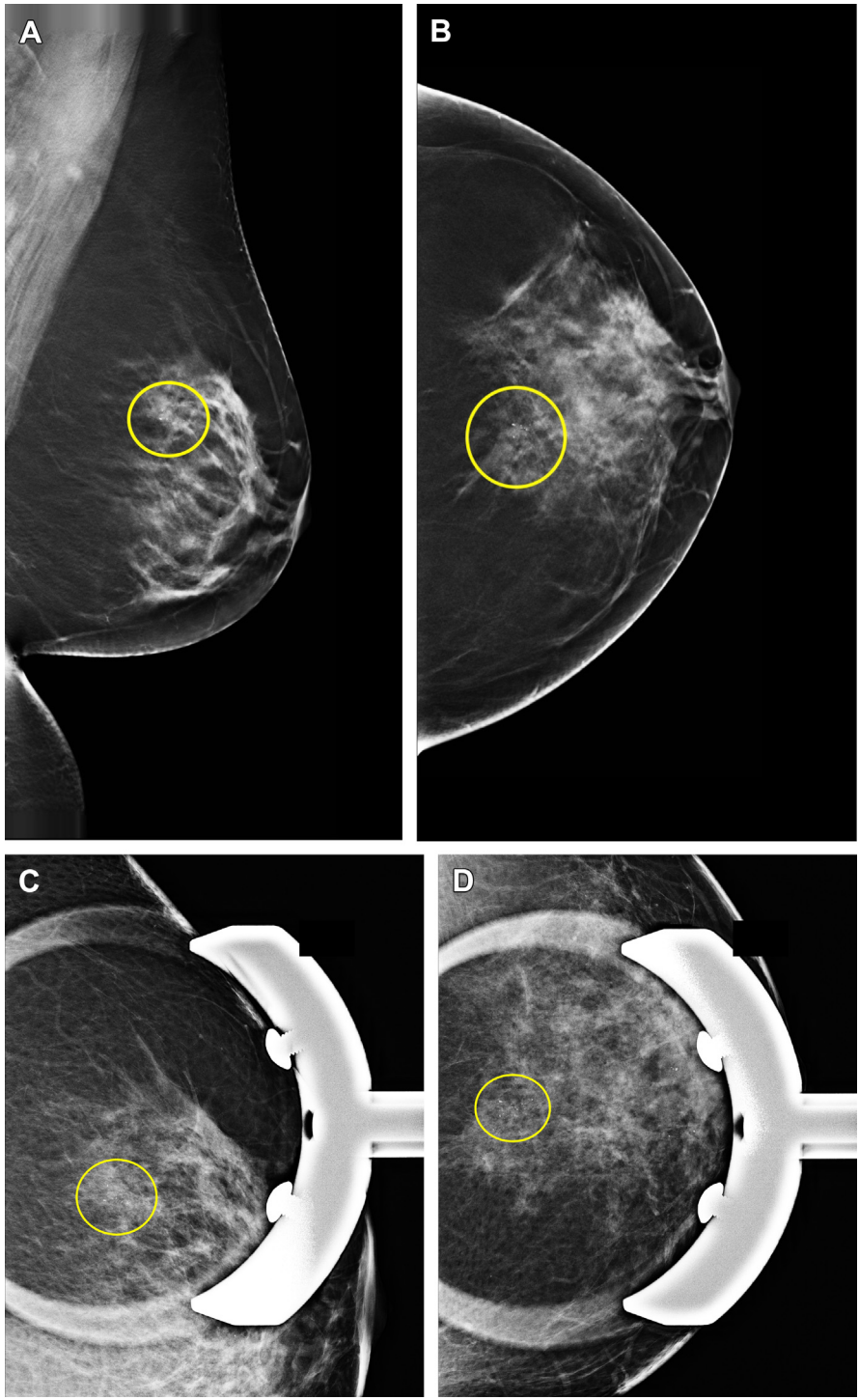

Fig. 3. Mediolateral oblique (*A*) and craniocaudal (*B*) slices in a 65 year old undergoing DBT screening mammogram demonstrates a group of faint calcifications (*circle*) in the 12:00 position of the left breast. For comparison, magnification mammogram [(*C*) lateral, (*D*) craniocaudal] demonstrates a group of fine pleomorphic calcifications (*circles* in (*C*) and (*D*)) with biopsy under stereotactic guidance and shown to be low-grade ductal carcinoma in situ.

breast MRI, DBT is limited in evaluation of the chest wall and has not been thoroughly studied to change the current standard of preoperative MRI.

Clinical Example of Extent of Disease

Fig. 4 demonstrates a case of multifocal breast cancer identified on DBT screening evaluation.

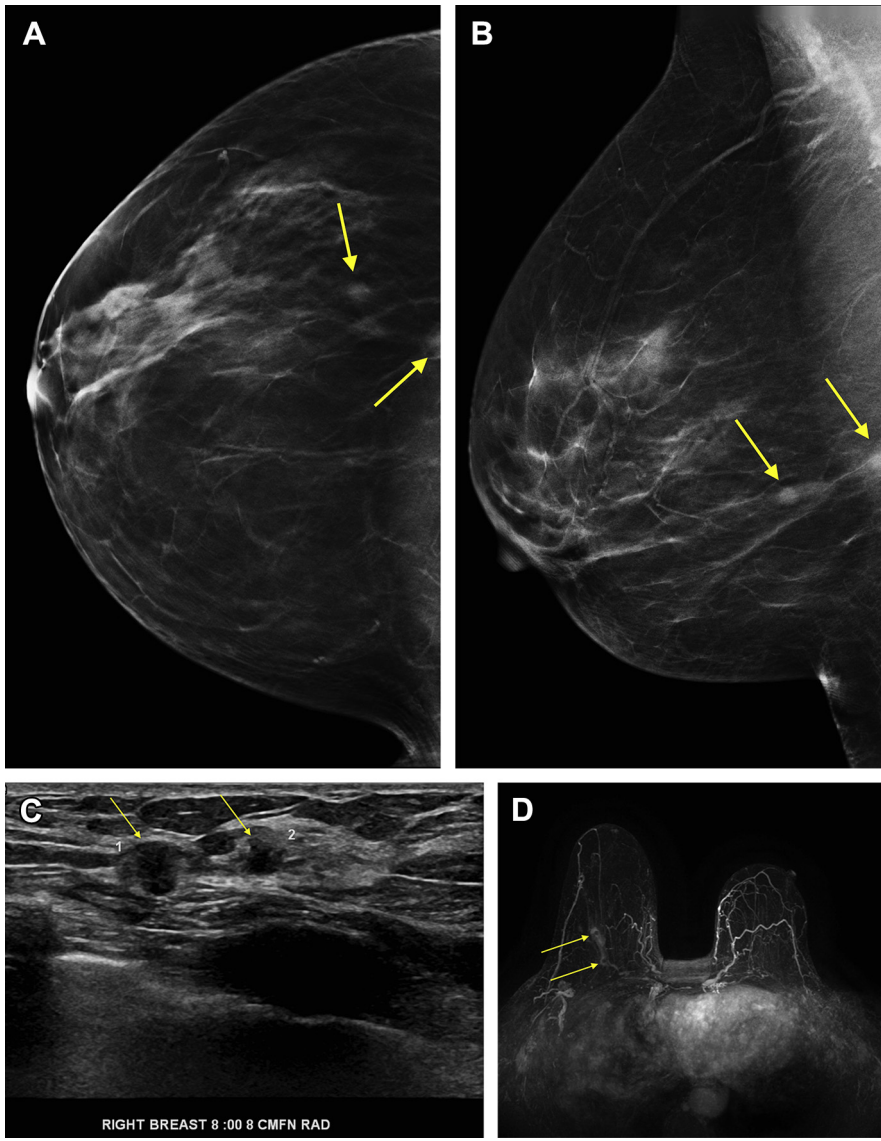

Fig. 4. Craniocaudal (*A*) and mediolateral oblique (*B*) slices from a DBT screening study in a 72-year-old woman demonstrates two focal asymmetries (*arrows*) in the lower outer right breast. (*C*) Targeted diagnostic ultrasound of the lesion demonstrates two masses (*arrows*), which were biopsy-proven invasive ductal carcinoma. (*D*) Preoperative breast MRI also demonstrates the multifocal breast cancer (*arrows*) and no additional findings.

INVASIVE LOBULAR CANCER

Detection of the extent of invasive lobular carcinoma (ILC) is a challenge on FFDM because ILC cells grow in files in between glandular structures with minimal distortion of architecture.[39] Because of this, it is common for FFDM to underestimate the extent of ILC. DBT enhances margin assessment on mammograms and according to Mariscotti and colleagues,[40] it provides a more accurate measurement of the size of all invasive tumors including ILC. A recent article by Chamming's and coworkers[41] also demonstrated significant increase in conspicuity of visualizing ILC in 23 patients on DBT as compared with 2D; however, their data did not demonstrate any significant improvement in determining the size of ILC when DBT was used.

HIGH-RISK PATIENT EVALUATION

In a detailed search of the literature, there were no dedicated studies or manuscripts that specifically evaluated the effects of DBT in the high-risk patient. In a study by Margolies and colleagues[42] evaluating how DBT changed patient management in a tertiary care facility, a subgroup of high-risk patients was identified and included patients with BRCA gene mutations and high risk based on family history or previous atypical or malignant biopsies. In the screening group of 711 patients in this study, 185 or 26.1% were considered high risk. No incremental benefit was shown in the subset of high-risk patients undergoing DBT. The authors suggest that the subgroup analyzed was too small to demonstrate a benefit from screening high-risk populations with DBT. Large and long-term studies are needed to determine if high-risk women are better served by screening them with DBT.

RADIAL SCAR AND SCLEROSING PAPILLARY LESIONS

The addition of DBT to 2D mammography has been shown to increase the detection rate of invasive cancers. However, several studies have also shown an increased sensitivity to stellate distortions simulating malignancy, increasing the recall rate, which has its associated adverse effects including psychosocial distress and decreased willingness to participate in subsequent screening. Because DBT reduces the effect of overlapping breast parenchyma, the characterization of spiculated tumors has increased.

An analysis of findings leading to recall in the Malmo Breast Tomosynthesis Screening Trial by Lång and colleagues[43] showed that stellate distortion was the major cause of recall when using either DBT or 2D mammography. However, there was a higher proportion of stellate distortion leading to recall in the DBT group compared with 2D mammogram alone (40.5% vs 31.9%). The use of DBT was able to identify more radial scars, postoperative scar tissue, sclerosing papillary lesions, and other benign lesions compared with 2D mammography alone. However, there were significantly fewer callbacks of round lesions (fibroadenomas and cysts) using DBT compared with digital mammography. Thus, although DBT may increase the callback rate for benign lesions, such as radial scar or sclerosing papillary lesion, it may also reduce further assessment of benign cysts and fibroadenomas. A longitudinal analysis done by Lang and colleagues[43] showed a drop in the false-positive callback rate in DBT readers over time, indicating that specificity in identifying lesions with DBT is improved with increased experience.

Fig. 5 illustrates postoperative scar and radial scar, both of which are readily identified by the long straight lines and stellate distortion.

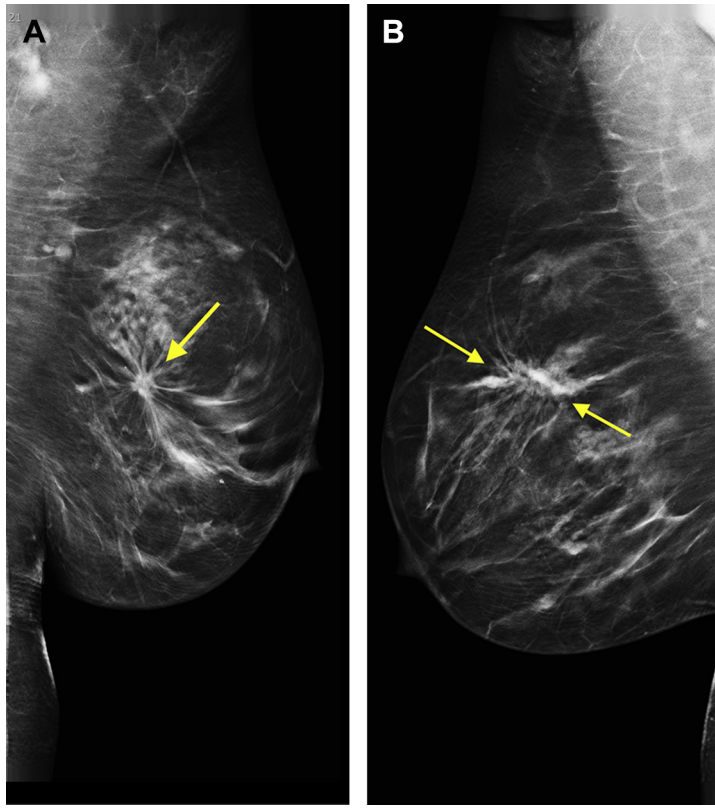

Fig. 5. (*A*) Single mediolateral oblique DBT slice in a 53 year old status post lumpectomy demonstrates architectural distortion (*arrow*) at the postsurgical scar. (*B*) Single mediolateral oblique DBT slice in another patient. Architectural distortion (Between *arrows*) was biopsy proven to be radial scar with atypia, which was surgically excised and showed no upgrade to malignancy.

DIGITAL BREAST TOMOSYNTHESIS–GUIDED BIOPSY AND SECOND-LOOK DIGITAL BREAST TOMOSYNTHESIS AFTER MRI

In addition to conventional stereotactic biopsy of asymmetries and calcifications, DBT has been used to perform image-guided biopsy of targets, such as architectural distortions that were not clearly seen on FFDM and demonstrated no ultrasound correlate.[44] Similarly, preoperative localization of tumors or areas of architectural distortion can be performed under DBT guidance. A special attachment and software localization package is available in most but not all of the currently available DBT units. In addition DBT has been used to evaluate surgical specimens. Urano and colleagues[45] demonstrated that DBT can provide a superior assessment of size of DCIS and extent of intraductal component on surgical specimens as compared with conventional 2D mammography in 65 surgical specimens.

Finally, DBT has been used to evaluate MRI-detected findings. A study by Clauser and colleagues[46] on 84 additional MRI findings in patients with breast cancer demonstrated that second-look ultrasound alone detected 52% of additional MRI findings, whereas adding second-look DBT to ultrasound resulted in identifying 75% of

additional MRI findings. Very similar data were presented by Mariscotti and colleagues[47] where adding DBT to second-look ultrasound resulted in overall detection of 89% of MRI-detected additional lesions. A combination of MRI-directed ultrasound and DBT, with DBT biopsy and wire localization capability, could potentially avoid the need of costly and not readily available MRI-guided interventions.

SUMMARY

DBT has quickly emerged as a better mammogram for all types of breast densities, although patients with dense breasts seem to benefit the most. The radiation dose associated with DBT is well less than the FDA-allowed maximum from radiographic mammography studies and the use of synthetic views will lead to further minimizing radiation exposure. The evidence presented shows that patients undergoing DBT will have more breast cancers detected and fewer callbacks for additional imaging. There will be, however, an increase in the detection of spiculated lesions, such as radial scars. More studies are underway to evaluate the accuracy and benefits of DBT. Of particular interest is the effectiveness of DBT in high-risk patients and accuracy compared with MRI.

REFERENCES

1. Tabar L, Yen MF, Vitak B, et al. Mammography service screening and mortality in breast cancer patients: 20-year follow-up before and after introduction of screening. Lancet 2003;361(9367):1405–10.
2. Tabar L, Vitak B, Chen TH, et al. Swedish two-county trial: impact of mammographic screening on breast cancer mortality during 3 decades. Radiology 2011;260(3):658–63.
3. Frisell J, Lidbrink E, Hellström L, et al. Followup after 11 years–update of mortality results in the Stockholm mammographic screening trial. Breast Cancer Res Treat 1997;45(3):263–70.
4. Alexander FE, Anderson TJ, Brown HK, et al. 14 years of follow-up from the Edinburgh randomised trial of breast-cancer screening. Lancet 1999;353(9168):1903–8.
5. Andersson I, Aspegren K, Janzon L, et al. Mammographic screening and mortality from breast cancer: the Malmo mammographic screening trial. BMJ 1988;297(6654):943–8.
6. Bjurstam N, Björneld L, Duffy SW, et al. The Gothenburg breast screening trial: first results on mortality, incidence, and mode of detection for women ages 39-49 years at randomization. Cancer 1997;80(11):2091–9.
7. Pisano ED, Gatsonis C, Hendrick E, et al. Diagnostic performance of digital versus film mammography for breast-cancer screening. N Engl J Med 2005;353(17):1773–83.
8. Whitehead J, Carlile T, Kopecky KJ, et al. Wolfe mammographic parenchymal patterns. A study of the masking hypothesis of Egan and Mosteller. Cancer 1985;56(6):1280–6.
9. Niklason LT, Christian BT, Niklason LE, et al. Digital tomosynthesis in breast imaging. Radiology 1997;205(2):399–406.
10. Sechopoulos I. A review of breast tomosynthesis. Part I. The image acquisition process. Med Phys 2013;40(1):014301.
11. Sechopoulos I. A review of breast tomosynthesis. Part II. Image reconstruction, processing and analysis, and advanced applications. Med Phys 2013;40(1):014302.

12. Rodríguez-Ruiz A, Castillo M, Garayoa J, et al. Evaluation of the technical performance of three different commercial digital breast tomosynthesis systems in the clinical environment. Phys Med 2016;32(6):767–77.
13. Hu YH, Zhao B, Zhao W. Image artifacts in digital breast tomosynthesis: investigation of the effects of system geometry and reconstruction parameters using a linear system approach. Med Phys 2008;35(12):5242–52.
14. Wu T, Moore RH, Kopans DB. Voting strategy for artifact reduction in digital breast tomosynthesis. Med Phys 2006;33(7):2461–71.
15. Förnvik D, Andersson I, Svahn T, et al. The effect of reduced breast compression in breast tomosynthesis: human observer study using clinical cases. Radiat Prot Dosimetry 2010;139(1–3):118–23.
16. Sechopoulos I, Sabol JM, Berglund J, et al. Radiation dosimetry in digital breast tomosynthesis: report of AAPM Tomosynthesis Subcommittee Task Group 223. Med Phys 2014;41(9):091501.
17. Svahn TM, Houssami N, Sechopoulos I, et al. Review of radiation dose estimates in digital breast tomosynthesis relative to those in two-view full-field digital mammography. Breast 2015;24(2):93–9.
18. Paulis LE, Lobbes MB, Lalji UC, et al. Radiation exposure of digital breast tomosynthesis using an antiscatter grid compared with full-field digital mammography. Invest Radiol 2015;50(10):679–85.
19. Shin SU, Chang JM, Bae MS, et al. Comparative evaluation of average glandular dose and breast cancer detection between single-view digital breast tomosynthesis (DBT) plus single-view digital mammography (DM) and two-view DM: correlation with breast thickness and density. Eur Radiol 2015;25(1):1–8.
20. Houssami N, Turner RM. Rapid review: estimates of incremental breast cancer detection from tomosynthesis (3D-mammography) screening in women with dense breasts. Breast 2016;30:141–5.
21. Houssami N. Digital breast tomosynthesis (3D-mammography) for screening women with dense breasts. Expert Rev Med Devices 2016;13(6):515–7.
22. Destounis SV, Morgan R, Arieno A. Screening for dense breasts: digital breast tomosynthesis. AJR Am J Roentgenol 2015;204(2):261–4.
23. Daskalaki A, Bliznakova K, Pallikarakis N. Evaluation of the effect of silicone breast inserts on X-ray mammography and breast tomosynthesis images: a Monte Carlo simulation study. Phys Med 2016;32(2):353–61.
24. Ciatto S, Houssami N, Bernardi D, et al. Integration of 3D digital mammography with tomosynthesis for population breast-cancer screening (STORM): a prospective comparison study. Lancet Oncol 2013;14(7):583–9.
25. Gilbert FJ, Tucker L, Gillan MG, et al. The TOMMY trial: a comparison of TOMosynthesis with digital MammographY in the UK NHS Breast Screening Programme–a multicentre retrospective reading study comparing the diagnostic performance of digital breast tomosynthesis and digital mammography with digital mammography alone. Health Technol Assess 2015;19(4):i–xxv, 1–136.
26. Rafferty EA, Park JM, Philpotts LE, et al. Assessing radiologist performance using combined digital mammography and breast tomosynthesis compared with digital mammography alone: results of a multicenter, multireader trial. Radiology 2013;266(1):104–13.
27. Rosenberg RD, Yankaskas BC, Abraham LA, et al. Performance benchmarks for screening mammography. Radiology 2006;241(1):55–66.
28. Friedewald SM, Rafferty EA, Rose SL, et al. Breast cancer screening using tomosynthesis in combination with digital mammography. JAMA 2014;311(24):2499–507.

29. Rafferty EA, Durand MA, Conant EF, et al. Breast cancer screening using tomosynthesis and digital mammography in dense and nondense breasts. JAMA 2016;315(16):1784–6.
30. Haas BM, Kalra V, Geisel J, et al. Comparison of tomosynthesis plus digital mammography and digital mammography alone for breast cancer screening. Radiology 2013;269(3):694–700.
31. Sharpe RE Jr, Venkataraman S, Phillips J, et al. Increased cancer detection rate and variations in the recall rate resulting from implementation of 3D digital breast tomosynthesis into a population-based screening program. Radiology 2016; 278(3):698–706.
32. Kopans D, Gavenonis S, Halpern E, et al. Calcifications in the breast and digital breast tomosynthesis. Breast J 2011;17(6):638–44.
33. Tagliafico A, Mariscotti G, Durando M, et al. Characterisation of microcalcification clusters on 2D digital mammography (FFDM) and digital breast tomosynthesis (DBT): does DBT underestimate microcalcification clusters? Results of a multicentre study. Eur Radiol 2015;25(1):9–14.
34. Destounis SV, Arieno AL, Morgan RC. Preliminary clinical experience with digital breast tomosynthesis in the visualization of breast microcalcifications. J Clin Imaging Sci 2013;3:65.
35. Berger N, Schwizer SD, Varga Z, et al. Assessment of the extent of microcalcifications to predict the size of a ductal carcinoma in situ: comparison between tomosynthesis and conventional mammography. Clin Imaging 2016;40(6):1269–73.
36. Mun HS, Kim HH, Shin HJ, et al. Assessment of extent of breast cancer: comparison between digital breast tomosynthesis and full-field digital mammography. Clin Radiol 2013;68(12):1254–9.
37. Mariscotti G, Houssami N, Durando M, et al. Accuracy of mammography, digital breast tomosynthesis, ultrasound and MR imaging in preoperative assessment of breast cancer. Anticancer Res 2014;34(3):1219–25.
38. Kim WH, Chang JM, Moon HG, et al. Comparison of the diagnostic performance of digital breast tomosynthesis and magnetic resonance imaging added to digital mammography in women with known breast cancers. Eur Radiol 2016;26(6): 1556–64.
39. Mann RM, Veltman J, Barentsz JO, et al. The value of MRI compared to mammography in the assessment of tumour extent in invasive lobular carcinoma of the breast. Eur J Surg Oncol 2008;34(2):135–42.
40. Mariscotti G, Durando M, Houssami N, et al. Digital breast tomosynthesis as an adjunct to digital mammography for detecting and characterising invasive lobular cancers: a multi-reader study. Clin Radiol 2016;71(9):889–95.
41. Chamming's F, Kao E, Aldis A, et al. Imaging features and conspicuity of invasive lobular carcinomas on digital breast tomosynthesis. Br J Radiol 2017;90: 20170128.
42. Margolies L, Cohen A, Sonnenblick E, et al. Digital breast tomosynthesis changes management in patients seen at a tertiary care breast center. ISRN Radiol 2014; 2014:658929.
43. Lång K, Nergården M, Andersson I, et al. False positives in breast cancer screening with one-view breast tomosynthesis: an analysis of findings leading to recall, work-up and biopsy rates in the Malmö Breast Tomosynthesis screening trial. Eur Radiol 2016;26(11):3899–907.
44. Durand MA, Wang S, Hooley RJ, et al. Tomosynthesis-detected architectural distortion: management algorithm with radiologic-pathologic correlation. Radiographics 2016;36(2):311–21.

45. Urano M, Shiraki N, Kawai T, et al. Digital mammography versus digital breast tomosynthesis for detection of breast cancer in the intraoperative specimen during breast-conserving surgery. Breast Cancer 2016;23(5):706–11.
46. Clauser P, Carbonaro LA, Pancot M, et al. Additional findings at preoperative breast MRI: the value of second-look digital breast tomosynthesis. Eur Radiol 2015;25(10):2830–9.
47. Mariscotti G, Houssami N, Durando M, et al. Digital breast tomosynthesis (DBT) to characterize MRI-detected additional lesions unidentified at targeted ultrasound in newly diagnosed breast cancer patients. Eur Radiol 2015;25(9):2673–81.